

The skull in chronic sarcoidosis

D. Landsberger, D. Rav'e and G. Friedman

Lipid Research Laboratory, Department of Medicine B, Hadassah University Hospital, P.O.B. 12000, Jerusalem 91120, Israel.

Summary: A report of a 63 year old woman with giant osteolytic skull lesions simulating metastatic disease, and generalized cutaneous lesions is presented. Biopsy of a skin lesion revealed non-caseating granulomas compatible with sarcoidosis. The literature dealing with calvarial sarcoidosis is reviewed.

Introduction

Sarcoidosis is a well-established clinical entity of unknown aetiology, characterized by non-caseating granulomas that can involve any organ or tissue. Osseous involvement is a well known feature. The reported incidence varies between 1-26%.¹ Bone involvement is usually limited to the short tubular bones of the hands and feet. The long bones and vertebrae are seldom involved. Sarcoidosis of the skull is a very rare manifestation of sarcoid with only eleven reported cases over the past 40 years.²⁻¹² The present authors wish to report on another patient with sarcoidosis and giant osteolytic lesions in the skull that mimicked a metastatic malignancy. The rarity of this clinical manifestation justifies its report.

Case report

A 63 year old woman was admitted to the Department of Ophthalmology, complaining of painful, red periorbital swelling on the right, of 3 days' duration. A diagnosis of periorbital cellulitis was made and treatment initiated with Orbicillin with good response. Since facial X-rays revealed blurring of the left maxillary sinus, maxillary sinus washout was performed and antibiotic therapy continued. Further skull X-rays revealed the presence of multiple, large osteolytic lesions in the skull (Figure 1). A tentative diagnosis of disseminated neoplasm was made and the patient was transferred to the Department of Medicine for further investigation.

Her past history revealed rheumatic heart disease diagnosed at age 17, and mitral valve replacement in 1979. For 3 years she had noticed the presence of violaceous skin lesions on her arms, face and back, which had not been investigated.

The patient denied weight loss, fever or constitutional symptoms, but had mild dyspnoea on exertion, present for many years. Physical examination on admission showed a well-nourished woman in no distress. There was no lymphadenopathy and no signs of heart failure. A mild mitral systolic murmur was present, and good air entry to both lungs with no adventitious sounds. No abdo-

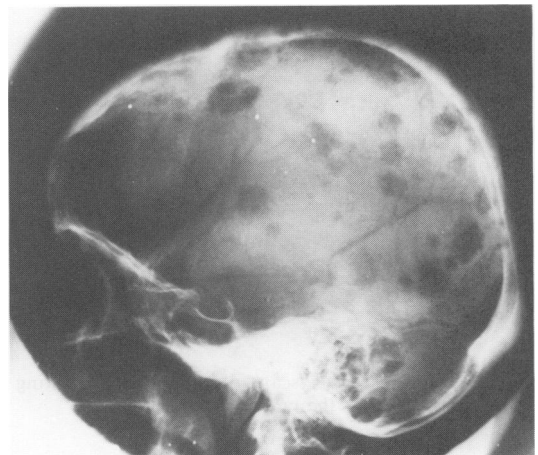


Figure 1 Lateral film of the skull disclosing multiple giant lytic foci.

minal visceromegaly was noted and no neurological abnormalities were present. On her arms, face and back there were numerous flesh-coloured to violaceous nodules, measuring 1 to 2 cm in diameter. Examination of the patient's eyes disclosed no evidence of uveitis.

Erythrocyte sedimentation rate was 30 mm/h, haemoglobin, white cell count and thrombocyte count were normal as were serum electrolytes, calcium, phosphorus, alkaline phosphatase and liver function tests. A tuberculin skin test was negative at 72 hours.

Chest X-ray revealed enlarged heart, hilar prominence and interstitial lung infiltrates. A computed tomograph (CT) scan of chest and abdomen disclosed hilar lymphadenopathy, splenomegaly and retro peritoneal lymphadenopathy. Bilateral xeromammographic examination disclosed no evidence of malignant tumour. A ^{99m}Tc bone scan (Figure 2) revealed numerous areas of increased uptake in the skull. A gallium-67 scan showed marked bilateral uptake in the lungs with a picture compatible with a diffuse interstitial process. In addition, there was marked uptake of gallium in the skull. There was no radiological or bone scan evidence of involvement of other parts of the skeleton. Bronchoscopy was normal except for a suspicious nasopharyngeal plaque which was biopsied. A biopsy of one of the skin lesions was also undertaken. The pathological report of both specimens was that of multiple non-caseating granulomas, containing epithelioid cells

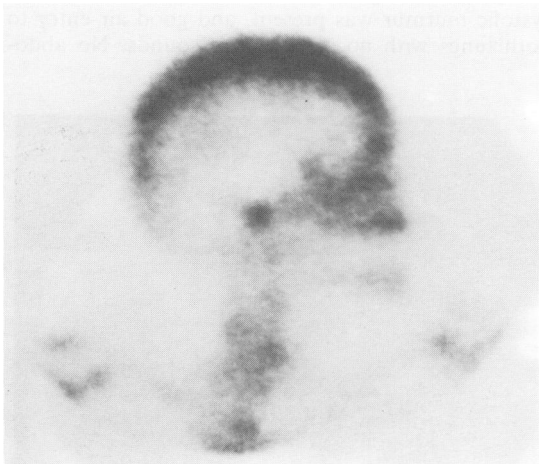

Figure 2 ^{99m}Tc bone scan of the skull, showing increased uptake at the cranial vertex.

and multinucleated giant cells, most typical of sarcoid.

In view of the positive biopsy results from two sites, history, X-ray and nuclear scan findings, a diagnosis of systemic sarcoidosis was made. The patient was discharged with no specific therapy. During a follow-up period of 10 months, the patient has remained well.

Discussion

Osseous lesions in sarcoidosis are usually seen in the chronic stages of the disease. Mayok and colleagues¹ reported an overall incidence of 14% in a review of a large series, but the range may vary between 1 to 26%.^{13,14}

Bony involvement is most frequently limited to the vertebrae, hands and feet, and especially to the terminal phalanges. Localization to the skull is among the rarest findings in sarcoidosis, only eleven cases having been described during the past 40 years.²⁻¹¹ The calvarial lesions in the patient presented in this report were similar to those described previously. The lesions in the skull appear on X-ray as multiple areas of bone translucency with well-demarcated margins with no surrounding sclerotic or reactive changes. The diameter of the lesions varied from 0.1 cm to 4 cm. In contrast to metastatic neoplasms, the calvarial tables are intact, and serum alkaline phosphatase is usually normal,^{3,6,8} in spite of the massive bone destruction. Although the cause for the osteolytic process in sarcoidosis is not known, the assumption is that it might be related to increased production of 1,25-dihydroxycholecalciferol by the sarcoid granulomata.^{16,17}

Clinically calvarial sarcoidosis might manifest itself by headaches and tenderness over the vertex of the skull.⁵ However, in most reported cases, the lesions are discovered incidentally. Since partial or complete resolution may occur spontaneously, the role of adrenocortical steroids in the treatment of calvarial sarcoidosis cannot be assessed.⁹

The association of osseous and cutaneous lesions in chronic sarcoidosis has previously been stressed.^{3,15} The patient presented here showed the coexistence of cutaneous and skull sarcoidosis. A skin biopsy contributed to the establishment of the diagnosis.

Recognizing that lytic lesions in the skull can be found in sarcoidosis is important in order to establish a proper differential diagnosis.

References

1. Mayok, R.H., Betrand, P., Morrison, C.E. & Scott, J.H. Manifestations of sarcoidosis: analysis of 145 patients with a review of nine series selected from the literature. *Am J Med* 1963, **35**: 67-89.
2. Posner, I. Sarcoidosis: a case report. *J Pediatr* 1942, **20**: 486-495.
3. Tierstein, A.S., Wolf, B.S. & Siltzbach, L.E. Sarcoidosis of the skull. *N Engl J Med* 1961, **265**: 65-68.
4. Turner, O.A. & Weiss, S.R. Sarcoidosis of the skull: report of a case. *Am J Roentgenol Radium Therm Nucl Med* 1969, **105**: 322-325.
5. Olsen, T.G. Sarcoidosis of the skull. *Radiology* 1963, **80**: 232-234.
6. Franco-Saenz, R., Ludwig, G.D. & Henderson, L.W. Sarcoidosis of the skull. *Ann Intern Med* 1970, **72**: 929-931.
7. Zimmerman, R. & Leeds, N.E. Calvarial and vertebral sarcoidosis. *Radiology* 1976, **119**: 384.
8. Case Records of the Massachusetts General Hospital. *N Engl J Med* 1982, **307**: 1257-1264.
9. Cinti, D.C., Hawkins, H.B. & Slavin, J.D. Radioisotope bone scanning in a case of sarcoidosis. *Clin Nucl Med* 1986, **10**: 192-194.
10. Bodie, F.B., Kheir, S.M. & Emily, F.O. Calvarial sarcoid mimicking metastatic disease. *J Am Acad Dermatol* 1980, **3**: 401-405.
11. Prashant, K.R. & Marta, A.K. Combined calvarial and CNS sarcoidosis. Report of 2 cases. *Arch Neurol* 1981, **38**: 261-262.
12. Prashant, K.R., Singh, R. & Vieras, F. Extra-pulmonary localisation of gallium in sarcoidosis. *Clin Nucl Med* 1984, **12**: 9-15.
13. Reisner, D. Boeck's sarcoid and systemic sarcoidosis. Study of 35 cases. *Am Rev Tuberc* 1944, **49**: 289-307 and 437-462.
14. Lofgren, S. Primary pulmonary sarcoidosis. Clinical course and prognosis. *Acta Med Scand* 1953, **145**: 465-474.
15. James, D.G. Dermatological aspects of sarcoidosis. *Q J Med* 1959, **28**: 109-125.
16. Papapoullous, S.E., Clemens, T.L., Fraher, L.J., Lewin, I.G., Sandler, L.M. & O'Riordan, J.L.H. 1,25 Dihydroxycholecalciferol in the pathogenesis of the hypercalcaemia of sarcoidosis. *Lancet* 1979, **i**: 627-630.
17. Barbour, G.L., Coburn, J.W., Slatopolsky, E., Norman, A.W. & Horst, R.L. Hypercalcaemia in an anephric patient with sarcoidosis: Evidence for external generation of 1,25-dihydroxyvitamin D. *N Engl J Med* 1981, **305**: 440-443.