

Histiocytic cytophagic panniculitis

D.A. Hilton¹, B.P. O'Malley² and S.T.S. Durrant³

¹Department of Histopathology, ²University Department of Medicine and ³Department of Haematology, Leicester Royal Infirmary, Infirmary Square, Leicester LE1 5WW, UK.

Summary: A 33 year old man developed fever, malaise, jaundice, pancytopenia, coagulation abnormalities, hepatomegaly, pleural effusions and a subcutaneous lump. Biopsies revealed a lobular panniculitis with the presence of cytophagic histiocytes; erythrophagocytosis was also demonstrated in the liver and bone marrow. Despite the use of chemotherapy (CHOP) his clinical condition deteriorated and he died 5 months after presentation. This illness is consistent with the recently described syndrome of histiocytic cytophagic panniculitis.

Introduction

Histiocytic cytophagic panniculitis is a recently described syndrome characterized by fever, hepato-splenomegaly, pancytopenia and abnormalities of liver function and blood coagulation.¹ Histologically there is infiltration of subcutaneous tissue, bone marrow, liver, spleen and lymph nodes with morphologically benign histiocytic cells showing marked erythrophagocytosis and leucophagocytosis. Although showing none of the usual cytological features of malignant histiocytosis, the majority of the reported cases have followed a fatal course. We report a case of this condition and review the literature.

Case report

A 33 year old male lorry driver presented with a 3-week history of fever, sweats and malaise. On examination he was found to have a subcutaneous lump on his forearm, jaundice and hepatomegaly.

Investigations showed a pancytopenia (haemoglobin 97 g/l, white cell count $2.0 \times 10^9/l$, platelets $59 \times 10^9/l$), normal ESR, raised C-reactive protein (7 mg/l), and abnormal liver function tests (bilirubin 32 $\mu\text{mol/l}$, aspartate transaminase 252 IU/l, alkaline phosphatase 430 IU/l, albumin 29 g/l). The initial monospot test was positive but several repeat tests were all negative. Viral titres and cultures of blood, urine, stool and bone marrow culture were negative. Titres for Q fever, psittacosis, brucella, leptospira and legionella were also negative as was the autoantibody screen. His initial chest X-ray was normal but he subsequently developed bilateral pleural effusions and ascites. Coagulation studies were abnormal: international

normalized ratio 1.4, partial thromboplastin time 49 s (control 41 s), fibrinogen 0.7 g/l, fibrinogen degradation products 500 mg/ml, thrombin time 31 s (control 15 s) the skin biopsy showed panniculitis. A bone marrow aspirate was reported as normal and a liver biopsy reported prominent erythrophagocytosis.

A trial of steroids (prednisolone 20 mg/day) induced an initial response in his temperature and cytopenias, but after 5 weeks his disease relapsed.

Following a transfer to the Leicester Royal Infirmary a repeat marrow aspirate (and trephine biopsy) showed marked erythrophagocytosis. This, combined with the previous history and investigations, led to a clinical diagnosis of a malignant histiocytosis. He was given combination chemotherapy (CHOP) which produced an initial clinical response but his symptoms recurred between courses. He received a total of three courses of chemotherapy but his clinical condition deteriorated with recurrent pyrexia, multiple skin lesions, pleural effusions, ascites, peripheral oedema, pancytopenia and deranged liver function tests. He died 5 months after presentation.

Pathology

Biopsy of the subcutaneous lump showed a lobular panniculitis with extensive fat necrosis, haemorrhage and an infiltrate of lymphocytes and histiocytes many of which contained phagocytosed leucocytes and erythrocytes (Figures 1 and 2). Liver biopsy revealed fatty change and prominent Kupffer cells showing erythrophagocytosis. Bone marrow examination at this time was unremarkable.

A repeat bone marrow examination revealed florid histiocytosis with active erythrophagocytosis

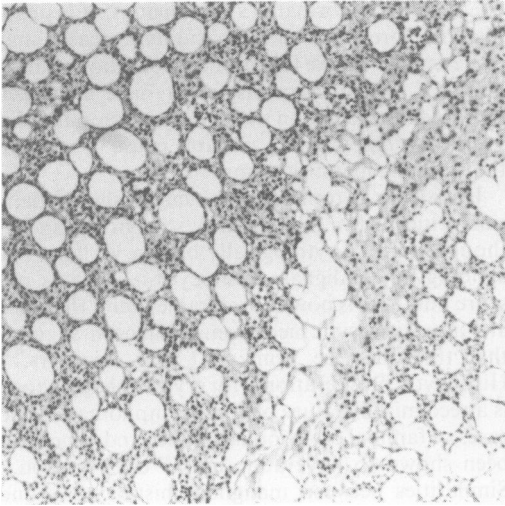


Figure 1 Section for subcutaneous fat showing infiltrate of mononuclear cells (haematoxylin and eosin $\times 100$).

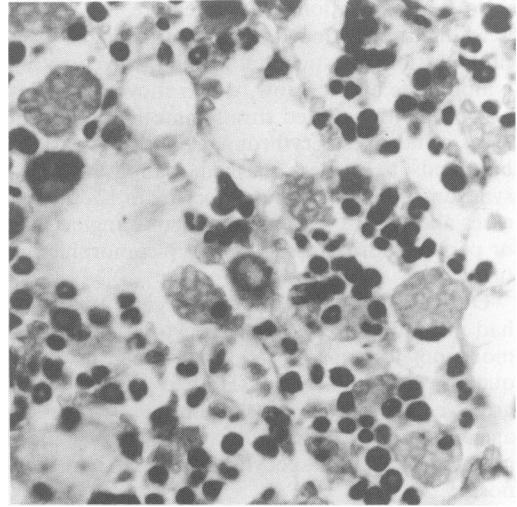


Figure 3 Bone marrow trephine showing prominent erythrophagocytosis by benign histiocytes (haematoxylin and eosin $\times 400$).

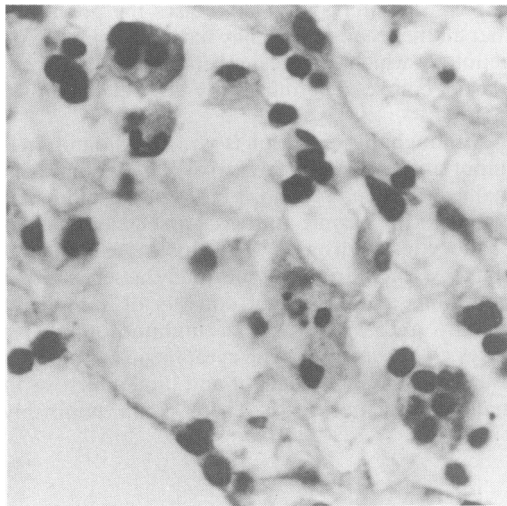


Figure 2 High power field of subcutaneous fat showing phagocytic histiocytes (haematoxylin and eosin $\times 400$).

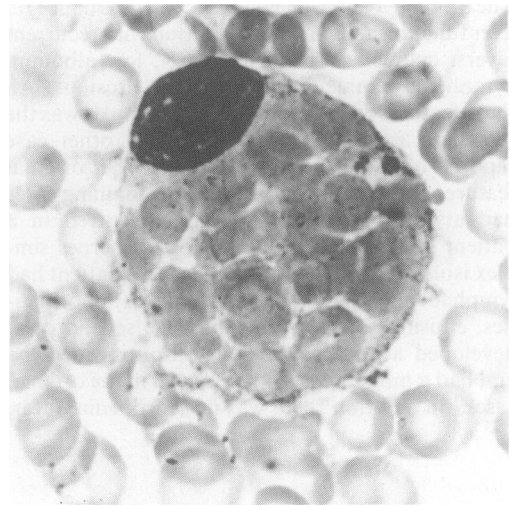


Figure 4 Bone marrow smear showing histiocytes filled with ingested erythrocytes (May-Grunwald-Giemsa $\times 1000$).

but no cytological atypia (Figures 3 and 4).

Post mortem examination confirmed the presence of ascites and pleural effusions. There was both hepatomegaly (1900 g) and splenomegaly (425 g) but no lymphadenopathy. Histological infiltration of bone marrow, spleen and lymph nodes with cytophagic histiocytes was confirmed. The liver showed fatty change but the sinusoidal spaces were too autolytic to comment upon. The post-mortem diagnosis was histiocytic cytophagic panniculitis.

Discussion

Histiocytic cytophagic panniculitis poses diagnostic problems because the progressive clinical deterioration typical of a malignant process is associated with cytologically benign disease.

In the virus-associated haemophagocytic syndrome,² which has some clinical and pathological similarities to our patient, reported adult cases are on immunosuppressive agents and either die in the acute episode or make a full recovery in 1–8 weeks.

Also skin infiltration is not a feature.

Malignant histiocytosis is characterized by a proliferation of histiocytes, within the liver, spleen, lymph node and marrow, which show cytological atypia, multinucleated forms, mitotic figures and areas of necrosis. Erythrophagocytosis is variable but tends to be less marked than in the viral syndrome. Skin involvement occurs in 12–50% of cases and consists of a subcutaneous angiocentric or periappendicular infiltrate of pleomorphic histiocytes.^{3,4}

Our patient displayed no cytological atypia and had pronounced erythrophagocytosis. The initial monospot test was positive but numerous subsequent tests were negative. He had a chronic progressive course, was not on immunosuppressive agents, and had skin infiltration. This excluded post-viral haemophagocytic syndrome as a diagnosis.

The clinicopathological features in our case correlate most closely with cytophagic histiocytic panniculitis which is regarded as a variant of malignant histiocytosis. To date 9 other cases of this condition have been described^{1,5–8} (Table I). The original 5 cases¹ all had marked disturbances in liver function and blood coagulation with recurrent fevers, cytopenias, a normal ESR, low albumin, cytophagic panniculitis and 4 had effusions. All these features were present in our patient as was the relentless and fatal course. Of the 4 other case reports one had the majority of the original features and was fatal.⁵ Two of the remaining cases had atypical features. One case⁶ occurred in a patient taking prednisolone who had herpes simplex isolated from her throat. Also this patient had lymphadenopathy and no coagulation abnormalities, effusions or pancytopenia. The second case⁷ developed acute episodes of non-pitting oedema and had a monocytosis not reported in the original cases,¹ in addition there was no leucopenia, fever,

coagulation abnormalities or effusions. It is possible therefore, that the two surviving cases may represent less severe forms of the condition. Raised levels of tumour necrosis factor have also been reported in association with this syndrome and this has been suggested as a possible cause of some of the systemic manifestations.⁸

Histiocytic cytophagic panniculitis shares many similarities with malignant histiocytosis and is thought to be a cytologically benign variant. The aetiology of malignant histiocytosis remains obscure but there is now considerable doubt that they are true histiocytic neoplasms. Isaacson suggests that they may be primary T cell disorders.^{9,10} Histiocytic proliferation with erythrophagocytosis is a recognized feature of T cell lymphomas^{9,11} and cases of familial erythrophagocytic syndrome have been shown to have abnormal T cell function.¹² Similarities between malignant histiocytosis and virus-associated haemophagocytic syndrome are interesting, and it has recently been suggested that some cases of malignant histiocytosis may be a lethal form of Epstein-Barr virus infection^{13,14} and in view of this the initial positive monospot test in our case is interesting. This raises the possibility that all these conditions may have a common viral aetiology which initiates either a reactive or neoplastic course determined by as yet unknown factors.

Although this condition is rare, its recognition is important, especially in view of the differences in management and prognosis between the malignant histiocytic syndrome and virus-associated haemophagocytic syndrome.² Virus-associated haemophagocytic syndrome¹ is normally a self-limiting condition, and treatment consists of supportive therapy and withdrawal of immunosuppressive drugs,² whereas histiocytic cytophagic panniculitis usually follows a malignant and fatal course as in malignant histiocytosis. There is no uniformly

Table I Cases of histiocytic cytophagic panniculitis in the literature

| | Sex/Age | Fever | Abnormal coagulation | Effusion | Outcome | Treatment |
|--------------------------------------|---------|-------|----------------------|----------|----------|--------------|
| Winkleman <i>et al.</i> ¹ | F 27 | Yes | Yes | Yes | Death | * |
| | F 23 | Yes | Yes | Yes | Death | * |
| | M 26 | Yes | Yes | Yes | Death | * |
| | F 81 | No | Yes | No | Death | * |
| | F 58 | Yes | Yes | Yes | Death | * |
| Marsh <i>et al.</i> ⁵ | M 30 | Yes | Yes | * | Death | * |
| March <i>et al.</i> ⁶ | F 60 | Yes | No | No | Survival | Prednisolone |
| Barron <i>et al.</i> ⁷ | M 40 | No | No | No | Survival | CHOP Bleo |
| Maury <i>et al.</i> ⁸ | M 33 | Yes | * | * | * | CHOP Bleo |
| Current case | M 33 | Yes | Yes | Yes | Death | CHOP |

*Data not available.

agreed upon treatment for malignant histiocytosis but regimes usually involve combination chemotherapy; recently induction with cyclophosphamide, vincristine, doxorubicin and prednisone fol-

lowed by maintenance with alternate courses of vincristine and doxorubicin (CO-PAD) has been shown to be highly effective.¹⁵

References

1. Winkelmann, R.K. & Walter Bowie, E.J. Haemorrhagic diathesis associated with benign cytophagic panniculitis and systemic histiocytosis. *Arch Intern Med* 1980, **140**: 1460-1463.
2. Risdall, R.J., McKena, R.W. & Nesbit, M.E. Virus-associated haemophagocytic syndrome. *Cancer* 1979, **44**: 993-1002.
3. Pileri, S., Mazza, P., Rivano, M.T. *et al.* Malignant histiocytosis (true histiocytic lymphoma) clinicopathological study of 25 cases. *Histopathology* 1985, **9**: 905-920.
4. Ducatman, B.S., Wick, M.R., Morgan, T.N. *et al.* Malignant histiocytosis. *Hum Pathol* 1984, **15**: 368-377.
5. Marsh, W., Opal, S.M. & Fitzpatrick, J.E. Cytophagic histiocytic panniculitis. *Arch Dermatol* 1985, **121**: 910-913.
6. March, L.M., Webb, J. & Eckstein, R.P. Cytophagic panniculitis. *Aust N Z J Med* 1986, **16**: 397-401.
7. Barron, D.R., Davis, B.R., Pomeranz, J.R. *et al.* Cytophagic histiocytic panniculitis. *Cancer* 1985, **55**: 2538-2542.
8. Maury, C.P.J. & Pettersson, T. Detection of circulating tumour necrosis factor in systemic histiocytosis. *Br J Haematol* 1989, **71**: 293-294.
9. Isaacson, P.G. Haemophagocytic syndrome. Differential diagnostic aspects in a case of well-differentiated malignant histiocytosis. Letters to the case. *Path Res Pract* 1988, **183**: 80-85.
10. Isaacson, P.G. Histiocytic malignancy. *Histopathology* 1985, **9**: 1007-1011.
11. Jaffe, E.S., Costa, J., Fauci, A.S. *et al.* Malignant lymphoma and erythrophagocytosis. *Am J Med* 1983, **75**: 741-749.
12. Ladisch, S., Poplack, D.E., Holiman, B. *et al.* Immunodeficiency in familial erythrophagocytic lymphohistiocytosis. *Lancet* 1978, **i**: 581-583.
13. Su, I.J., Hsieh, H.J. & Lee, C.Y. Histiocytic medullary reticulosis: a lethal form of primary EBV infection in young children in Taiwan. *Lancet* 1989, **i**: 389 (letter).
14. Tcherniat, M.C. & Del Fraissy, J.F. Histiocytic medullary reticulosis, a lethal form of primary EBV infection. *Lancet* 1989, **i**: 1265-1266 (letter).
15. Bruigieres, L., Cailland, J.M., Patte, C. *et al.* Multidrug therapy in malignant histiocytosis. *Med Ped Oncol* 1989, **17**: 193-196.