

Sickle cell trait and stroke in the young adult

K. Radhakrishnan, A.K. Thacker, J.C. Maloo and M.A. El-Mangoush

Neurology Unit, Department of Medicine, Medical University, Benghazi, Libya

Summary: Two young patients with sickle cell trait (AS haemoglobinopathy) and ischaemic stroke are reported. The stroke involved the internal carotid artery territory in one and the brainstem in the other. A review of the literature is presented to suggest that the association of sickle cell trait and cerebral infarction is more than coincidental. Haemoglobin electrophoresis should be undertaken routinely in young subjects with ischaemic stroke.

Introduction

Although documented, it is still not widely appreciated that sickle cell trait, the heterozygous state for the sickle cell gene (AS haemoglobinopathy), can cause cerebral infarction. To the best of our knowledge, only 12 patients are reported in English language publications with stroke attributed to sickle cell trait.¹⁻³

Stroke occurs with increased frequency in the younger age group in Afro-Asian countries⁹ and no definite cause to explain this phenomenon is found in the majority.¹⁰ People with sickle cell trait are usually asymptomatic and confirmation of the diagnosis requires detection of sickling and haemoglobin electrophoresis.¹¹

This report of two young subjects with sickle cell trait and stroke emphasizes the importance of investigating for this association when a cerebral infarction occurs without known risk factors.

Case reports

Case 1

An 18 year old, right handed, unmarried black Libyan female developed left hemicranial headache, followed the next day by weakness of right arm and slurred speech. There was no history of heart disease, abdominal pain, haematuria, hypertension, diabetes mellitus, oral contraceptive intake or stroke. On examination, the patient was alert, oriented and co-operative. Speech was dysarthric with mild expressive aphasic defects. The optic fundi and ocular movements were normal. She had a right central facial paresis, 3/5 weakness of the right upper limb, brisk tendon reflexes on the right upper and lower extremities and a right

Babinski sign. Blood pressure was 110/70 mmHg and the rest of the systemic examination revealed no abnormality.

The haemoglobin was 12.5 g/dl; white blood counts, sedimentation rate, blood biochemistry, chest X-ray, electrocardiogram and echocardiogram were normal. Serology for syphilis, L.E. cells and antinuclear factor was negative. Sickling test was positive. Haemoglobin electrophoresis demonstrated 36% haemoglobin S; the remainder was haemoglobin A. Left carotid angiogram disclosed a complete block of the supraclinoid part of the internal carotid artery (Figure 1). She was treated with aspirin and dipyridamole. At one month follow-up, neurological examination revealed only mild clumsiness of right hand movements.

Case 2

A 38 year old, right handed black Libyan male was hospitalized for headache, facial asymmetry, gait disturbance and diplopia of 2 days duration. There was no history of heart disease, hypertension, diabetes mellitus, smoking or drug or alcohol abuse. Examination showed an alert patient with intact memory and a dysarthric speech. The optic fundi disclosed retinal haemorrhages and exudates, and multiple neovascular tufts in and around the optic discs. There was paralysis of abduction of right eye ball and a right peripheral facial paralysis. He had mild weakness of left upper and lower limbs with increased tendon reflexes. The left finger-nose test was clumsy. All modalities of sensation were intact. The blood pressure was 130/80 mmHg. Examination of the heart, chest and abdomen showed no abnormality.

The haemoglobin was 14 g/dl; blood counts, biochemistry, serology for syphilis, electrocardiogram, echocardiogram and cerebrospinal fluid examination evinced no abnormality. The sickling test was positive; haemoglobin electrophoresis

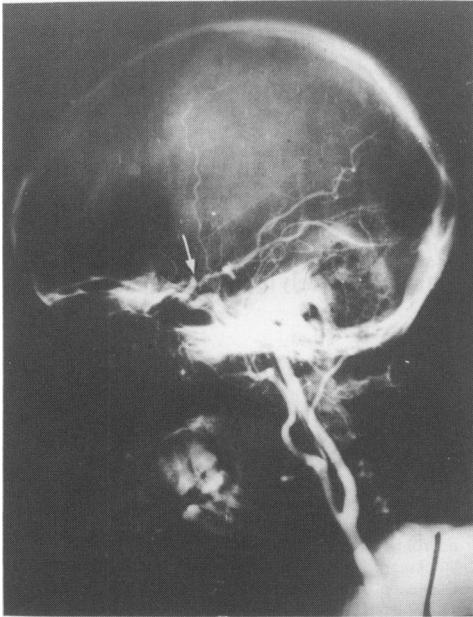


Figure 1 Left carotid angiogram shows complete block (arrow) of the supraclinoid portion of internal carotid artery.

showed 38% HbS and 62% HbA. An enhanced computed tomographic scan disclosed a small area of decreased density involving the right side of pons. He was treated with aspirin. His neurological deficit resolved in the next 3 weeks.

Discussion

In the absence of vasculitis, a source of embolism or other risk factors for cerebrovascular disease such as hypertension, diabetes mellitus, contraceptive pills or smoking leaves sickle cell trait as the only plausible explanation of ischaemic stroke in our

young patients. Neither of them was anaemic and neither exposed to any hypoxic episodes before or at the onset of the neurological deficit.

Sickle cell disease, the homozygous state for the sickle cell gene (SS haemoglobinopathy), is an important risk factor in the development of stroke; most strokes occur in subjects under the age of 15 years.¹² By contrast, sickle cell trait (AS haemoglobinopathy) is considered to be a benign condition. Several studies in large populations have suggested that sickle cell trait does not impair survival.¹¹ Of the 12 cases where an association of stroke and sickle cell trait has been suggested, only 9 offer evidence of confirmation by haemoglobin electrophoresis. The details of 11 cases, including our patients, are summarized in Table I. The age ranged from 12–38 years, mean 24.8 years. Male to female ratio was 2.7:1. Three of them had sino-venous thrombosis, the remainder were ascribed to arterial occlusions. Sickling at the site of vascular occlusion was demonstrated in autopsied cases.^{4,8} In 2 patients anaesthesia and hypoxia were incriminated as precipitating factors; in the rest strokes occurred spontaneously. In our second patient and in one of the cases reported by Reyes,⁸ the stroke involved the brain stem.

It has been traditionally held that the cerebral vessels most frequently involved in children with sickle cell disease and neurological complications are the small venules, capillaries and precapillary arterioles.¹³ However, angiographic studies had disclosed in 6 out of 7 cases, partial or complete occlusion of large cerebral vessels.¹⁴ The internal carotid artery was involved in all 6 patients; the supraclinoid portion, as in our first patient, being affected in all.¹⁴ Occasionally, collateral circulation can be a prominent feature exhibiting a Moyamoya type appearance.¹⁴

Ocular lesions associated with sickle cell trait include retinal vein tortuosity, microaneurysms, retinal haemorrhages and exudates, central retinal artery occlusion and retinitis proliferans.¹⁵ The

Table I Stroke in sickle cell trait

Patient no.	Age (years)	Sex	Diagnosis	Haemoglobin electrophoresis	Reference
1.	26	M	? Temporo-parietal infarct	AS	Ende <i>et al.</i> (1953) ³
2.	25	M	? Cerebral venous thrombosis	AS	
3.	12	M	Sagittal sinus thrombosis	AS	Schenk (1964) ⁴
4.	12	M	Sagittal sinus thrombosis	AS	Dalal <i>et al.</i> , (1974) ⁵
5.	22	M	Bilateral cerebral infarcts	AS	Handler & Perkin (1982) ⁶
6.	24	M	Bilateral cerebral infarcts	AS	Greenberg & Massey (1985) ⁷
7.	35	M	Right middle cerebral artery territory infarct	AS	
8.	32	F	Bilateral cerebral infarcts	AS	Reyes (1989) ⁸
9.	29	F	Pontine infarct, bilateral cerebral infarcts	AS	
10.	18	F	Left internal carotid occlusion	AS	Present report
11.	38	M	Pontine infarct	AS	

M = male; F = female; AS = sickle cell trait.

second patient in the present report had a proliferative retinopathy. Most of the recent reports on sickle cell trait with stroke have not included a detailed description of the optic fundus.⁶⁻⁸

The percentage of the haemoglobin S in sickle cell trait can vary from 25-45%. In carriers who have a high concentration of haemoglobin S, the risk of sickling is not much less than in patients with homozygous sickle cell anaemia.¹⁶ Haemoglobin electrophoresis was not routinely performed during the Benghazi stroke study.⁹ This investigation was not mentioned in the evaluation of risk

factors in a recent review which summarized most of the studies of stroke in the young.¹⁷

The association of sickle cell trait and stroke seems to be more than coincidental. This complication can occur even in the absence of a potential hypoxic episode. A high index of suspicion is required to establish the diagnosis. The sickle cell gene is common among some populations of Africa, Mediterranean region, Middle East and Asia.^{18,19} Haemoglobin electrophoresis should be undertaken routinely in young subjects with stroke.

References

1. Thompson, R.K., Wagner, J.A. & Macleod, M. Sickle cell disease: Report of a case with cerebral manifestations in the absence of anemia. *Ann Intern Med* 1948, **29**: 921-928.
2. Diggs, L.W. & Jones, R.S. Clinicopathologic conference. *Am J Clin Pathol* 1952, **22**: 1194-2000.
3. Ende, N., Pizzolato, P. & Ziskind, J. Sicklemia. *Ann Intern Med* 1955, **42**: 1065-1075.
4. Schenk, E.A. Sickle cell trait and superior longitudinal sinus thrombosis. *Ann Intern Med* 1964, **60**: 465-470.
5. Dalal, F.Y., Schmidt, G.B., Bennett, E.J. & Ramamurthy, S. Sickle cell trait. A report of postoperative neurological complication. *Br J Anaesthesiol* 1974, **46**: 387-388.
6. Handler, C.E. & Perkin, G.D. Sickle cell trait and multiple cerebral infarctions. *J R Soc Med* 1982, **75**: 550-553.
7. Greenberg, J. & Massey, E.W. Cerebral infarction in sickle cell trait. *Ann Neurol* 1985, **18**: 354-355.
8. Reyes, M.G. Subcortical cerebral infarctions in sickle cell trait. *J Neurol Neurosurg Psychiatry* 1989, **52**: 516-518.
9. Radhakrishnan, K., Ashok, P.P., Sridharan, R. & Mousa, M.E. Stroke in the young: incidence and pattern in Benghazi, Libya. *Acta Neurol Scand* 1986, **73**: 434-438.
10. Chopra, J.S. & Prabhakar, S. Clinical features and risk factors in stroke in young. *Acta Neurol Scand* 1979, **60**: 289-300.
11. Sears, D.A. The morbidity of sickle cell trait. A review of literature. *Am J Med* 1978, **64**: 1021-1036.
12. Hindmarsh, P.C., Brozovic, M., Brook, C.G.D. & Davies, S.C. Incidence of overt and covert neurological damage in children with sickle cell disease. *Postgrad Med J* 1987, **63**: 751-753.
13. Baird, R.L., Weiss, D.L., Ferguson, A.D. *et al.* Studies in sickle anemia. XXI Clinicopathological aspects of neurological manifestations. *Pediatrics* 1964, **34**: 92-100.
14. Stockman, J.A., Nigro, M.A., Mishkin, M.M. & Oski, F.A. Occlusion of large cerebral vessels in sickle-cell anemia. *N Engl J Med* 1972, **287**: 846-849.
15. Nagpal, K.C., Asdourian, G.K., Patrianakos, D. *et al.* Proliferative retinopathy in sickle cell trait. Report of seven cases. *Arch Intern Med* 1977, **137**: 325-328.
16. Konotey-Ahulu, F.I.D. Anaesthetic deaths and the sickle cell trait. *Lancet* 1969, **i**: 267-268.
17. Alvarez, J., Matias-Guiu, J., Sumalla, J. *et al.* Ischaemic stroke in young adults. I. Analysis of the etiological subgroups. *Acta Neurol Scand* 1989, **80**: 28-34.
18. Lehman, H. Distribution of the sickle cell gene. A new light on the origin of the East African. *Eugenics Rev* 1954, **46**: 3-23.
19. Kamel, K. & Awny, A.Y. Origin of the sickling gene. *Nature* 1965, **205**: 919-920.