

Abdominal mass in a 19-year-old with neurofibromatosis

Isaac Samuel, Shriram Jakate, Michael M Ramsey, Theodore J Saclarides

A 19-year-old white man with known von Recklinghausen's neurofibromatosis developed anorexia and abdominal pain associated with a mobile lower abdominal mass. Characteristic café-au-lait spots and subcutaneous neurofibromas were present. Other features associated with von Recklinghausen's disease¹⁻⁴ included mental retardation, a history of headaches and seizures, and scoliosis. Magnetic resonance imaging (MRI) showed a tubular mass 3 × 7 × 8 cm in the lower abdomen (figure 1). A diagnostic laparoscopy was performed (figure 2).

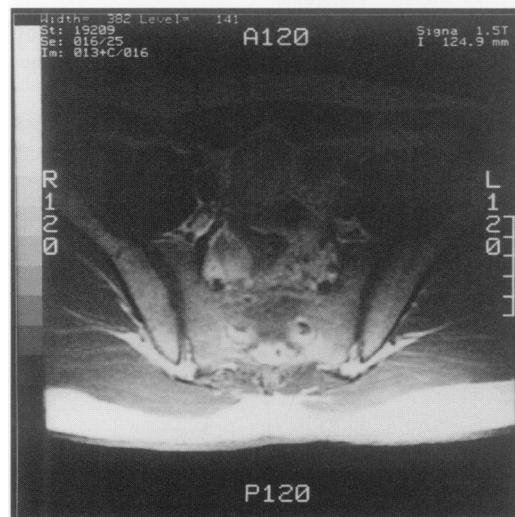
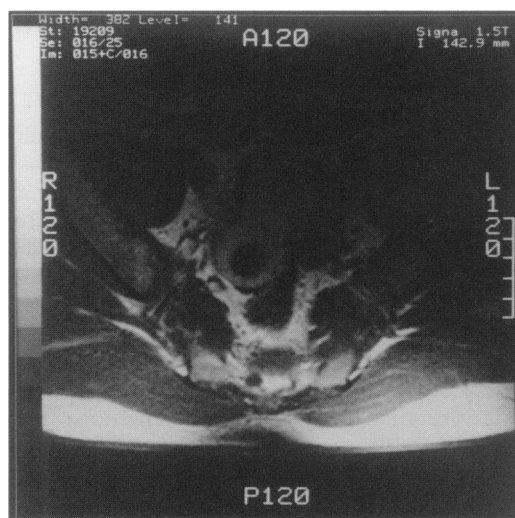


Figure 1 MRI scan of abdomen

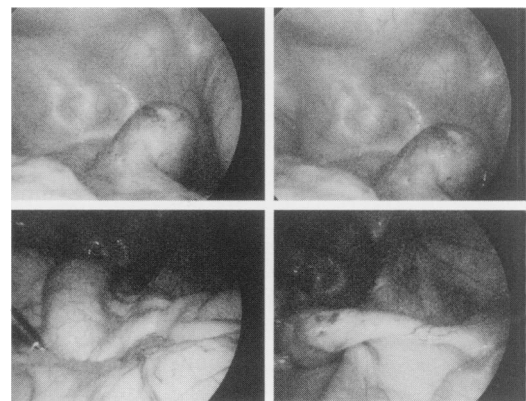


Figure 2 Laparoscopy

Rush-Presbyterian-
St Luke's Medical
Center and Rush
Medical College,
1653 West Congress
Parkway, Chicago,
IL 60612, USA
Department of
General Surgery
I Samuel
TJ Saclarides
Department of
Pathology
S Jakate
Department of
Internal Medicine
MM Ramsey

Correspondence to
Dr Theodore Saclarides

Accepted 10 May 1996

Questions

- 1 What is the most likely cause of the abdominal mass?
- 2 What is the risk of malignant transformation associated with neurofibromatosis?

Answers

QUESTION 1

Neurofibroma of the appendix. This was confirmed by an open appendectomy.

QUESTION 2

The risk of sarcomatous change in neurofibromas is about 15%.³

Gastrointestinal involvement in neurofibromatosis

Neurofibromas in patients who do not have von Recklinghausen's disease, although often multiple, are not associated with café-au-lait spots.¹ Approximately 25% of patients with von Recklinghausen's neurofibromatosis have or develop gastrointestinal neurofibromatosis, while only about 15% of those with neurofibromas arising in the gastrointestinal tract are associated with von Recklinghausen's disease.²⁻⁴ Gastrointestinal neurofibromas most often occur in the small intestine, followed by the stomach, while involvement of the colon and appendix is infrequent.^{3,4} Presenting features of gastrointestinal neurofibromatosis have included symptoms such as abdominal pain, haematemesis, haematochezia and melena, or complications such as gastrointestinal obstruction, perforation, intussusception, and volvulus formation.^{3,4}

Discussion

Von Recklinghausen's neurofibromatosis is an autosomal dominant disorder with variable penetration, characterised by multiple neurofibromas and café-au-lait spots.¹ To the best of our knowledge, only eight cases of appendiceal neurofibromatosis have previously been reported in the literature; of these, six were associated with von Recklinghausen's neurofibromatosis, and two were examples of solitary appendiceal neurofibroma not associated with von Recklinghausen's disease.² In previous reports, appendiceal neurofibromatosis has

Neurofibromatosis

Essential features:

- multiple neurofibromatosis
- café-au-lait spots, six or more, measuring at least 1.5 cm

Associated features:

- headache
- seizures
- mental retardation
- Lisch nodules (pigmented iris hamartomas)
- macrocephaly
- central nervous system tumours
- pseudarthrosis
- kyphoscoliosis
- short stature
- sarcomatous malignant transformation
- medullary carcinoma of the thyroid
- pheochromocytoma
- hypertension
- constipation
- pruritus

presented as a palpable mass or with acute appendicitis, or has remained asymptomatic.² Although abdominal pain was a feature in the present report, histopathologic examination of the appendix failed to reveal acute appendicitis. The initial laparoscopic approach was converted to an open appendectomy since, if this were a malignant mucocele, possible spillage induced by the laparoscopic instrument could be avoided. Although appendiceal involvement is rare, it should be considered in the differential diagnosis of lower abdominal pain in patients with multiple neurofibromatosis.

Final diagnosis

Appendiceal neurofibromatosis in von Recklinghausen's disease.

Keywords: appendix, neurofibromatosis, von Recklinghausen's disease

1 Riccardi VM, Von Recklinghausen neurofibromatosis. *N Engl J Med* 1981; 305: 1617-27.

2 Olsen BS. Giant appendicular neurofibroma. A light and immunohistochemical study. *Histopathology* 1987; 11: 851-5.

3 Davis GB, Berk RN. Intestinal neurofibromas in von Recklinghausen's disease. *Am J Gastroenterol* 1973; 60: 410-4.

4 Hochberg FH, Dasilva AB, Galdabini J, Richardson EP. Gastrointestinal involvement in von Recklinghausen's neurofibromatosis. *Neurology* 1974; 24: 1144-51.