

Tumour seeding following percutaneous endoscopic gastrostomy placement in head and neck cancer

Douglas Thorburn, Sabeeha N Karim, David S Soutar, Peter R Mills

Summary

We report the case of a patient with advanced squamous carcinoma of the supraglottic larynx and hypopharynx who developed metastatic gastric deposits occurring at the site of a percutaneous endoscopic gastrostomy tube, inserted 10 months previously by the pull technique. We review seven previous reports of tumour deposits occurring at the site of placement of a percutaneous endoscopic gastrostomy in patients with head and neck cancer, and consider alternative methods of enteral feeding in such patients.

Keywords: percutaneous endoscopic gastrostomy, head and neck cancer, metastases, tumour implantation

A 56-year-old Caucasian man presented in April 1994 with a 20-month history of a slowly growing left-sided neck lump. He had no systemic symptoms at the time of presentation. He had a long history of alcohol abuse, including alcohol-related seizures, and heavy tobacco use. On examination there was a 6 × 6 cm firm fixed non-tender mass in the left submandibular region. Fine needle aspirate of this mass was in keeping with a poorly differentiated metastatic large cell carcinoma. Direct laryngoscopy revealed a grossly abnormal supraglottic region and epiglottis with biopsies confirming an extensive poorly differentiated squamous cell carcinoma, with obvious keratin pearls (figure 1) staged as T4 N3. Radical surgery was the preferred treatment option but at operation left radical neck dissection was incomplete as the tumour had spread out with the deep cervical nodes, invaded the internal jugular vein and extended across the base of the skull. In view of this extensive nodal involvement, pharyngolaryngectomy was abandoned and a tracheostomy was performed. Postoperatively, in June 1994, a Ponsky percutaneous endoscopic gastrostomy (PEG) tube (Bard interventional products, CR Bard Inc, USA) was inserted using the pull method as described by Gauderer and colleagues.¹ He then received radical radiotherapy to the primary tumour site and neck to a total dose of 6600 cGy.

Following discharge in August 1994 he was followed up every two months as an outpatient. In December 1994 he developed a left

lower motor neuron facial nerve palsy; CT scanning at that time showed no evidence of recurrent disease at the base of the brain.

In April 1995 his general condition had deteriorated such that he was re-admitted for nursing care and to improve his analgesia. His haemoglobin on admission was 6.8 g/dl and he was transfused four units of packed cells. At that time blood was first noted to be leaking through the PEG tube lumen. He developed intermittent obstruction to PEG tube feeding and occasional small haematemesis. A barium contrast study was performed through the PEG tube and this showed no abnormality within the stomach and duodenum. An oesophago-gastroduodenoscopy in May 1995 revealed a 5-

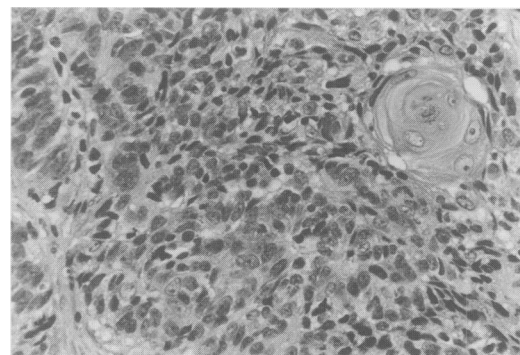


Figure 1 Histology of the supraglottic tumour. This is a poorly differentiated carcinoma with no glandular differentiation but with foci of squamous differentiation

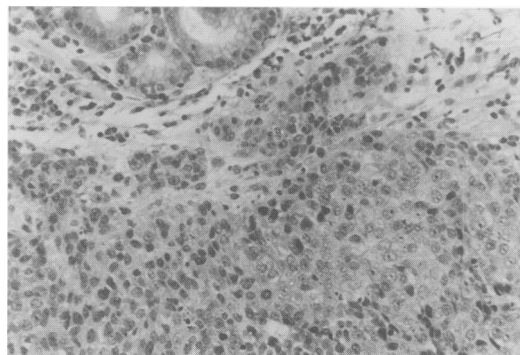


Figure 2 Histology of the gastric tumour at the site of the PEG tube. This is a poorly differentiated squamous carcinoma infiltrating the gastric mucosa. The cells are arranged in solid sheets and there is no glandular differentiation

Western Infirmary,
Glasgow G11 6NT,
UK
Gastroenterology
Unit
D Thorburn
PR Mills
University Department
of Pathology
SN Karim

Plastic Surgery Unit,
Canniesburn
Hospital, Glasgow
G61 1QL, UK
DS Soutar

Correspondence to Dr
Peter R Mills, Consultant
Gastroenterologist, Floor
8, Gartnavel General
Hospital, Glasgow G12
0YN, UK

Accepted 21 August 1996

Table Summary of published cases of tumour implantation at gastrostomy sites in patients with head and neck cancer. All PEGs were inserted using the pull method

Reference	Age (years)/ Sex	Site of primary	Stage of tumour	Histology	Time to implantation (months)	Other metastases	Length of survival (months)
5	72/male	pharyngeal	T4 N2 M0	squamous	post-mortem	pulmonary	6
6	68/male	supraglottic laryngeal	T4 N3b M0	squamous	15	pulmonary	18
7	53/male	posterior pharyngeal	T4 N2a M0	squamous	6	not reported	not reported
8	45/male	supraglottic larynx	T4 N2 M0	squamous	12	pulmonary	28
	76/female	oropharynx	T4 N0 M0	squamous	16	pulmonary, mediastinal	19
9	65/male	hypopharynx	Tx N0 M0	squamous	11	hepatic	15
10	43/male	hypopharynx	T4 N2 M0	squamous	4	not reported	not reported
11	41/male	glossal	T4 N2b M0	squamous	13	no evidence	29
present	56/male	supraglottic larynx	T4 N3 M0	squamous	11	no evidence	15

Learning points

- patients with head and neck cancers undergoing treatment benefit from enteral nutritional support
- PEG placement by the pull technique prior to treatment is the commonest means of nutritional support in these patients
- PEG placement by the pull technique in these patients can be associated with the development of gastric malignant metastatic deposits at the site of tube placement
- when curative resection is planned for patients with head and neck cancers, a pre-operative PEG may be better inserted percutaneously or using radiological methods.

cm ulcerated tumour adjacent to the PEG tube site with a small amount of blood clot on the ulcer base. Biopsies of this tumour showed a poorly differentiated carcinoma with no evidence of glandular differentiation (figure 2). Mucin stains were negative. The appearance of the gastric tumour was the same as much of the original tumour. His haemoglobin continued to fall slowly and he required further blood transfusion. Gastrostomy feeding was abandoned in view of persistent tube obstruction. His general condition continued to deteriorate and he died at the end of June 1995. *Post-mortem* examination was declined by his relatives.

Discussion

Patients with head and neck cancer commonly present in a catabolic state secondary to odynophagia or oropharyngeal obstruction. As the gastrointestinal tract remains functional, enteral feeding is the favoured route of nutritional support. Percutaneous endoscopic gastrostomy has superseded nasogastric tube placement and surgical gastrostomy as the commonest method of providing long-term nutritional support. Nasogastric tube feeding is associated with gastro-oesophageal reflux and aspiration, nasal ulceration and deformity, and frequent tube blockage, and is poorly tolerated for cosmetic reasons. Surgical gastrostomy has the disadvantage of requiring an operation and most studies have shown it to be associated

with an increased incidence of complications compared to PEG placement. PEG tubes are usually placed by the pull method where the tube is pulled through the oropharynx into position in the stomach by an endoscopically placed guide-wire which runs from the mouth to the stomach and through the anterior abdominal wall.^{1,2} Russell *et al* have described a less frequently used technique where the PEG tube is inserted percutaneously under endoscopic control.³ Insertion is not without risk; complications are usually minor but the procedure-related mortality rate is around 3%.

Pre-operative insertion of a PEG feeding tube is a means of improving nutrition and reducing the hospital stay of patients with advanced head and neck carcinoma.⁴ There are now nine cases (including our patient) reported with gastric tumour seeding occurring at the site of a PEG tube placed by the pull method in patients with advanced carcinoma of the head and neck (table).⁵⁻¹¹ In the report by Bushnell *et al*, the PEG tube was inserted six weeks after local disease had been macroscopically cleared by surgery.⁶ In all the other reports there was extensive oropharyngeal disease at the time of PEG insertion. The median time until presentation with malignant gastric deposits at the PEG site was 12 months after insertion (range 4-16 months). When peristomal deposits were reported, metastatic disease was found elsewhere below the clavicles in five patients (four pulmonary, one hepatic).^{5,6,8,9} In the remaining patients no comment was made about tumour spread. Problems reported secondary to the PEG metastases were pain, ulceration, and peristomal drainage of gastric contents. This case is the only one where gastrointestinal haemorrhage and recurrent anaemia were noted.

Gastric metastases are rare in patients with head and neck cancer with one large autopsy study of 832 cases reporting a prevalence of 1.3%.² The prevalence of peristomal metastases in patients with gastrostomy tubes is not known as they may not be obvious clinically even when present. In PEG patients the mechanism of metastatic spread is thought to be either implantation, when the PEG tube is pulled past the oropharyngeal tumour at the time of insertion, or by haematogenous spread. Tumour implantation is the favoured explana-

tion as the gastric tumour is always reported at the site of the gastrostomy and on each occasion the PEG tube has been inserted by the pull method. Against this is the report of gastric malignant deposits in one patient who had no evidence of local disease when the PEG tube was inserted.⁶ In addition, there is a single case report of a patient with locally advanced squamous carcinoma of the tongue developing metastases at the site of a surgically placed gastrostomy.¹³ It is possible that local trauma to the gastric mucosa at the time of gastrostomy siting predisposes to seeding of malignant cells which are already within the circulation.

In patients with head and neck squamous carcinoma, enteral feeding, usually by PEG, is planned for most patients with advanced local disease. The current recommendation is that gastrostomy is performed prior to resection of the primary tumour.⁴ As illustrated, this may well be associated with a slight increase in the risk of tumour implantation into the stomach, particularly if the gastrostomy tube is inserted

by the pull method where the feeding tube is drawn past the oropharyngeal tumour. Theoretically, the risk of implantation with the Russell percutaneous technique is less, as the PEG tube is placed directly through the anterior abdominal wall into the stomach under endoscopic guidance, without coming into contact with the tumour mass.³ We feel that, when pre-operative gastrostomy is planned for patients being considered for curative surgery for head and neck cancer, the gastrostomy might preferably be inserted by the percutaneous route. This may be either under endoscopic control as described by Russell *et al*³ or using radiological methods.¹⁴ At least clinicians looking after patients with head and neck cancers should be aware of this potential complication when placing PEG tubes by the commonly used pull method.

The authors are grateful to Professor DG MacDonald, Glasgow Dental School, for access to the laryngeal histology.

- 1 Cauderer ML, Ponsky JL, Izant RJ Jr. Gastrostomy without laparotomy: a percutaneous endoscopic technique. *J Paediatr Surg* 1980; 15: 872-5.
- 2 Hussain A, Woolfrey S, Massey J, Geddes A, Cox J. Percutaneous endoscopic gastrostomy. *Postgrad Med J* 1996; 72: 581-5.
- 3 Russell TR, Brotman M, Norris F. Percutaneous gastrostomy: a new simple cost-effective technique. *Am J Surg* 1984; 148: 132-7.
- 4 Gibson, S, Wenig BL. Percutaneous endoscopic gastrostomy in the management of head and neck carcinoma. *Laryngoscope* 1992; 102: 977-80.
- 5 Preyer S, Thul P. Gastric metastasis of squamous cell carcinoma of the head and neck after percutaneous endoscopic gastrostomy - report of a case. *Endoscopy* 1989; 21: 295.
- 6 Bushnell L, White TW, Hunter JG. Metastatic implantation of laryngeal carcinoma at a PEG exit site. *Gastrointest Endosc* 1991; 37: 480-2.
- 7 Huang DT, Thomas G, Wilson WR. Stomal seeding by percutaneous endoscopic gastrostomy in patients with head and neck cancer. *Arch Otolaryngol Head Neck Surg* 1992; 118: 658-9.
- 8 Meurer MF, Kenady DE. Metastatic head and neck carcinoma in a percutaneous gastrostomy site. *Head Neck* 1993; 15: 70-3.
- 9 Laccourreye O, Chabardes E, Merite-Drancy A, *et al*. Implantation metastasis following percutaneous endoscopic gastrostomy. *J Laryngol Otol* 1993; 107: 946-9.
- 10 Schiano TD, Pfister D, Harrison L, Shike M. Neoplastic seeding as a complication of percutaneous endoscopic gastrostomy. *Am J Gastroenterol* 1994; 89: 131-3.
- 11 Lee DS, Mohit-Tabatabai MA, Rush BF, Levine C. Stomal seeding of head and neck cancer by percutaneous endoscopic gastrostomy tube placement. *Ann Surg Oncol* 1995; 2: 170-3.
- 12 Kotwall C, Sako K, Razack MS, *et al*. Metastatic patterns in squamous cell cancer of the head and neck. *Am J Surg* 1987; 154: 439-42.
- 13 Alagaratnam TT, Ong GB. Wound implantation - a surgical hazard. *Br J Surg* 1977; 64: 872-5.
- 14 Rosenzweig TB, Palenstrand AM, Esplin CA, Gilsdorf RB. A method of radiologic-assisted gastrostomy when percutaneous endoscopic gastrostomy is contraindicated. *Am J Surg* 1994; 168: 587-91.