

Thoracic Vertebral Actinomycosis: *Actinomyces israelii* and *Fusobacterium nucleatum*[∇]

Hitoshi Honda,¹ Matthew J. Bankowski,^{2*} Eric H. N. Kajioka,³ Nalurporn Chokrungrvaranon,⁴ Wesley Kim,² and Scott T. Gallacher⁴

Division of Infectious Diseases, Washington University School of Medicine, St. Louis, Missouri¹; Diagnostic Laboratory Services, Inc., and John A. Burns School of Medicine, University of Hawaii, Honolulu, Hawaii²; Division of Infectious Diseases, University of Colorado, Denver, Colorado³; and Department of Internal Medicine, University of Hawaii Internal Medicine Residency Program, Honolulu, Hawaii⁴

Received 27 August 2007/Returned for modification 26 September 2007/Accepted 28 February 2008

***Actinomyces* spp. are considered rare pathogens in today's medicine, especially with thoracic vertebral involvement. Classic actinomycosis (50%) presents as an oral-cervicofacial ("lumpy jaw") infection. This report describes a case of spinal cord compression caused by *Actinomyces israelii* with the coisolation of *Fusobacterium nucleatum*. There are limited numbers of similar cases.**

CASE REPORT

The case described here involves a 43-year-old Filipino man who presented to a medical center emergency department with a chief complaint of acute lower back pain and urinary incontinence. He had been in his usual state of health until approximately 3 days prior to admission, when he first noticed a gradual onset of bilateral lower-extremity weakness, followed by difficulty with walking and, finally, the inability to arise from bed. In addition, the patient stated that he had been experiencing low-grade fevers and progressive weight loss over the past several months. His medical history was unremarkable and did not include any recent trauma. The patient had emigrated from the Philippines to Hawaii about 20 years earlier. However, he denied any history of exposure to tuberculosis or any recent travel back to the Philippines or Southeast Asia.

In the emergency room, the patient appeared to be disoriented, although he was able to follow simple commands. His vital signs included a temperature of 97.8°F, blood pressure of 121/75 mm Hg, a heart rate of 116 beats/min, and mild tachypnea, with an O₂ saturation of 99% on room air. On physical examination, he was noted to have poor dentition and evidence of multiple previous dental extractions. A neurological examination revealed significant bilateral lower-extremity weakness (two of five) with brisk deep-tendon reflexes, positive ankle clonus, and a positive Babinski sign, as well as diminished rectal tone. The remainder of the physical examination was unremarkable. Laboratory blood findings were significant for leukocytosis (22.0 × 10⁹/liter) with 87% segmented neutrophils, an elevated platelet count of 722 × 10⁶/liter, and an erythrocyte sedimentation rate of 84 mm/h. A screen for human immunodeficiency virus type 1 and 2 antibodies was negative. The remaining laboratory findings were noncontributory.

A chest X ray showed a left-lower-lobe infiltrate with minimal pleural effusion.

Because of the possibility of spinal cord compression and injury, the patient was admitted to the medical intensive care unit for further workup and management. This included magnetic resonance imaging of the spine, which showed an abnormal signal intensity involving the thoracic vertebrae from T5 through T8 and an abnormal soft tissue mass enhancement consistent with an apparent abscess that involved the left posterior chest wall and ribs and that extended to the thoracic vertebral column and into the epidural space, with apparent spinal cord compression. A computed tomography scan of the chest revealed similar abnormal findings involving the left posterior chest wall and ribs as well as a collapsed left lower lobe with minimal pleural effusion. A bone scan also showed increased activity within the thoracic vertebrae and left ribs but with no mention of bony erosion. The patient was started empirically on intravenous (i.v.) antibiotics, consisting of ceftriaxone at 2 g every 24 h and vancomycin at 1 g every 12 h, as well as dexamethasone. This was followed immediately by an emergent thoracic laminectomy and debridement of the epidural abscess. Very thick fibrinous material was present overlying the dura, and several pockets of gross purulence were seen from T5 to the superior aspect of T9. There was a well-organized abscess running over the entire extent of exposure and tapering at the rostral and caudal ends. Abscess fluid samples for aerobic and anaerobic culture were obtained intraoperatively, placed in a BBL Port-A-Cul envelope (221607; BD), and transported to the Microbiology Laboratory. The wound was then irrigated with a copious volume of antibiotic-containing saline and closed. The culture was positive for both *Actinomyces* spp. and *Fusobacterium* spp. Blood and urine cultures showed no growth. Stains for acid-fast bacilli and mycobacterial cultures were also negative.

The patient's antibiotic regimen was changed to i.v. penicillin G at 2 × 10⁶ units every 4 h and clindamycin at 600 mg every 6 h. Postoperatively, the surgical wound healed well without the expression of purulence. The patient's bilateral lower-extremity motor strength improved markedly during his remaining hospital course. However, residual bowel and urinary dysfunction still per-

* Corresponding author. Mailing address: Department of Clinical Microbiology, Diagnostic Laboratory Services, Inc., 650 Iwilei Road, Suite 300, Honolulu, HI 96817. Phone: (808) 589-5242. Fax: (808) 589-5215. E-mail: mbankowski@dlslab.com.

[∇] Published ahead of print on 12 March 2008.

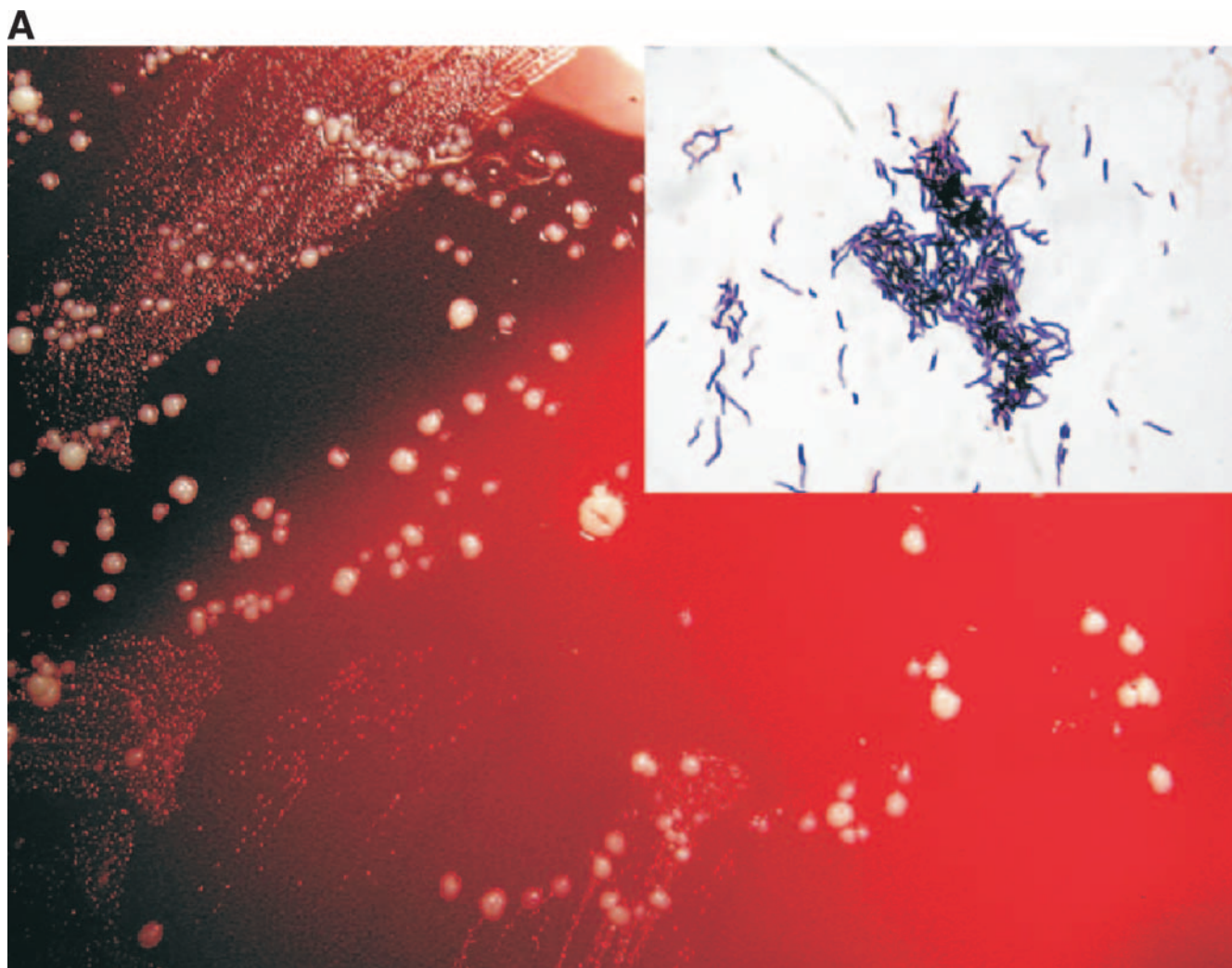


FIG. 1. (A) *Actinomyces israelii* “molar tooth” appearance on sheep blood agar and microscopic morphology showing branching gram-positive bacilli; (B) *Fusobacterium nucleatum* (larger colony) and *A. israelii* (smaller colony) colony morphology on sheep blood agar and microscopic morphology showing fusiform gram-negative bacillus for *F. nucleatum*.

sisted. He was subsequently transferred to a rehabilitation center for 6 weeks of i.v. antibiotic therapy consisting of penicillin G and clindamycin. This was followed by 12 months of oral amoxicillin at 500 mg three times a day.

MATERIALS AND METHODS

Culture isolation and microscopy. A Gram stain was used to identify the microscopic morphology of the isolates. Culture was performed with brucella agar as the primary anaerobic medium. The Rapid ANA II system (API) was used for the biochemical identification of the anaerobe.

PCR and sequencing. The identity of the isolate was confirmed by 16S rRNA gene sequencing. A fragment of the 16S rRNA gene was amplified from DNA extracted from the bacterial isolate by PCR with *Pfu* DNA polymerase, a PCR mixture, and universal eukaryotic primers 27F and 1492R. The thermal cycling conditions consisted of denaturation at 94°C for 3 min, followed by 30 cycles at 94°C for 45 s, 55°C for 45 s, and 72°C for 90 s. A final extension was carried out at 72°C for 7 min, followed by cooling to 4°C. The PCR product was then purified with a Qiagen PCR purification kit and sequenced with the following primers: 27F (AGAGTTTGATCMTGGCTCAG), 530R (GTA TTA CCG CGG CTG CTG), 981R (GGG TTG CGC TCG TTG CGG G), and 1492R (TACGGYT ACCTTGTTACGACTT). DNA sequencing was performed with a BigDye Terminator cycle sequencing kit (version 3.1), and the sequence was resolved on an

ABI 3730XL DNA analyzer (Applied BioSystems, Foster City, CA). The full 16S rRNA gene sequences were then assembled by use of the Seqman program (DNASTar). Sequence analysis was performed with the ChromasPro program (version 1.33; Technelysium Pty. Ltd.) and a search with the BLAST program (www.ncbi.nlm.nih.gov/BLAST/BLAST.cgi).

RESULTS

Anaerobic culture of the epidural abscess resulted in the isolation of both *Actinomyces israelii* (Fig. 1A) and *Fusobacterium nucleatum* (Fig. 1B). *Fusobacterium* spp. are non-spore forming and nonmotile. The classic microscopic description for *Fusobacterium* spp. is a gram negative, spindle-shaped bacillus, as revealed by this isolate and shown in Fig. 1B (10). The identification of *Fusobacterium nucleatum* was confirmed with the Rapid ANA II system (API). Both bacteria are commonly found as a part of the normal flora in the human oral cavity. However, it should be noted that once disruption of the mucosa occurs, they can contribute to the development of a systemic anaerobic infection.

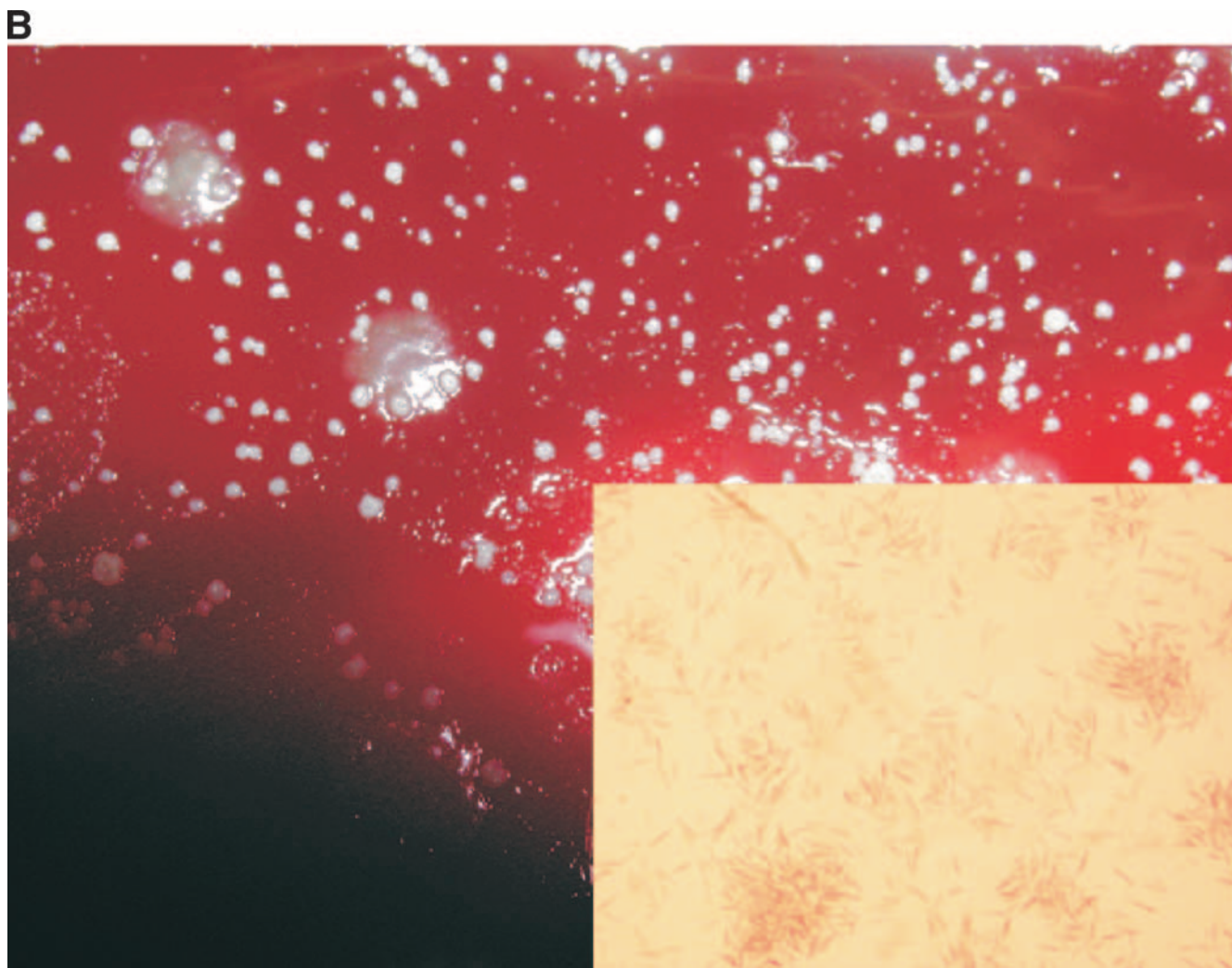


FIG. 1—Continued.

Actinomyces spp. are gram-positive branching bacilli, which often present with a beaded appearance on Gram stain (10). They are characteristically identified as nonmotile, non-spore-forming, non-acid-fast, and facultative anaerobes. These features were present in the isolate from the case described here. Culture isolates can be presumptively identified from both their microscopic and macroscopic appearances, as outlined in the algorithm in Fig. 2. This algorithm was constructed by one of us (M.J.B.) from characteristics described in authoritative microbiology reference textbooks (10, 18). However, definitive identification relies upon complex phenotypic testing (i.e., carbohydrate fermentation, enzyme profiles, or gas chromatography) or 16S rRNA sequencing. This isolate was identified from the primary anaerobic culture (brucella agar) by both phenotypic and genotypic approaches. The isolate only grew anaerobically and exhibited the typical “molar tooth” appearance, as demonstrated on a sheep blood agar plate (Fig. 1A).

The isolate was identified as *A. israelii* with a base identity homologous to the sequence of *A. israelii* strain A1 (GenBank accession no. AF479270.1) at 889/891 nucleotides (99.8%).

DISCUSSION

Classic actinomycosis is well documented as an oral-cervicofacial (i.e., termed appropriately as “lumpy jaw”) lesion, which occurs in approximately 55% of actinomycosis cases (2). Infection occurs at other sites and is manifest as thoracic (15%), abdominal and pelvic (20%), musculoskeletal (rare), and central nervous system (rare) disease. However, actinomycosis with the involvement of thoracic vertebral bone has rarely been described (15).

Disruption of the mucosal membrane is essential for the formation of actinomycosis. Once *Actinomyces* invades the tissue of a disrupted mucus membrane, it slowly expands and develops into an abscess. Classic actinomycosis usually occurs following trauma, dental procedures, or other such surgical procedures at sites where these bacteria may reside as part of the normal flora.

Several risk factors for the development of actinomycosis exist. It occurs more commonly in males, but there is no clear explanation for this. Other risk factors may include poor oral

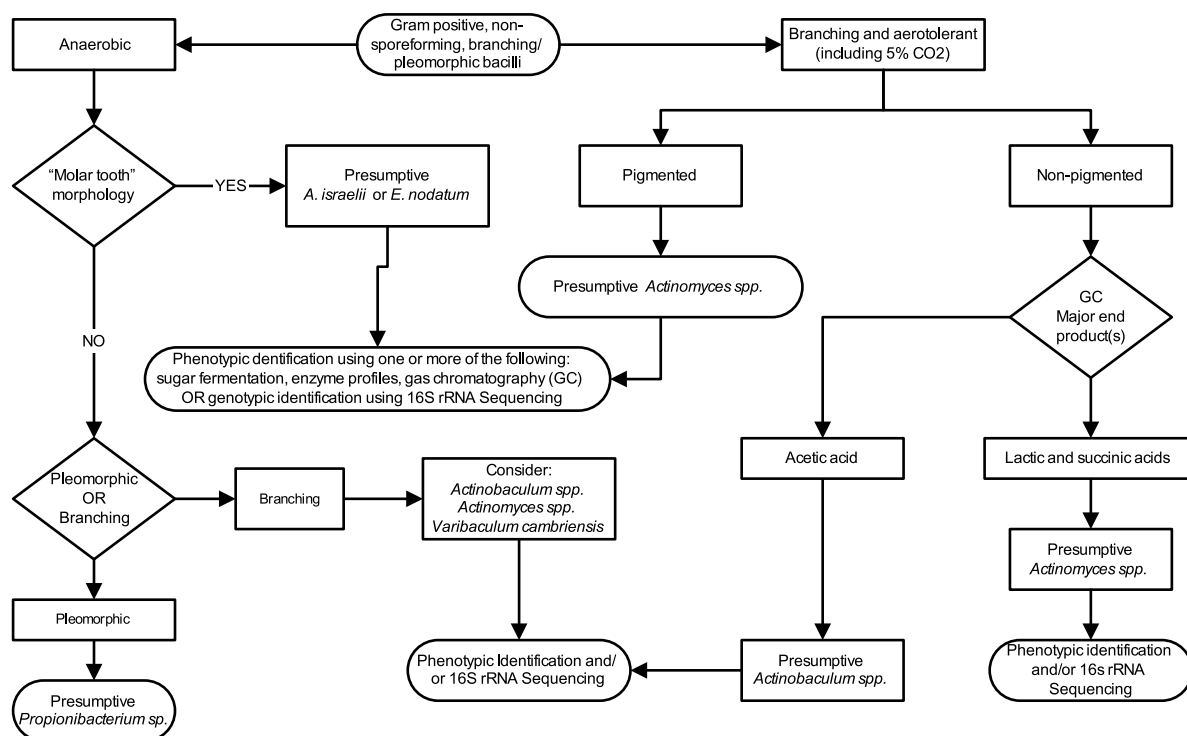


FIG. 2. Algorithm for the identification of gram-positive, non-spore-forming, branching/pleomorphic bacilli.

hygiene and the use of intrauterine devices. In addition, immunocompromise and other conditions, such as diabetes, alcoholism, infections with immunosuppressive agents (e.g., human immunodeficiency virus), and steroid use, are thought to predispose individuals to the development of actinomycosis (1, 4, 8, 20, 22).

The diagnosis of actinomycosis requires a high degree of clinical suspicion, since *Actinomyces* spp. are insidious organisms and infections with these organisms may show only non-specific clinical manifestations (e.g., low-grade fever or other constitutional symptoms) (22, 24). Even in a patient with thoracic vertebral actinomycosis, the clinical appearance does not differ remarkably from that resulting from other diseases causing spinal cord compression, such as malignancy or an epidural abscess (6, 22, 24).

Actinomyces was originally discovered in 1877 as a genus containing the causative agent of actinomycosis in cattle. Thereafter, in 1891, *A. israelii* was first isolated from a lung abscess by Wolff and Israel (1, 22). Since then, other *Actinomyces* spp. and related bacteria have been isolated and are believed to be involved in a wide variety of human infections. Oral infections have classically been linked to *A. israelii*. However, a number of other species have also been involved in human infections. These include *Actinomyces meyeri*, *Actinomyces graevenitzii*, *Actinomyces turicensis*, *Actinomyces gerencseriae*, *Actinomyces odontolyticus*, *Actinomyces cardiffensis*, *Actinomyces radingae*, *Actinomyces naeslundii*, other *Actinomyces* spp., and a closely related species, *Varibaculum cambriensis* (18, 22).

Members of the genus *Actinomyces* are frequently isolated with other bacteria, including *Fusobacterium* spp., *Bacteroides*

spp., *Capnocytophaga* spp., *Eikenella* spp., *Staphylococcus* spp., *Streptococcus* spp., and *Enterococcus* spp. (1, 22). Although the relationship between the coisolation of these organisms and their role in the pathogenesis of actinomycosis still remains unclear, the concomitant presence of other organisms may play an important role in reducing oxygen tension, making it more conducive for the growth of anaerobes. The coexistence of those organisms may be related to both a common source and their facilitation of the growth and development of *Actinomyces* (11).

The vertebral involvement of actinomycosis is usually secondary to an infection of contiguous tissue rather than hematogenous spread. (6). Likewise, it is unlikely to be the result of vertebral osteomyelitis and epidural abscesses due to common bacterial pathogens.

A search of the literature from 1950 to 2007 revealed a total of only 14 other cases of thoracic vertebral actinomycosis. The present case is the 15th. These cases are listed in Table 1 (3, 6, 7, 9, 12, 13, 17, 19, 23, 24, 25, 26, 27). In summary, they show that 9/15 (60%) were caused by *A. israelii*, the average age of the patients was 42.2 years, 12/14 (85.7%) cases occurred in males, and at least 8/12 (66.7%) cases were associated with thoracic involvement or other pulmonary symptoms. In addition, another organism(s) was coisolated in 7/15 (46.7%) cases. Epidemiological data in these cases were consistent with those of other nonthoracic cases, even where the details were not well documented.

Actinomycosis is sometimes difficult to differentiate from mycobacterial disease (caused by both *Mycobacterium tuberculosis* and non-*M. tuberculosis*) and diseases caused by *Nocardia asteroides* due to the similarities in the clinical manifestations

TABLE 1. Cases of actinomycosis with thoracic vertebral involvement

Age (yr) and gender ^a	<i>Actinomyces</i> species	Yr	Other bacterium species cultured	Risk factor or diagnosis	Country	Duration of antimicrobial therapy
43/M	<i>A. israelii</i>	Current case	<i>Fusobacterium nucleatum</i>	Rib osteomyelitis	United States	6 wk of i.v. penicillin G with i.v. clindamycin, 12 mo amoxicillin
51/M	<i>A. israelii</i>	2006	None	Pneumonia	Israel	8 wk of i.v. penicillin G, 12 mo of amoxicillin
50/F	<i>A. israelii</i>	2006	<i>Bacteroides melaninogenicus</i>	None	India	12 wk of oral ofloxacin with rifampin
38/M	<i>A. israelii</i>	2006	<i>Fusobacterium</i> spp.	Alcohol abuse, cerebral involvement	Denmark	8 wk of i.v. metronidazole with i.v. penicillin G, 12 mo of amoxicillin
32/M	<i>A. israelii</i>	2000	None	Mediastinal involvement	China	6 wk of i.v. penicillin G, 6 mo of oral penicillin V
34/F	<i>Actinomyces</i> spp.	1998	<i>Actinobacillus actinomycetem-comitans</i>	None	France	12 wk of oral ofloxacin with rifampin
33/M	<i>Actinomyces</i> spp.	1998	None	None	Japan	3 wk of piperacillin, 5 wk of oral erythromycin
46/M	<i>Actinomyces</i> spp.	1990	None	Pneumonia, alcohol abuse	United States	6 wk of i.v. penicillin G, 12 mo of oral penicillin G
56/M	<i>A. israelii</i>	1989	None	9 mo cough	United Kingdom	5 wk of i.v. clindamycin, 3 wk of oral clindamycin
40/M	<i>A. meyeri</i>	1989	None	Lung involvement	Denmark	6 wk of penicillin G, 12 mo of oral penicillin V
31/M	<i>A. israelii</i>	1981	<i>Propionibacterium acnes</i> , <i>Enterococcus</i> spp.	Cough	United States	Penicillin G (duration not stated), 6 wk of oral penicillin V
45/M	<i>A. israelii</i>	1979	<i>Actinobacillus actinomycetem-comitans</i>	Dental work	United States	Penicillin G and oral ampicillin (duration not stated)
52/M	<i>A. israelii</i>	1979	<i>Actinobacillus actinomycetem-comitans</i>	Lung involvement	United States	8 wk of i.v. penicillin G, 12 mo oral penicillin V
42/M	<i>Actinomyces bovis</i>	1960	None	Cough, rib osteomyelitis	United Kingdom	3 wk of i.v. penicillin G
42/NS ^b	<i>Actinomyces</i> spp.	1951	None	Lung involvement	United Kingdom	NS ^b

^a M, male; F, female.

^b NS, not indicated.

and bacterial morphologies (6, 21, 22, 24). Identification of the organism is critical, since the choice of antimicrobial agent(s) differs for the treatment of infections caused by each bacterial pathogen and may affect both patient morbidity and patient mortality. In addition, *Actinomyces* spp. are slowly growing and anaerobic; thus, optimal specimen collection requires an anaerobic culture and extended growth (possibly 14 to 21 days). A proposed scheme for the identification of *Actinomyces* spp. is described in Fig. 2.

The treatment of actinomycosis includes antimicrobial therapy with or without surgery. Penicillin is the antibiotic of choice, although other antimicrobial agents, such as clindamycin, tetracycline, and erythromycin, can be used in cases of penicillin allergy (14, 16). The optimal duration of antimicrobial therapy should be tailored depending on the severity of illness. However, a longer duration of treatment with antimicrobial agents is usually necessary, since the premature termination of antimicrobial therapy may cause a relapse of actino-

mycosis (5). Conventional therapy dictates treatment with an i.v. antimicrobial agent for 6 to 8 weeks, followed by treatment with an oral antimicrobial agent for 6 to 12 months. Among the cases listed in Table 1, 7/15 (46.7%) received antibiotic treatment for 6 months or more.

The patient presented in this case study was diagnosed with thoracic vertebral actinomycosis due to *A. israelii*. It is not known how much *Fusobacterium nucleatum* contributed to the infection or the role of this anaerobe in the pathogenesis of actinomycosis. However, as suggested by others, it may be reasonable to consider *F. nucleatum* as a potential copathogen when treatment is considered (15). The most likely disease progression was probably from an extension of a primary lung infection (itself caused by the aspiration of oral flora), followed by destruction of the ribs, the development of empyema, and subsequent paraspinal abscess formation. The main risk factors in the patient's history were a history of alcoholism and poor dentition.

Conclusion. *Actinomyces* spp. are often found as part of the normal flora of the oral cavity and the gastrointestinal and vaginal tracks. Actinomycosis can develop at virtually any site. Due to the slow development of infection, attention to risk factors during certain procedures (e.g., dental examination) and a careful physical examination are especially important in order to detect and treat the patient in the early stage of actinomycosis. Since the hallmark of infection is the formation of an abscess, surgical treatment may also be necessary, regardless of the site of infection, in order to prevent the spread of the disease.

Emphasis should be placed on having a high degree of clinical suspicion and the use of appropriate techniques to obtain a specimen adequate to achieve a successful diagnosis of actinomycosis. The patient's symptoms in this case improved with surgical decompression and antimicrobial therapy. However, the patient did not fully recover from urinary and bowel impairment, despite appropriate treatment. Since actinomycosis with thoracic vertebral column involvement is rarely encountered and reported, actinomycosis should be considered in patients with spinal cord compression with risk factors, regardless of their clinical manifestation(s).

ACKNOWLEDGMENTS

We thank Terrie Koyamatsu (microbiology manager), Claire Ying (microbiology supervisor), and the clinical microbiology staff at Diagnostic Laboratory Services, Inc., and The Queen's and Kuakini Health Systems for their technical expertise, manuscript review, and comments on this case study. We also thank Shaobin Hou, University of Hawaii at Manoa, for his expertise and performing the sequencing for this study.

REFERENCES

1. **Apotheloz, C., and C. Regamey.** 1996. Disseminated infection due to *Actinomyces meyeri*: case report and review. *Clin. Infect. Dis.* **22**:621–625.
2. **Bennhoff, D. F.** 1984. Actinomycosis: diagnostic and therapeutic considerations and a review of 32 cases. *Laryngoscope* **94**:1198–1217.
3. **Birley, H. D., E. L. Teare, and J. A. Utting.** 1989. Actinomycotic osteomyelitis of the thoracic spine in a penicillin-sensitive patient. *J. Infect.* **19**:193–194.
4. **Cendan, I., A. Klapholz, and W. Talavera.** 1993. Pulmonary actinomycosis. A cause of endobronchial disease in a patient with AIDS. *Chest* **103**:1886–1887.
5. **Chao, D., and A. Nanda.** 2002. Spinal epidural abscess: a diagnostic challenge. *Am. Fam. Physician* **65**:1341–1346.
6. **Cope, V. Z.** 1951. Actinomycosis of bone with special reference to infection of vertebral column. *J. Bone Joint Surg. Br.* **33B**:205–214.
7. **Fenichel, I., and I. Caspi.** 2006. The use of external fixation for the treatment of spine infection with *Actinomyces bacillus*. *J. Spinal Disord. Tech.* **19**:61–64.
8. **Gaffney, R. J., and M. A. Walsh.** 1993. Cervicofacial actinomycosis: an unusual cause of submandibular swelling. *J. Laryngol. Otol.* **107**:1169–1170.
9. **Gaini, S., B. T. Roge, C. Pedersen, S. S. Pedersen, and A. S. Brenoe.** 2006. Severe *Actinomyces israelii* infection involving the entire spinal cord. *Scand. J. Infect. Dis.* **38**:211–213.
10. **Holt, J. G., N. R. Krieg, P. H. A. Sneath, J. T. Staley, and S. T. Williams.** 2000. Group 20. Irregular nonsporing gram positive rods, p. 571–572. *In* Bergey's manual of determinative bacteriology, 9th ed. Lippincott Williams & Wilkins, Philadelphia, PA.
11. **Jordan, H. V., D. M. Kelly, and J. D. Heeley.** 1984. Enhancement of experimental actinomycosis in mice by *Eikenella corrodens*. *Infect. Immun.* **46**:367–371.
12. **Kannagara, D. W., T. Tanaka, and H. Thadepalli.** 1981. Spinal epidural abscess due to *Actinomyces israelii*. *Neurology* **31**:202–204.
13. **Lane, T., S. Goings, D. W. Fraser, K. Ries, J. Pettrozzi, and E. Abrutyn.** 1979. Disseminated actinomycosis with spinal cord compression: report of two cases. *Neurology* **29**:890–893.
14. **Lerner, P. I.** 1974. Susceptibility of pathogenic actinomycetes to antimicrobial compounds. *Antimicrob. Agents Chemother.* **5**:302–309.
15. **Mandell, G. L., R. G. Douglas, J. E. Bennett, and R. Dolin.** 2005. Mandell, Douglas, and Bennett's principles and practice of infectious diseases, 6th ed. Elsevier, Philadelphia, PA.
16. **Martin, M. V.** 1985. Antibiotic treatment of cervicofacial actinomycosis for patients allergic to penicillin: a clinical and in vitro study. *Br. J. Oral. Maxillofac. Surg.* **23**:428–434.
17. **Muller, P. G.** 1989. Actinomycosis as a cause of spinal cord compression: a case report and review. *Paraplegia* **27**:390–393.
18. **Murray, P. R., E. J. Baron J. H. Jorgensen, M. L. Landry, and M. A. Pfaller (ed.).** 2007. Manual of clinical microbiology, 9th ed. ASM Press, Washington, DC.
19. **Nolan, R. L., J. D. Ross, and S. W. Chapman.** 1990. Thoracic actinomycosis presenting as spinal cord compression. *J. Miss. State Med. Assoc.* **31**:41–45.
20. **Ossorio, M. A., C. L. Fields, R. P. Byrd, Jr., and T. M. Roy.** 1997. Thoracic actinomycosis and human immunodeficiency virus infection. *South. Med. J.* **90**:1136–1138.
21. **Smego, R. A., Jr.** 1987. Actinomycosis of the central nervous system. *Rev. Infect. Dis.* **9**:855–865.
22. **Smego, R. A., Jr., and G. Foglia.** 1998. Actinomycosis. *Clin. Infect. Dis.* **26**:1255–1261.
23. **Ushikoshi, S., I. Koyanagi, K. Hida, Y. Iwasaki, and H. Abe.** 1998. Spinal intrathecal actinomycosis: a case report. *Surg. Neurol.* **50**:221–225.
24. **Varshney, M. K., V. Trikha, and S. A. Khan.** 2006. Actinomycosis or tuberculosis? A diagnostic dilemma. *Scand. J. Infect. Dis.* **38**:378–381.
25. **Voisin, L., O. Vittecoq, O. Mejjad, C. Krzanowska, T. Defives, C. Cambon-Michot, and X. Le Loet.** 1998. Spinal abscess and spondylitis due to actinomycosis. *Spine* **23**:487–490.
26. **Young, W. B.** 1960. Actinomycosis with involvement of the vertebral column: case report and review of the literature. *Clin. Radiol.* **11**:175–182.
27. **Yung, B. C., J. C. Cheng, T. T. Chan, T. K. Loke, J. Lo, and P. Y. Lau.** 2000. Aggressive thoracic actinomycosis complicated by vertebral osteomyelitis and epidural abscess leading to spinal cord compression. *Spine* **25**:745–748.