

## CASE REPORT

# Exact moment of tendon of pectoralis major muscle rupture captured on video

Alberto Castro Pochini, Benno Ejnisman, Carlos Vicente Andreoli, Gustavo Cara Monteiro, Anna Maria Fleury, Flavio Faloppa, Moises Cohen, Walter Manna Albertoni

*Br J Sports Med* 2007;41:618–619. doi: 10.1136/bjism.2006.033563

A powerlifting athlete ruptured his left tendon of the pectoralis major muscle while attempting to lift 160 kg in a Brazilian bench press championship. The injury seemed to occur in the concentric phase of exercise; however, the more common mechanism of rupture is during the eccentric phase. The tendon was reinserted to the humerus 3 weeks later with screws and washers. The athlete returned to competitive activities after 5 months. One year later he lifted 170 kg and won the national championship.

### CASE HISTORY

A powerlifting 30-year-old athlete in an international bench press championship at his third attempt had total rupture of the pectoralis major tendon when lifting 160 kg (see supplemental video, available online at <http://bjism.bmj.com/supplemental>). Even after injury the athlete won the championship with the other two preview attempts. The injury was caught on film by cameras from the left side. The tendon rupture occurred at the concentric phase after the bar had touched the chest of athlete. The competition stopped and the left shoulder was swelling, but he did not report pain at the moment of injury. Magnetic resonance imaging (MRI) showed a desinsertion lesion of the pectoralis major muscle (PMM). The athlete was treated surgically with reinsertion of the tendon (fig 1A) to the humerus with screw and washer (fig 1B). An isokinetic test in dynamometer, Cybex, model 6000 (Division of Lumex, Inc, Ronkonkoma, NY, USA) showed horizontal adduction deficit:  $-10$  grades/s. After 6 months he returned to the championships and 1 year later won the national bench press championship, lifting 170 kg. He had been using anabolic steroids for years. Now after 4 years' follow-up the athlete is still in powerlifting championships.

### DISCUSSION

Until the end of the 1970s, only 45 cases of total injury of the PMM had been reported.<sup>1</sup> After a review by McEntire *et al*,<sup>2</sup> an additional 11 cases were reported, totalling 56 cases described.

In the past 20 years, there has been an increase in the incidence of upper limb muscle injuries, especially in sports requiring strong physical activity, such as weight lifting, and with the concurrent use of anabolic steroids.<sup>3</sup> Today, nearly 200 cases have been reported.<sup>4</sup>

Anatomically, according to Wolfe *et al*<sup>5</sup> the PMM has a triangular like shape, originating at the medial clavicle, sternum anterior surface, costal cartilage (1st to 6th) and aponeurosis of the oblique external muscle of abdomen, laterally converging through three muscle portions (clavicle, sternum and costal-abdominal). The PMM is a medial rotator and an important adductor of the shoulder.<sup>5–7</sup>

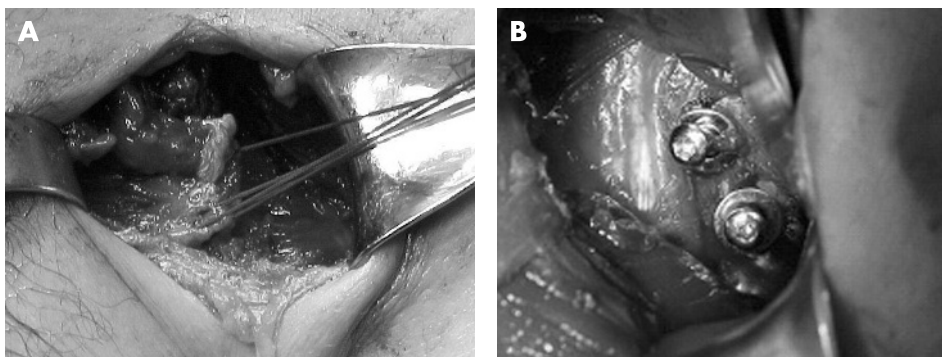
Indirect injury is the most common mechanism of PMM rupture in athletes. Most incidences occur in weightlifting athletes during bench press exercises. Direct injury of the PMM occurs in contact sports, such as rugby and football.

Clinically, the athlete may present with pain, ecchymosis and oedema at the anterior region of the shoulder and thorax, with functional restraining of adduction and medial rotation.

Schepsis *et al*<sup>8</sup> found that 47% of injuries occurred during the bench press movement. The most common mechanism of injury for PMM rupture is overload with sudden maximal contraction, with the shoulder extended and opposing to strength in an anteroposterior direction. Wolfe *et al*<sup>5</sup> described the moment in which the pectoralis muscle ruptured by simulating the supine movement in cadavers. With an injury on the lower portion of the muscle, the upper remaining fibres would be overloaded and could subsequently disrupt, leading to total PMM injury.<sup>7</sup>

Aarimaa *et al*<sup>4</sup> reported, in studies with rats, that the chronic use of anabolic steroids reduces the tendon's resistance to tension. The athlete presented here may have had tendinopathy of the PMM in association with chronic use of anabolic steroids.

The reported history and physical tests virtually confirm the diagnosis. Pain, ecchymosis, and palpable defect on the anterior axillary region is a common finding.<sup>8</sup> The patient may also complain about a volume increase of the chest region and report pain and weakness to forced adduction.<sup>8</sup>



**Figure 1** (A) Intraoperative image of the ruptured tendon of the pectoralis major muscle. (B) Washer and screws used for reinsertion of the tendon.

### What is already known on this topic

Most ruptures of the tendon of pectoralis major occur in the eccentric phase of the movement.

### What this study adds

The rupture of tendons of pectoralis major may happen in concentric movement in bench press exercises.

In chronic cases of PMM rupture, the marked medial retraction resulting from PMM contraction is evident. The patient presented did not report pain at the moment of injury, but a feeling of medial muscle retraction before the interruption of the bench press exercise.

Magnetic resonance imaging enables a better definition of the injured structure.<sup>2,9</sup> Lee *et al* showed some essential concepts of PMM rupture by using magnetic resonance assessment.<sup>6</sup>

Partial lesions, at the muscular portion (medial) are treated conservatively<sup>8</sup> by analgesic treatment, rest and immobilisation with slings for 3 weeks and active movement after 10 days.

Schepesis *et al* reported that in all cases of PMM desinsertion, the sternocostal portion was affected, but the tendinous clavicular portion was also often involved.<sup>8</sup>

Zeman *et al*<sup>3</sup> reported nine cases of total injury of the PMM, with excellent outcomes in surgically treated cases, and in the five cases conservatively treated, residual weakness was present.

Schepesis *et al*,<sup>8</sup> Wolfe *et al*<sup>5</sup> and Kretzler and Richardson<sup>1</sup> did not find any significant difference in surgical treatment of acute and chronic cases. Aarimaa *et al* found outcomes with surgical treatment were better in patients using anabolic steroids.<sup>4</sup>

Although we disagree that the isokinetic evaluation criterion is crucial for determining whether surgery should be carried out, we believe that it is an important factor in improving the evaluation of adduction strength. Other authors such as Kretzler *et al*,<sup>1</sup> Wolfe *et al*,<sup>5</sup> Miller *et al*,<sup>9</sup> Schepesis *et al*<sup>8</sup> and Aarimaa *et al*<sup>4</sup> have also used the isokinetic dynamometry for assessment of patients.



Supplementary video available online at <http://bjsm.bmj.com/supplemental>

### Authors' affiliations

Alberto Castro Pochini, Benno Ejnisman, Carlos Vicente Andreoli, Gustavo Cara Monteiro, Anna Maria Fleury, Flavio Faloppa, Moises Cohen, Walter Manna Albertoni, Federal University of Sao Paulo, Brazil

Conflict of interest: None declared.

Informed consent was obtained for publication.

Correspondence to: Dr A C Pochini, Federal University of Sao Paulo, Brazil; apochini@uol.com.br

Accepted 7 February 2007

Published Online First 17 April 2007

### REFERENCES

- 1 Kretzler HH Jr, Richardson AB. Rupture of the pectoralis major muscle. *Am J Sports Med* 1989;**17**:453–8.
- 2 McEntire JE, Hess WE, Coleman SS. Rupture of the pectoralis major muscle. A report of eleven injuries and review of fifty-six. *J Bone Joint Surg Am* 1972;**54**:1040–6.
- 3 Zeman SC, Rosenfeld RT, Lipscomb PR. Tears of the pectoralis major muscle. *Am J Sports Med* 1979;**7**:343–7.
- 4 Aarimaa V, Rantanen J, Heikkila J, *et al*. Rupture of the pectoralis major muscle. *Am J Sports Med* 2004;**32**:1256–62.
- 5 Wolfe SW, Wickiewicz TL, Cavanaugh JT. Ruptures of the pectoralis major muscle. An anatomic and clinical analysis. *Am J Sports Med* 1992;**20**:587–93.
- 6 Lee J, Brookenthal KR, Ramsey ML, *et al*. MR imaging assessment of the pectoralis major myotendinous unit: an MR imaging-anatomic correlative study with surgical correlation. *AJR Am J Roentgenol* 2000;**174**:1371–5.
- 7 Marmor L, Bechtol CO, Hall CB. Pectoralis major muscle function of external portion and mechanism of rupture of normal muscle: case reports. *J Bone Joint Surg Am* 1961;**43**:81–7.
- 8 Schepesis AA, Grafe MW, Jones HP, *et al*. Rupture of the pectoralis major muscle. Outcome after repair of acute and chronic injuries. *Am J Sports Med* 2000;**28**:9–15.
- 9 Miller MD, Johnson DL, Fu FH, *et al*. Rupture of the pectoralis major muscle in a collegiate football player. Use of magnetic resonance imaging in early diagnosis. *Am J Sports Med* 1993;**21**:475–7.

### COMMENTARY

It is rare to capture on video the exact moment of an injury; it is remarkable that this article reports just this! It seems that, although most such injuries are said to occur during an eccentric contraction, in this patient the injury apparently occurred at the transition between isometric and concentric muscle action. Food for thought!

Nicola Maffulli

Keele University School of Medicine, Hartshill, UK;  
osa14@keele.ac.uk