

CURRENT SURVEY

## Nephropathy and viroses

HOBART A. REIMANN  
M.D.

*Department of Medicine, The Hahnemann Medical College and Hospital,  
Philadelphia, Pennsylvania 19102, U.S.A*

### Summary

The kidneys often are involved during viral diseases, but seem to be peculiarly resistant to injury in contrast to other organs and tissues. They rarely bear the brunt of infection. Clinical evidence of viral nephritis or nephrosis seldom is of serious import and when it occurs it may be indistinguishable from that of other cause unless specific diagnostic criteria are fulfilled. With increasing interest in the subject, as happens in other circumstances, more evidence of acute or chronic viral injury to the kidneys no doubt will accrue.

### *Viral infections associated with renal disturbance*

Cytomegaloviral	Rubella
Varicella	Influenza
Mumps	Rabies
Measles	Herpes zoster and hominis
ECHO	Yellow fever
Coxsackie	Hemorrhagic fevers
Poliomyelitis	Hepatitis
Adenoviral	Infectious mononucleosis
Variola	Lymphocytic choriomeningitis
Vaccinia	Aleutian mink disease

### Introduction

Filtrable agents were regarded for decades as monotropic causes of dermal, mucosal, neural, hepatic and glandular disease. Interest in recent years included viral infections of the lungs,<sup>1</sup> intestine,<sup>2</sup> myocardium,<sup>3</sup> endocardium<sup>4</sup> and synovialis.<sup>5</sup> The organs and tissues mentioned often bear the brunt of infection, but viruses in general are polytropic. Renal involvement has given less concern for several reasons. It is incidental to systemic or localized viral infections, usually is mild or inapparent and seldom is of clinical importance. For example, in contrast to viral arthritis with overt inflammation, viral nephritis without clinical pathognostic evidence is detectable only by biopsy or necropsy study with cultural or serologic proof. Acute lesions if present, resemble those of other origin, and albuminuria occurs during 'febrile nephrosis' common to any febrile disease. Yet invasion of

the kidney may be expected because human and animal renal cells are especially suited to the culture of viruses in the laboratory, viremia and viruria occur during viral diseases and viruses together with acute lesions appear in the kidneys. It is important to know if viral infections of the kidney ever lead to chronic nephropathy or predispose the kidney to secondary bacterial invasion.

Historically, Henoch<sup>6</sup> described varicellar nephritis in 1884. The first observation of cellular inclusions indicative of viral renal infection was made by Ribbert also in 1884, but not published until 1904.<sup>7</sup> Others then saw similar forms in the kidney, later in renal tubules and in areas of focal interstitial nephritis.<sup>8</sup> Councilman described the renal lesions of yellow fever in 1890.<sup>9</sup> Mumps with nephritis was recognized in 1905.<sup>10</sup> Between then and 1925, Weigert, Fahr and others found renal lesions during variola, varicella and measles. Viruria during rabies was noted in 1927<sup>11</sup> and the word first appeared in a dictionary in 1965.<sup>12</sup> After the development of virologic diagnostic methods, percutaneous renal biopsy and knowledge of autoimmunity, interest in the matter increased.<sup>13</sup>

### Viruria

According to Utz's review in 1964, viruses appeared in urine during rabies, lymphocytic choriomeningitis, mumps, vaccinia, measles, rubella, Russian spring-summer disease, Newcastle disease, coxsackie-viral, cytomegalo-viral ECHO and adeno-viral infections. Hardly any of the published reports gave evidence of functional disturbance, nor of viruses or lesions in the kidneys during viruria. Depending upon the virus, viremia and viruria occurred in the prodromal period, during the illness, and occasionally viruria persisted during convalescence or indefinitely.<sup>14</sup> Mumps, coxsackie and ECHO viruses derived from human urine when inoculated into mice seemed to grow in their kidneys suggesting the same to occur during viral disease in man.<sup>15</sup>

### Viruses in the kidney

Influenza virus was present in the kidney of a patient who died from influenza, in one who in addition had chronic renal disease<sup>16</sup> and in the urine of others.<sup>17</sup> Cytomegalo-, adeno-, coxsackie-, measles and varicella viruses grew in cultures of renal cells obtained at necropsy from infants with malformations and other disease.<sup>18</sup> Immunofluorescent technique visualized measles virus antigen in the kidney.<sup>19</sup> An unidentified virus resided in the kidneys of infants in the absence of lesions.<sup>20</sup> Viral renal infection without inflammation was noted in a monkey infected with papova virus.<sup>21</sup> Some viruses reside commensally in simian kidneys<sup>22</sup> and others probably live in human ones.

Thus far, viruses have been recovered from the kidneys chiefly of infants, during severe viral infections at any age, from kidneys previously damaged, but also from healthy children.<sup>23</sup> It is uncertain in most instances if the viruses invaded the kidneys to cause overt or inapparent infection, resided there commensally, or like other filtrable blood-borne substances were trapped in the kidney or traversed the tissue harmlessly for excretion in the urine. Inclusion-bearing cells in the urine<sup>24</sup> and in the kidney as described by numerous observers suggest the presence of a virus, but are unspecific.

### Cytomegaloviral disease

Cytomegalovirus, a commensal, becomes invasive when host-resistance is impaired. During systemic infection, the kidneys usually are affected, especially abnormal or previously injured ones. Viruria continued in some patients for more than 4 years without evidence of renal dysfunction.<sup>25</sup> In infants who died, there were focal accumulations of monocytic cells and inclusion-bodies in the epithelial cells of the tubules, some of which were necrotic. Small hemorrhagic areas and interstitial infiltration of lymphocytes appeared about the involved tubules.<sup>26</sup> Renal failure during disseminated disease has not been recorded. Viruria continued for months in seven of eight healthy children and the complement-fixation test gave a positive result for the infection. Infection probably was latent in the salivary glands or elsewhere and virus either escaped harmlessly in the urine, or inapparent urinary tract infection persisted.<sup>23</sup>

### Varicella

Varicellar glomerulonephritis, first observed 84 years ago, was mentioned as a feature incidental to other involvement by a number of observers between 1929 and 1962.<sup>27-33</sup> Evidence of neph-

ritis was noted in 0.1% of victims of varicella.<sup>34</sup> In several fatal cases, the histologic changes resembled those of poststreptococcal glomerulonephritis. Focal epithelial degeneration was present in the renal pelvis and at the angles of calices. Swollen cells contained intranuclear inclusions. Cells of the collecting tubules were degenerated but the glomeruli were normal. Focal necrosis, submucosal hemorrhages with mild leukocytic infiltration and intranuclear inclusions were in the lining cells of the ureters, and epithelial cells of the bladder had intracytoplasmic inclusions.<sup>29</sup> In another fatal case, vesicular lesions speckled the renal surface and firm red nodules were in the cortex and medulla. Endothelial cells, fibroblasts and cells in the glomerular tufts and convoluted tubules contained inclusions.<sup>32</sup>

Acute glomerulonephritis regarded as a complication of varicella affected a child and two adults, one of whom died. Each had proteinuria and microscopic or gross hematuria before or during the exanthem. Azotemia, oliguria and edema were noted in the adults but the blood pressure was undisturbed. Renal biopsy disclosed hypercellular glomerular capillaries, swollen endothelial cells, and occasional obliteration of the space in Bowman's capsule similar to that in Fig. 1. The changes resembled those of poststreptococcal glomerulonephritis.<sup>35, 36</sup>

Discoid pocks and areas of epithelial and mesothelial necrosis seen on the bladder wall at necropsy probably were varicellar lesions.<sup>37</sup> Lesions in the bladder were visible cystoscopically during varicella in two children with hematuria.<sup>38, 39</sup>

### Mumps

Evidence of mumps nephritis was rare or inconclusive according to the descriptions of twelve cases published between 1905 and 1961 referred to by Hughes.<sup>40</sup> Other cause was not always excluded. Two children whose urine contained albumin, erythrocytes and casts died from renal failure. Interstitial fibrosis, remnants of glomeruli, patchy scars in the parenchyma but well-preserved tubules were present in one who died from uremia. The other had nephrosis with many hypercellular tufts, thickened capsular epithelium, fragmentation of some tubular cells, but little evidence of acute inflammation.<sup>40</sup> The observers felt that the virus rather than a hypersensitive reaction to it injured the kidneys directly. Acute nephritis and transient hypertension occurred in a 15-year-old girl.<sup>41</sup> Transient mild renal dysfunction occurred during viruria in twenty adults with mumps.<sup>42</sup> In general, while viruria is

common, clinical evidence of mumps nephritis is rare.

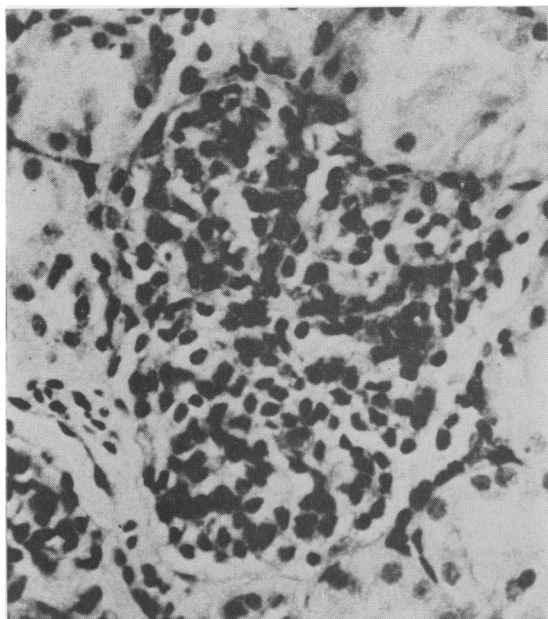


FIG. 1. ECHO 9 virus infection. Hypercellular glomerulus; almost complete obliteration of space of Bowman's capsule. (Courtesy of Dr A. M. Yuceoglu.)

### Measles (Rubeola)

Measles viruria soon after the exanthem and characteristic giant cells in the mucosa of the bladder suggested specific invasion of the urinary tract.<sup>43</sup> Inclusion-bearing cells appeared in greatest number and in best developed form in the urine during the prodromal and eruptive stages. They also appeared after live virus anti-measles vaccination. Their specificity is in doubt because similar bodies occur during other infections and occasionally during health.<sup>44, 45</sup> The affected cells may have been exfoliated locally or extruded from the blood. By electron microscopy, according to Bolande, the bodies were homogeneous, unlike the crystalline particles of the virus and they contained no measles antigen. Histologically, focal hyperplasia and cellular degeneration appeared in the parietal epithelium of Bowman's capsule. Eosinophilic masses in some cells resembled the inclusion bodies in the urine.<sup>46</sup> In other studies, the diagnosis of measles was made by applying a direct immunofluorescent procedure which disclosed measles antigen in epithelial cells in urine.<sup>47</sup> Later, Lipsey and Bolande by immunofluorescent technique diagnosed measles post-mortem in three children who died during some other debilitating disease or from dissemin-

ated virosis. Measles virus antigen appeared in the cytoplasm of proximal and collecting tubule cells, in epithelial cells of Bowman's capsule, and in the mucosa of the renal pelvis, ureter and bladder. From those sites, fluorescent cells, inclusion-bearing and multi-nucleated cells probably were exfoliated into the urine.<sup>19</sup> Evidently, viral cellular infection occurred without obvious inflammatory changes. Paradoxically, measles occasionally causes prolonged remission of nephrosis of other origin in children and once was recommended as a form of therapy. Double nucleated cells were in the urine during roseola infantum.<sup>48</sup>

### Enteroviral infections

Hematuria and albuminuria often accompanied enteroviral infections.<sup>49</sup> Glomeruli contained fibrinoid deposits after type 9 ECHO virus disease.<sup>50</sup> Microscopic hematuria was observed in 50% of victims during an epidemic. Acute glomerulonephritis occurred in twins infected with ECHO 9 virus. Biopsy made several weeks after the onset of disease in both cases disclosed large hypercellular glomerular tufts almost obliterating the capsular spaces and occasionally adherent to the capsular walls (Fig. 1). Some tubules contained casts and blood, but there was no evidence of interstitial nephritis.<sup>51</sup>

Immunofluorescent coxsackie virus antigen was detected in cells in the urine of patients.<sup>52</sup> Types B3 and B4 antigen were demonstrated respectively as evidence of inapparent infection in the glomeruli and interstices in two patients, suggesting its possible causal relation to chronic glomerulonephritis.<sup>53</sup> Coxsackie virus B1 multiplied in the urinary tract of inoculated mice.<sup>54</sup> In other mice, the glomerular tufts were engorged with erythrocytes a week after inoculation with B4 virus. Between 5 and 8 weeks later, specific antigen and immunoglobulin appeared in the glomeruli, some of which were swollen and adherent to the capsule, probably as an auto-immune-like effect.<sup>55</sup>

Among eighteen children vaccinated orally with live type 1 poliomyelitis virus, viruria occurred in one, and in one of five control subjects. Leukocytes with cytoplasmic inclusions increased in number in the urine.<sup>56</sup>

### Adenoviral disease

Glomerulonephritis was listed as an occurrence during adenovirus type 7 pneumonia in five of twenty-seven children. Congestion of glomeruli, cytoplasmic vacuolization and karyolysis in epithelial cells of the tubules were thought to be related either to anoxia or to the toxic effects

of the virus.<sup>57</sup> Sohler described a similar instance.<sup>58</sup> In a fatal case of systemic adenovirus type 7 infection, viral particles visualized by electron microscopy grew in cell cultures of the normal-appearing kidney.<sup>59</sup> Hematuria accompanied adenovirus types 3 and 4 infection in two children, and recurred after attacks of influenza 2 months later.<sup>60</sup> During rubella or rubella-form disease, adenovirus types 4 and 7 were in the urine in eleven of thirty-two patients.<sup>61</sup> None of this evidence proves renal injury to be caused specifically by adenoviruses. They are common commensals, persist in the kidneys<sup>22</sup> and may be excreted passively in the urine.<sup>63</sup> Adenovirus type 11 caused acute hemorrhagic cystitis in children.<sup>63a</sup>

### Miscellaneous viral infections

Influenza was thought to be a cause of nephritis in 1920,<sup>64</sup> but at that time bacterial superinfections were common, and the viruses of influenza were unknown. Focal interstitial collections of mononuclear cells, dilated blood vessels and degeneration of the epithelial cells in the outer pyramidal zone were observed in *smallpox*<sup>65</sup> which also often is complicated by pyogenic cocci. Two instances of acute glomerulonephritis followed anti-smallpox vaccination.<sup>66,67</sup> Necropsy study of eighteen infants with congenital *rubella* disclosed focal, chronic, interstitial nephritis in four. Lymphocytes and histiocytes infiltrated the cortical interstitium. Rubella virus was present in six kidneys where it was found oftenest and in the absence of viremia.<sup>68</sup> Renal involvement accompanied generalized *herpes simplex virus*.<sup>69</sup> Focal degeneration of the kidneys was noted in *rabies*<sup>70</sup> and in simian herpetic viral disease.<sup>71</sup> A herpes-type virus was present constantly in naturally occurring winter renal tumours of frogs.<sup>72</sup> Hematuria accompanied unilateral lesions of *herpes zoster* in the bladder.<sup>73</sup>

Renal lesions of *yellow fever* as described in 1890 consisted of tubular degeneration, congestion, hemorrhage and necrosis of glomerular vessels and epithelial desquamation in Bowman's capsules. According to Elton, hemoglobinuric nephrosis, as a secondary lesion induced by bleeding or by hepatic injury, occasionally caused oliguria or ended in anuria and death<sup>74</sup> (Fig. 2). Other observers described dominant changes in the tubules and intranuclear inclusions in the epithelial cells, but no hemorrhage or inflammation.<sup>75</sup>

Probably for similar reasons, similar changes occur in the *hemorrhagic fevers* as 'nephrosonephritis'. Oliver regarded the lesions to be peculiar to the infection. Hemorrhage by diapedesis and from ruptured capillaries in the subcort-

ical medullary zone in places invaded the cortex. Necrosis was seen in portions of nephrons and tubules.<sup>76</sup> Others described swollen kidneys, proteinuria, oliguria and renal failure. A diuretic phase resulted from residual tubular injury.<sup>77</sup> What seemed to be a similar disease was described as *nephropathia epidemica* in Sweden.<sup>78</sup> In simian hemorrhagic fever, the renal lesions resembled those seen in secondary shock.<sup>78a</sup>

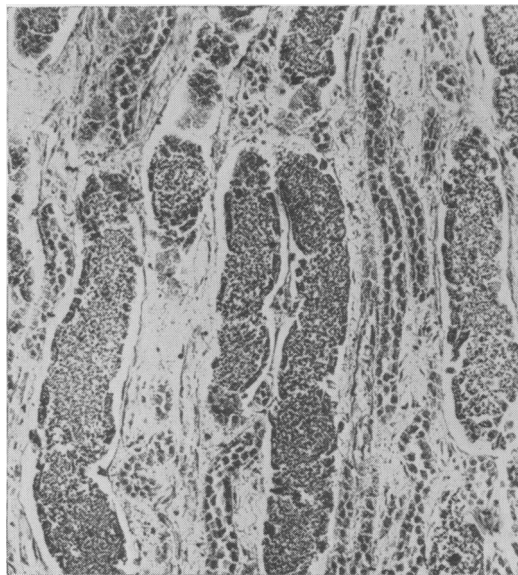


FIG. 2. Yellow fever. Tubules filled with erythrocytes and debris; degeneration and necrosis of lining cells. (Courtesy of Dr Norman W. Elton.)

Evidence of renal injury and dysfunction occurs in *infectious hepatitis*, but whether a virus, its toxic products or other factor is causal is unknown.<sup>79</sup> In other studies, non-inflammatory lesions discovered by biopsy involved the glomeruli and tubules. Interstitial edema, glomerular swelling, focal cellular invasion, epithelial hyperplasia and hypertrophy were present. Some thickened Bowman's capsules contained erythrocytes. The lesions disappeared after 3 months. Viremia and viruria were said to have been demonstrated by the inoculation of animals with material from patients,<sup>80,81</sup> but it is doubtful if transmission of human hepatitis to animals is possible.

Gross hematuria and albuminuria occurred in about 10% of patients with *infectious mononucleosis*, probably a viral disease. Renal tissue obtained by biopsy had granulomatous lesions, active and advanced destruction of some glomeruli with fibrosis and fibrotic scars. There was lymphocytic infiltration with fibrosis in and

around the medium-sized arterioles representing glomerulitis and arteriolitis (Fig. 3). Urinalysis 8 months after recovery gave normal results.<sup>82</sup> By means of indirect immunofluorescence on tissue obtained by biopsy, a specific heterophile-reactive antigen appeared in the glomeruli and tubules in twelve of thirteen cases. A mild diffuse inflammatory reaction suggested active infection, but renal function was undisturbed.<sup>83</sup> Electron microscopy disclosed focal deposits possibly of immune origin in glomeruli like those in lipoid nephrosis.<sup>83a</sup> Transient acute nephritis occurred in a youth with infectious mononucleosis-like disease. There were albumin, erythrocytes, leukocytes and casts in the urine, temporary hypertension and retention of urea nitrogen in the blood.<sup>84</sup>

In mice inoculated with *lymphocytic choriomeningitis* virus, direct immunofluorescent technique visualized the virus and its antibody deposited in the mesangia and capillary walls of the glomeruli and tubular cells (Fig. 4). Accumulation of virus in the kidney may cause delayed lesions.<sup>85</sup> Chronic infection in mice induced perivascular lymphocytic infiltration, degenerated tubular epithelium, thickened Bowman's capsules, enlarged glomeruli and eventually fibrosis and hyalinization.<sup>86</sup> Antithymocyte serum administered to neonatal mice delayed maturation of the lymphoid system which favored tolerance to lymphocytic choriomeningitis virus at a later age and ended in chronic immunopathic glomerulonephritis.<sup>87</sup>

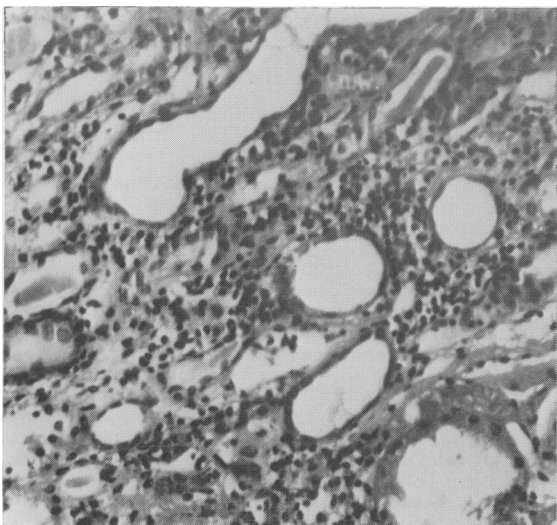


FIG. 3. Infectious mononucleosis. Mononuclear cell infiltration; interstitial edema, some dilated tubules with hyaline casts and atrophy of lining cells. (Courtesy of Dr J. H. Peters.)

Acute glomerulitis in the absence of hemolytic streptococcal infection affected a group of patients with acute pharyngitis. Renal biopsy disclosed mild focal glomerular injury. A virus was suspected as the cause.<sup>88</sup> An unidentified virus presumably caused viral nephritis in five other patients.<sup>89</sup>

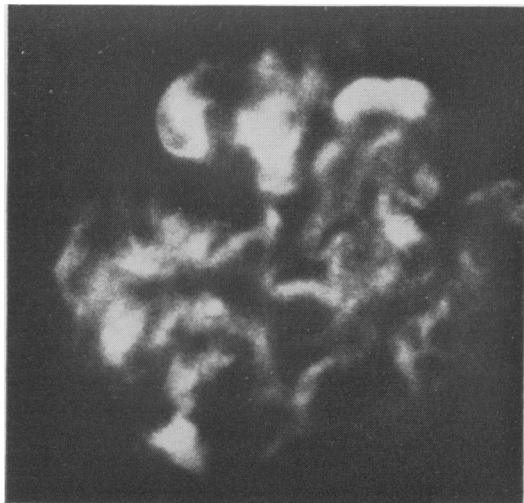


FIG. 4. Lymphocytic choriomeningitis in the mouse. Immunofluorescence of viral antigen-antibody complement complex trapped in a glomerulus. Elsewhere thickened and irregular basement membranes. Capillary loops hyalinized and obstructed. Perivascular cuffing with monocytes. (Courtesy of Dr M. B. A. Oldstone.)

Further interest pertains to the possible bearing of newly recognized 'slow' viruses on renal infection.<sup>90</sup> Cellular proliferation of glomeruli and thickened capillary basement membrane and thrombosis characterize the Aleutian disease of mink.<sup>91</sup>

#### Non-viral infections

Scanty information pertains to renal involvement in rickettsial diseases. Vasculitis of renal blood vessels most likely happens as part of the general endothelial involvement. Hypotension occasionally leads to oliguria and renal insufficiency. Evidence of acute diffuse glomerulonephritis was recorded in 78% of cases of *epidemic typhus*, in 50% of Rocky Mountain spotted fever and in 30% of patients with Tsutsugamushi disease.<sup>92</sup> *Rocky Mountain spotted fever* induced in monkeys gave rise within 12 hr to swelling and proliferation of endothelial cells, exudation and hemorrhage in the glomeruli. Proliferated epithelium of Bowman's membrane, hemolysis in the glomerular tufts and intertubular capillaritis with rickettsiae in the vessels were observed.<sup>93</sup>

Acute renal failure occurred in patients deficient in glucose-6-phosphate dehydrogenase during murine and scrub typhus, probably because of intravascular hemolysis and cast formation superimposed on renal vasculitis.<sup>93a</sup>

Most patients with *psittacosis* have albuminuria. At necropsy, ecchymoses were present in the renal pelvic mucosa. The glomeruli were congested, the proximal tubules dilated, the interstitial tissues edematous and lymphocytes infiltrated perivascularly in the pelvic tunica propria. The changes were those of acute segmental 'toxic' nephrosis.<sup>94</sup> Nephritis occurred in a patient with ornithosis.<sup>95</sup>

### Comment

Primary or solitary renal involvement as caused by *Streptococcus*, *Staphylococcus*, *M. tuberculosis* and *S. typhosa*<sup>96</sup> has not been recorded during viral infections. Renal disturbance occasionally is predominant clinically only in yellow fever and the hemorrhagic fevers. Renal lesions and dysfunction in most of the twenty viral diseases listed on page 853 usually are mild or inapparent. They occur incidentally as benign hemorrhagic nephritis, focal glomerulitis or mild nephrosis especially during severe systemic or localized viral diseases, and when the kidneys are abnormal from previous injury or defect. The epithelium of the tubules and of the lower urinary tract often is involved. In most instances, even after acute viral injury, the kidneys, like the liver, lungs or myocardium, recuperate fully.

At present, it is difficult if not impossible to tell whether nephropathy is caused directly by a virus, by a hypersensitive reaction to a virus, by its toxin, or by administered drugs, or to ascribe renal disturbance to the non-specific effects of fever or injured tissue elsewhere, or to anoxia, hypotension, shock or other cause. A virus may act as an endogenous antigenic stimulus to abnormal immunologic activity or by acting directly may modify either a tissue antigen or lymphoid cellular function to evoke an autoimmune response.<sup>97</sup> The uncertainty of viral renal infection either alone or as an integral part of a systemic viral disease is reflected by the phrases 'associated with', 'a complication of', but rarely 'caused by', as used by many authors. Nor is there much evidence that viral renal infection leads to chronic nephropathy. No viruses were isolated from the urine of twenty-four victims of chronic urinary tract infection,<sup>98</sup> but a causal virus or evidence of its activity may have long since disappeared. Nevertheless, if viral encephalitis occasionally leaves chronic neural lesions, if hepatitis in rare instances precedes cirrhosis, and viral myocarditis or endocarditis at times ends

in permanent cardiopathy, it is probable that viral renal infection occasionally leads to chronic nephropathy. That this ensues at times was suggested histologically in cases of varicella,<sup>32</sup> mumps,<sup>40</sup> rubella,<sup>68</sup> infectious mononucleosis,<sup>82</sup> coxsackie virosis,<sup>53</sup> in experimental lymphocytic choriomeningitis<sup>85, 87</sup> and in 'slow' viral diseases.<sup>90, 91</sup> It is probable also that viral renal infection occasionally predisposes to secondary bacterial invasion, as happens in the lung during viral respiratory tract infections. Pyelonephritis was induced by inoculating colon bacilli into mice having murine adenoviral disease. Extensive cellular infiltration and tubular injury ensued.<sup>99</sup> Known viruses or undiscovered ones may be causes of so called abacterial pyuria.

During many viroses, features suggesting specific renal involvement are: (a) viruria, (b) inclusion-bearing cells in urine or tissue, (c) virus in the kidney or immunofluorescent evidence of its presence, (d) impaired renal function, (e) clinical, and (f) pathologic evidence of nephritis or the nephrotic syndrome. All or almost all of these six factors are needed to prove causal relation of a virus to renal disease. This has not been accomplished according to published studies, but is anticipated in future ones. Even those features are inconclusive and must be considered respectively: (a) viruria may ensue harmlessly after filtrable agents are excreted during viremia or when viruses are commensal in the kidney, (b) cellular inclusions are nonspecific and similar bodies appear in urine during non-viral infections and of healthy persons, (c) some viruses reside commensally in the kidney or may be present transiently without lesions, and (d), (e) and (f) acute nephritis or nephrosis may be of non-specific origin during any febrile disease.

### References

1. REIMANN, H.A. (1938) An acute infection of the respiratory tract with atypical pneumonia: A disease entity probably caused by a filtrable virus. *J. Amer. med. Ass.* **111**, 2377.
2. REIMANN, H.A., HODGES, J.H. & PRICE, A.H. (1945) Epidemic diarrhea, nausea and vomiting. *J. Amer. med. Ass.* **127**, 1.
3. KIBRICK, S. & BENIRSCHKE, K. (1950) Acute aseptic myocarditis and meningoencephalitis in the newborn child infected with coxsackie virus group B, type 3. *New Engl. J. Med.* **255**, 883.
4. BURCH, G.E. (1967) Coxsackie B viral myocarditis and valvulitis identified in routine autopsy specimens by immunofluorescent techniques. *Amer. Heart J.* **74**, 13.
5. SMITH, J.W. & SANFORD, J.P. (1967) Viral arthritis. *Ann. intern. Med.* **67**, 651.
6. HENOCH, E. (1884) Nephritis nach Varicellen. *Klin. Wschr.* **21**, 17.
7. RIBBERT, H. (1904) Über Protozoenartigen Zellen in der Niere eines Syphilitischen Neugeborenen und in der Parotis von Kindern. *Centralb. allg. Path.* **15**, 945.

8. MÜLLER, J. (1922) Über die Protozoenartigen Gebilde in den Harnkanalchenepithelien Neugeborener. *Virchows Arch. Path. Anat.* **238**, 481.
9. COUNCILMAN, W.T. (1890) *Report on the Etiology and Prevention of Yellow Fever* (By George Sternberg), pp. 151-159. U.S. Marine Hosp. Serv. Government Printing Office, Washington, D.C.
10. MILLER, J.A. (1905) Nephritis complicating mumps. *Med. News*, **86**, 585.
11. JONESCO, D. (1928) Virulence de l'urine dans la rage humaine. *C. R. Soc. Biol. (Paris)*, **97**, 1731.
12. DORLAND'S (1965) *Illustrated Medical Dictionary*. Saunders, Philadelphia.
13. JENSEN, M.M. (1968) Viruses and kidney disease. Review. *Amer. J. Med.* **43**, 897.
14. UTZ, J.P. (1964) Viruria in man. *Progress in Medical Virology* (Ed. by J. L. Melnick), Vol. 6, p. 17. Hafner, New York.
15. UTZ, J.P. (1960) The pathogenesis of viruria: animal kidney infections by viruses isolated from human urine. abstracted, *J. clin. Invest.* **39**, 1037.
16. OSEASOHN, R., ADELSON, L. & KAJI, M. (1959) Clinico-pathologic study of thirty-three fatal cases of Asian influenza. *New Engl. J. Med.* **260**, 509.
17. FRANCIS, T. & MAASAB, H.F. (1965) Influenza viruses, *Viral and Rickettsial Infections of Man* (Ed. by F. L. Horsfall and I. Tamm), p. 704. Lippincott, Philadelphia.
18. BENYESH-MELNICK, M., ROSENBERG, H.S. & WATSON, B. (1964) Viruses in cell cultures of kidneys of children with congenital heart malformations and other disease. *Proc. Soc. exp. Biol. (N.Y.)*, **117**, 452.
19. LIPSEY, A.I. & BOLANDE, R.P. (1967) The exfoliative source of abnormal cells in urine sediment of patients with measles. *Amer. J. Dis. Child.* **113**, 677.
20. DEINHARDT, F. & HOLMES, A.W. (1963) Isolation of a latent virus from the kidney of a newborn infant. *J. Lab. clin. Med.* **62**, 872.
21. ASHKENAZI, A. & MELNICK, J.L. (1962) Induced latent infection of monkeys with vacuolating SV-40 Popova virus in kidneys and urine. *Proc. Soc. exp. Biol. (N.Y.)*, **111**, 367.
22. HULL, R.N. & MINNER, J.R. (1957) New viral agents recovered from tissue cultures of monkey kidney cells. *Ann. N.Y. Acad. Sci.* **67**, 413.
23. ROWE, W.P., HARTLEY, J.W., CRAMBLETT, H.G. & MASTROTA, F.M. (1958) Detection of human salivary gland virus in the mouth and urine of children. *Amer. J. Hyg.* **67**, 57.
24. FETTERMAN, G.H. (1952) A new laboratory aid in clinical diagnosis of inclusion disease of infancy. *Amer. J. clin. Path.* **22**, 424.
25. WELLER, T.H. & HANSHAW, J.B. (1962) Virulogic and clinical observations on cytomegalic inclusion disease. *New Engl. J. Med.* **266**, 1233.
26. SMITH, M.G. & VELLIOS, F. (1950) Inclusion disease or generalized salivary gland virus infection. *Arch. Path.* **50**, 862.
27. DENNY, E.R. & BAKER, B.M. (1929) Varicella complicated by acute nephritis: Report of a case associated with streptococcal infection of the tonsils. *Bull. Johns Hopk. Hosp.* **44**, 201.
28. MILLOUS, P. (1936) Une Epidémie de Varicella maligne au Cameroun. *Bull. Acad. nat. Méd. (Paris)*, **115**, 840.
29. JOHNSON, H.N. (1940) Visceral lesions associated with varicella. *Arch. Path.* **30**, 292.
30. WARING, J.J., NEUBERGER, K. & GEEVER, E.F. (1942) Severe forms of chickenpox in adults with autopsy observations in a case with associated pneumonia and encephalitis. *Arch. intern. Med.* **69**, 384.
31. CLAUDY, W.D. (1947) Pneumonia associated with varicella: Review of the literature and report of a fatal case with autopsy. *Arch. intern. Med.* **80**, 185.
32. CHEATHAM, W.J., WELLER, T.H., DOLAN, T.F. & DOWER, O.C. (1956) Varicella, report of two fatal cases with necropsy, virus isolation, and serologic studies. *Amer. J. Path.* **32**, 1015.
33. RIGDON, R.H., SHOJAH, S.A. & GARBER, E.P. (1962) Fatal chickenpox: A review of the literature and a report of a case. *Amer. Pract.* **13**, 292.
34. BULLOWA, J.F. & WISHIK, S.M. (1935) Complications of varicella. I. Their occurrence among 2,354 patients. *Amer. J. Dis. Child.* **49**, 923.
35. YUCEOGLU, A.M., BERKOVICH, S. & MINKOWITZ, S. (1967) Acute glomerulonephritis as a complication of varicella. *J. Amer. med. Ass.* **202**, 879.
36. MINKOWITZ, S., WENK, R., FRIEDMAN, E., YUCEOGLU, A. & BERKOVICH, S. (1968) Acute glomerulonephritis associated with varicella infection. *Amer. J. med.* **44**, 489.
37. FOLEY, T.P. & PERRIN, E.V.D. (1967) Fatal varicella in a child with congenital heart disease. *J. Amer. med. Ass.* **202**, 147.
38. AMAR, A.D. (1966) Hematuria caused by varicella lesions in the bladder. *J. Amer. med. Ass.* **196**, 450.
39. CHICK, F.E. (1966) Hematuria complicating varicella. *J. Amer. med. Ass.* **197**, 299.
40. HUGHES, W.T., STEIGMAN, A.J. & DE LONG, H.F. (1966) Some implications of fatal nephritis associated with mumps. *Amer. J. Dis. Child.* **111**, 297.
41. MONTEIRO, G.E. & LILLICRAP, C.A. (1967) A case of mumps nephritis. *Brit. med. J.* **iv**, 721.
42. UTZ, J.P., HOUK, V.N. & ALLING, D.W. (1964) Clinical and laboratory studies of mumps. IV. Viruria and abnormal renal function. *New Engl. J. Med.* **270**, 1283.
43. GRESSER, I. & KATZ, S.L. (1960) Isolation of measles virus from urine. *New Engl. J. Med.* **263**, 452.
44. BOLANDE, R.P. (1959) Inclusion-bearing cells in the urine in certain viral infections. *Pediatrics*, **24**, 7.
45. MELAMED, M.R. & WOLINSKA, W.H. (1961) On the significance of intercytoplasmic inclusions in the urinary sediment. *Amer. J. Path.* **38**, 711.
46. BOLANDE, R.P. (1961) Significance and nature of inclusion-bearing cells in the urine of patients with measles. *New Engl. J. Med.* **265**, 919.
47. LLANOS-RODAS, R. & LIU, C. (1966) Diagnosis of measles from urinary sediments. *New Engl. J. Med.* **275**, 516.
48. GITTES, R.F. (1963) Observations of nucleogeminy in urinary-sediment cells in the roseola infantum syndrome. *New Engl. J. Med.* **269**, 446.
49. SYVERTON, J.T. (1959) Enteroviruses. *Pediatrics*, **24**, 643.
50. SABIN, A.B., WIGAND, R. & KRUMBIEGEL, E.R. (1958) ECHO type 9 virus disease. *Amer. J. Dis. Child.* **96**, 197.
51. YUCEOGLU, A.M., BERKOVICH, S. & MINKOWITZ, S. (1966) Acute glomerulonephritis associated with ECHO virus type 9 infection. *J. Pediat.* **69**, 603.
52. HINUMA, Y., MIYAMOTO, T., MURAI, Y. & ISHIDA, N.A. (1962) Detection of coxsackie virus antigen in urinary cells by immunofluorescence. *Lancet*, **ii**, 179.
53. BURCH, G.E. & SUN, S.C. (1968) Viral nephritis. Editorial. *Amer. Heart J.* **73**, 1.
54. JENSEN, M.M. (1965) Experimental viral infection of the urinary tract of mice. *J. infect. Dis.* **115**, 370.
55. SUN, S.C., BURCH, G.E., SOHAL, R.S., & CHU, K.C. (1968) Coxsackie B4 viral nephritis in mice and its autoimmune-like phenomena. *Proc. Soc. exp. Biol. (N.Y.)*, **126**, 882.
56. HART, A.F. & CHERRY, J.D. (1965) Cytology of the urine in children after oral poliovirus vaccine. *New Engl. J. Med.* **272**, 174.

57. CHANY, C., LEPINE, P. LELONG, M., LE-TAN VINH, S.P. & VIRAT, J. (1958) Severe and fatal pneumonia in infants and young children associated with adenovirus infections. *Amer. J. Hyg.* **67**, 367.
58. SOHIER, R., BENSIMON, P., & LAGABRIELLE, B. (1957) Infection à adenovirus (type 7 prime) avec atteinte pulmonaire et rénale. *Bull. Soc. méd. Hosp. (Paris)*, **3**, 37.
59. BENYESH-MELNICK, M. & ROSENBERG, H.S. (1964) The isolation of adenovirus type 7 from a fatal case of pneumonia and disseminated disease. *J. Pediat.* **64**, 83.
60. VAN DER VEEN, J. & VAN DER PLOEG, G. (1958) An outbreak of pharyngoconjunctival fever caused by types 3 and 4 adenovirus at Waalwijk, The Netherlands. *Amer. J. Hyg.* **68**, 95.
61. GUTEKUNST, R.R. & HEGGIE, A.D. (1961) Viremia and viruria in adenovirus infection, detection in patients with rubella or rubelliform illness. *New Engl. J. Med.* **264**, 374.
62. PEREIRA, H.G. *et al.* (1963) A short description of the adenovirus group. *Virology*, **20**, 613.
63. KLEIN, S.W. & HUANG, W. (1963) Adenovirus recovered from tissue cultures of human kidney cells. *J. Pediat.* **63**, 774.
- 63a. NUMAZACKI, Y. *et al.* (1968) Acute hemorrhagic cystitis in children. Isolation of adenovirus 11. *New Engl. J. Med.* **178**, 700.
64. THOMPSON, W.W.D. & MACAULEY, H.F. (1920) Influenza as an etiological factor in nephritis. *Lancet*, **i**, 481.
65. DOWNIE, A.W. (1965) The poxvirus group. *Viral and Rickettsial Infections of Man* (Ed. by F. L. Horsfall and I. Tamm), p.932. Lippincott, Philadelphia.
66. SALDUN, M.L. (1932) Glomérulo nefritis difusa en primera fase, postvacunación antivariolosa. *Arch. Pediat. Urug.* **3**, 422.
67. HERBUT, P.A. (1944) Diffuse glomerulonephritis following revaccination for smallpox. *Amer. J. Path.* **20**, 1011.
68. SINGER, D.B., RUDOLPH, A.J., ROSENBERG, H.S., RAWLS, W.E. & BONIUK, M. (1967) Pathology of the congenital rubella syndrome. *J. Pediat.* **71**, 665.
69. TUCKER, E.S. & SCOFIELD, G.F. (1961) Hepatorenal necrosis. *Arch. Path.* **71**, 538.
70. JOHNSON, H.N. (1965) Rabies virus. *Viral and Rickettsial Infections of Man* (Ed. by F. L. Horsfall and I. Tamm), p. 823. Lippincott, Philadelphia.
71. MCNAIR-SCOTT, T. & TOKUMARU, T. (1965) The Herpes virus group. *Viral and Rickettsial Infections of Man* (Ed. by F. L. Horsfall and I. Tamm), p. 907. Lippincott, Philadelphia.
72. MIZELL, M., STACKPOLE, C.W. & HALPEREN, S. (1968) Herpes-type virus recovery from 'virus-free' frog kidney tumors. *Proc. Soc. exp. Biol. (N.Y.)*, **127**, 808.
73. GIBBON, N. (1956) A case of herpes zoster with involvement of the urinary bladder. *Brit. J. Urol.* **28**, 417.
74. ELTON, N.W., ROMERO, A., & TREJOS, A. (1955) Clinical pathology of yellow fever. *Amer. J. clin. Path.* **25**, 135.
74. ELTON, N.W. (1952) Histopathology of the kidney in yellow fever. *Arch. Med. Panamemos*, **1**, 41.
75. MAGALHAES, A. DE G. (1931) The kidneys in yellow fever. *Arch. Path.* **11**, 561.
76. OLIVER, J. & MACDOWELL, M. (1957) The renal lesion in epidemic hemorrhagic fever. *J. clin. Invest.* **36**, 99.
77. JOHNSON, K.M. (1967) Epidemic hemorrhagic fever: hemorrhagic nephrosonephritis. *Textbook of Medicine* (Ed. by P. B. Beeson and W. McDermott), p. 116. Saunders, Philadelphia.
78. MYHRMAN, H. (1951) Nephropathia epidemica a new infectious disease in northern Scandinavia. *Acta med. scand.* **140**, 52.
- 78a. ALLEN, A.M. *et al.* (1968) Simian hemorrhagic fever. II. Studies in pathology. *Amer. J. Trop. med. Hyg.* **17**, 413.
79. CONRAD, M.E., SCHWARTZ, F.D. & YOUNG, A.A. (1964) Infectious hepatitis—a generalized disease. A study of renal, gastrointestinal and hematologic abnormalities. *Amer. J. Med.* **37**, 789.
80. FINDLAY, J.M. & WILLCOX, R.R. (1945) Transmission of infectious hepatitis by feces and urine. *Lancet*, **i**, 212.
81. GILES, J.P. *et al.* (1964) Early viremia and viruria in infectious hepatitis. *Virology*, **24**, 107.
82. TAUB, E.A. (1966) Renal lesions, gross hematuria and marrow granulomas in infectious mononucleosis. *J. Amer. med. Ass.* **195**, 1153.
83. PETERS, J.H. (1967) Heterophile reactive antigen in infectious mononucleosis. *Science*, **157**, 1200.
- 83a. ALTER, S. *et al.* (1968) The kidney and infectious mononucleosis: Light and electron microscopic study. *Ann. intern. Med.* **68**, 1178.
84. COHEN, G.J. (1955) Acute nephritis complicating an illness resembling infectious mononucleosis; A case report. *Clin. Proc. Child. Hosp.* **11**, 38.
85. OLDSTONE, M.B.A. & DIXON, F.J. (1967) Lymphocytic choriomeningitis: Production of antibody by 'tolerant' infected mice. *Science*, **158**, 1193.
86. POLLARD, M., SHARON, N. & TEAH, B.A. (1968) Congenital lymphocytic choriomeningitis virus infection in gnotobiotic mice. *Proc. Soc. exp. Biol. (N.Y.)*, **127**, 755.
87. HIRSCH, M.S., MURPHY, F.A. & HICKLIN, M.D. (1968) Immunopathology of lymphocytic choriomeningitis virus infection of newborn mice. *J. exp. Med.* **127**, 757.
88. BATES, R.C., JENNINGS, R.B. & EARLE, D.P. (1957). Acute nephritis unrelated to group A hemolytic streptococcus infection: Report of ten cases. *Amer. J. Med.* **23**, 510.
89. SAKAMOTO, A. *et al.* (1952) Virus nephritis, preliminary note. *Tohoku. J. exp. Med.* **56**, 229.
90. DIXON, F.J. (1967) Glomerulonephritis and immunopathology. *Hosp. Pract.* **2**, 35.
91. KARSTAD, L. (1967) Aleutian disease, a slowly progressive viral infection of mink. *Current Topics in Microbiology and Immunology*, Vol. 40, p. 9. Springer-Verlag, New York.
92. ALLEN, A.C. & SPITZ, S. (1945) A comparative study of the pathology of scrub typhus (Tsutsugamushi disease) and other rickettsial diseases. *Amer. J. Path.* **21**, 603.
93. WOLF, G.L., COLE, C.R., CARLISLE, H.N. & SASLAW, S. (1967) The pathogenesis of Rocky Mountain spotted fever in monkeys. *Arch. Path.* **84**, 486.
- 93a. WHELTON, A., DONADIO, J.V. & ELISBERG, B.L. (1968) Acute renal failure complicating rickettsial infections in glucose-6-phosphate dehydrogenase-deficient individuals. *Ann. intern. Med.* **69**, 323.
94. YOW, E., BRENNAN, J.C., PRESTON, J. & LEVY, S. (1959) The pathology of psittacosis. A report of two cases with hepatitis. *Amer. J. Med.* **27**, 739.
95. VALESEK, W. (1968) Ornithosis in the population of Vienna. *Wien. Klin. Wschr.* **79**, 810.
96. REIMANN, H.A. (1938) Typhoid pyelonephritis: Renal typhoid. *J. Amer. med. Ass.* **111**, 691.
97. EAST, J., PROSSER, P.R., HOLBOROW, E.F. & JAQUET, H. (1967) Autoimmune reactions and virus-like particles in germ-free NZB mice. *Lancet*, **i**, 755.
98. ANDERSON, T.G., MCCREA, L.E. & SETTEMBRINO, A.T. (1963) Viruses as the etiologic agents of urinary tract infection. *J. Urol.* **90**, 92.
99. GINDER, D.R. (1964) Increased susceptibility of mice infected with mouse adenovirus to Escherichia coli-induced pyelonephritis. *J. exp. Med.* **120**, 117.