

## THE FULL-THICKNESS SKIN GRAFT.

By T. POMFRET KILNER, F.R.C.S.

*(Associate Plastic Surgeon, St. Thomas's Hospital; Plastic Surgeon, St. Andrew's Hospital, Dollis Hill; London County Council; Queen Mary's Hospital, Roehampton; Princess Elizabeth of York Hospital for Children, Shadwell; and Lord Mayor Treloar Hospital, Alton.)*

In my previous contributions to this Journal (May and September, 1934) I dealt in considerable detail with the preparation and uses of the Thiersch graft: in this article I propose to discuss other forms of free skin graft.

### The Wolfe Graft.

Although several previous attempts had been made to transplant whole-thickness skin with varying degrees of success, the credit for the introduction of this form of free skin graft is usually correctly given to Wolfe of Glasgow who, in 1875, described his successful use of the material in the reconstruction of a lower eyelid.

In 1896, Krause reported the use of the same type of graft in a large series of cases and described in great detail a technique which differs little from that employed to-day. In view of this work, in which full credit was given to the earlier reports of Wolfe and others, it is not unreasonable that this graft should be named, as it frequently is, the Wolfe-Krause graft. "Full-thickness," "Dermo-epidermal" and "Dissected" are alternative names for the same material.

The Wolfe graft consists of the full thickness of the skin down to, but not including, subcutaneous fat. It is outlined by a sharp scapel and is freed in much the same manner as that employed in raising skin in the dissecting room. When the outlining incision is being made the skin should not be stretched: once this incision is completed, stretching of the skin by an assistant facilitates the removal of the graft.

The graft should be cut to precisely the size and shape of the defect it is to fill and no allowance made for contraction as was at one time advised. It is essential that lymph spaces should be kept open in as nearly as possible normal state if early establishment of nutrition is to be assured. In order to ensure this a pattern is made in tin-foil, cellophane, or other convenient material, of the area to be covered and this, applied to the donor area, is used as a guide for the outlining incisions. With very few exceptions it is impracticable to cut a Wolfe graft (as it is possible and desirable to cut a Thiersch graft) before dealing with the recipient area.

The scar or ulcer is carefully and freely excised, when possible well out into normal surrounding skin and down to healthy subcutaneous tissue. Undermining of the edges is to be avoided for this may lead to hæmatoma formation. The margins of such a wound usually retract spontaneously and sometimes to a surprising extent once they are freed from the scar tissue. It is only after this has occurred that it is possible to judge the size of graft required and it is for this reason that the taking of the graft is deferred until this stage.

Hæmostasis is of paramount importance and is obtained, without ligatures, by the firm application of gauze sponges wrung out of iced saline solution or by blowing a stream of air on the surface from a hair-drying machine. Where discrete bleeding vessels persist, diathermy coagulation may be employed, but the areas of coagulation should be kept as small as possible.

The pattern is now cut and is marked in any convenient manner to indicate its outer surface and, if of roughly symmetrical shape, at least one of its extremities. It is surprisingly easy to find oneself with a perfectly cut graft which will fill the defect only with its raw surface outwards if these precautions are not taken, and if the pattern is not transferred immediately to the donor area.

In order to maintain strict asepsis in the donor area and more especially when some infection is present in the recipient area, the pattern may be boiled or otherwise sterilized at this stage and the operator's gloves may be changed or washed.

The graft is now cut in the manner described, avoiding all unnecessary trauma by the use of fine tissue hooks in lieu of dissecting forceps. I have found the earlier form of tissue hook too thick and large for this purpose and have had made a particularly fine hook with detachable handle. By this means I can ensure the possession of really sharp hooks at all times for the hook portion of the instrument may be discarded for replacement or repair whenever it becomes blunt or otherwise damaged. The graft is spread out on the pattern, correctly orientated and, wrapped in gauze soaked in warm saline, is put on one side while the raw surface left by its removal receives attention. If the raw surface is a small one it may be closed by direct approximation of its edges, after suitable undermining, but this procedure frequently leads to the formation of a keloidal scar. If left to epithelialise spontaneously, healing is delayed for several weeks, the wound is a painful one for dressings and the resulting scar is often a very disfiguring one. For some time now it has been my practice to cut a Thiersch graft from the neighbouring skin and apply it with marginal suture fixation and pressure dressing to the raw surface. This ensures a perfectly healed surface in 7—10 days.

The graft is now transferred to the recipient area and placed in correct position by reference to the markings on the pattern. Single sutures are placed at four cardinal points and the edges of the graft are then very carefully stitched to the margins of the defect by a fine silk-worm gut suture on an eyeless (atraumatic) needle applied in continuous end-on (vertical) mattress fashion. The edges are handled very gently with fine dissecting forceps or with the fine tissue hooks already mentioned. All blood is expressed from under the graft, by rolling a folded gauze sponge over it, before the final points of the suture are inserted. A layer of Tulle Gras is applied and a pressure dressing is built up of cottonwool soaked in either saline or flavine-paraffin emulsion. This dressing is held snugly in position under gentle elastic tension by the application of either Elastoplast strapping or a crêpe bandage. Ferris Smith, doing experimental work on such grafts, found that the ideal pressure was 30 m.m. mercury and provided this by incorporating in the dressing a rubber bag (Fig. 3) which could be kept pumped up, by means of a sphygmomanometer apparatus, to this pressure. Sorbo-rubber and sea sponges have been used for the same purpose. In the majority of situations the technique described is sufficient: in others, where application of pressure to an irregular surface is required, the pressure bag method repays the extra trouble it entails.

## THE FULL-THICKNESS SKIN GRAFT.

---

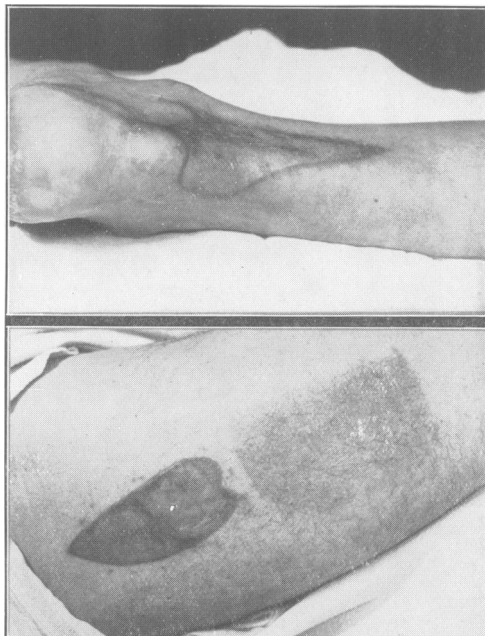


FIG. 1.

Wolfe graft applied to raw surface left by complete excision of chronic ulcer over Tendo Achillis. The lower photograph shows the donor area and the area from which a Thiersch graft was taken to cover it



FIG. 2.

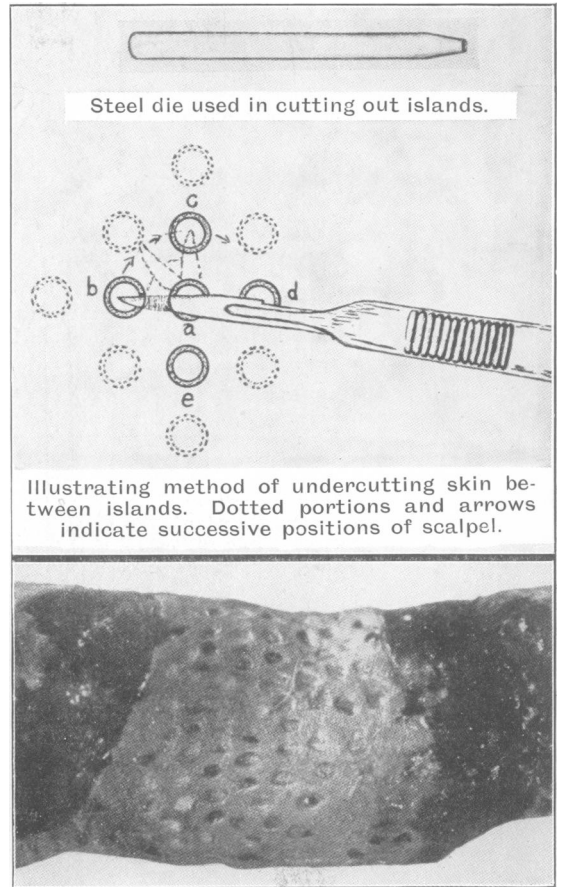
A dog-bite of the lip with loss of skin and deep tissue treated by the immediate application of a small Wolfe graft.

THE FULL-THICKNESS SKIN GRAFT.

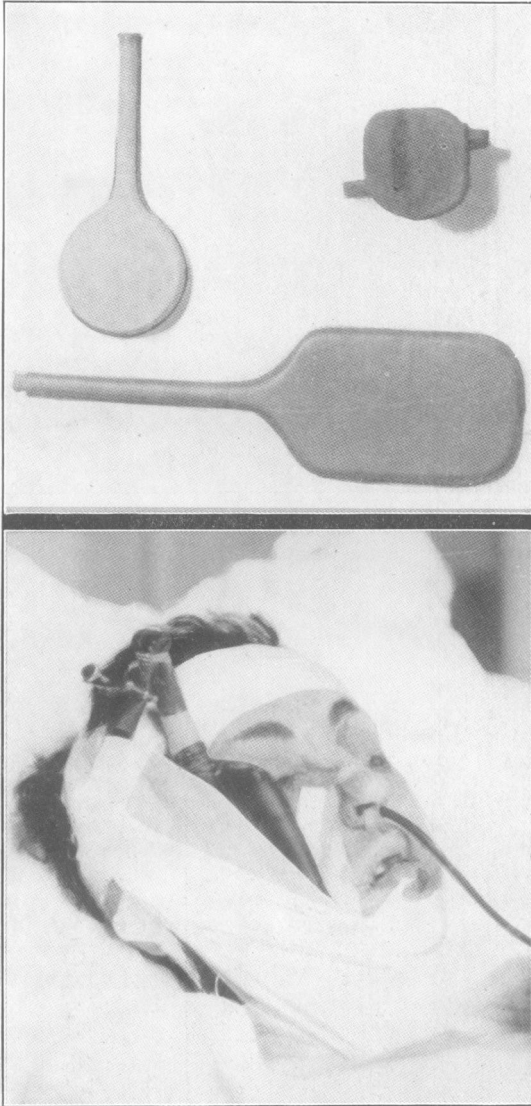

FIG. 3.

Pressure bags devised by Ferris Smith.  
 Mode of application over Wolfe graft of cheek.  
 Optimum pressure, 30 m.m. Hg.  
 (Illustration kindly supplied by Dr. Ferris Smith).



Sieve graft covering entire popliteal space.

FIG. 4.

The Sieve graft as devised by Douglas.  
 (From *Surgery, Gynecology & Obstetrics*, 1930, L, 1019.)

## THE FULL-THICKNESS SKIN GRAFT.

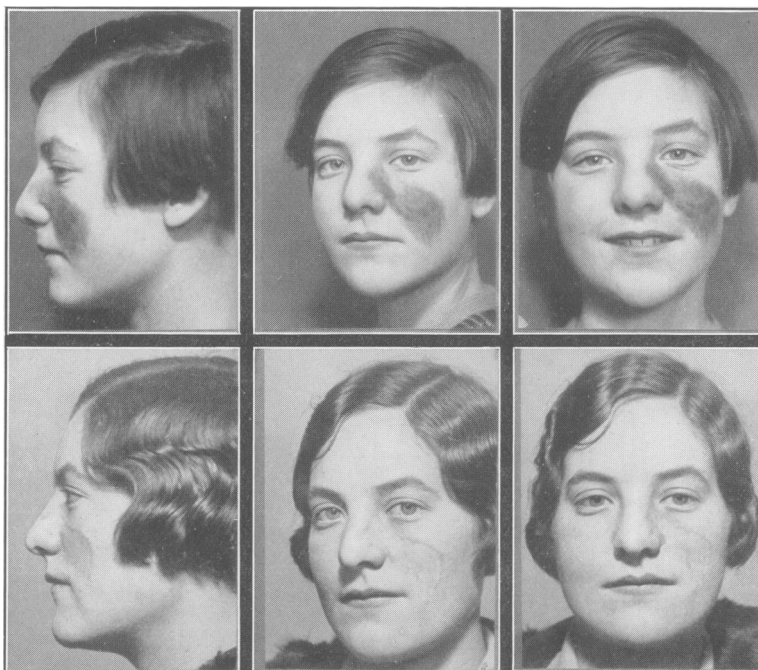

FIG. 5.

Wolfe graft replacement of large pigmented hairy mole. The lower photographs do not do the case justice for with a minimum of "paint and powder" the cheek looks perfectly natural.

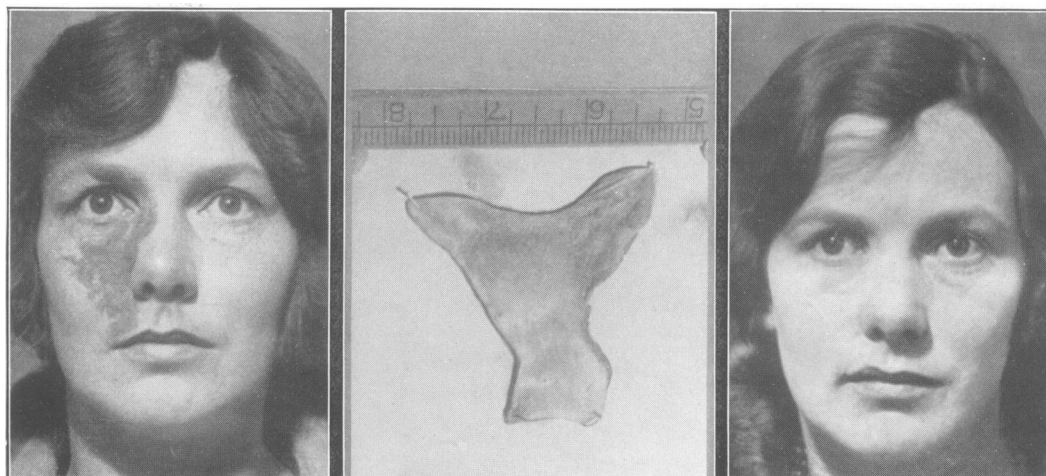


FIG. 6.

Replacement by split-skin graft of the scarred and disfiguring area left by a variety of treatment of a capillary naevus.

## THE FULL-THICKNESS SKIN GRAFT.

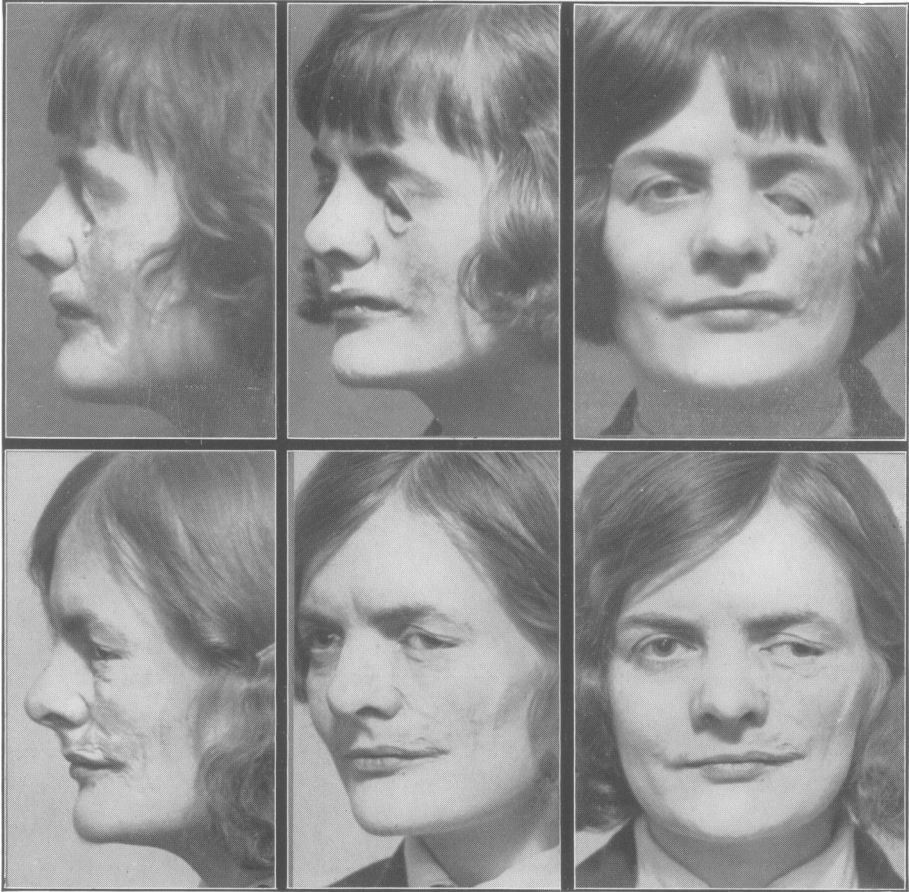

FIG. 7.

Severe burn of face producing extreme ectropion of eyelid, eversion of upper lip and disfiguring scarring of cheek. Ectropion of eyelid and eversion of lip treated by Thiersch grafts applied on moulds. Scarring of cheek excised: raw surface covered by Wolfe graft from right buttock. Pressure dressing by felt over Tulle Gras.

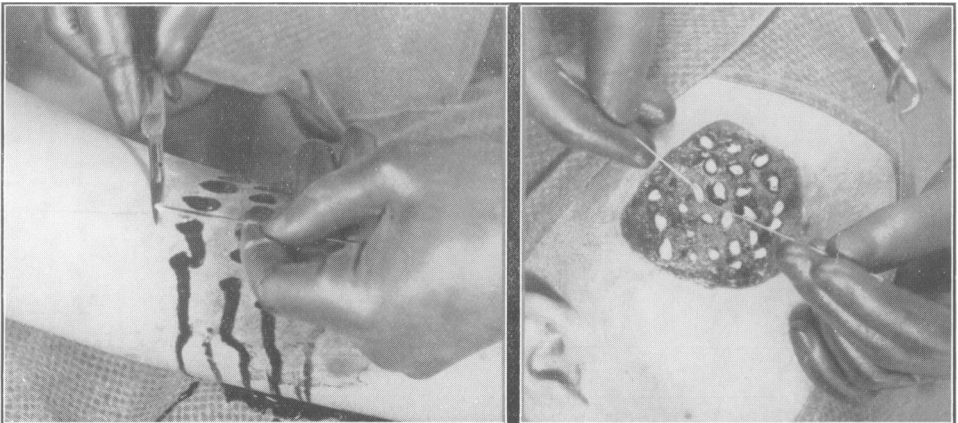


FIG. 8.

The "Pinch Graft"—showing method of cutting and application of small deep grafts.

Perforations or snicks in the graft may be employed to provide for escape of blood or serum but these detract from the cosmetic result and are not necessary when hæmostasis and uniform pressure-dressing can be obtained.

Wolfe grafts are most successful when the recipient area is backed up by bone: they are least likely to succeed on soft mobile surfaces. When a limb is under treatment, splinting of adjacent joints should be provided.

It has been shewn by Staige Davis and Traut that the Wolfe graft derives its early nutrition from lymph exuding from the raw surface under it. It is for this reason that it is so important that all receptive lymph spaces shall be normally open and not closed as they would be were the graft cut larger than the defect. Vessels grow in rapidly from the edges of the defect and actual bleeding from such a graft has been noted in 84 hours.

The dressings are left undisturbed for about 7 days when the surface of the graft and the suture line are very gently wiped and the sutures are removed. The dressing is reapplied and pressure is maintained for a further 5—7 days. Bullæ sometimes develop and these should be snipped with fine scissors and treated with 1 per cent. watery picric acid solution. Any small area of surface necrosis should be treated in similar manner, the object being to maintain a state of dry and localized, rather than moist and spreading gangrene.

Massage, preferably with some greasy preparation such as cold cream, lanoline cream or cocoa butter, will do much to keep the graft soft and supple. Without it the surface epithelium becomes dry and dirty-looking and takes a considerable time to shed itself.

While the percentage of successful and complete "takes" with the Thiersch graft should be in the region of 100, the corresponding figure for Wolfe grafts may be roughly stated as 75.

Occasionally the whole graft may be lost owing to the formation of a hæmatoma under it, while frequently small areas of necrosis occur which may rob the result of cosmetic perfection.

The marginal scar is usually good but in some cases is keloidal and requires suitable Radium treatment.

While contraction in a Thiersch grafted area is by no means uncommon, little or no contraction occurs in an area successfully grafted with whole-thickness skin.

In some individuals a Wolfe graft remains dead-white and may stand out as a very obvious patch: in others, apparently as the result of blood disintegration in its substance, it may take on a peculiar dirty brown tinge which may last for a long time or even be permanent. Expression of blood from the graft before sewing it in position may prevent this discolouration.

It is important to choose, for an exposed normally hairless region, a donor area free from hairs and for this reason shaving should play no part in pre-operative preparation. Even when this point has received careful attention trouble may be experienced from the free growth of hairs which were absent or barely visible in the recipient area.

Figs. 1, 2, 5 and 7 show results of various types of case treated with the Wolfe graft.

### Hairy Wolfe Graft.

Free full-thickness skin grafts may be taken from the scalp or other hair-bearing regions. Such grafts will survive and continue to grow hair and are of particular value in the restoration of eyebrows in cases of severe facial burns. The technique employed differs in no essential detail from that already described but, where practicable, due attention should be given both in taking and in planting the graft, to the direction of the hairs.

Although ideal in theory I have had little success with the transplantation of hairy skin from the pubic region to fill defects in the hairy scalp.

### Other forms of free Skin Graft.

Various modifications of the two main forms of free skin graft have been introduced. Chief among these should be mentioned the *small deep (pinch) grafts* described by Staige Davis (Fig. 8). These grafts are taken without difficulty under local anæsthesia by picking up points of skin on the ends of long straight needles and slicing off the cones so formed with a sharp knife. They are essentially Wolfe grafts in their centres and Thiersch grafts at their edges. They differ from the Reverdin form of graft much as the Wolfe graft differs from the Thiersch graft. They should be between 0.2 and 0.5 c.m. in diameter and they may be applied to a granulating surface where they are disposed at intervals of 0.5 c.m. The cosmetic result which they give is not sufficiently good to warrant their use on exposed parts but they provide a most valuable means of obtaining healing in those long-standing raw surfaces from which it is difficult or impossible to eradicate all infection, and on which sheet grafts of the Thiersch variety so frequently fail.

*The Intermediate, Split-skin or Thick Razor graft*, used extensively by Blair and Brown, usually cut by the help of the suction box mentioned in my first article in this Journal, takes a place mid-way between the Thiersch and the Wolfe graft both as regards certainty of "take" and final appearance. Both the Lane-Joynt and Humby apparatus may be employed for cutting such grafts. Fig. 6 illustrates the use of such a graft on the cheek and upper lip.

Douglas has described the *Sieve graft*—a full-thickness graft with numerous circular perforations corresponding to islets of skin left behind on the donor surface (Fig. 4). With this, again, the cosmetic result is likely to be far from ideal while the method of Thiersch grafting the raw surface in the donor area does away with the necessity for assisting healing by leaving behind islands of skin.

*Buried Grafts.* Braun has revived a method of burying thin pinch grafts originally described by Pollock in 1870. McClelland and Keller have separately described *Tunnel grafting*, the introduction of full-thickness skin strips into tunnels made below a granulating surface.

Thiersch graft strips have been woven into similar surfaces while epithelial paste, obtained by scraping moist skin with a knife, has been injected below such granulations.

The probable explanation of the success of all these latter methods is the "natural" pressure-dressing and accurate apposition of graft to bed which the procedures provide. All have their uses in selected cases.