

# PATELLECTOMY

RODNEY SWEETNAM, F.R.C.S.

*Orthopaedic Surgeon, The Middlesex Hospital.*

REMOVAL of the patella for fracture began to be performed towards the end of the last century. Good reports followed the introduction of this novel procedure and everyone seemed surprised that the results were so good in spite of the removal of what had hitherto been regarded as a vital link in the quadriceps apparatus. Unfortunately, however, Heineck (1909) in an influential paper strongly condemned the procedure and there then followed a period when it seems that the operation was regarded with disfavour. It was not until over twenty years later, following a paper by Brooke (1937), that patellectomy again became popular. Ever since that time surgeons have without hesitation considered total removal of this bone an acceptable procedure in certain fractures; some, however, felt that, although justified following irrevocable injury, patellectomy itself so damaged the normal mechanism and power of the knee that it was only warranted under these extenuating circumstances. They did not feel that it was justified in patients with established patello-femoral osteoarthritis, let alone as a method of preventing serious dissemination of osteoarthritis in knee joints affected by early and mild degeneration or chondromalacia of the patello-femoral compartment alone.

Patellectomy is now an established manœuvre, not only in certain fractures, but also in patello-femoral osteoarthritis, and even in the treatment of generalised osteoarthritis when symptoms and signs, both clinical and radiological, suggest that a major part of the pain is arising beneath the knee cap.

## Pathological Considerations

### Fractures

- Fractures of the patella are of three types:—
- Direct violence (comminuted)
  - Muscle violence (transverse)
  - Minor marginal fractures

In considering the operation of patellectomy, we are mainly concerned with severe comminuted fractures but in some cases also with widely separated transverse fractures (Fig. 1).

The former are usually the result of a blow or a fall to the ground onto the flexed knee; the latter, a sudden violent contraction of the quadriceps as the patient stumbles.

Often there is wide separation of the fragments which, when comminution is present, makes any attempt at reduction quite impossible.

Transverse fractures when widely separated are usually associated with rupture of the lateral expansions at the level of fracture and it is this soft tissue injury, just as much as the fracture itself, which makes operative repair necessary. In this type of fracture it is not always necessary to remove the patella, for accurate reduction and firm fixation may be achieved at operation thus ensuring a smooth articular surface when the bone heals.

## Patello-Femoral Osteoarthritis

Chondromalacia patellæ (Wiles, Andrews and Devas, 1956) and recurrent subluxation or dislocation are frequent precursors of patello-femoral osteoarthritis. Gradual erosion of the articular cartilage causes the usual underlying reactive bone changes until the appearance is identical with that of osteoarthritis due to trauma, infection, rheumatoid arthritis, or any of the other known or unknown causes of patello-femoral osteoarthritis.

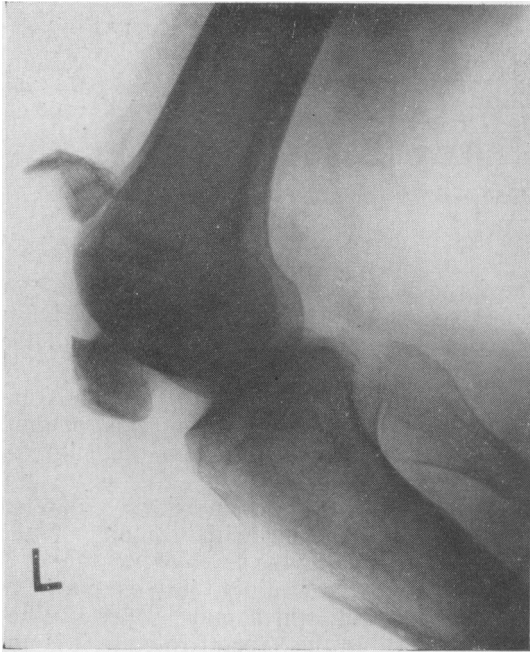In all cases, progressive wear of the articular surfaces of the patella and femoral condyles produce the local symptoms and signs of osteoarthritis which sooner or later must spread to the remainder of the knee joint. (Figs. 2 and 3).

## Indications for Patellectomy

### Fractures

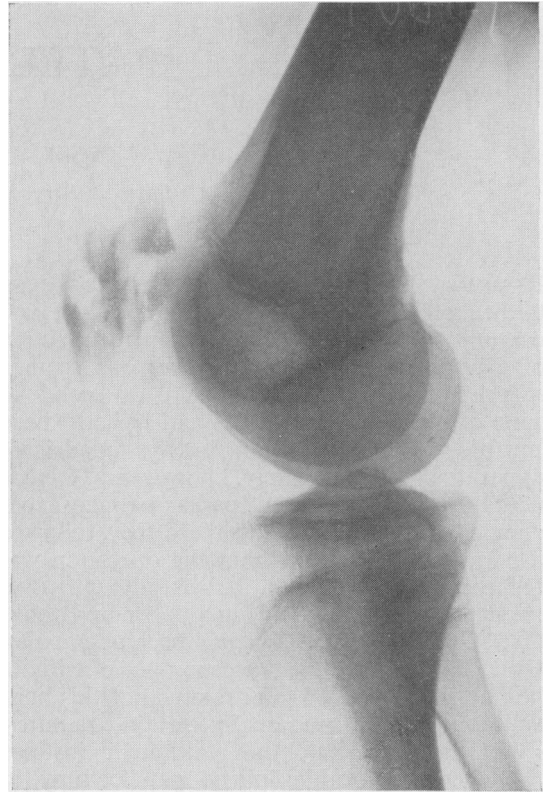
Comminuted fractures of the patella usually produce disruption of the articular surface which, in view of the multiplicity of fracture lines, commonly defy attempts at reduction. Nothing short of "anatomical" replacement can be accepted, and as this is virtually impossible in most cases, patellectomy is the most satisfactory treatment.

In transverse fractures, perfect reduction and



(a)

FIG. 1.—(a) Widely separated transverse fracture of the patella.



(b)

FIG. 1.—(b) Comminuted fracture of the patella.

firm fixation must be achieved if the bone is to be retained, and if this is not possible, then the patella must also be excised.

### Osteoarthritis.

Early osteoarthritis of the knee beginning in the patello-femoral part of the joint may cause troublesome symptoms at an early stage. There is very little doubt that removal of the patella soon after the onset of pain in such cases, not only rids the patient of the symptoms, but also reduces the likelihood of the degenerative arthritis spreading to involve the whole joint.

In certain patients with late generalised osteoarthritis of the knee, the predominant symptoms are those due to the osteoarthritic changes in the patello-femoral joint. When it seems likely that a significant proportion of the pain is arising beneath the knee-cap, removal of the patella may well bring about great relief—albeit partial, but none the less welcome.

Pain experienced under the knee-cap on going up or down stairs or rising from a sitting position, particularly if associated with a feeling of crepitus, suggests patello-femoral osteoarthritis, and when associated with palpable crepitus and pain on moving the patella on the

femoral condyles, radiographs are likely to confirm its presence. In such patients, removal of this source of pain by patellectomy is often very successful indeed.

### Recurrent Dislocation of the Patella in Adults

Whereas patellectomy is seldom indicated in children with recurrent dislocation, in adults with secondary degenerative changes it is often performed. In most cases some form of realignment of the quadriceps apparatus must also be done to prevent recurrent lateral slipping of the central portion of the tendon (West and Soto-Hall, 1958).

### Less Common Indications

Removal of the patella may be indicated as part of some other procedure, for example arthrodesis, arthroplasty or synovectomy, or very rarely in chronic infection of the bone itself.

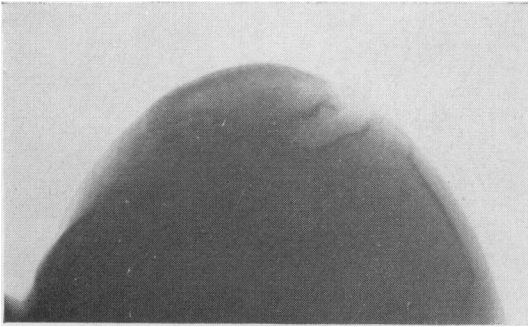


FIG. 2.—Patello-femoral osteoarthritis.

### Method of Operation

The choice of operative method must, of course, depend upon the indication. There are, however, two basic techniques:—

1. Simple enucleation, with the gap being closed by suture of the vertical incision through the anterior fibro-tendinous tissue from which the patella has been dissected.
2. Closure of the patellar gap by direct transverse suture of quadriceps tendon to patellar ligament.

In addition, various "plastic" methods of reinforcing the gap by flaps or advancements with or without direct suture of quadriceps to patellar ligaments have been advised, but they are not widely used.

In fracture of the patella a similar choice is presented in comminuted fractures due to direct violence and therefore unassociated with rupture of the lateral expansions. Transverse fractures accompanied by complete rupture of these expansions, however, are usually repaired by direct suture across the whole breadth of the quadriceps apparatus.

In the absence of damage to the lateral expansions, the choice, therefore, is between direct ligament to tendon suture with shortening of the central portion of the quadriceps apparatus, or leaving the gap and relying upon the strength of the lateral expansions without the possible disadvantage of any disproportionate shortening of the patellar portion. In the latter case, the gap is bridged by the thin patellar aponeurosis closed vertically by a few catgut sutures.

Closure of the gap transversely by suture of quadriceps tendon to patellar ligament, not always an easy procedure, is, I believe, not only unnecessary but actually a cause of delayed recovery of full extension as well as flexion.

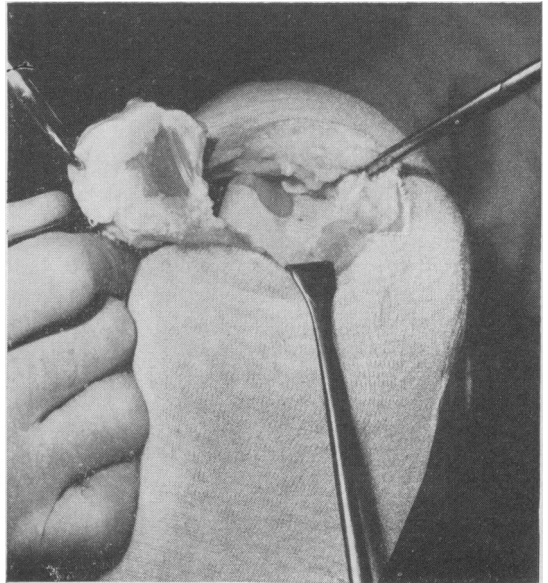


FIG. 3.—Patello-femoral osteoarthritis. The changes here are mainly in the lateral part of the joint.

It is not difficult to understand why recovery of flexion is delayed, because shortening of the quadriceps complex has occurred. The reason for the delay in extension is more complicated.

In order to understand why such an extension lag may develop when the central portion of the quadriceps has been shortened, one has to remember and visualise the lateral expansions, the importance of which has been stressed by Hey Groves (1937). Although thin, these broad tendinous bands produce deep markings at their sites of insertion into the tibia, thus indicating their strength and power of muscular pull transmitted to the bony attachment. Clearly they do not only possess considerable strength, but also act with the patellar portion of the quadriceps in producing extension of the knee, the whole being one functioning unit.

Direct suture of quadriceps tendon to patellar ligament must shorten the central portion of the quadriceps apparatus by a distance equal to the height of the patella. This inevitably produces some "bunching up" and therefore relative lengthening of the lateral expansions, which must disorganise the co-ordinated action of the quadriceps as a whole, and render any muscle action exerted through these lateral expansions much less effective compared with a similar force transmitted through the shortened central portion.

Should it be, therefore, that the patellar part

of the quadriceps apparatus, probably the strongest, is the more effective in extending the flexed or semi-flexed knee, whereas the vastus medialis and lateralis through the lateral expansions are largely responsible for securing the last twenty or so degrees of extension, then we should have a ready explanation for the development of a lag of extension in spite of closing the patellar gap transversely. More than this—we might reasonably assume that the lag was actually caused by the closure with central shortening and apparent lengthening of the lateral expansions. Indeed, no such lag should, or in my experience does, occur if the gap is not closed in this way.

I believe, therefore, that least damage is done to the quadriceps at the time of patellectomy by simple enucleation of the bone through a vertical incision through its anterior fibro-tendinous covering. The edges of this layer are later brought together with three or four quite fine catgut sutures, because, as can be demonstrated at operation, there is no tension on this line of suture when the knee is flexed; indeed, tension becomes less as flexion increases.

When patellectomy is performed for a transverse fracture it is commonly found that the lateral expansions of the quadriceps are widely torn on both sides at the level of fracture. The subsequent repair of the whole width of the quadriceps at this level usually results in almost equal shortening of central and lateral portions. This is because there is a certain amount of overlapping of the thin lateral expansions as they are repaired; a fortunate occurrence, for in this way relative shortening of the central portion is avoided and a subsequent lag in extension is unusual.

### Operative Technique

When the lateral expansions are intact, the following simple technique is advised.

A small transverse skin incision is best, and usually it need be only a little longer than the width of the patella itself. The anterior surface is cleared by dissecting back the upper and lower skin flaps.

Enucleation of the bone is carried out by sharp dissection. A distinct layer of fibro-tendinous tissue runs over and is adherent to its anterior surface, and blends with the quadriceps tendon above and patellar ligament below. This layer is incised vertically down to bone and the flaps elevated outwards until they become continuous with the lateral expansions on either side (Fig. 4a). The bone is then

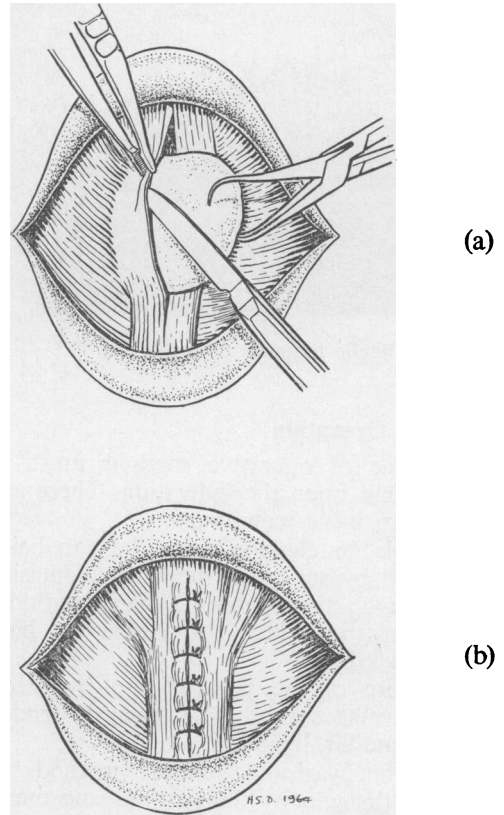


FIG. 4.—(a) Elevation of the fibro-tendinous layer during enucleation of the patella.  
(b) Closure of the defect by approximation of the lateral fibro-tendinous flaps.

grasped with a towel clip or similar instrument and its remaining peripheral ligamentous and synovial attachments freed.

The central defect in the quadriceps, left by the enucleation of the patella, is simply closed by approximation of the two lateral flaps by a series of quite fine plain catgut sutures (Fig. 4b). It can readily be demonstrated that this vertical suture line is not under tension when the knee is flexed; indeed flexion tends to bring the edges together. In time these thin fibro-tendinous flaps hypertrophy, in some cases even producing bone from remaining remnants of detached periosteum. The central portion of the quadriceps tendon thus becomes firmly united to the patellar tendon without shortening.

*Damaged Lateral Expansions.* Fractures of the patella caused by indirect violence are frequently widely separated and accompanied by tearing of the lateral expansions. In such cases, when patellectomy is indicated, great

care must be taken to repair these expansions after the fragments of bone have been removed.

No special description of the technique is necessary. The transverse tear of the whole quadriceps apparatus is usually repaired with stout chromic catgut and in this case the quadriceps tendon firmly approximated to the patellar ligament. No harm comes from this direct suture because the lateral expansions will have been shortened by an equal amount by the natural slight bunching and overlap which occurs along the transverse suture line.

#### After Treatment

The traditional post-operative management requires four to six weeks' immobilisation of the knee in full extension, followed by several further weeks of protected weight bearing with a plaster backslab. Indeed, in patients in whom the lateral expansions have been torn and repaired at operation, this is still the best routine to follow. After enucleation of the patella, however, immobilisation and protection is quite unnecessary.

After operation no more than a light wool and crepe pressure dressing is required. No suture line is under tension, so that no other support is necessary. Static quadriceps exercises commence on the day after operation, flexion exercises on the fifth day, and walking, at first with reduced weight on the leg using crutches, two days later.

When the wound is soundly healed and the patient walking independently with crutches or sticks, he is encouraged to enter a rehabilitation centre where progress is usually more

rapid than in an Out-patient Physiotherapy Department.

#### Comment

Removal of the patella is now a common operation, and provided that the correct indications are observed, the end result is usually good. Many different techniques of operation are employed and their very number suggests that the final results probably differ little one from another. I have no doubt, however, that the simple technique described combined with early post-operative mobilisation produces a very good result in the great majority of patients, not only more quickly than by other methods, but at the expense of less effort in the post-operative period.

The long-term results of removal of the patella in man do not suggest that its absence gives rise to excessive wear or degenerative change in the articular surface of the femoral condyles (West, 1962). Experimental evidence, however, does indicate that such wear occurs after patellectomy in the rabbit (Bruce and Walmsley, 1942).

Certainly the good long-term results in man confirm that any harmful effect must be slight and of little consequence when compared with the known benefits of the operation. From the purely mechanical view as well, we know that joint function is so little impaired that any reduction in performance is usually so slight as to prove unnoticed. Indeed, Brooke (1937) has expressed the view, which he bases upon experimental evidence, that the mechanical advantage of the quadriceps is actually improved by patellectomy!

#### REFERENCES

- BROOKE, R. (1937): The Treatment of Fractured Patella by Excision. A Study of Morphology and Function, *Brit. J. Surg.*, **24**, 733.
- BRUCE, J., and WALMSLEY, R. (1942): Excision of the Patella. Some Experimental and Anatomical Observations, *J. Bone Jt. Surg.*, **24**, 311.
- EVANS, D. K. (1962): Osteomyelitis of the Patella, *Ibid.*, **44** (B), 319.
- GROVES, Hey E. W. (1937): A Note on the Extension Apparatus of the Knee Joint, *Brit. J. Surg.*, **24**, 747.
- HEINECK (1909): The Modern Operative Treatment of Fractures of the Patella, *Surg. Gynec. Obstet.*, **9**, 177.
- WEST, E. E., and SOTO-HALL, R. (1958): Recurrent Dislocation of the Patella in the Adult, *J. Bone Jt. Surg.*, **40** (A), 386.
- WEST, E. E. (1962): End Results of Patellectomy, *Ibid.*, **44** (A), 1089.
- WILES, P., ANDREWS, P. S., and DEVAS, M. B. (1956): Chondromalacia of the Patella, *Ibid.*, **38** (B), 95.