
Research/Recherche

Red-dot card test of the paracentral field as a screening test for optic nerve disease in onchocerciasis*

I. Murdoch,^{1,2} B.R. Jones,^{1,2} O.E. Babalola,¹ S.N. Cousens,³ I. Bolarin,¹ & A. Abiose^{1,4}

A new screening test for optic nerve pathology is described, consisting of a series of four red targets presented at an angle of 12° in the paracentral field above and below the horizontal meridian. Non-perception and desaturation of the targets are recorded. Inter-observer variability studies found a κ value = 0.8. A total of 6831 individuals aged ≥ 5 years in communities that were mesoendemic for savanna onchocerciasis in Kaduna State, northern Nigeria, were screened using the test. Of the participants 22% were unable to complete the test; almost two-thirds of these (62%) were aged 5–8 years. After exclusion of those visually impaired or blind according to WHO criteria and those unable to complete the test, the test showed a sensitivity of 40% and a specificity of 98% for optic nerve disease when inability to visualize one or more targets was used as the definition of test failure. The sensitivity increased to 54% with a specificity of 96% when the criterion for failure included desaturation of one or more targets. These values compare favourably with those for other available screening methods. The test took 1–2 minutes to perform and was readily accepted by patients and nurses.

Introduction

Traquair postulated that all colour isopters were of equal size if hue, saturation and intensity were equated (1), and this has been corroborated by subsequent work by Carlow et al. (2). The presence of central and/or paracentral red desaturation, however, remains a useful indicator of significant optic nerve damage (3, 4).

In a large community-based trial of ivermectin for the treatment of onchocerciasis in the guinea savanna of Kaduna State, northern Nigeria, communities were screened for optic nerve disease to ascertain whether ivermectin provoked optic neuritis with loss of vision in the first few weeks after dosing, and whether the drug given annually would exacerbate or prevent onchocercal optic nerve disease from occurring subsequently. A simple card test involving presentation of red targets at an angle of 12° in the paracentral field was devised for this purpose. This article describes the test and presents an evaluation of its use in screening.

Method and subjects

The red-dot card test is designed for use at 33 cm from the patient's eyes and a cord of this length is attached to the base of the card to ensure easy determination of this working distance. The card itself

* From the Kaduna–London Collaboration for Research on Onchocerciasis.

¹ Ahmadu Bello University Teaching Hospital, Kaduna, Nigeria.

² International Centre for Eye Health, Institute of Ophthalmology, London, England. Requests for reprints should be sent to Dr Murdoch at the following address: 79 Minster Road, London NW2 3SJ, England.

³ Department of Epidemiology and Population Sciences, London School of Hygiene and Tropical Medicine, London, England.

⁴ National Eye Centre, Kaduna, Nigeria.

Reprint No. 5739

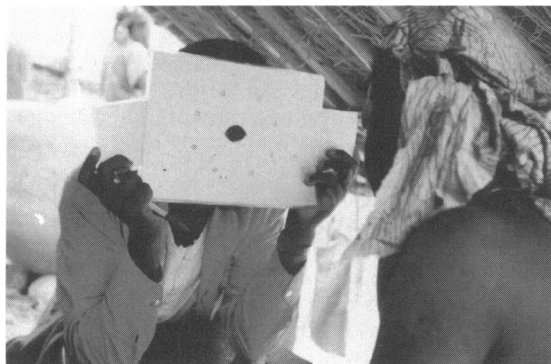
consists of a central fixation hole and four 1-cm diameter circular areas which lie above and below the horizontal meridian at an angle of 12° from fixation. These circular areas can be turned red by moving the “slides” at the side of the test card. In addition there are four “dummy holes” in the card so the patient does not know where the red colour will appear. A central hole for the examiner’s eye ensures that central fixation can be checked throughout the test. The cards were manufactured locally and laminated for durability in the field (Fig. 1).

The test identifies two levels of defect: (1) when all spots are seen but one or more spot is reported as having colour desaturation; and (2) when one or more red spots are not seen.

Six ophthalmic nurses were trained in the use of the cards and a small inter-observer study was carried out. The nurses worked in pairs in the local ophthalmic outpatient department, each pair testing 41 patients (82 eyes) with the card; each patient was tested separately by both nurses. For the 82 eyes tested there were five discordant results: for two eyes one nurse recorded inability to see one spot and another nurse recorded ability to see it; in one eye desaturation was recorded by one nurse and not by the other; and in the final two eyes there was disagreement as to which quadrant/hemifield showed desaturation (overall $\kappa = 0.8$).

A total of 6831 individuals aged ≥ 5 years were screened for optic nerve disease using a variety of screening tools including visual acuity, blue–yellow colour perception, Arden contrast sensitivity gratings, paracentral confrontation with a 6-mm white target, and peripheral confrontation by counting fingers in four outer quadrants, in addition to ocular

Fig. 1. Use of the red-dot card test on the left eye of an individual. The slides are both withdrawn, so no red dots are currently visible. The observer is holding the card test and checking the patient’s fixation by looking through the central hole.



examination with fundoscopy (5). Mark-1 Friedman field analysis was performed on a random sample ($n = 329$) of those screened and on all those in whom optic nerve pathology was suspected from any of the above tests. If three or more spots were missed or four or more spots had reduced sensitivity in any quadrant with the Friedman test, a field defect was considered to be present.

In all instances the free and informed consent of the subjects was obtained prior to testing.

On the basis of the findings in the random sample, the full screening process (“gold standard”) was shown to have $>99\%$ sensitivity for detecting optic nerve disease. Individuals identified as having possible optic nerve disease were given a detailed examination by ophthalmologists, which included the Friedman field test, dilated fundoscopy for optic disc assessment, and fluorescein angiography to look for optic neuritis. A diagnosis of definite or probable optic nerve disease was then made according to the criteria shown below.

- *Definite optic nerve disease*
 - marked disc pallor recorded by an ophthalmologist together with defects in visual function and/or pupillary light response; or
 - active optic neuritis confirmed by fluorescein angiography and angiography
- *Probable optic nerve disease*
 - an eye with no perception of light together with no view of the disc and no history or other ocular pathology to account for the finding; or
 - an afferent pupillary defect identified by an ophthalmologist together with no view of the disc and no history or other ocular pathology to account for the finding; or
 - mild or moderate disc pallor recorded by an ophthalmologist in association with recorded defects in visual function or an afferent pupillary defect; or

Table 1: Comparison of the results of the red-dot card assessment of visual fields by ophthalmic nurses with those of the Friedmann field test (results for single eyes)^a

Friedmann field test finding:	Ophthalmic nurse finding:		
	Normal	Red desaturation defect	Red dot not seen
Normal	867	118	33
Defect	319	89	321

^a κ for desaturation or not seen = 0.43; κ for not seen = 0.44.

Table 2: **Red-dot card assessment of optic nerve disease compared with a gold standard comprising a full screening process plus an ophthalmological examination** (results for single eyes after exclusion of individuals visually impaired or blind according to WHO criteria)

Gold standard	Red-dot card test finding:			
	Normal	Red desaturation	Red dot not seen	Unable to perform test
No optic nerve disease	9340	234	198	2521
Probable or definite optic nerve disease	262	76	227	142

- disc pallor recorded by an ophthalmic nurse, disc not seen by an ophthalmologist and three or more visual function tests failed or an afferent pupillary defect.

Results

The results obtained using the red-dot card test and those using the Friedmann field test are compared in Table 1. A comparison of performance in the red-dot card test with that in the gold standard is shown in Table 2. Individuals who were visually impaired or blind according to WHO criteria have been excluded from the analysis.

For detection of optic nerve disease, the sensitivity of the red-dot card test was 32% for inability to see one or more dots (40% after exclusion of those unable to perform the test) and 43% for inability to see a dot or perceive desaturation of a spot (54% after exclusion of those unable to perform the test). The specificity was 78% for inability to see one or more dots (98% after exclusion of those unable to perform the test) and 76% for inability to see a dot or perception of desaturation (96% after exclusion of those unable to perform the test).

Inability to perform the test was strongly linked to age, with 62% of all those unable to perform the test being aged 5–8 years. The sensitivity and specificity levels are quoted here with exclusion of those unable to perform the test.

Discussion

The sensitivity and specificity of the red-dot card test compare favourably with those reported by Trobe et al. for two colour tests carried out on 28 eyes with chiasmal hemianopias, 17 eyes with optic nerve fibre bundle defects, and 14 normal controls. Using a confrontation technique and a tangent screen technique, they reported a sensitivity of 79–83% for chiasmal defects and only 17–34% for optic nerve defects using static targets. The specificities were 73–74% for chiasmal defects and 100% for optic nerve defects.

The time taken is always an important consideration in undertaking screening work. The red-dot card test took 1–2 minutes per subject to explain and perform, a similar time to the simultaneous counting fingers field test and slightly longer than visual acuity testing. An average of 15 minutes was taken for a Friedmann field examination. The red-dot card test proved acceptable to patients and staff in field work aimed at screening populations for optic nerve disease.

Acknowledgements

We thank the ophthalmic nurses I. Liman, B. Lawal, S. Labwane, J. Onyema, J. Dauda and P. Danboyi, and the Director and following staff of the Nigerian Institute for Trypanosomiasis Research: S. Idakwo, B. Asha, I. Nuhu, M. Zakari, A. Agwu, M. Kura, A. Oseni, J. Gadzama, for their invaluable technical help in undertaking this field work; and the Kaduna State Ministry of Health, local government area workers and villagers in the trial areas for their cooperation. This work was sponsored by the UNDP/World Bank/WHO Special Programme for Research and Training in Tropical Diseases (Project I.D. numbers 870456 and 910553), the Leverhulme Trust and Sight Savers.

Résumé

Un nouveau test de dépistage de l'atteinte du nerf optique dans l'onchocercose: le Red Dot Card Test

Cet article décrit un nouveau test de dépistage de l'atteinte du nerf optique (Red Dot Card Test), qui consiste à présenter un carton portant quatre points rouges à un angle de 12° dans le champ paracentral, au-dessus et au-dessous du méridien horizontal. L'absence de perception et la désaturation des points rouges sont notées. L'étude de la variabilité inter-observateurs chez des infirmiers en ophtalmologie effectuant le test a montré des résultats discordants pour cinq des 82 yeux examinés ($\kappa = 0,8$).

Au total, 6831 personnes âgées de cinq ans et plus, vivant dans des communautés où l'onchocercose de savane est mésoendémique, ont été

examinées dans l'Etat de Kaduna, dans le nord du Nigéria. Parmi les sujets examinés, 22% ont été incapables de faire le test; près des deux tiers d'entre eux (62%) étaient des enfants de cinq à huit ans.

Les résultats ont été comparés à ceux d'une méthode de dépistage beaucoup plus complète des lésions patentes ou probables du nerf optique, de sensibilité supérieure à 99% et prise comme référence. Après exclusion des sujets atteints d'une perte de vision ou aveugles selon les critères de l'OMS, et des malades incapables de faire le test, on a obtenu une sensibilité de 40% et une spécificité de 98% pour le dépistage d'une atteinte du nerf optique en prenant comme définition de test négatif l'incapacité de voir au moins un des quatre points. La sensibilité passait à 54% avec une spécificité de 96% lorsque le critère de négativité prenait en compte la désaturation d'un ou plusieurs points. Ces résultats sont tout à fait comparables à

ceux des autres méthodes de dépistage disponibles. Le test s'exécute en une à deux minutes et est bien accepté par les malades et par les infirmiers.

References

1. **Traquair HM.** *An introduction to clinical perimetry*, 6th ed. London, Kimpton, 1949.
2. **Carlow TJ et al.** Colour perimetry. *Archives of ophthalmology*, 1976, **94**: 1492–1496.
3. **Trobe JD et al.** Confrontation visual field techniques in the detection of anterior visual pathway lesions. *Annals of neurology*, 1981, **10**: 28–34.
4. **Walsh H.** Topical diagnosis of lesions in the visual sensory pathway. In: Miller NR, ed. *Clinical neuro-ophthalmology*, vol. 1, 4th edit, Williams & Wilkins, Baltimore, MD, USA.
5. **Abiose A et al.** Reduction in incidence of optic nerve disease with annual ivermectin to control onchocerciasis. *Lancet*, 1993, **341**: 130–134.