

Studies on the treatment and prevention of colorectal liver metastases

Irving Taylor MD ChM FRCS

Senior Lecturer and Honorary Consultant Surgeon, Royal Liverpool and Broadgreen Hospitals, Liverpool

Key words: COLORECTAL NEOPLASMS; LIVER METASTASES; DIAGNOSIS; HAEMODYNAMICS; TREATMENT; PREVENTION

Summary

Liver metastases occur in as many as 50% of patients with colorectal cancer and are regarded as a principal cause of death. Both clinical and experimental studies have been undertaken in an attempt to understand the haemodynamic changes occurring in established liver metastases. Trials of various forms of treatment based on these observations are described. In addition attempts to reduce the incidence of subsequent liver metastases are discussed.

Introduction

'A cancer of the intestine seldom kills of itself; it most commonly kills by producing some other disease which produces more immediate mischief.'

JOHN HUNTER

Improvements in surgical techniques, modern antibiotics, and advances in anaesthesia have ensured a smoother postoperative course for patients undergoing surgery for colorectal cancer. Unfortunately, recurrence-free survival after surgery alone remains static. Adjuvant systemic cytotoxic therapy either with single agents such as 5-fluorouracil (1-3) or with combination chemotherapy (4) indicate some benefit, but in general, for the toxicity incurred, the results are disappointing. Adjuvant local radiotherapy may have a role in preventing local recurrence in Dukes Stage-C rectal cancer (5,6) but does not reduce distant metastases — particularly to the liver.

The development of colorectal liver metastases remains a major problem in management. In most series 15-20% of patients with primary colorectal cancer have multiple liver metastases at the time of initial surgery, although this figure could be much greater. In addition as many as 50% of patients will eventually develop liver metastases, often in the absence of recurrence elsewhere (7).

Once liver metastases have developed the

prognosis is poor, the median survival varying in different series between 4 and 9 months (8-10). It is known that liver metastases develop by tumour invasion of the mesenteric veins (11), and hence tumour emboli enter the liver via the portal vein. While the majority of these cells are destroyed, some undoubtedly survive and may subsequently develop into micro-metastases. Although these enter a period of dormancy, some 'awaken' and form macroscopic metastases.

This paper discusses studies designed to investigate the diagnosis, haemodynamics, treatment, and possible prevention of colorectal liver metastases.

Diagnosis of liver metastases

It is frequently stated that accurate preoperative diagnosis of liver metastases is neither important nor necessary. The reasons given are: firstly, that accurate techniques for the recognition of small metastases are not available; and secondly, that the management of the primary tumour would not be altered, and in any case no worthwhile treatment exists for multiple liver metastases. While these contentions may be true, it has been demonstrated by reference to other cancers that attempts at accurate staging of malignant disease eventually leads to more rational assessment and hence improved management and possibly improved prognosis. It is helpful for the surgeon to be aware before operating that liver metastases are present since he may wish to treat these either by resection (if solitary) or by infusional techniques (if multiple). Under these circumstances preoperative hepatic angiography is valuable to establish accurate hepatic arterial anatomy.

Several techniques are now available for liver imaging. We have performed a study to assess the value of liver ultrasound scanning compared with technetium-99m (^{99m}Tc)-sulphur colloid scanning in a group of 100 patients presenting with colorectal cancer (12). Fifteen patients

were subsequently shown to have liver metastases at laparotomy. Isotope scanning gave a correct preoperative diagnosis in 14 patients and ultrasound scanning was accurate in 13. Serum alkaline phosphatase levels were elevated in 13. Of the 85 patients without metastases the liver was correctly reported as normal in 83 (97.6%) by isotope scanning and in 84 (98.8%) by ultrasound scanning.

Accordingly ultrasound scanning of the liver appears to be as accurate as isotope scanning for the detection of multiple colorectal liver metastases. The facilities for ultrasound are becoming more widely available and almost daily technical improvements are being made. Although it is still heavily operator-dependent and has a 10% failure rate, with future advances it is likely that ultrasound will provide an accurate method of 'screening' for liver metastases. Nevertheless, at the present time small metastases undetectable by conventional imaging techniques do exist and influence prognosis.

Can colorectal liver metastases be predicted?

A prospective survey was performed to determine whether specific clinical investigations were of value in predicting the subsequent development of colorectal liver metastases (13). Ninety-eight patients with primary colorectal cancer but without liver metastases at the time of initial surgery (as determined by preoperative isotope and ultrasound scanning and the surgeon's impression at operation) were followed up for 2-5 years. Isotope scanning and more recently ultrasound scanning of the liver were carried out at 6-monthly intervals and the outcome in all patients has been monitored.

Twenty-three different 'risk factors' were noted, but only 3 were shown to be statistically significantly associated with the development of liver metastases. Of the 21 patients who subsequently developed such metastases 61.9% had a history of preoperative weight loss (greater than 7 lb (3.18 kg)) ($p = 0.0018$), 61.9% had Dukes Stage-C tumours ($p = 0.0015$), and 67.0% had an elevated preoperative serum alkaline phosphatase level ($p = 0.001$). Using logit analysis these three 'risk factors' were shown to be independent of each other, but their effect was additive in that 71.9% of patients with all three factors developed multiple liver metastases within 15 months.

Accordingly it would appear that certain patients with colorectal cancer have an increased risk of developing metachronous liver metastases, and if they can be recognised be-

fore operation, then more selective adjuvant therapy is theoretically possible.

The blood supply of colorectal liver metastases

The growth and development of liver metastases depends primarily on an adequate blood supply. Breedis and Young (14) originally demonstrated, using injection techniques in living and postmortem material, that the hepatic artery was the chief blood supply to established liver metastases. This finding has been confirmed in postmortem casts (15) and more recently in vivo both in experimental animals (16) and patients (17).

CLINICAL STUDIES

Studies were performed to measure flow into colorectal liver metastases in patients undergoing surgery for primary colorectal cancer (18). Liver blood flow was calculated by measuring the rate of clearance of xenon-133 (^{133}Xe) after direct parenchymal injection, 0.1-0.15 ml (100-150 μCi) of ^{133}Xe dissolved in saline being injected into both normal liver and metastases at operation. A 2.5-cm (1-in) sodium iodide detector with multihole collimator was used to record clearance. Previous studies in the dog had shown that this method is reproducible and gives an accurate indication of tissue perfusion compared with both electromagnetic flowmetry and an indicator dilution technique using ^{51}Cr -labelled red blood cells. This technique gave a mean value in normal liver of 73.4 ± 33.7 (SD) ml/min/100 g and in metastatic tissue of 41.5 ± 22.5 ml/min/100 g. Occlusion of the hepatic artery showed a consistent fall of perfusion into metastatic tissue to almost zero, indicating a predominant blood supply via the hepatic artery.

Seventeen patients undergoing infusional treatment for multiple colorectal liver metastases were also studied, 2 mCi of ^{133}Xe dissolved in saline being injected into the portal vein and/or the hepatic artery while the patient was positioned supine under the gamma camera so that the anterior surface of the liver was in its field of view. These studies allowed haemodynamic monitoring of flow into liver metastases. In patients with portal vein catheters alone ^{133}Xe imaging indicated little if any perfusion into metastatic tissue. As expected, with hepatic arterial injection there was good perfusion of metastatic tissue. However, of prime interest were patients in whom hepatic artery ligation and cytotoxic perfusion was being performed as well as portal venous perfusion. In these patients injection of ^{133}Xe not only into the hepatic artery but also into the portal vein re-

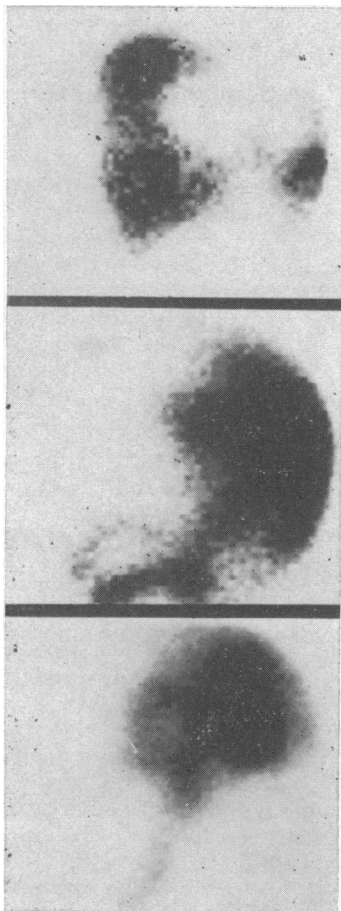


FIG. 1 *Top scan shows preoperative ^{99m}Tc -sulphur colloid liver scan with liver metastases as filling defects. After ^{133}Xe injection into the hepatic artery (middle scan) perfusion is again chiefly to the metastases. Injection of ^{133}Xe into the portal vein with the hepatic artery ligated (lower scan) also produced a distribution image to the liver metastases. (Reproduced by permission from the British Journal of Cancer (18).)*

vealed good perfusion of metastatic tissue (Fig. 1). Hence after hepatic artery ligation a compensatory haemodynamic state exists whereby perfusion into metastatic tissue occurs from the portal vein. These findings may explain the initial good response which may occur following hepatic artery ligation alone, although objective remission may be only **short-lived**.

It has been suggested that portal venous flow to metastatic tissue is minimal because the thin-walled vein is easily compressed by tumour tissue, whereas higher arterial pressure and the thicker walls allow arterial flow. Clearly this is unlikely to be the entire explanation.

Other possibilities exist to explain increased portal venous flow following arterial ligation. For instance, are haemodynamically active substances released by metastatic tissue during the period of ischaemia? None have so far been described. We investigated the possibility that haemodynamically active gut hormones may be released by ischaemic metastatic tissue. However, no increased levels of gastrin, substance P, bombesin, or cholecystokinin were recognised within metastatic tissue.

ANIMAL STUDIES

Experimental studies have been carried out on the rat to study dose responses for haemodynamically active substances on liver and tumour blood flow. The responses in normal liver and within metastatic tumour have been compared and the response to hepatic artery ligation studied.

Of the various agents studied — vasopressin, glucagon, and adrenaline — the responses to vasopressin have been the most interesting (19). Nutritional blood flow measured by the clearance of ^{133}Xe following parenchymal injection and portal venous flow measured by electromagnetic flowmetry were studied in 48 rats before and during infusion of vasopressin. Vasopressin in the dosage range 0.05–1.0 U was infused into a systemic vein over 20 min. Two doses produced statistically significant changes in blood flow: 0.4 U increased nutritional liver blood flow from a mean of 57.2 ± 9.3 (SEM) ml/min/100 g tissue to a mean of 82.5 ± 9.9 ml/min/100 g and decreased portal venous flow; 1.0 U decreased nutritional flow from a mean of 86.7 ± 13.8 ml/min/100 g to 44.3 ± 6.3 ml/min/100 g. Other doses produced no significant change. Hence the dose of vasopressin necessary to produce therapeutically desired changes in hepatic blood flow is critical.

Colorectal cancer was produced in rats with azoxymethane and in approximately 10% spontaneous multiple liver metastases developed. Nutritional blood flow into tumour tissue was measured by direct parenchymal ^{133}Xe injection. The effect of hepatic artery ligation was also studied. Vasopressin (0.4 U) enhanced the effect of hepatic artery ligation in reducing perfusion to spontaneously occurring liver metastases while maintaining perfusion to normal liver tissue. Hence in the chemotherapy of liver metastases it is possible that vasopressin could be used as an adjunct to render tumour tissue **ischaemic**.

Glucagon had no statistically significant effect on total liver blood flow but increased portal venous flow, whereas adrenaline

(1:200 000) increased both total liver blood flow and portal venous flow. The responses to these substances, however, suggest that they are unlikely to be of therapeutic value as an adjunct to arterial ligation.

Treatment of established colorectal liver metastases

Patients with solitary liver metastases are probably best treated by resection (20,21). A recent study reported an 82% 1-year survival rate and a 41% 3-year survival rate following resection of large solitary hepatic metastases (22). Unfortunately, at the time of presentation less than 5% of liver metastases are solitary.

In patients with multiple synchronous colorectal liver metastases techniques designed to deliver high concentrations of cytotoxic agents directly to metastatic tissue via the hepatic artery have been described (23-25). In addition, hepatic arterial ligation alone or in combination with cytotoxic therapy is feasible (26,27). More recently internal radiation therapy by the administration of yttrium-90 (⁹⁰Y) microspheres via the hepatic artery has been described (28-30) and attempts at complete liver dearterialisation embarked upon (30).

A clinical trial designed to assess the value of different perfusion techniques in the management of colorectal liver metastases was reported in 1978 (31). Patients with resectable colorectal cancer and palpable liver secondaries at the time of surgery were each allocated to one of four regimens. Hepatic artery ligation and arterial cytotoxic perfusion (using 5-fluorouracil) and portal vein cytotoxic perfusion (via the umbilical vein) did not improve symptom-free survival compared with a control group who had resection of the primary tumour alone. However, the group of patients who underwent both hepatic artery ligation and perfusion as well as cytotoxic perfusion via the umbilical vein did have a significantly increased postoperative survival (mean 9.8 ± 3.4 (SD) months) (Fig. 2).

A possible explanation for this improvement may be related to the compensatory mechanisms that were shown to occur following hepatic artery ligation (see above). In man the portal vein supplies about 75% of hepatic blood flow and has an oxygen saturation approaching 85%, which is sufficient to provide 30-35% of the oxygen requirements of the liver. As previously described, following hepatic artery ligation there is a compensatory increase in portal vein blood flow and one could postulate that tumour growth which initially diminishes after hepatic artery ligation subsequently increases as perfusion via the portal vein increases.

Complete dearterialisation of the liver is difficult and unlikely to be completely achieved. Michels (32) described 26 routes by which arterial blood can reach the liver, and the development of a collateral circulation has been demonstrated in man by arteriography as early as 1 week after hepatic artery ligation.

Accordingly, possible theoretical benefits could accrue from hepatic artery ligation combined with portal vein cytotoxic perfusion. This technique has the benefit of avoiding long-term hepatic artery perfusion, which in our experience is frequently associated with technical problems and high cytotoxicity. Further encouragement for this method was provided by a report which suggested possible therapeutic benefit from this regimen (33).

Thirty-five patients have been treated by this technique over the past 5 years. Selection of patients was rigid. All were under 65 years of age and had an operable primary colorectal cancer with multiple liver metastases but no evidence of distant spread elsewhere. There was good liver function in each patient with no evidence of jaundice or ascites and no intra-abdominal sepsis.

Intraoperative blood flow studies using parenchymal injection of ¹³³Xe have been carried out on several patients to ensure adequate reduction of flow to metastatic tissue following hepatic artery ligation. In other patients intraoperative injection of 5% fluorescein into the hepatic artery was sufficient to confirm the predominant

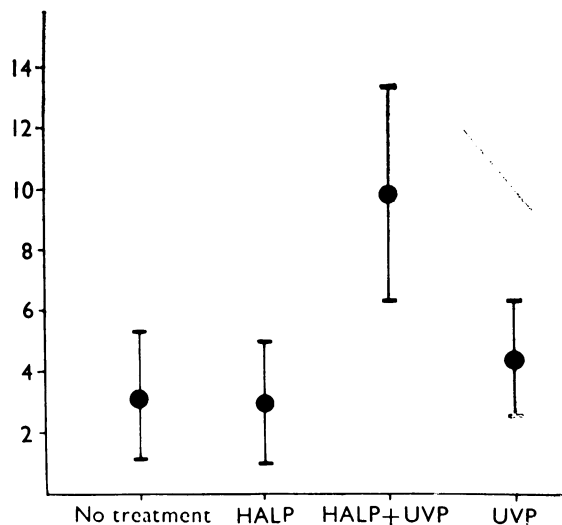


FIG. 2 Mean survival rates in each group of patients (months ± 1 SD). HALP = hepatic artery ligation and perfusion, UVP = umbilical vein perfusion. (Reproduced by permission from the British Journal of Surgery (31).)

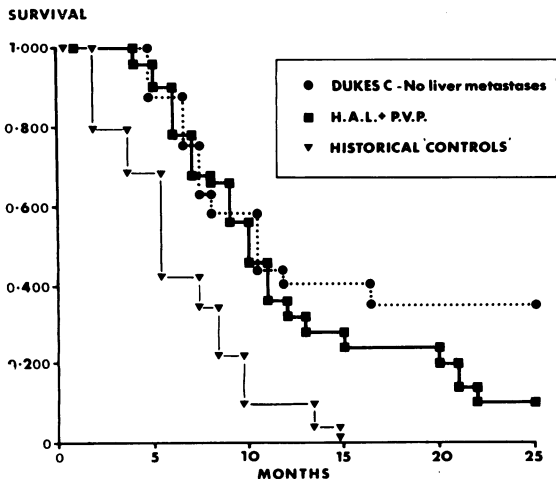


FIG. 3 Survival analysis following hepatic artery ligation (HAL) and portal vein perfusion (PVP) contrasted with a mean of historical control patients and patients with Dukes Stage-C colorectal cancer without liver metastases.

arterial flow to metastases. A number of post-operative complications occurred, including wound infection (28.6%), anastomotic dehiscence (5.7%), oral ulceration (20%), leucopenia (22.8%), and thrombocytopenia (22.8%). In patients in whom less than 20% of the liver was tumour tissue (Stage 1) the median survival was 15.0 months; when 20–70% of liver was tumour tissue (Stage 2) median survival fell to 10.5 months; and in patients in whom more than 70% of liver was tumour tissue (Stage 3) mean survival was 5.5 months.

The results in these patients were compared with those in a group of historical 'controls' (with untreated liver metastases but resected colorectal cancer) and a group of patients with Dukes Stage-C cancer but without liver metastases (Fig. 3). It is apparent that the results have been disappointing. Some marginal benefit in terms of symptom-free survival was obtained, but it is doubtful whether this slight (if any) improvement justifies routine use of this technique. However, the prognosis was not significantly worse than in patients with Dukes Stage-C disease. The median survival of the group as a whole was 10 months.

Nevertheless, the theory of metastatic ischaemia by arterial ligation is, I believe, sound. However, further research and subsequent controlled clinical trials are necessary to establish a technique which adequately produces ischaemia without subsequent compensatory phenomena—hence our interest in haemodynamically active substances as previously described. In addition,

hepatic arterial embolisation seems promising and deserves further study (34,35).

Studies on the possible prevention of subsequent colorectal liver metastases

The treatment of established multiple liver metastases remains unsatisfactory. The prognosis is poor and few patients survive longer than 1 year. It is known that micrometastases reach the liver by the portal venous system and initially obtain their nutrition from portal venous blood.

A randomised controlled trial was initiated in October 1975 to assess the possibility of reducing the incidence of subsequent liver metastases in patients presenting with primary colorectal cancer by adjuvant cytotoxic perfusion (with 5-fluorouracil) given directly into the portal venous system via the 'obliterated' umbilical vein. Two hundred and twelve consecutive patients with colorectal cancer but without macroscopic liver metastases (all patients have preoperative ^{99m}Tc -sulphur colloid scans, liver function tests, and more recently ultrasound scanning of the liver) were randomly allocated into either a control group or a group who received postoperative cytotoxic perfusion. There were 12 postoperative deaths (6 in each group) and 13 patients were excluded following randomisation (presence of liver metastases at laparotomy, cirrhosis, and because of technical problems with insertion of umbilical catheter). The doses used and the early results of this study have been published previously (36).

The mean age, site, stage, degree of differentiation, and extent of local fixity of the tumour

Details of patients randomised in adjuvant cytotoxic liver perfusion study

	Control group	Perfusion group
No of patients	97	90
Mean age (years \pm 1 SD)	63.4 \pm 11.0	62.5 \pm 12.9
Dukes staging		
A	11.2 %	8.5 %
B	58.9 %	55.3 %
C	29.9 %	36.2 %
Degree of differentiation		
Well	58.9 %	51.1 %
Moderately	30.8 %	37.2 %
Poor/anaplastic	10.3 %	11.7 %
Degree of fixity		
Free or moderately adherent	78.5 %	60.6 %
Densely adherent	15.0 %	17.0 %
Macroscopic tumour remaining locally	6.5 %	22.3 %*

* $\chi^2 = 11.37$; $df = 2$; $p = 0.0034$.

showed no statistically significant differences between the two groups of patients (see table). In the postoperative period nausea occurred more frequently in the perfusion group than in the controls although the median hospital stay in the two groups was similar (16.1 and 17.0 days respectively).

So far 38 patients in the control group have died and liver metastases were present in 17. In the perfusion group 19 patients have died with recurrent disease and of these 5 had multiple liver metastases.

The early results (median follow-up 34 months) of this trial suggest that the incidence of liver metastases may be reduced by this technique, although the incidence of local and/or peritoneal recurrence, particularly in rectal cancer, is not altered.

Conclusions and the future

There is little need to emphasise the problems of liver metastases. Once established, the prognosis associated with them is poor and no readily available and unequivocally effective treatment is feasible. In this paper I have discussed specific lines of research which have been undertaken in an attempt both to treat and, it is hoped, to prevent (or at least delay) the development of established liver metastases in patients with colorectal cancer.

Future research in this direction will necessitate studies of tumour haemodynamics and attempts to prevent compensatory flow into tumour tissue. In addition, further controlled clinical trials to assess chemotherapeutic as well as adjuvant regimens are required.

The majority of these studies were performed in the Department of Surgery, Royal Liverpool and Broadgreen Hospitals, Liverpool. I should like to express my appreciation to several people for their assistance and encouragement: Mr J T Rowling supplied the initial impetus; Professor R Shields allowed the facilities of the Department of Surgery to be made available; Mr B Mooney, a research registrar, helped in the animal studies; Mr J Yates, Mrs S Roberts, and Mr G Lepts provided invaluable technical assistance; Miss M Crowley type the manuscript. Professor R Shields and Mr D George allowed patients admitted under their care to be included in the various studies. Finally, I should like to extend my gratitude to the University Cancer Research Committee for funding the various projects.

References

- 1 Ansfield F. A less toxic fluorouracil dosage schedule. *JAMA* 1964;190:234-6.
- 2 Horton J, Olson KB, Sullivan J, *et al.* 5-fluorouracil in cancer: an improved regimen. *Ann Intern Med* 1971;73:897-900.
- 3 Higgins GA, Dwight RW, Smith JV, *et al.* Fluorouracil as an adjuvant to surgery in carcinoma of the colon. *Arch Surg* 1971;102:339-41.
- 4 Higgins GA, Humphrey E, Juler GL, *et al.* Adjuvant chemotherapy in the treatment of large bowel cancer. *Cancer* 1976;38:1461-7.
- 5 Kligerman MM, Urdaneta N, Knowlton A, *et al.* Pre-operative irradiation of rectosigmoid carcinoma, including its regional lymph nodes. *AJR* 1972;114:498-503.
- 6 Wang CC, Schultz MD. The role of radiation therapy in the management of carcinoma of the sigmoid, rectosigmoid and rectum. *Radiology* 1962;79:1-5.
- 7 Cedermark BJ, Schultz SS, Bashi S, *et al.* The value of liver scan in the follow-up of patients with adenocarcinoma of the colon and rectum. *Surg Gynecol Obstet* 1977;144:745-8.
- 8 Pestana C, Reitemeier RJ, Moertel CG, *et al.* The natural history of carcinoma of the colon and rectum. *Am J Surg* 1964;108:826-9.
- 9 Jaffe BM, Donegan WL, Watson F, *et al.* Factors influencing survival in patients with untreated hepatic metastases. *Surg Gynecol Obstet* 1968;127:1-11.
- 10 Bengmark S, Hafstrom L. The natural history of primary and secondary malignant tumours of the liver. 1. The prognosis for patients with hepatic metastases from colonic and rectal carcinoma by laparotomy. *Cancer* 1969;23:198-202.
- 11 Fisher ER, Turnbull RB. The cytologic demonstration and significance of tumour cells in the mesenteric venous blood in patients with colorectal cancer. *Surg Gynecol Obstet* 1955;100:102-7.
- 12 Lamb G, Taylor I. Grey-scale ultrasound scanning of the liver in the pre-operative diagnosis of colorectal liver metastases. *Gut* 1980;21:A902-3.
- 13 Mooney B, West C, Taylor I. Can the subsequent development of colorectal liver metastases be predicted? *Gut* 1980;21:A903.
- 14 Breedis C, Young G. Blood supply of neoplasms in the liver. *Am J Pathol* 1954;30:969-85.
- 15 Healey JE. Vascular patterns in human metastatic liver tumours. *Surg Gynecol Obstet* 1965;120:1187-93.
- 16 Lien WM, Ackerman NB. The blood supply of experimental liver metastases. *Surgery* 1970;68:334-40.
- 17 Gelin L, Lewis DH, Nilsson L. Liver blood flow in man during abdominal surgery. *Acta Hepatosplenologica (Stuttgart)* 1968;15:13-20.
- 18 Taylor I, Bennett R, Sherriff S. The blood supply of colorectal liver metastases. *Br J Cancer* 1979;39:749-56.
- 19 Mooney B, Shields R, Taylor A, Taylor I. Vasopressin and liver blood flow: an experimental dose response study. *Br J Surg* 1980;67:831 (abs.).
- 20 Fortner JG, Kim KD, MacLean BJ, *et al.* Major hepatic resection for neoplasia: personal experience in 108 patients. *Ann Surg* 1978;188:363-70.
- 21 Wilson SM, Adson MA. Surgical treatment of hepatic metastases from colorectal cancer. *Arch Surg* 1976;111:330-3.

- 22 Adson MA, Van Heerden JA. Major hepatic resections for metastatic colorectal cancer. *Ann Surg* 1980;191:576-83.
- 23 Brennan MJ, Talley RW, Drake EH, *et al.* 5-Fluorouracil treatment of liver metastases by continuous hepatic artery infusion via Cournard catheter. Results and suitability for intensive post-surgical adjuvant chemotherapy. *Ann Surg* 1963;158:405-17.
- 24 Ariel IM, Pack GT. Intra-arterial chemotherapy for cancer metastases to liver. *Ann Surg* 1965;91:851-61.
- 25 Ansfield FJ, Ramirez G, Skibba JL, *et al.* Intra-hepatic arterial infusion with 5FU. *Cancer* 1971;28:1147-51.
- 26 Fortner JG, Mulcare RJ, Solis A, *et al.* Treatment of primary and secondary liver cancer by hepatic artery ligation and infusion chemotherapy. *Ann Surg* 1973;178:162-72.
- 27 Gulesserian HP, Lawton RL, Condon RE. Hepatic artery ligation and cytotoxic infusion of liver metastases. *Arch Surg* 1972;105:280-5.
- 28 Grady ED. Internal radiation therapy of hepatic cancer. *Dis Colon Rectum* 1979;22:371-5.
- 29 Ariel IM, Padula G. Treatment of symptomatic metastatic cancer to the liver from primary colon and rectal cancer by the intra-arterial administration of chemotherapy and radioactive isotopes. *J Surg Oncol* 1978;10:327-36.
- 30 Almersjo O, Bengmark S, Rudanstam CM, *et al.* Evaluation of hepatic dearterialization in primary and secondary cancer of the liver. *Am J Surg* 1972;124:5-9.
- 31 Taylor I. Cytotoxic perfusion for colorectal liver metastases. *Br J Surg* 1978;65:109-14.
- 32 Michels NA. Collateral arterial pathways to the liver after ligation of the hepatic artery and removal of the coeliac axis. *Cancer* 1953;6:708-14.
- 33 Murray-Lyon IM, Dawson JL, Parsons VA, *et al.* Treatment of secondary hepatic tumours by ligation of hepatic artery and infusion of cytotoxic drugs. *Lancet* 1970;2:172-5.
- 34 Allison DJ. Therapeutic embolization. *Br J Hosp Med* 1978;20:707-14.
- 35 Taylor I, Dockray GJ, Lamb G. Hepatic artery ligation and embolization for the carcinoid syndrome: report of intra-operative liver blood flow studies in a case with high substance P concentration in liver metastases. *Clin Oncol* 1980;6:277-84.
- 36 Taylor I, West CR, Rowling J. Adjuvant liver perfusion for colorectal cancer. *Br J Surg* 1979;66:833-7.