

Primary torsion of the omentum

Susan E Basson FRCS

Senior House Officer, Wycombe General Hospital, High Wycombe, Bucks*

Peter A Jones FRCS

Lecturer in Surgery, St George's Hospital, London SW17

Key words: OMENTUM; TORSION

Summary

Primary torsion of the omentum is an uncommon cause of acute abdominal emergency. Five cases are reported and the English-language literature reviewed.

Introduction

Torsion of an intra-abdominal organ is a twisting of all or part of the structure upon itself with the formation of a narrow neck. Clinical presentation normally depends on coincident circulatory embarrassment eventually leading to infarction.

Torsion of the greater omentum may be primary or secondary, the latter being far more common. Infarction of the omentum may also occur in the absence of torsion and may therefore be classified thus:

- 1) With torsion:
 - a) primary (no underlying pathology),
 - b) secondary (for example, adhesions, inflammation, tumour, or external herniation).
- 2) Without torsion:
 - a) primary idiopathic segmental infarction,
 - b) segmental infarction due to systemic disease (for example, vasculitis, polycythaemia, or multiple emboli).

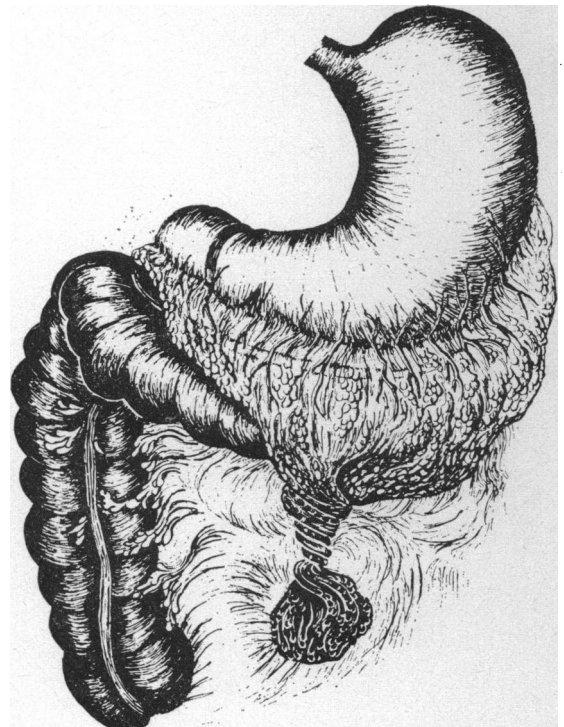
We present 5 cases of segmental infarction of the greater omentum due to primary torsion and review the literature.

Case reports

1) A 30-year-old businessman was admitted to hospital with a 5-day history of increasingly severe, constant pain in the right iliac fossa. He had no other symptoms and there was no relevant past history. He was moderately obese and had a temperature of 37.3°C with a pulse rate of 100/min. There was well-localised, marked tenderness and release tenderness in the right iliac fossa. The white cell count was $14.2 \times 10^9/l$ ($14.2 \times 10^3/mm^3$) and a preoperative diagnosis of acute appendicitis was made. Through a gridiron incision free serosanguineous fluid was found. A retrocaecal appendix was not inflamed.

A mass of indurated omentum 7 cm \times 5 cm was found adherent to the anterior abdominal wall in the region of the umbilicus. It was infarcted by torsion through three complete turns upon itself (see figure). The infarcted tissue was resected and the appendix removed. The patient made an uneventful post-operative recovery.

2) A 20-year-old student was admitted to hospital with a 24-h history of sudden abdominal pain starting in the periumbilical region and later shifting to the right iliac fossa. There were no other symptoms and no relevant past history. The patient was afebrile with a pulse rate of 96/min. There was tenderness, release tenderness, and guarding in the right iliac fossa. A full blood count was normal. A preoperative diagnosis of acute appendicitis was made. At operation through a Lanz incision a small amount



Drawing of omental torsion in Case 1

*Present appointment: Surgical Registrar, Mayday Hospital, Croydon, Surrey

of free serosanguineous fluid was found. The appendix was normal. A portion of omentum 6 cm × 4 cm was found to have undergone torsion and infarcted. The infarcted omentum and the appendix were resected, the patient making an uneventful recovery.

3) A 48-year-old company director presented with a 48-h history of constant pain in the right iliac fossa associated with slight nausea. There were no other symptoms and no relevant past history. He was afebrile and his pulse rate was 84/min. There was tenderness, release tenderness, and guarding in the right iliac fossa. A full blood count was normal and again a preoperative diagnosis of acute appendicitis was made. Through a gridiron incision a small amount of serosanguineous fluid was found. The appendix was normal. A mass 5 cm × 6 cm adherent to the anterior abdominal wall was found to be omentum which had undergone torsion and subsequent infarction. This was excised and appendectomy performed, the patient making an uneventful recovery.

4) A 48-year-old accountant presented with a 2-day history of increasingly severe, constant pain in the right iliac fossa. The pain had started after a violent cough and was aggravated by movement. There were no other symptoms and no relevant past history. He was slightly overweight, with a temperature of 37.3°C and a pulse rate of 76/min. There was well-localised tenderness over McBurney's point. No investigations were performed as a firm diagnosis of acute appendicitis was made. Through a gridiron incision a small amount of blood-stained fluid was noted. The appendix was normal, but a portion of omentum 4 cm × 3 cm had undergone torsion upon itself and infarcted. The infarcted omentum and the appendix were removed. The postoperative course was uneventful.

5) A 43-year-old van driver was admitted with a 19-h history of constant pain in the right iliac fossa associated with anorexia and mild nausea. There were no other symptoms and no significant past history. He was afebrile and his pulse rate was 80/min. There was marked tenderness and guarding on the right side of the abdomen. A full blood count was normal. Acute appendicitis was diagnosed. Through a gridiron incision free blood-stained fluid was found together with primary omental torsion. The black omentum, measuring 15 cm × 12 cm, was excised and a normal appendix was also removed. The postoperative course was uneventful.

Histological examination confirmed infarcted omentum in all cases.

Discussion

Primary torsion of the omentum was first described by Eitel in 1899 (1). It is a rare condition which typically presents to the surgeon as acute abdominal pain (2). A complete review of

the English-language literature revealed a total of 218 reported cases of well-defined primary torsion (2-21) (cases in which no distinction between idiopathic infarction and infarction secondary to torsion was made being excluded). All age groups were affected, but it occurred most commonly in the third and fourth decades. There were 122 male patients and 80 female, giving a male predominance of 3 : 2; in 16 cases the sex was not specified.

The most frequent presentation was with pain in the right iliac fossa and tenderness, often exquisite, localised to the same region, where a mass might be felt; in 94% of the cases reviewed by Mainzer and Simoes (3) the pain was eventually localised to the right side of the abdomen. With our 5 cases included, 166 out of a total of 223 were initially diagnosed as acute appendicitis. In the remaining 57 cases many other diagnoses were mistakenly made before operation, acute cholecystitis, chronic appendicitis, and appendix abscess being the next most frequent; others included perforated peptic ulcer, sigmoid volvulus, acute hydronephrosis, torsion of an ovarian cyst, and mesenteric adenitis, while in 16 cases no diagnosis was attempted. Indeed, the diagnosis was correctly made before operation in only one case. The absence or minimal degree of systemic upset and a longer history favours the diagnosis of omental torsion (2,5), but the definitive diagnosis must be made at operation. The presence of serosanguineous fluid, a normal appendix, and an indurated mass adherent to the anterior abdominal wall are the usual findings. The treatment is simple excision with incidental appendectomy.

Various theories have been suggested regarding the pathogenesis of primary omental torsion, but none can be applied to all cases. Eitel (1) originally attributed the cause to a combination of physical exertion and pressure maintained against the abdominal wall. His patient, a miner, regularly carried a heavy box, always taking the weight of the load against the same point on his abdominal wall. (After the operation he used a wheelbarrow!) Various anatomical factors may be involved. Bifid and accessory omenta have been demonstrated and free, tongue-like projections of omentum have also been incriminated. This last was clearly a factor in 3 of our cases and probably in the remaining 2. Obesity is frequently stressed (15,19,22) but was present in only 12% of cases in the largest review by Mainzer and Simoes (3). Two of our patients were noted to be overweight.

More improbably a relative venous redundancy in relation to the arterial supply, supposedly leading to venous engorgement, kinking of the omental veins, and subsequent precipitation

of torsion of the omentum, was proposed by Payr (23). He failed, however, to demonstrate experimentally that torsion could be induced by altering the specific gravity at a free point of omentum.

Precipitating factors include trauma, overexertion, sudden changes in body position, and overeating. It has been suggested that this last leads to hyperperistalsis and an increase in passive movement of the omentum (24). One interesting aspect of the aetiology is the predominance of right-sided torsions. It has been proposed that this reflects the larger size of the right side of the omentum and hence its greater redundancy, making it more liable to undergo torsion than the left side (24). Although this anatomical fact may well be the reason, we suggest that the important differential diagnosis of acute appendicitis renders it imperative to operate on those with right-sided signs. In contrast, left-sided primary omental torsion would probably be diagnosed as acute diverticulitis and managed conservatively. The natural history of autoamputation of the infarcted tissue would be compatible with resolution in some patients on conservative treatment; left-sided torsions may be seldom seen because they are not operated on and therefore not diagnosed.

We thank Mr J A Dormandy, Mr P H Lord, Mr J Grogono, and Mr F I Tovey for allowing us to report their patients and the Department of Educational Technology, St George's Hospital Medical School, for drawing the figure.

References

- 1 Eitel GG. Rare omental torsion. *New York Medical Record* 1899;55:715-6.
- 2 Brodribb AJM. Primary idiopathic omental torsion: a report of 2 cases. *Br J Surg* 1974;61:305-6.
- 3 Mainzer RA, Simoes A. Primary idiopathic torsion of the omentum: review of the literature and report of six cases. *Arch Surg* 1964;88:974-81.
- 4 DeRosario JL. Spontaneous torsion of the omentum. *Can Med Assoc J* 1965;92:1180-1.
- 5 Fahlund GTR, Smedley WP. Primary torsion of the greater omentum: report of four cases. *Am Surg* 1965;31:285-8.
- 6 Tompkins RK, Sparks FC. Primary torsion of the omentum: mimic of appendicitis. *Am Surg* 1966;32:399-402.
- 7 Martorell RA. Idiopathic torsion and infarction of the omentum. *Am Surg* 1968;34:252-5.
- 8 Spitz I, Pantanowitz D, Thaning O. Primary torsion of the omentum: a report of four cases and review of the literature. *S Afr J Surg* 1970;8:49-52.
- 9 Malek F, Riley EJ. Primary torsion and segmental infarction of greater omentum. *Am Surg* 1970;36:549-51.
- 10 Chudgar RG, Pai AM, Velankar KH. Acute torsion of the greater omentum: a case report. *J Postgrad Med* 1971;17:193-4.
- 11 Brown HJ, Noone RB. Primary omental torsion. *J Okla State Med Assoc* 1971;64:177-80.
- 12 Todd DW. Infarction of the omentum. *Milit Med* 1971;136:37-8.
- 13 Grover NK, Taneja OP, Gulati SM. Acute abdomen caused by primary torsion of the greater omentum. *Int Surg* 1972;57:587-8.
- 14 Wijthoff SJM. Primary torsion and primary infarction of the greater omentum. *Arch Chir Neerl* 1972;24:297-302.
- 15 Adams JT. Primary torsion of the omentum. *Am J Surg* 1973;126:102-5.
- 16 Barcia PJ, Nelson TG. Primary segmental infarction of the omentum with and without torsion. *Am J Surg* 1973;126:328-31.
- 17 Beltz DE, Weisbrod LW. Segmental infarction of the greater omentum. *Wis Med J* 1974;73:74-5.
- 18 Freed JS, Edelman S. Primary torsion of the greater omentum mimicking duodenal ulcer. *Am J Gastroenterol* 1976;66:386-9.
- 19 Appelqvist P. Primary torsion of the whole greater omentum: a case report and review of the literature. *Acta Chir Scand* 1976;142:91-3.
- 20 Rabau MY, Wolfstein I, Tulchinsky D. Omental torsion. *Med Chir Dig* 1976;5:353-5.
- 21 Maclean DA. Primary torsion of the omentum in children. *J R Coll Surg Edinb* 1977;22:430-2.
- 22 Schnur PL, McIlrath DC, Carney JA, *et al*. Segmental infarction of the greater omentum. *Mayo Clin Proc* 1972;47:751-5.
- 23 Payr E. Weitere experimentelle und klinische Beiträge zur Frage der Stieldrehung intraperitonealer Organe und Geschwulste. *Deutsche Zeitschrift für Chirurgie* 1906;85:392-415.
- 24 Lipsett PJ. Torsion of the greater omentum: report of 2 cases. *Ann Surg* 1941;114:1026-34.