

J. Young, Dr D. J. Beale and Dr A. Vickers and Mr Ian Malcomson.

References

- ALBRIGHT, F., FORBES, A.P. & HENNEMAN, P.H. (1952) Pseudo-pseudo hypoparathyroidism. *Transactions of the Association of American Physicians*, **65**, 337.
- DUDLEY, A.W. & HAWKINS, H. (1970) Mineralisation of the central nervous system in pseudo-pseudo hypopara-

thyroidism. *Journal of Neurology, Neurosurgery and Psychiatry*, **33**, 147.

- MATHEWS, W.B. (1957) Familial calcification of the basal ganglia with response to parathormone. *Journal of Neurology, Neurosurgery and Psychiatry*, **20**, 172.
- MOSKOWITZ, M.A., WINICKOFF, R.N. & HEINZ, R.E. (1971) Familial calcification of the basal ganglia. *New England Journal of Medicine*, **8**, 72.
- ROBERTS, P.D. (1959) Familial calcification of the cerebral basal ganglia and its relation to hypoparathyroidism. *Brain*, **82**, 599.

Postgraduate Medical Journal (October 1972) **48**, 639-642.

Slow recovery from carbon monoxide poisoning

D. F. ABBOTT
M.B., M.R.C.P.

Addenbrooke's Hospital, Cambridge

Summary

A case of accidental carbon monoxide poisoning due to the incomplete combustion of natural gas is reported. The patient had prolonged coma and decerebrate rigidity, but eventual recovery of neurological and intellectual function was almost complete.

Introduction

Poisoning with carbon monoxide as a result of accidental or suicidal exposure to coal gas is a frequent occurrence. In 1963 there were 1193 deaths due to accidental poisoning (Registrar General's Statistics). Since that time there has been a fall in the incidence of coal gas poisoning, so that in 1969 there were 316 deaths. This is partly due to the use of natural gas (*British Medical Journal*, 1970). Natural gas consists of methane and minor proportions of other gases and is non-toxic. However, its use may lead to carbon monoxide poisoning as a result of incomplete combustion (Report of the Inquiry into the Safety of Natural Gas as a Fuel). There has been a report of such a case in this neighbourhood (Anderson, 1970).

Carbon monoxide poisoning may result in diverse neurological and psychiatric features. The incidence of different syndromes varies from series to series. A recent report of 138 patients (Smith & Brandon, 1970) showed prolonged delirium in 20%, pyramidal signs in 19.6% and extra-pyramidal signs in 2.5%. There were no cases of decerebrate rigidity. Five patients (3.8%) developed permanent defects, of which two had dementia alone, one had dementia with Parkinsonism, and two patients had spastic hemiplegia which may have preceded exposure.

Present address: Geriatric Unit, Whittington Hospital and University College Hospital, 4 St Pancras Way, London, N.W.1.

In a series of 290 cases of severe carbon monoxide poisoning from Paris (Bour, Pasquier & Bertrand-Hardy, 1966), 33.7% developed decerebrate rigidity. The usual duration of rigidity was a few hours. The average duration of coma in their series was 16 hr and in only two patients did it exceed 24 hr. One patient was in coma for 4 days and another for 5 days. Six patients had residual neurological manifestations and twenty-three had residual psychiatric syndromes.

Case report

The patient was an 18-year-old undergraduate. He was found lying deeply comatose on the floor of his room on the first day of the Lent term, 1971. Another undergraduate in the room was found to be dead and had not been seen for the preceding 24 hr.

On arrival at Addenbrooke's Hospital the patient was stuporous but responded to painful stimuli and turned his head in response to his name being called. Deep tendon reflexes were symmetrically very brisk; both plantar reflexes were equivocal. There was marked rapid eye movement. The pupils were of normal size and reacted briskly to light. The fundi were normal. There was no neck stiffness.

There was a tachypnoea of 34/min, BP 120/90 mmHg, pulse 110/min regular, good volume. Both hands were cyanosed but there was no cyanosis elsewhere and no evidence of abnormal pinkness. There were blisters on the left thigh and the buttocks had signs of early epidermal necrolysis (Fig. 1). There was no evidence of intravenous injections. The patient's clothing was covered in vomit.

There was a strong suspicion that drugs had been used and drug overdose was initially considered to be the most likely possibility.

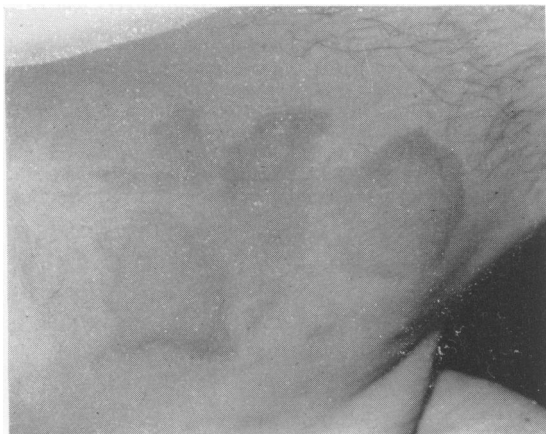

FIG. 1.

The following investigations were performed: Blood urea 62 mg/100 ml; sodium 137 mEq/l; bicarbonate 10 mEq/l. Glucose 100 mg/100 ml. Barbiturates and salicylates were not present in the blood. Arterial blood gas analysis—pH 7.33; PCO_2 22 mmHg; standard bicarbonate 15 mEq/l; base excess 13 mEq/l; oxygen saturation 94%. The arterial and the venous blood used for these estimations was of normal colour. The urine was screened for noxious substances in the hospital laboratory and at Guy's Hospital Poisons Reference Bureau. No abnormality was found.

The patient was observed overnight and given intermittent 28% oxygen. Fifteen hours after his

removal from the room where he had been found he showed no signs of recovery. He was more deeply comatose and no longer responded to painful stimuli or to noise. There was generalized muscular rigidity, with episodes of facial spasm associated with flexion of his upper limbs and extension of both lower limbs. His pupils became very dilated but still responded briskly to light. He was incontinent of urine.

On doing a further venesection the blood was noted to be cherry-red in colour.

In the meantime, further information concerning the circumstances in which the patient had been found became available. His room was without ventilation, all the windows were closed and the gas fire was fully on.

At the necropsy of the deceased man the cause of death was shown to be carbon monoxide poisoning. It was considered that the patient was also poisoned with carbon monoxide and he was therefore transferred to a hyperbaric oxygen chamber 16 hr after admission. The original blood sample, which had been taken 4 hr after the patient had been discovered, was reported as having 20% carboxyhaemoglobin when analysed chemically.

It therefore appeared that the patient had developed decerebrate rigidity as a result of carbon monoxide poisoning. He had not improved with hyperbaric oxygen at 22 lb/sq in. for 3 hr and this treatment was therefore discontinued, but he continued to receive 95% oxygen by face mask. Dexamethazone 10 mg was given followed by 4 mg daily with the object of reducing cerebral oedema. Diazepam 10 mg every 4 hr was used for the recurrent spasm. Both drugs were given intramuscularly. Prophylactic chest and limb physiotherapy was given.

After 2 days he developed a urinary tract infection and the following day showed signs of bronchopneumonia. He was treated by physiotherapy and trimethoprim and sulphamethoxazole. Later cloxacillin and ampicillin were used, as indicated by sensitivity tests.

At this stage the chances of complete recovery were considered to be minimal. For 6 days he remained comatose and in a state of decerebrate rigidity with recurrent muscle spasms associated with bouts of hyperpnoea.

After 140 hr he opened his eyes in response to a noise. This was the first evidence of any improvement. On the seventh day an EEG showed dominant generalized delta wave activity down to 1 cycle/sec, which was symmetrical and more marked in the anterior than the posterior regions.

On the eighth day his eyes were open for much of the time, and occasionally they were turned towards activity in the ward, but he remained quite mute and showed no evidence of comprehension of speech or

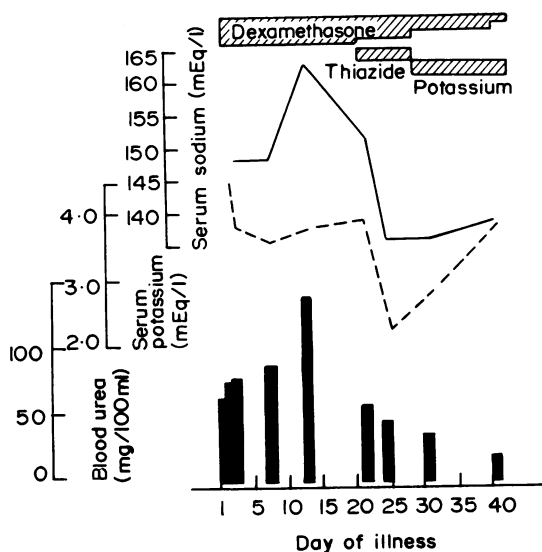


FIG. 2.

actions. There was generalized gross muscle weakness with increased tonus. Occasional spasms continued. During this period he was fed intravenously and later via a naso-gastric tube. He received intensive physiotherapy and dexamethazone was continued at 4 mg a day for 19 days before being gradually withdrawn.

Sixteen days after admission it became possible to communicate with the patient, who was taught to use a code of blinking in reply to questions; one blink signifying an answer of 'Yes' and two blinks signifying an answer of 'No'. In this way the patient was able to make some of his wishes known, but he became exhausted after answering two or three questions. He lapsed into stupor on many occasions and Cheyne-Stokes respirations were observed. On the seventeenth day he had recovered slight power in both arms. On the twenty-third day, in response to the question 'Who are you?' the patient spelt out his name on an alphabet board. Following this he made a rapid and sustained recovery. On the twenty-fifth day he spoke a few words and from then on his power of speech gradually returned.

EEG was repeated on the thirty-first day and the record had improved markedly. The slow activity had been replaced by alpha activity with amplitudes up to 50 μ V. There was a small amount of 4-7 cycles/sec activity slightly more marked on the left than the right.

Lumbar puncture was performed on the thirty-fourth day. Clear fluid at 100 mm pressure was found. There was free rise and fall. CSF: glucose 62 mg/100 ml; protein 30 mg/100 ml; polymorphs 7 cells/mm³; red cells 26/mm³; colloidal gold normal, WR and VDRL negative.

By the thirty-eighth day the patient could hold a reasonable conversation.

On the forty-eighth day the Wexler Adult Intelligence Scale (WAIS) was administered. He was found to have a verbal IQ of 107 and a performance IQ of 91.

He continued to exhibit loss of muscle power in all four limbs, more marked in the right upper and lower limbs with mainly proximal weakness. All deep reflexes were still symmetrically brisk; both plantars were equivocal. There was a marked tremor of the left hand which was worse on movement.

The patient initially had retrograde amnesia for 12 days but later the period shortened to 1 day. He had a post-incident amnesia of 4 weeks.

On the sixty-second day he had a grand mal fit which occurred whilst watching television and just after having drunk a quarter of a bottle of wine which he had had smuggled into hospital. Following this his right plantar was found to be extensor but there were no other new neurological signs. The EEG was unchanged. He was treated with pheno-

barbitone 30 mg twice daily and did not have further fits.

The patient was discharged from hospital 71 days after admission and continued to attend the physiotherapy and occupational therapy departments. At 84 days the patient considered that he was entirely normal. However, his mother had noted loss of concentration and less social tolerance than before the incident. There remained slight impairment of rapidly alternating movements in both upper limbs and symmetrical hyperreflexia in both upper and lower limbs. There was impaired touch sensation of the right great toe and the left metatarsophalangeal region. Proprioception was decreased on the right. The plantar reflexes were normal and there were no other central nervous system abnormalities.

Psychometry was performed again 130 days after the incident. Using the same WAIS subtests as previously he was found to have a verbal IQ of 130 and a performance IQ of 123. These values are comparable with other university students. The only previous intelligence test he had taken was at the time of the 11+ examination when using National Foundation of Educational Research tests he was found to have verbal quotients of 130 and 139, an arithmetic quotient of 136 and English quotient of 122.

The patient was able to return to his studies in October 1971.

Discussion

An examination of the patient's room and gas fire had been made shortly after his admission. The flue of the gas fire was blocked by fallen flue lining (pargeting). All the windows were closed and the only ventilation was a small gap beneath the door. There was evidence that the fire had burnt continuously for 25 hr and that the patient and the deceased man had been in the room all that time.

The fire was subsequently burnt under the same conditions and the carbon monoxide in the room was sampled at 10-min intervals for 40 min. After this time the concentration was 0.030% but the experiment was not continued for longer. After burning for 25 hr it is calculated that a concentration of greater than 1% would have been reached, which would have resulted in a carboxyhaemoglobin level of over 70% (von Oettingen, 1944). This level may cause unconsciousness, respiratory failure and death if exposure is prolonged (Henderson & Haggard, 1943).

The reported carboxyhaemoglobin level of 20% is not high, but was on blood taken 4 hr after leaving the atmosphere, during some of which time the patient had received oxygen. The biochemical abnormalities during the early stages of treatment are shown in Fig. 2.

It is suggested that as very slow recovery occurred, treatment of severe carbon monoxide poisoning in young patients should be optimistic. It is also suggested that more rigorous efforts should be made to ensure the patency of the flues of gas burning appliances by regular inspection.

Acknowledgments

I am grateful to Dr A. P. Dick for permission to publish this case, and to Dr G. A. Gresham for his assistance, and to Mr M. V. Durrell, City Coroner, for permission to examine the evidence given at the inquest of the deceased undergraduate, and to Miss H. P. Middleton for secretarial assistance.

References

- ANDERSON, T.B. (1970). Letter to Editor *Lancet*, i, 466.
- BOUR, H., PASQUIER, P. & BERTRAND-HARDY, J-M. (1966) Le coma oxycarboné. Etude général, clinique, biologique et thérapeutique de 290 Cas. *Semaine des Hôpitaux de Paris* 42, 1839.
- BRITISH MEDICAL JOURNAL (1970) Editorial. 3, 180.
- HENDERSON, Y. & HAGGARD, H.W. (1943) *Chemical Asphyxiants in Noxious Gases and the Principles of Respiration Influencing their Action*, 2nd edn, p. 168. Reinhold Publishing Corporation, New York.
- Report of the Inquiry into the Safety of Natural Gas as a Fuel (1970) Ministry of Technology, H.M.S.O.
- SMITH, J.S. & BRANDON, S. (1970) Acute carbon monoxide poisoning—3 years' experience in a defined population. *Postgraduate Medical Journal*, 46, 65.
- VON OETTINGEN, W.F. (1944) *Bulletin* 290. U.S. Public Health Service, Washington D.C. U.S. Government Printing Office.