

Pathology of primary cardiomyopathies

ECKHARDT G. J. OLSEN

I WOULD like to discuss the pathological aspects of primary cardiomyopathies, with emphasis on diagnosis, in the following order:

- (1) Congestive cardiomyopathy (systolic pump failure).
- (2) Hypertrophic cardiomyopathy, with or without obstruction (diastolic compliance failure).
- (3) Obliterative cardiomyopathy.

Congestive cardiomyopathy

The hearts are usually hypertrophic and all chambers are dilated, often to a severe degree. Conventional measurements of ventricular wall thickness may fall within the normal range, due to dilatation masking the severe degree of hypertrophy which may be present. Endocardial thickening may be widespread and is of a non-specific variety, consisting of fibro-elastic tissue. Thrombus may be superimposed which can reduce the ventricular cavity size.

Careful examination of the left ventricular wall will frequently show some fibrous replacement of myocardial muscle limited to the inner third of the myocardium. These changes are best seen in the left ventricle, but they may also be observed in the right ventricle where they are less severe (Fig. 1).

Histology

Light microscopic examination shows a uniform picture. The normal architecture is preserved. The myocardial fibres from either ventricle or atrium, although hypertrophied, are usually attenuated as a result of dilatation, and measurements of the myocardial fibre diameters fall within normal range (5–12 μm). The myocardial fibres which show the greatest attenuation lie close to the endocardium; towards the epicardium the fibres are usually thicker. The nuclear changes of hypertrophy are present which, if thinning of myocardial fibres is evident, suggests that hypertrophy is present (Fig. 2a).

Fine fibrous replacement of only part of myocardial fibres is occasionally present, and two to three fibres may run into small foci of fibrosis. This is frequently seen in cases suffering from congestive cardiomyopathy, but it is by no means pathognomonic. This fine fibrous replacement may be scattered throughout the myocardium and differs in degree from the larger areas of fibrous replacement confined to the inner third of the myocardium,

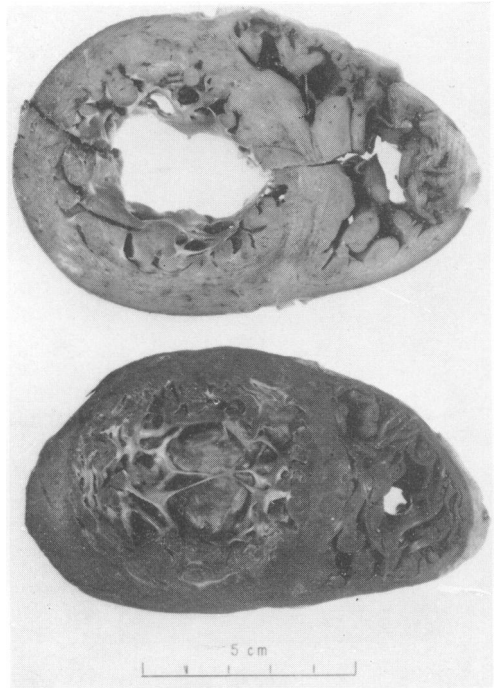

FIG. 1. Cross-section of a heart of a patient suffering from congestive cardiomyopathy. Note the dilatation of both ventricles and some patchy fibrous replacement particularly in the inner third of the left ventricle. In the lower section thrombus can be seen overlying the apex.

which can easily be seen macroscopically. Foci of chronic inflammatory cells may sometimes be seen. The small myocardial blood vessels have been normal in all the material personally examined.

Extensive *histochemical* examination has been undertaken in collaboration with my colleagues Susan Van Noorden and A. G. E. Pearse. No specific features have been found and the increased activity of the various enzyme systems which has been observed reflects hypertrophy of the myocardial fibres.

Ultrastructural changes also show the appearance of ordinary hypertrophy with an increase in mitochondria. The cristae in some of these subjects show alteration of the normal arrangement and occasional mitochondrial 'ghosts' are seen. There is a moderate increase of lipofuscin granules and accumulation of glycogen.

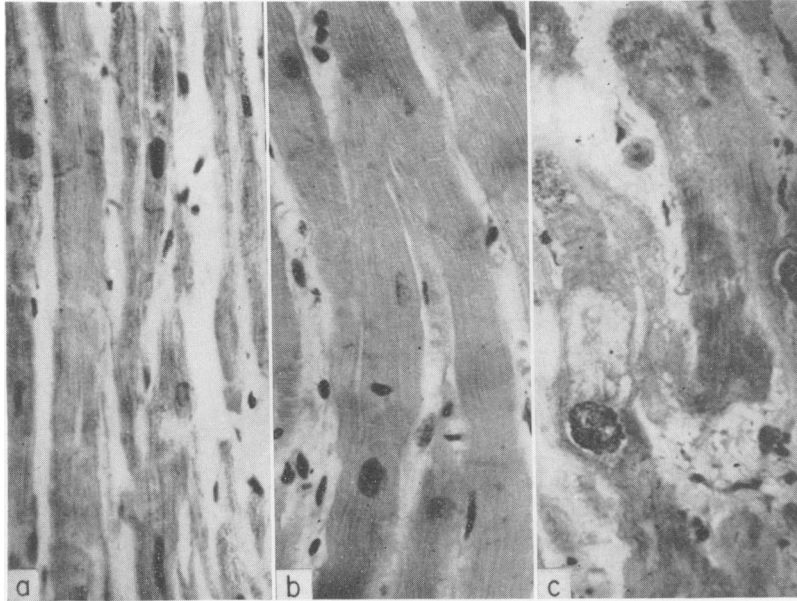


FIG. 2. Photomicrograph to compare hypertrophy of myocardial fibres. (a) Congestive cardiomyopathy. Note the long runs of attenuated myocardial fibres and the nuclear changes of hypertrophy. (b) Myocardial hypertrophy due to aortic valve stenosis. Note the long runs of regular, hypertrophied fibres and the absence of a perinuclear halo. (c) Hypertrophic cardiomyopathy with obstruction. Note the extreme hypertrophy, bizarre-shaped nuclei, a perinuclear halo surrounding one of the nuclei, dystrophic myocardial fibrils and apparent interruption of myocardial fibres by fibrous tissue. All sections were taken from the interventricular septum at the same magnification. H & E, $\times 330$.

Aetiology

The aetiology of congestive cardiomyopathy, which enjoys a large number of synonyms (Cockshott, Thorpe & Ikeme, 1967), is unknown. Various theories have been proposed.

(1) Viral theory. A variety of viruses have been identified but definite proof is still lacking (Gardner *et al.*, 1967; Fletcher & Wenger, 1968).

(2) A deficiency in succinic dehydrogenase has been suggested (Kobernick *et al.*, 1963). In our own experience an increase has been consistently observed.

(3) Arteriopathy of the small vessels has been proposed (James, 1964).

(4) An infective agent has been suggested (Baimbridge *et al.*, 1967) but appearances observed by these workers have been variously explained as being due to toxic effects or artefact (Grist, 1967; Van Noorden *et al.*, 1971).

Hypertrophic cardiomyopathy with or without obstruction (diastolic compliance failure)

When patients with this disease come to necropsy, the striking abnormality in the heart is the asym-

metric hypertrophy of the interventricular septum. Attention was drawn to this asymmetric hypertrophy by Professor Donald Teare (1958). An abnormally placed anterior mitral valve leaflet has been described (Björk *et al.*, 1961; Björk, 1964) but in our experience this has not been observed (Fig. 3), although the anterior leaflet and, to a certain extent, the posterior leaflet, is occasionally thickened. This is a non-specific feature, collagen being superimposed on to the 'deformed face' of the mitral valve cusps. This is secondary to mitral incompetence which is frequently present.

The extent of the abnormal fibres can be assessed by studying numerous longitudinal sections of the heart. They usually extend from the region of the apex to the aortic valve (Fig. 4). The abnormal fibres may involve the posterior or anterior surfaces of the left ventricular cavity to a variable extent. On cross-section, the tremendous asymmetric hypertrophy of the ventricular septum is usually striking when one compares it with the thickness of the free wall of the left ventricle. The left ventricular cavity is usually small and the right cavity may be a narrow slit. Fibrous tissue, often arranged in

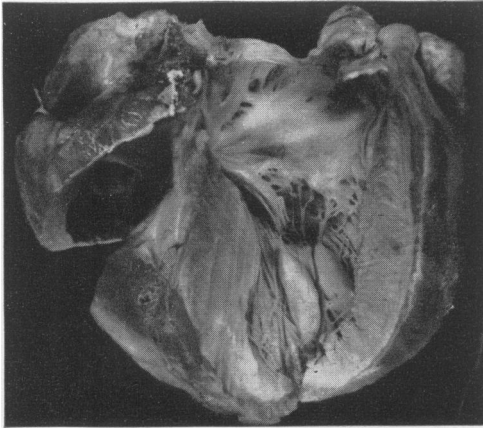


FIG. 3. Hypertrophic cardiomyopathy with obstruction. The left ventricle has been opened to show the asymmetric hypertrophy seen at the interventricular septum. Note the slight thickening of the anterior mitral valve cusp (secondary to mitral insufficiency). (With permission of the editors and publishers of *Cardiovascular Clinics*.)

whorls, can be seen in the thickened interventricular septum. The muscle most commonly involved is the deep bulbospiral muscle, and the overlying superficial bulbospiral and deep sinospiral muscle may become so thin that the abnormal muscle apparently extends to the ventricular cavities. Very occasionally the deep sinospiral muscle may be the only part involved.

Histology

The histological features are striking and in my opinion pathognomonic. In cases of hypertrophic cardiomyopathy with obstruction, the regular arrangement of the long runs of parallel muscle fibres is totally lost in the affected areas and the fibres run in all directions. In addition to this, one finds tremendous hypertrophy of individual myocardial fibres and values of 60–90 μm are common. The nuclei are extremely large and often bizarre in shape, containing large clumps of chromatin. The nuclei are often surrounded by a clear perinuclear halo. This must be distinguished from oedema of myocardial cells which may occasionally be responsible for the perinuclear spaces. The myocardial fibrils adjacent to these haloes disappear and have a moth-eaten appearance. There is also an increase in collagen tissue which surrounds individual myocardial fibres, and gives the appearance that these fibres are of a rather short length. Another feature, which we have found useful from a diagnostic point of view, is the so called whorl formation (Fig. 5). Marked fibrous replacement can occur in the affected areas but we have been

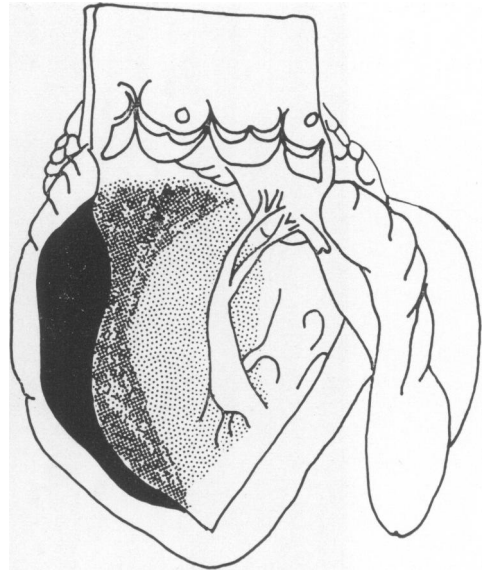


FIG. 4. Diagrammatic representation of the extent of abnormal fibres; the stippled effect has been employed to convey a three-dimensional picture.

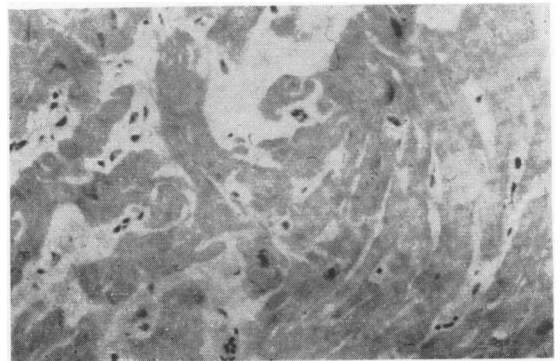


FIG. 5. From a patient with hypertrophic obstructive cardiomyopathy showing a small whorl of hypertrophied myocardial fibres. H & E, $\times 330$.

unable to relate these appearances to length of history. Quantitative estimation of collagen has never been more than 2% of the whole myocardial mass (Gvozdzjak, personal communication).

The histological appearances of congestive cardiomyopathy and hypertrophic cardiomyopathy with obstruction are summarized in Fig. 2, and compared with left ventricular hypertrophy due to aortic valve stenosis. The bundle of His in all these cases showed no abnormality. It has been suggested that there might be some abnormal connections or displacement of the left bundle fasciculi (Lunel, personal communication 1972).

Hypertrophic cardiomyopathy without obstruction

When the patients with obstruction lose the obstructive element clinically before death in the majority of cases, the 'bulge' is still observed at necropsy. Very occasionally the interventricular asymmetry may completely disappear. It is therefore essential that clinical information is available, as otherwise the pathologist may fail to look in the right area and a diagnosis may never be reached. Multiple cross-sections allow reconstruction of the arrangement of these abnormal fibres. They are in exactly the same position as in the cases which show the asymmetric hypertrophy prominently.

The aetiology is unknown. It has been suggested that the asymmetric hypertrophy may represent a rhabdomyoma or hamartoma. A congenital growth derangement was suggested by Schmincke as early as 1907. Noradrenosis has been suggested (Pearse, 1964) but subsequent work has shown that this fluorescence may not be specific for noradrenosis and may also occur in collagen tissue. It has also been suggested that the primary disorder might be one of myocardial muscle metabolism (Lannigan, 1965).

Professor Pearse, Miss Van Noorden and I have examined two groups of patients (Table 1). From each of the patients (who suffered from a variety of heart conditions in which myocardial hypertrophy may occur), biopsy material was obtained and was compared with biopsy material from twenty patients

TABLE 1. Patients used as controls and patients with hypertrophic cardiomyopathy with obstruction.

Clinical diagnosis	No. of patients
Group I	
Normal	5
Congestive cardiomyopathy	4
Cardiomyopathy of unknown type	4
Infective endocarditis	1
Hypertension (essential)	4
Tetralogy of Fallot	4
Ventricular septal defect	2
Mitral stenosis	3
Subaortic stenosis	13
Aortic valve stenosis	7
Total	47
Group II	
Hypertrophic cardiomyopathy with obstruction	20
Total number of patients' hearts examined	67

(With permission of the editors and publishers of *Cardiovascular Clinics.*)

suffering from hypertrophic cardiomyopathy with obstruction. The biopsy material was obtained at surgical operation which formed part of the patients' treatment. The material was examined histologically, histochemically and electron-microscopically. Histograms have been constructed to assess the diagnostic value of the various criteria which have been described above, and fibrosis, short interrupted fibres, large bizarre nuclei, perinuclear haloes, whorls and average fibre diameter, have been examined (Fig. 6).

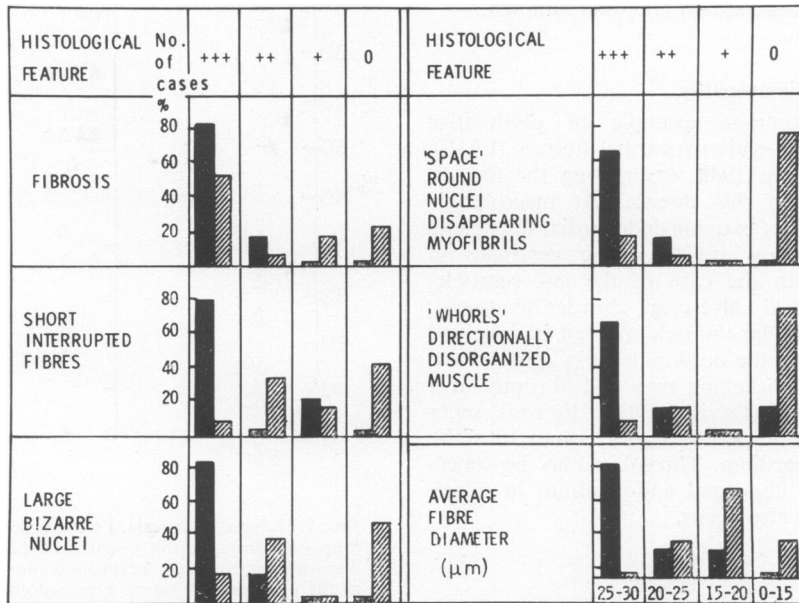


FIG. 6. Closed columns, patients suffering from hypertrophic obstructive cardiomyopathy; diagonally hatched columns, patients suffering from left ventricle hypertrophy due to organic obstruction.

Histochemical investigation has also been carried out and many enzyme systems have been examined. We found only glycogen of real diagnostic importance; there is a marked increase of glycogen, particularly in the perinuclear area and also to a certain extent between the fibrils.

Electron-microscopic examination was not helpful from a diagnostic point of view as the distribution of abnormal fibrils was patchy and no criterion was pathognomonic. Generally speaking, the changes seen ultrastructurally can be observed at light microscopic level.

We have also attempted to show the diagnostic appearances by a quantitative method and have awarded points to each biopsy according to the severity of the criteria present. In histological examination five criteria were used, in histochemical examination four criteria, and ultrastructurally seven criteria were used. The findings in a small number of patients show that a diagnosis at histochemical level can be made with a high degree of accuracy, but that at histochemical and ultrastructural level considerable overlap exists (Fig. 7). When we examined the histological criteria for the larger number of patients we found that even at histological level there was considerable overlap between the two groups of patients, and a few of these patients clinically diagnosed as hypertrophic cardiomyopathy with obstruction fall well below the 50% mark. The reason for this low index is commonly insufficient material or perhaps that a non-diseased area was sampled.

Obliterative cardiomyopathy

The most common example of obliterative cardiomyopathy is endomyocardial fibrosis (EMF). J. N. P. Davies in 1948 was among the first to draw attention to this disease. At macroscopic level this consists of extreme endocardial thickening involving the inflow tracts of the ventricles in particular, and in the case of the left ventricle, the posterior mitral valve cusp, chordae tendineae, and posterior papillary muscle may all be involved in this process. As the outflow tract is approached, the endocardial thickening may end abruptly in a thick, rolled edge (Davies, 1968). Fibrous septa extend from the thickened endocardium into the underlying myocardium. Thrombus may be superimposed on the abnormal endocardium in which calcification may also occur.

Histology

The thickened endocardium, in contrast to non-specific endocardial thickening, is arranged in zones. The superficial zone consists of hyalinized

collagen tissue in which foci of calcification may occur. The middle zone is composed of loose fibrous tissue and the deepest zone (nearest the myocardium) the so-called granulation tissue zone, consists of dilated vascular channels and inflammatory cells made up predominantly of lymphocytes or plasma cells. Eosinophils may also be seen in these areas (Fig. 8).

Conclusion

The diagnosis of congestive cardiomyopathy can only be made by exclusion of all other possible causes and there is no characteristic pathological appearance.

Hypertrophic cardiomyopathy with or without obstruction, has a characteristic histological appearance and can be diagnosed with a high degree of accuracy. Histochemical and ultrastructural investigations (with the exception of staining for glycogen) are not helpful in making the diagnosis. The patchy distribution within the affected myocardium makes interpretation of needle biopsy material very difficult.

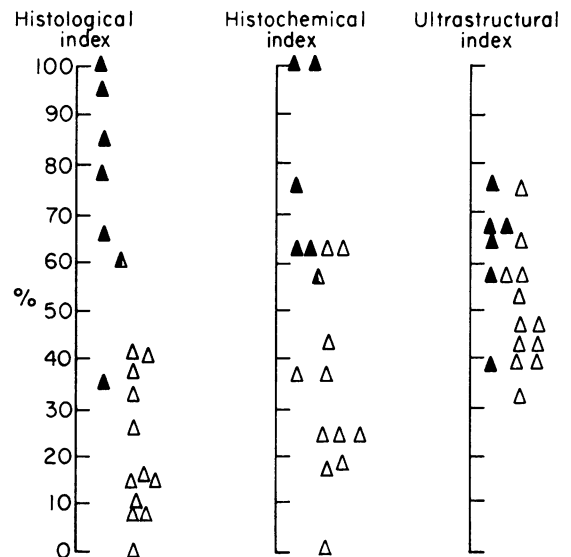


FIG. 7. Diagnostic criteria. Points were awarded to each biopsy according to the severity of the criteria examined. The total for each case is expressed above as a percentage of the possible maximum. Five histological, four histochemical, and seven ultrastructural criteria were used. ▲, Patients suffering from hypertrophic obstructive cardiomyopathy; △, patients suffering from left ventricular hypertrophy due to organic obstruction.

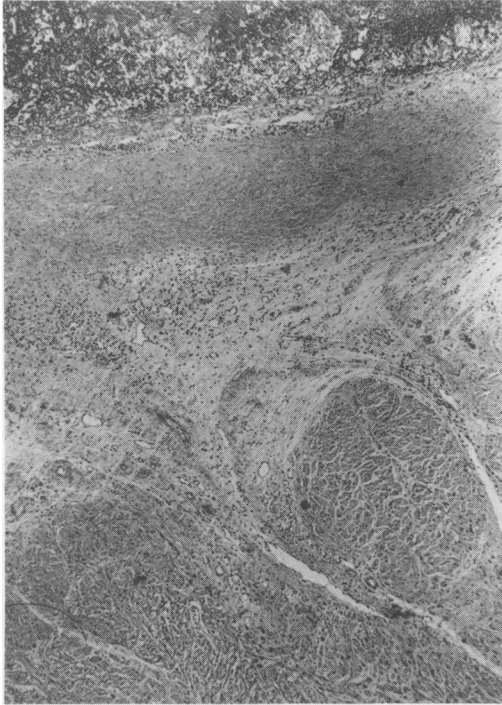


FIG. 8. Photomicrograph from a case of endomyocardial fibrosis. At the top recent thrombus can be seen above a layer of collagenous tissue. The zone above the myocardium shows the granulation tissue layer with inflammatory cells and dilated vessels. H & E, $\times 33$. (With permission of the editors and publishers of *Cardiovascular Clinics*.)

References

- BAIMBRIDGE, M.V., DARRACOTT, SALLY, CHAYEN, J., BITENSKY, LUCILLE & POULTER L.W. (1967) Possibility of a new infective aetiological agent in congestive cardiomyopathy. *Lancet*, **i**, 171.
- BJORK, V.O., HULTQUIST, G. & LODIN, H. (1961) Subaortic stenosis produced by an abnormally placed anterior mitral valve leaflet. *Journal of Thoracic Cardiovascular Surgery*, **41**, 659.
- BJORK, V.O. (1964) In: *Cardiomyopathies*, p. 127, Ciba Foundation Symposium. Churchill, London.
- COCKSHOTT, W.P., THORPE, G.J. & IKEME, A.C. (1967) Radiological aspect of heart muscle disease in Nigerian adults. *Circulation*, **36**, 460.
- DAVIES, J.N.P. (1948) Endocardial fibrosis in Africans. *East African Medical Journal*, **25**, 10.
- DAVIES, J.N.P. (1968) The ridge in endomyocardial fibrosis. *Lancet*, **i**, 631.
- FLETCHER, G.F. & WENGER, N.K. (1968) Auto-immune studies in patients with primary myocardial disease. *Circulation*, **37**, 1032.
- GARDNER, M.B., LEE, P.V., NORRIS, J.C., PHILLIPS, E. & CAPONEGRO, P. (1967) Virus-like particles in cardiac biopsy. *Lancet*, **ii**, 95.
- GRIST, N.R. (1967) Aetiology of congestive cardiomyopathy. *Lancet*, **ii**, 395.
- JAMES, T.N. (1964) An etiologic concept concerning the obscure cardiomyopathies. *Progress in Cardiovascular Diseases*, **7**, 43.
- KOBERNICK, S.D., MANDELL, G.M., FIRKIN, R.M. & HASHIMOTO, Y. (1963) Succinic dehydrogenase deficiency in idiopathic cardiomegaly. *American Journal of Pathology*, **43**, 661.
- LANNIGAN, R. (1965) Hypertrophic subaortic stenosis with myocardial fibre degeneration, 1965. *British Heart Journal*, **27**, 772.
- NOORDEN, VAN, SUSAN, OLSEN, E.G.J. & PEARSE, A.G.E. (1971) Hypertrophic obstructive cardiomyopathy, a histological, histochemical and ultrastructural study of biopsy material. *Cardiovascular Research*, **5**, 118.
- PEARSE, A.G.E. (1964) The histochemistry and electron-microscopy of obstructive cardiomyopathies In: *Cardiomyopathies*, p. 132, Ciba Foundation Symposium. Churchill, London.
- SCHMINCKE, A. (1907) Ueber linksseitige muskulose conusstenosen. *Deutsche medizinische Wochenschrift*, **33**, 2082.
- TEARE, D. (1958) Asymmetrical hypertrophy of the heart in young adults. *British Heart Journal*, **20**, 1.