

CASE REPORTS

Familial spontaneous pneumothorax

J. C. DELANEY*
M.B., Ch.B., M.R.C.P.

A. GALE
M.B., Ch.B.

B. A. WALKER
M.D., M.R.C.P.

Broadgreen Hospital, Liverpool

Summary

Familial spontaneous pneumothorax is a rare condition. Two families with this condition are described: identical twin sisters of one family and three brothers of another family. The suggestion is made that at least some cases of spontaneous pneumothorax are genetically determined.

Introduction

Spontaneous pneumothorax usually occurs sporadically in healthy young adults and the cause is often unknown. Kjaergaard (1935), and Brock (1948) favoured the presence of hereditary congenital lung cysts, which by rupturing, produced a pneumothorax. Familial cases of spontaneous pneumothorax have been described several times since the original description by Faber (1921). The occurrence of spontaneous pneumothorax in the identical twins of one family and in three brothers of another family, as reported below, greatly favours an hereditary aetiology.

Case report

Family 1 (Fig. 1)

A 47-year-old woman was admitted to hospital in June 1972 after the sudden onset of retrosternal pain which had radiated to the left arm. Twenty-four hours later the pain had subsided but she was aware of a 'clicking noise' in her chest. On examination, there was reduced air-entry over the left upper lobe and a systolic click was heard over the heart (Hamman's sign). This sign, attributed to air in the mediastinum, usually indicates a shallow left pneumothorax and a chest X-ray confirmed the diagnosis. She made an uneventful recovery and was discharged 8 days after admission. Some years previously her twin sister had been admitted with a left sided pneumothorax from which she had made a complete recovery. No other member of the family

(parents, three brothers, two sisters) had been similarly affected. The sisters were identical twins of average height with no evidence of any of the hereditary disorders of connective tissue which are sometimes associated with spontaneous pneumothorax. Their alpha-1-antitrypsin levels were within normal limits. This is the first description of this condition occurring in twins.

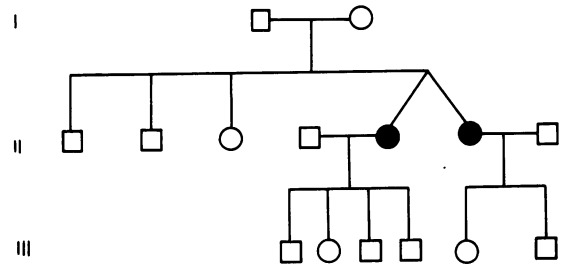


FIG. 1. Pedigree to Family 1.

Family 2 (Fig. 2)

A 20-year-old man was admitted in March 1971 with a right-sided pneumothorax. This was treated conservatively, without the insertion of an intercostal tube, and 11 days later the patient was discharged, having made a complete recovery. In June and July of that year he had two severe left-sided chest pains: each one was accompanied by a 'clicking noise' heard, not only by the patient, but by other members of the family, suggesting that he had suffered further small pneumothoraces (Hamman, 1939)

An X-ray film taken at the time of the last attack suggested a small left apical pneumothorax. When seen in August he had made a complete recovery. Interestingly, this man's two brothers had each suffered a spontaneous pneumothorax. They were all tall (about 6 ft), and thin, but there were no other features to suggest the Marfan syndrome. Their alpha-1-antitrypsin levels were normal. Their two sisters and parents were in good health.

* Present address: Senior Medical Registrar, Walton Hospital, Rice Lane, Liverpool L9 1AE.

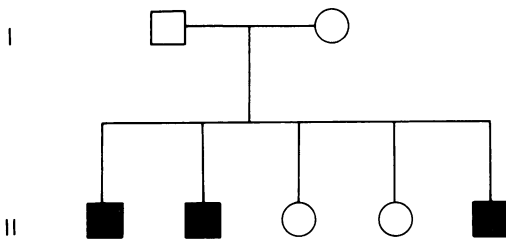


FIG. 2. Pedigree to Family 2.

Discussion

Spontaneous pneumothorax usually affects healthy young adults and is thought to be caused by the rupture of small subpleural blebs which are found in the apex of the upper lobe of an otherwise healthy lung. It has been suggested that individuals with pneumothorax tend to be above average height. Consequently, there is an increased gravitational stress on the lung apex, causing subsequent expansion and rupture of a bulla (Leading Article, 1971). The second family described above, were all tall and this may have been a predisposing factor in the production of pneumothorax in that family.

However, a familial predisposition towards spontaneous pneumothorax has been described. Leites and Tannenbaum (1960) reviewed the literature on this condition and found reports of twelve families in which spontaneous pneumothorax had occurred in two or more members. They described a family in which three brothers exhibited this condition. Taddei (1968) added a further report. Berlin (1950) reported two families with spontaneous pneumothorax in three and five members of different generations respectively. He claimed that predisposition to

the disease was dominantly inherited but that not all 'carriers' suffered the final consequences of it, i.e. clinically verified spontaneous pneumothorax. Clarke (1964) described a family in which pneumothorax occurred in two brothers and a step-brother and he suggested an autosomal dominant inheritance.

The occurrence of spontaneous pneumothorax in two families, as reported here, with three brothers of one family and identical twins of another family being affected, suggests that at least some cases of spontaneous pneumothorax are genetically determined.

Acknowledgment

We would like to thank Dr C. M. Ogilvie, Consultant Physician, Liverpool Royal Infirmary, for permission to report the second case.

References

- BERLIN, R. (1950) Familial occurrence of pneumothorax simplex. *Acta medica scandinavica*, **137**, 268.
- BROCK, R.C. (1948) Recurrent and chronic spontaneous pneumothorax. *Thorax*, **3**, 88.
- CLARKE, C.A. (1964) *Genetics for the Clinician*, 2nd Edition, p. 148. Blackwell Scientific Publications: Oxford.
- FABER, E.E. (1921) Spontaneous pneumothorax hos 2 søskende (Spontaneous pneumothorax in 2 siblings). *Hospitalstidende*, **64**, 573.
- HAMMAN, L. (1939) Spontaneous mediastinal emphysema. *Bulletin of the Johns Hopkins Hospital*, **64**, 1.
- KJAERGAARD, H. (1935) Cystic lungs. *Acta medica scandinavica*, **86**, 407.
- LEADING ARTICLE (1971) Apical lung diseases and spontaneous pneumothorax. *British Medical Journal*, **4**, 573.
- LEITES, V. & TANNENBAUM, E. (1960) Familial spontaneous pneumothorax. *American Review of Respiratory Diseases*, **82**, 240.
- TADDEI, M. (1968) Le pneumothorax spontané familial (Familial spontaneous pneumothorax). *Schweizerische Medizinische Wochenschrift*, **98**, 1396.