

SESSION I

Chairman: DR WALLACE BRIGDEN

The relation between function and causation in cardiomyopathy

CELIA M. OAKLEY
M.D., F.R.C.P.

*Department of Cardiology, Royal Postgraduate Medical School, Hammersmith Hospital,
Du Cane Road, London W12 120HS*

Definition

Cardiomyopathy is defined as 'heart muscle disorder of unknown cause or association' (Oakley, 1972).

We have abandoned the terms primary and secondary cardiomyopathy in order to focus attention on the need to establish the nature of the causal mechanisms in these all too common disorders. Secondary heart muscle disease is best described according to its cause. Disappearance of the word 'cardiomyopathy' will accompany understanding of the genesis of the primary heart muscle disorders. Primary heart muscle disorders are at the present time far more common than secondary myocardial disorders and account for more than 90% of all patients referred to the Royal Postgraduate Medical School for investigation and treatment of a myocardial fault.

Classification

Classification is a cloak for ignorance. Lacking knowledge of aetiology, we group cardiomyopathies according to the nature of the myocardial fault and these functional distinctions are supported by recognizable histopathological differences between the groups (Fig. 1) (Goodwin, 1974; Oakley, 1974).

Systolic pump failure is the basic fault in dilated or congestive cardiomyopathy (COCM). The fault is primarily diastolic in the other types.

In hypertrophic cardiomyopathy (HOCM) the left ventricle is hypertrophied but not dilated, and left ventricular outflow tract obstruction is a common but not invariable accompaniment.

Outside these two major groups are two minor ones which probably overlap, primary restrictive

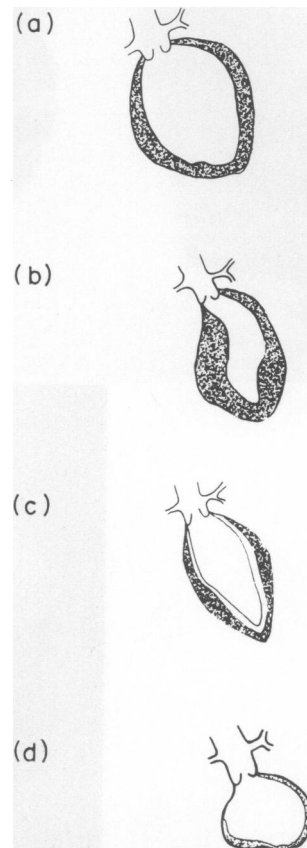


FIG. 1. Functional classification of cardiomyopathy. (a) 'Congestive' or dilated (COCM); (b) hypertrophic obstructive or non-obstructive (HOCM); (c) restrictive (ROCM); (d) oblitative (EMF).

cardiomyopathy (ROCM) and obliterative cardiomyopathy. The latter comprises mainly the tropical disorder endomyocardial fibrosis (EMF) but also Löffler's disease described from temperate climes.

Endocardial fibro-elastosis (EFE) is alone in being a primary dilated cardiomyopathy with a specific pathology. It may, however, represent the infantile response to left ventricular dilatation resulting from any cause and, thus, be the infantile form of COCM.

Dilated cardiomyopathy

Primary dilated or congestive cardiomyopathy

(COCM) is almost certainly highly heterogeneous in origin because the end result of almost any cause of myocardial damage will be failure of contractile ability with an increase in residual volume and progressive dilatation of the cavity of the left ventricle (Fig. 2).

All the known secondary heart muscle disorders lead to systolic pump failure. All except one are associated with progressive left ventricular dilatation. Cardiac amyloid is a partial exception in which compensatory ventricular dilatation does not occur probably because it is impossible, the muscle being stiffened by extensive deposition of amyloid. The

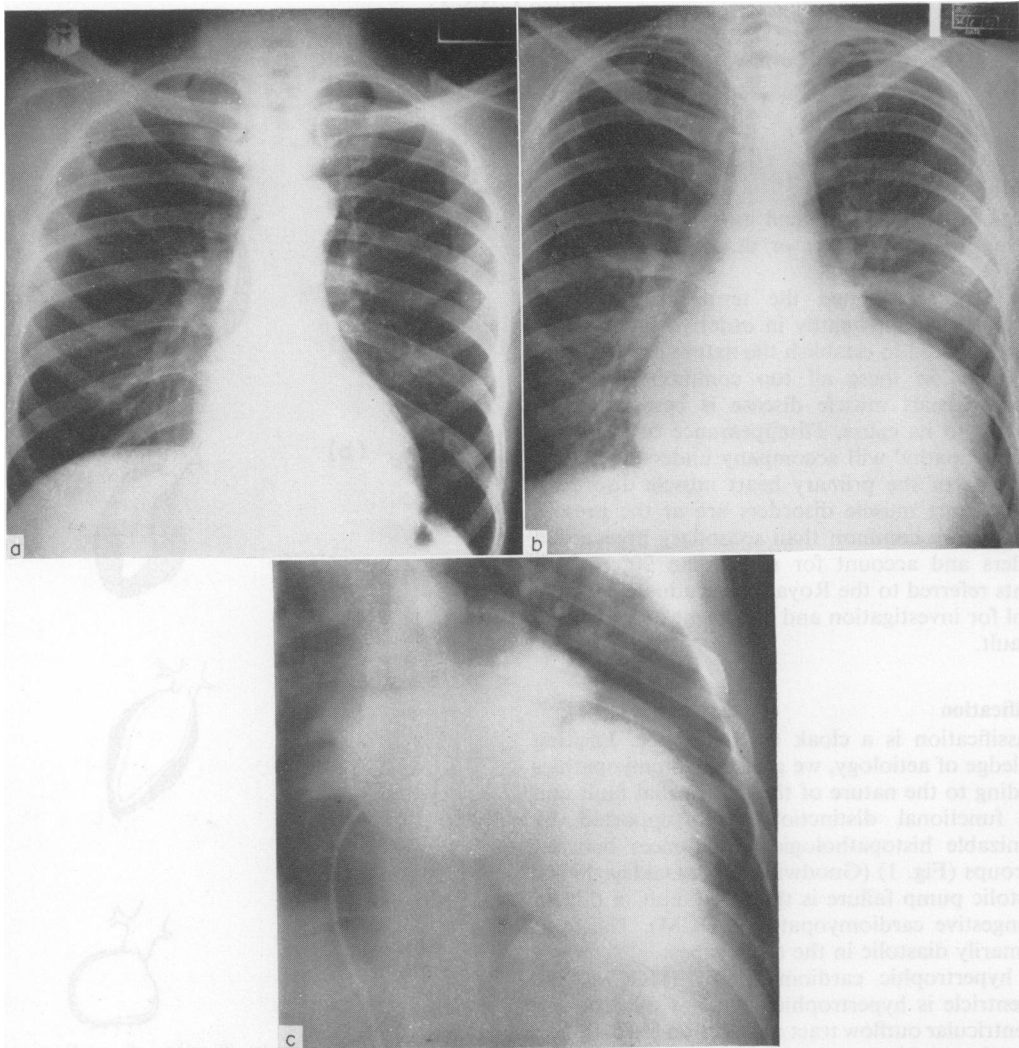


FIG. 2. (a) Plain radiograph of the chest in COCM showing left ventricular enlargement; (b) plain radiograph of the chest in COCM showing greater left ventricular enlargement in a more advanced case; (c) angiogram of the left heart chambers showing gross dilatation of the left ventricle at an advanced stage of COCM.

systolic failure of an undilated left ventricle leads to early death from critical reduction in stroke output at a less advanced stage than would otherwise occur.

Origin and natural history

The onset of left ventricular failure in COCM has been related to previous virus myocarditis, alcoholism and hypertension. There is no evidence of virus infection by the time a patient with COCM is seen. Alcohol is a myocardial depressant but its aetiological role has yet to be proved. Hypertension has much appeal and much circumstantial evidence to support it but it is well nigh impossible to prove because heart failure resulting from high blood pressure would reduce the blood pressure. Complete recovery of a previous dilated and failing left ventricle is so rare that the possibility of proving the thesis by the reappearance of hypertension is infrequent.

Very little is known about the onset or natural history of COCM because the patient with malfunction of the left ventricle short of heart failure is essentially asymptomatic. Such an individual may live a normal life in this state for a variable time (and maybe for years) before the development of shortness of breath or clinical heart failure lead to the discovery of a cardiac fault. The total duration of the disorder from onset to death may last years or only weeks. Some patients may indeed achieve an equilibrium with stability or only very sudden late deterioration. It is frequently stated that the symptoms followed a 'flu-like illness' and, *sic*, that the myocardial disorder is probably 'post myocarditic'. This clinical illness is more likely to have been unrecognized left ventricular failure than a virus infection but is misdiagnosed because the patient may seem an unlikely candidate for heart failure and his doctor does not think of the possibility. When acute myocarditis of proved virus origin is followed up, any evidence of persisting myocardial dysfunction is rare.

COCM is seen at all ages but is comparatively rare in children and is more common in middle age than in young adults. It follows that COCM is most usually seen in patients who are in the coronary age group. Since angina is not unknown in COCM, the development of cardiac symptoms in patients of this age is often responsible for a preferred clinical diagnosis of ischaemic heart disease.

Hypertrophic cardiomyopathy with or without obstruction

Hypertrophic obstructive cardiomyopathy (HOCM) is probably a genetically homogeneous condition with a dominant inheritance but its clinical appearances are widely variable. Inability to diagnose the affected young who are still clinically normal

and the persistently clinically normal adults, who are only mildly afflicted, has been responsible for descriptions of familial and sporadic cases and even dominant and recessive modes of inheritance. HOCM used only to be recognized when left ventricular hypertrophy was associated with outflow tract obstruction. This was a blinkered view and it has gradually been appreciated that outflow tract obstruction is present in only a certain proportion of patients. It develops in childhood or early adult life from an earlier non-obstructive phase. Later on in the disease the obstruction occasionally disappears again spontaneously, although with continuing clinical deterioration. It is, thus, that obstruction to left ventricular outflow is neither an invariable feature of the disorder nor constant during the lifetime of individual patients. In addition, it is variable from moment to moment, according to the state of sympathetic activity, heart rate or left ventricular filling of the patient. The myocardial hypertrophy that characterizes this disorder appears to be primary rather than secondary to any increase in work load (Fig. 3).

The disorder does not appear to have a biochemical basis but to reside in the arrangement of the myocardial fibres and possibly also of the myofibrils. The recognizable HOCM cell may have either a focal or widely distributed arrangement and it is helpful to consider that the diverse clinical spectrum and variable natural history are attributable to the differing number and distribution of abnormal myocardial cells within the left and, occasionally also, within the right ventricle.

Obstruction to left ventricular outflow does not develop until septal hypertrophy and fibrosis have immobilized the septum and splinted the left ventricle by preventing normal shortening during systolic ejection. A normally acting and uninvolved free wall contracts actively and tends to be bent around the immobile septum. This results in the contracted papillary muscles pulling on the mitral leaflets which are dragged into the ventricle and the valve is reopened. The anterior mitral leaflet hits the protruding septum during systole and obstruction results.

With the progress of time, deterioration in the contractile ability of the left ventricle can lead to spontaneous relief of obstruction in a few patients. This will occur when the end systolic volume becomes larger because vigorous contraction of the free wall and papillary muscles no longer occurs. Clinical deterioration follows because the stroke volume falls as a result of a decrease in ejection fraction without an increase in end diastolic volume. Sudden death may occur because left ventricular filling is slow and so the small stroke volume cannot be compensated by tachycardia. Moreover, tachycardia may be

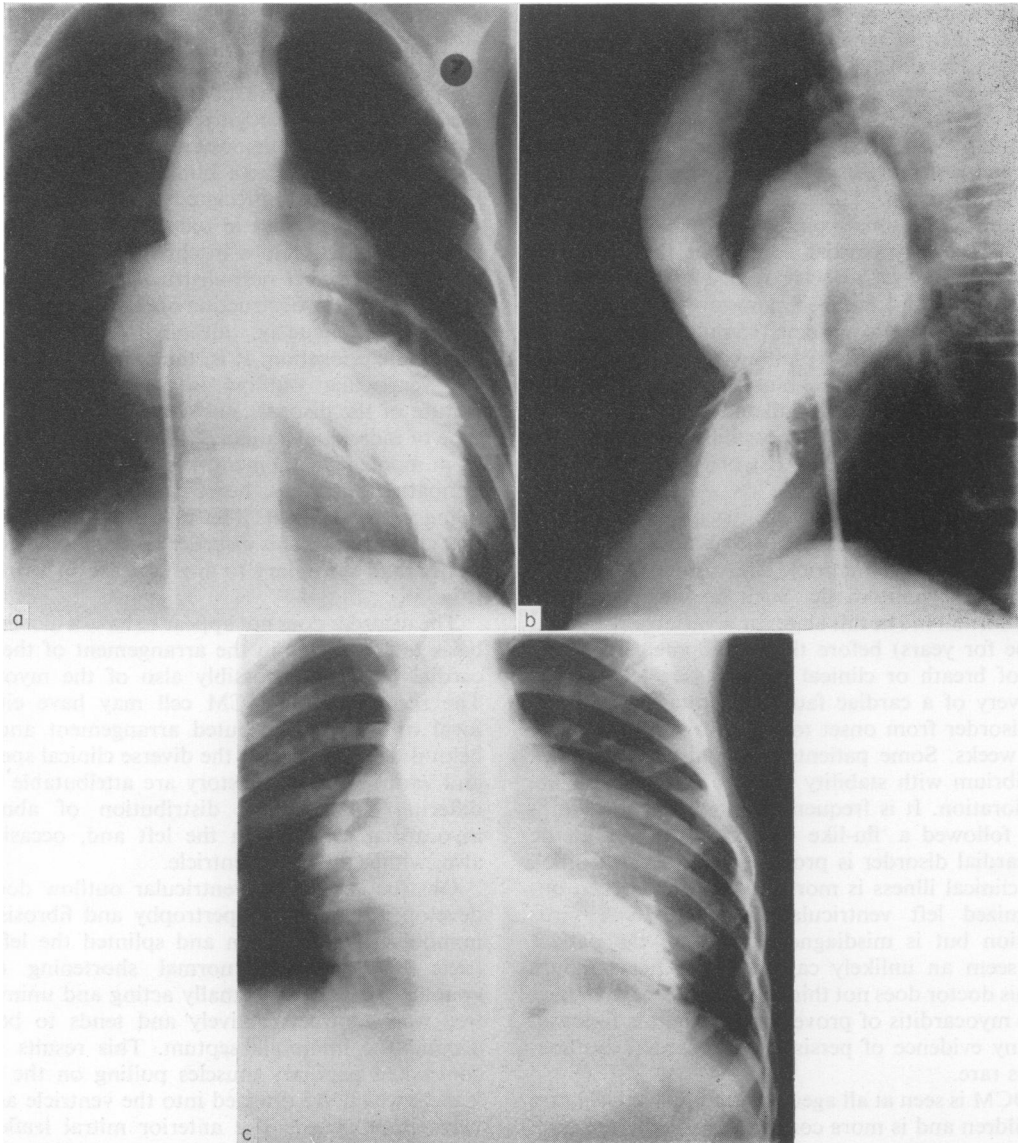


FIG. 3. The appearance of the left ventricle in HOCM. (a) Frontal view in HOCM with obstruction showing bent left ventricular cavity and asymmetrical hypertrophy less marked in the free wall than in the septum; (b) lateral view of the same patient as in (a) showing dislocation of anterior leaflet of the mitral valve towards the septum at the point of obstruction; (c) frontal view of left ventricular angiogram from child with non-obstructive form of HOCM of great severity. There is an increase in thickness of the free wall as well as the septum and the cavity of the left ventricle is undeformed.

dangerous on account of curtailment of vital coronary blood flow to the hypertrophied and excessively demanding myocardium. Ventricular indistensibility and poor left atrial emptying may eventually lead to an increase in left atrial size and atrial fibrillation with further fall in output and the development of clinical congestive failure which

may lead to confusion with dilated cardiomyopathy.

In patients with less focal hypertrophy of the left ventricle, obstruction to left ventricular outflow may never develop. When the left ventricle is more diffusely involved the shape of the left ventricle remains comparatively normal, there is no systolic reopening of the mitral valve and no obstruction to

ejection. If hypertrophy is severe and generalized the presentation is usually during childhood with problems caused by the inability of the left ventricle to fill, and sudden death may be the first 'symptom'. Others present with syncope on effort, shortness of breath or inability to keep up. Others, less severe, may present in older life or may remain asymptomatic, never detected and yet be gene carriers.

Recently ultrasound has been shown to be a sensitive method of detecting abnormal thickness of the septum in clinically normal and symptom-free young or mildly affected relatives of patients with classical HOCM.

Primary restrictive cardiomyopathy (ROCM)

This is a much rarer group of patients most of whom probably have endocardial disease involving

the left ventricle alone or both ventricles. Systolic contractile function is normal and the fault is a diastolic one (Fig. 4). In contrast to HOCM, filling is completed rapidly and the left ventricular cavity is of normal shape although the interior may be abnormally smooth with diminished prominence of trabeculation (seen in diastole) and of papillary muscle indentations (best seen in systole). Involvement of the atrio-ventricular valves in the endocardial process may lead to some mitral regurgitation and when the right ventricle is also involved then there may be tricuspid regurgitation as well.

These patients present with congestive features when the right ventricle is involved, but when the left ventricle only is involved the disorder may be asymptomatic. A surprising number of patients complain of chest pain resembling angina and the

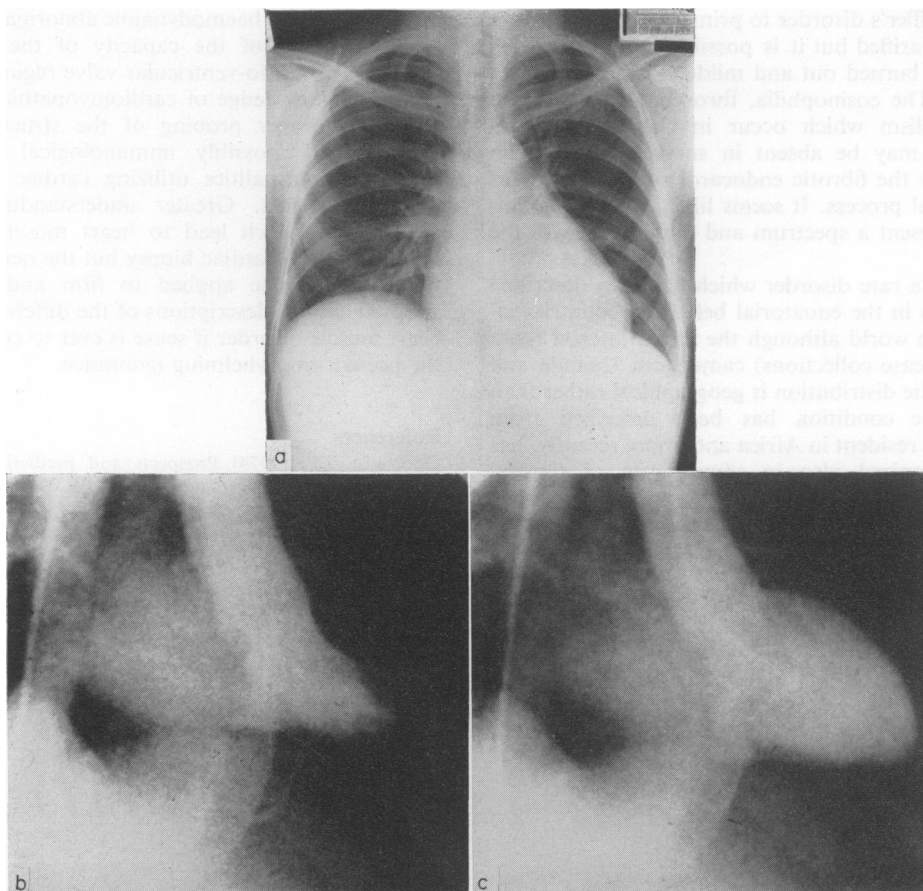


FIG. 4. (a) Plain radiograph of the chest in ROCM; the heart is not enlarged; there is slight pulmonary venous congestion; (b) frontal view left ventricular angiogram in ROCM in systole, and (c) in diastole. The left ventricular contraction is normal. There is some mitral regurgitation. The outline of the ventricle is unduly smooth and the apex appears a little obliterated.

cause of this has not been explained but may lead to the discovery of the disorder in patients which might otherwise have gone undetected.

When the right ventricle is involved, the presentation with a high venous pressure in the neck, hepatomegaly and an early third heart sound together with a normal size heart, suggests constrictive pericarditis. There are usually differences which may enable the distinction to be made but it can be very difficult.

Endomyocardial fibrosis (EMF) and Löffler's disease

These are also essentially endomyocardial disorders in which there may be involvement of the atrio-ventricular valves together with fibrosis and obliteration of the body of the left or right ventricle. It is considered by some that the two conditions represent the same disorder as it occurs in tropical and in temperate climes respectively. The relationship of Löffler's disorder to primary ROCM has not yet been clarified but it is possible that ROCM represents a burned out and milder form of Löffler's disorder. The eosinophilia, thrombotic obliteration and embolism which occur in classical Löffler's syndrome may be absent in surviving cases who retain only the fibrotic endocardium as a legacy of the original process. It seems likely that the conditions represent a spectrum and merge one with the other.

EMF is a rare disorder which has been described from areas in the equatorial belt from countries all around the world although the initial interest (and, therefore, case collections) came from Uganda and Nigeria. The distribution is geographical rather than ethnic; the condition has been described from Europeans resident in Africa and, more recently, has been recognized also in some parts of Central America and Southern India. The endocardial lesions seem to start with thrombosis, perhaps initiated by an allergic or inflammatory reaction, and then progress to fibrosis.

The presentation depends on the sites of involve-

ment within the heart. With left-sided disease, the patient presents either with mitral regurgitation due to involvement of the posterior cusp of the mitral valve or with left ventricular failure resembling COCM. The African patient with right-sided disease characteristically presents with a grossly raised jugular venous pressure and ascites, suggesting advanced constrictive pericarditis. In other cases, the heart shadow may be very large because of associated pericardial effusion.

In Africa, EMF is much less common than primary COCM. In Europe, Löffler's disorder is even rarer than is EMF in Africa. Unlike EMF, Löffler's disorder is usually largely or wholly confined to the left ventricle. Embolism is common. As in EMF, mitral regurgitation occurs owing to involvement of the mitral valve apparatus in the endocardial process.

Both in EMF and in Löffler's disorder the systolic contractility of the left ventricle is little if at all impaired and the haemodynamic abnormality results from reduction of the capacity of the ventricles together with atrio-ventricular valve regurgitation.

Further knowledge of cardiomyopathies must be based on deeper probing of the structural, biochemical and, possibly, immunological and virus-induced abnormalities utilizing cardiac biopsy in afflicted patients. Greater understanding of the mechanisms which lead to heart muscle disorder will come from cardiac biopsy but the new information needs to be applied to firm and generally adopted clinical descriptions of the different sorts of heart muscle disorder if sense is ever to come out of the present overwhelming ignorance.

References

- GOODWIN, J.F. (1974) Prospects and predictions for the cardiomyopathies. *Circulation*, **50**, 210.
- OAKLEY, C.M. (1972) Clinical definitions and classification of cardiomyopathies. *Postgraduate Medical Journal*, **48**, 703.
- OAKLEY, C.M. (1974) The clinical recognition of the cardiomyopathies. *Circulation Research*, **35** (Suppl.), 2.