

SESSION III

Chairman: DR WALTER ABELMANN

The coronary arteries in active viral cardiomyopathies

G. E. BURCH*
M.D.

*Department of Medicine of the Tulane University School of Medicine and the
Charity Hospital of Louisiana, New Orleans*

Summary

These studies reveal that in mice, Cocksackie B₄ and EMC viruses produce not only myocardial disease but extensive disease of the myocardial capillaries, coronary arteries, aorta and mesenteric arteries and veins and other arteries and veins. These lesions impair luminal calibre and, in turn, lead to myocardial ischaemia. This ischaemia contributes further to the myocardial damage. It is postulated that viruses initiate arteriosclerosis in man. A 19-year-old man who died of Cocksackie B₄ viral cardiomyopathy had changes in the aorta noted on light and electron microscopy which are compatible with atherosclerosis. The relationship of these aortic changes to the viral infection can only be opened to speculation. Nevertheless, all of these studies establish a new concept of the possible initiating cause of arteriosclerosis, a common and extremely important disease of man.

ONE of the enigmas of cardiology is the cardiomyopathies. This disease entity is considered and classified differently among cardiologists throughout the world (Goodwin and Oakley, 1972; Hudson, 1970; Burch and DePasquale, 1968). Some limit the term to the idiopathic state (Goodwin and Oakley, 1972) whereas others consider the cardiomyopathies to have causes, some known and some unknown (Hudson, 1970; Burch and DePasquale, 1968; Brigiden, 1957; Evans, 1961; Burch, Giles and Colcolough, 1970). Unfortunately, in most cases the diagnosis is not made until the disease is far advanced in its chronic stage, so that the aetiology is difficult,

if not impossible, to establish. Thus, most of the studies of pathogenesis and pathology are concerned with studying the 'tombstones' of the disease. For some time we have been concerned with investigating the role of viruses in the production of acute and chronic cardiopathy (Burch and DePasquale, 1964, 1968). These studies have shown that viruses will produce myocardial (Burch and DePasquale, 1966; Sohal and Burch, 1969; Burch *et al.*, 1971a), pericardial (Tsui and Burch, 1971), valvular (Burch and DePasquale, 1966; Burch *et al.*, 1966, 1971; DePasquale *et al.*, 1966), mural endocardial (Burch *et al.*, 1966, 1971c) and even coronary vascular disease (Sohal *et al.*, 1968; Burch, Tsui and Harb, 1971). Thus, not only is the myocardium damaged to a variable extent acutely and chronically, but there is superimposed stress produced by haemodynamic changes and impairment of coronary blood flow. In addition, we have shown that the nervous system of experimental animals is damaged by the viruses (Tsui and Burch, 1972). This, in turn, could involve innervation to the heart with resultant physiological disturbances. Even though our studies have been limited to the picornavirus group, other viruses, including unknown ones, may be responsible for heart disease.

This report is concerned primarily with damage to the coronary arteries and the aorta by the Cocksackie B₄ virus and the encephalomyocarditis (EMC) virus.

Method

The types of virus used and methods of study are described in detail in previous publications (Burch *et al.*, 1971a, b, 1973; Tsui and Burch, 1971). Briefly, we used random-breed suckling and 12-day-old HaM/ICR mice. The mice were inoculated intraperitoneally with 0.025-0.1 ml of monkey

* Supported by Grant HL-06769 from the National Heart and Lung Institute of the U.S. Public Health Service, the Rudolph Matas Memorial Fund for the Kate Prewitt Hess Laboratory, the Rowell A. Billups Fund for Research in Heart Disease and the Feazel Laboratory.

kidney cell culture fluid containing Coxsackie B₄ virus with titres of 10⁻³ to 10⁻⁵ TCID₅₀, or L-cell cultures containing EMC virus with a titre of 10⁻⁶ TCID₅₀. The animals were killed 24 hr to 10 days after inoculation. Samples of myocardial tissue and aorta were collected immediately upon death and fixed for light and electron microscopic examination as previously described (Burch *et al.*, 1971a, b).

Results

The results are briefly illustrated in Figs 1–21. The younger the mice, the more fulminating was the disease, everything else being the same.

The ultrastructure of the normal myocardial capillary (Fig. 1) is similar to that described by Palade (1961). Careful comparison of the normal capillary with those in Figs 2–7 readily reveals the damage produced in the capillaries of the myocardium of the mouse by Coxsackie B₄ virus. The endothelial cells became swollen, the capillary lumen was narrowed and the endothelial cells were damaged to variable extent from mild to extensive (Figs 2–7). There may be focal to total injury of the individual endothelial cell, including disruption of the basement membrane and formation of platelet thrombi which almost completely obstruct the capillary lumen.

Histological studies of the aorta and coronary arteries of these mice revealed extensive damage of these vessels (Figs 8 and 9). The endothelium of the aorta and coronary arteries of the mice was destroyed and the intima denuded; oedema and inflammation were present; pyknotic nuclei were numerous; and

the general morphology was disorganized. The damage varied considerably in extent from area to area. Mitotic figures were noted. The changes were less extensive by the third day after inoculation.

It should be mentioned that the same changes were found in the pulmonary veins and mesenteric arteries and veins of the viral infected mice. Lesions have been found in arteries and veins elsewhere in these mice as well.

The EMC virus produced the same type of lesions noted by both light and electron microscopy, Burch and Harb (1975a); Burch and Harb (1975b) as did the Coxsackie virus (Figs 10–13). The EMC virus was also found to produce crystals in the heart and blood vessels, whereas Coxsackie B₄ virus has been found so far to produce crystals only in the pancreas of our mice.

The lesions noted in the coronary arteries, aorta and myocardial capillaries are well illustrated by the figures and described by the legends. The lesions produced by the viruses were so variable and sharply localized that one could demonstrate a wide spectrum of damage varying from normal areas to slight damage to total necrosis. A characteristic cytonecrosis (Harb and Burch, 1973; Burch and Harb (1975) (Figs 10–13) was found to be produced by the picornaviruses in all types of tissues studied, including cells of the arteries. This virocytonecrosis (Harb and Burch, 1973; Burch and Harb (1975b) has been found adjacent to viral crystals (Burch *et al.*, 1971a, c; Burch and Harb, 1975a, b; Harb and Burch, 1973).

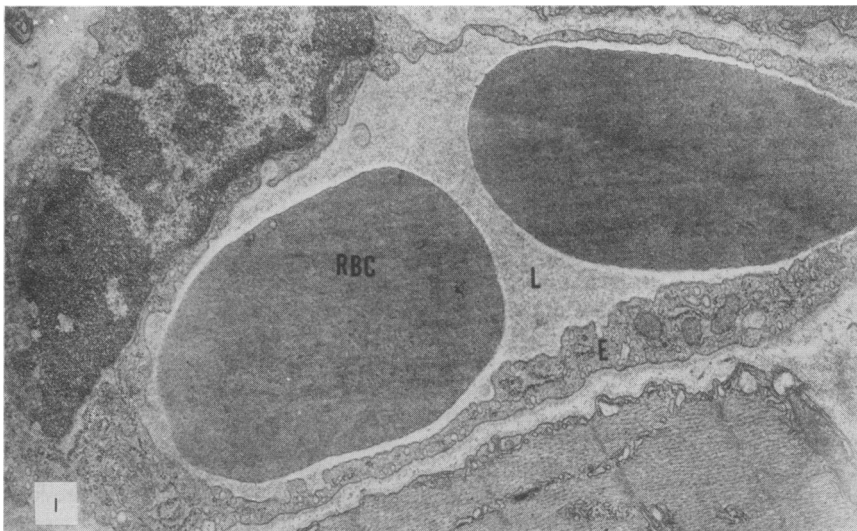


FIG. 1. Normal myocardial capillary of 5-day-old suckling mouse. The endothelial cells (E) are normal, and the lumen (L) contains red blood cells (RBC) and precipitated plasma protein. ($\times 22,950$) (Sohal *et al.*, 1968).

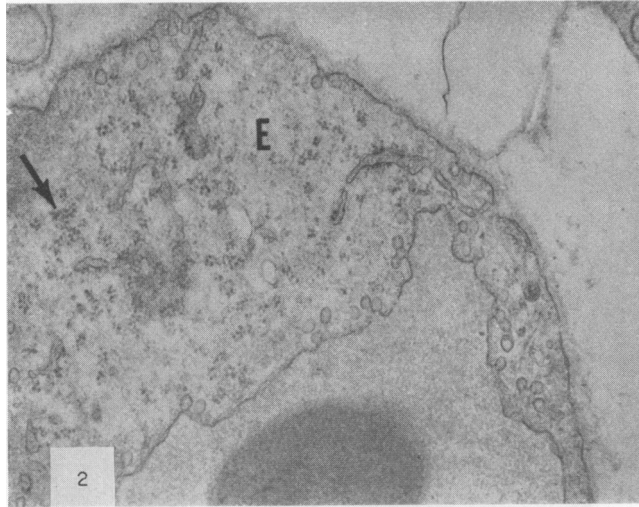


FIG. 2. Portion of myocardial capillary of 5-day-old mouse infected with Coxsackie B₄ virus. The endothelial cell (E) is swollen and contains clusters of ribosomes (arrow). ($\times 36,960$) (Sohal *et al.*, 1968).

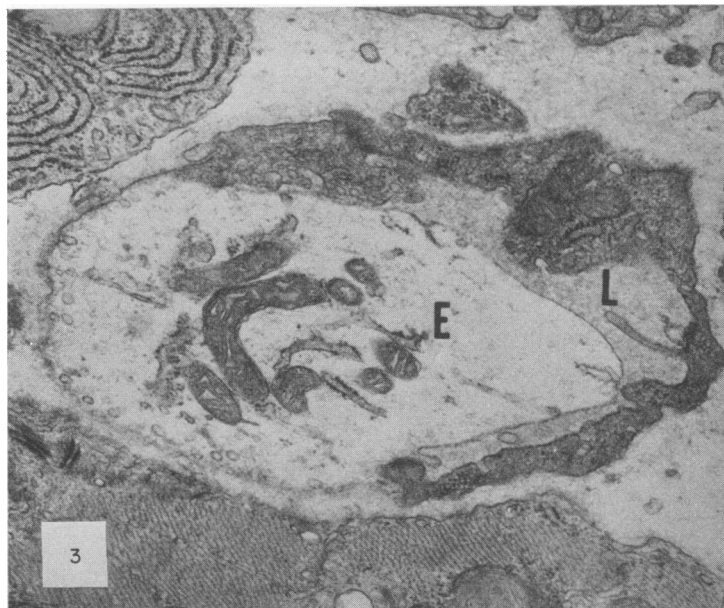


FIG. 3. Myocardial capillary of 5-day-old mouse infected with Coxsackie B₄ virus. The endothelial cell (E) is so swollen that the lumen (L) is almost closed. ($\times 33,540$) (Sohal *et al.*, 1968).

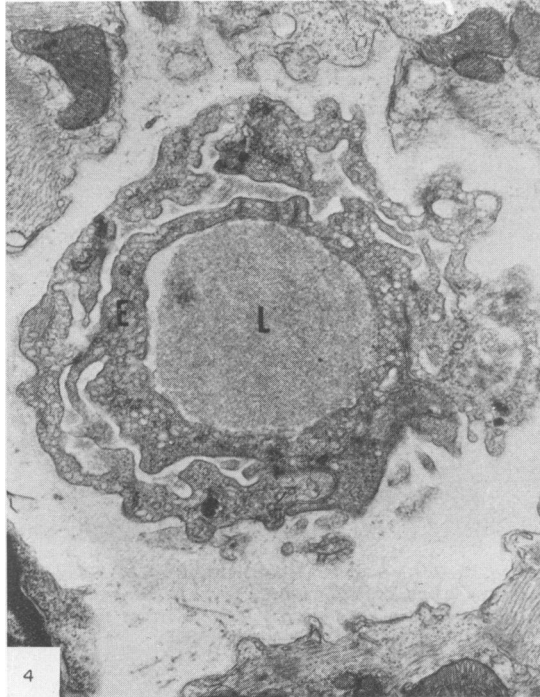


FIG. 4. Myocardial capillary of 5-day-old mouse infected with Coxsackie B₄ virus showing a double layer of endothelial cells (E) surrounding the capillary lumen (L). ($\times 28,160$) (Sohal *et al.*, 1968).

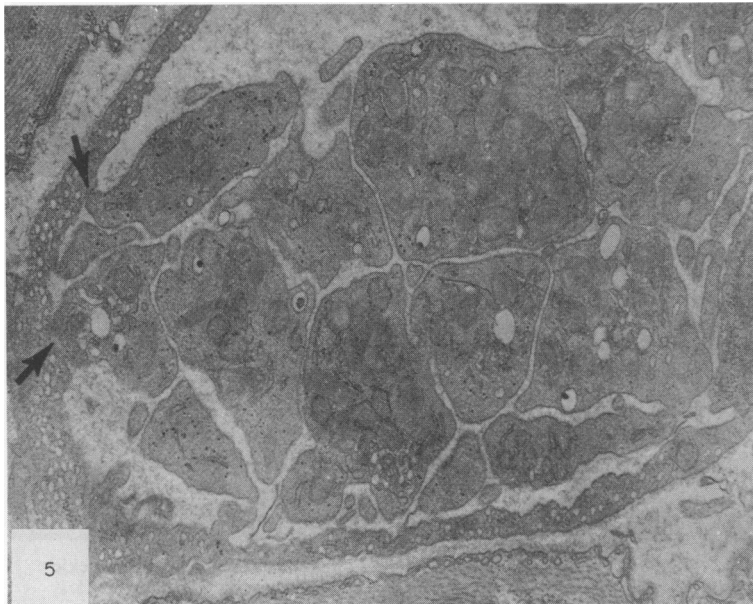


FIG. 5. Myocardial capillary of a Coxsackie B₄ virus infected mouse showing a platelet thrombus in the lumen, with some platelets in contact with the endothelial surface (arrows). ($\times 25,600$) (From Sohal *et al.*, 1968).

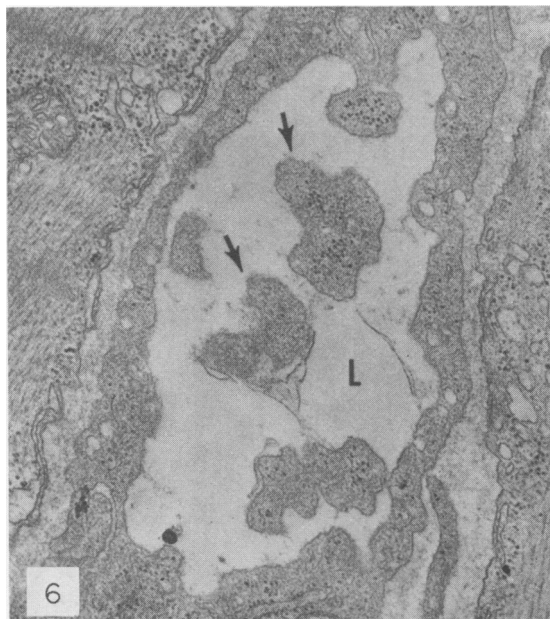


FIG. 6. Myocardial capillary of a Cocksackie B₄ virus infected mouse, with pieces of cytoplasm (arrows), apparently detached from the endothelial cells, within the lumen (L). ($\times 41,280$) (From Sohal *et al.*, 1968).

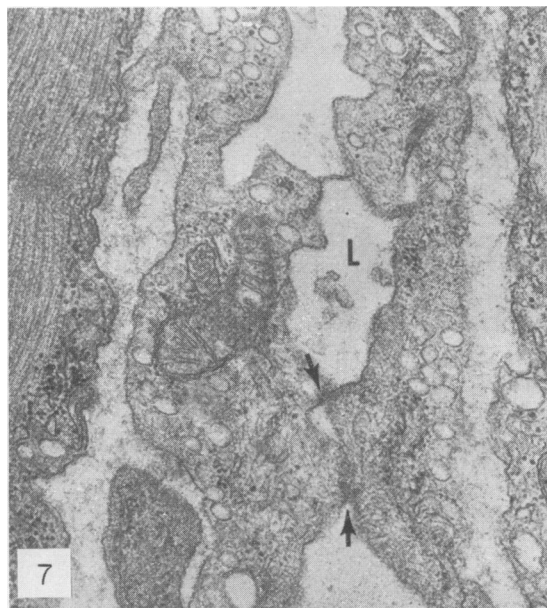


FIG. 7. Myocardial capillary of a Cocksackie B-virus infected mouse in which the lumen (L) is partially blocked by opposing endothelial cells in contact with each other (arrows). ($\times 58,820$) (From Sohal *et al.*, 1968).

Discussion

The illustrations contained in this report demonstrate very well the lesions produced by viruses in the coronary capillaries and arteries, the aorta, and other arteries and veins of our experimentally infected animals. The mechanism by which the damage is produced is not clear. It would appear from some tissue sections that the virus itself is responsible for at least some, if not all, of the vascular diseases. This is supported by findings of viral crystals adjacent to areas of cytonecrosis (Figs 11–13) in cells of the aorta. It is possible, however, in the instance of the myocardial capillaries, that with damage to adjacent myocardial cells the capillaries are secondarily damaged also. Such details of pathogenesis of vascular damage must await further investigation. Nevertheless, the capillary and arterial damage can be extensive (Figs 2 and 3) and associated with thrombus formation (Fig. 5) with resultant obstruction to myocardial blood flow and subsequent ischaemic damage to the myocardium. When it is realized that the valves of the heart are also damaged (Burch and DePasquale, 1968; Burch *et al.*, 1966; DePasquale *et al.*, 1966; Burch *et al.*, 1971c) and that the associated haemodynamic stress is imposed upon the already extensively damaged myocardium (the source of power for the pump), it is easy to realize how severe viral disease of the heart can be. It is no wonder, therefore, that a severe chronic cardiomyopathy can follow.

It is impossible to be concerned with aortic and arterial viral lesions of these types without wondering how the repair will manifest itself. The lesions of repair must vary considerably in extent and severity. Surely, it is not possible to extrapolate with certainty findings from mice to men. Nevertheless, it is interesting to postulate that repair of such viral lesions in the aorta and arteries of man may result in the 'tombstones'—arteriosclerosis and atherosclerosis—important and extremely common lesions of the higher pressure vessels of man. Viral infections of the arteries in infancy, childhood and adult life may initiate the arteriosclerotic lesions found in later life and recently described (Mitchell, 1973; McMillan, 1973) even in infancy and childhood.

The relationship of viral infections to the production of arteriosclerosis must await long and tedious investigations in the future. The experimental models used by us provide an opportunity to study this problem. As mentioned above, extrapolation from experimental animals to man must be made with considerable caution. However, I had a patient (19-year-old male) who had Cocksackie B₄ viral infection, determined clinically and by immunofluorescent assay, with a severe cardiomyopathy who died and whose tissues were available for study. Among the many different types of tissue collected

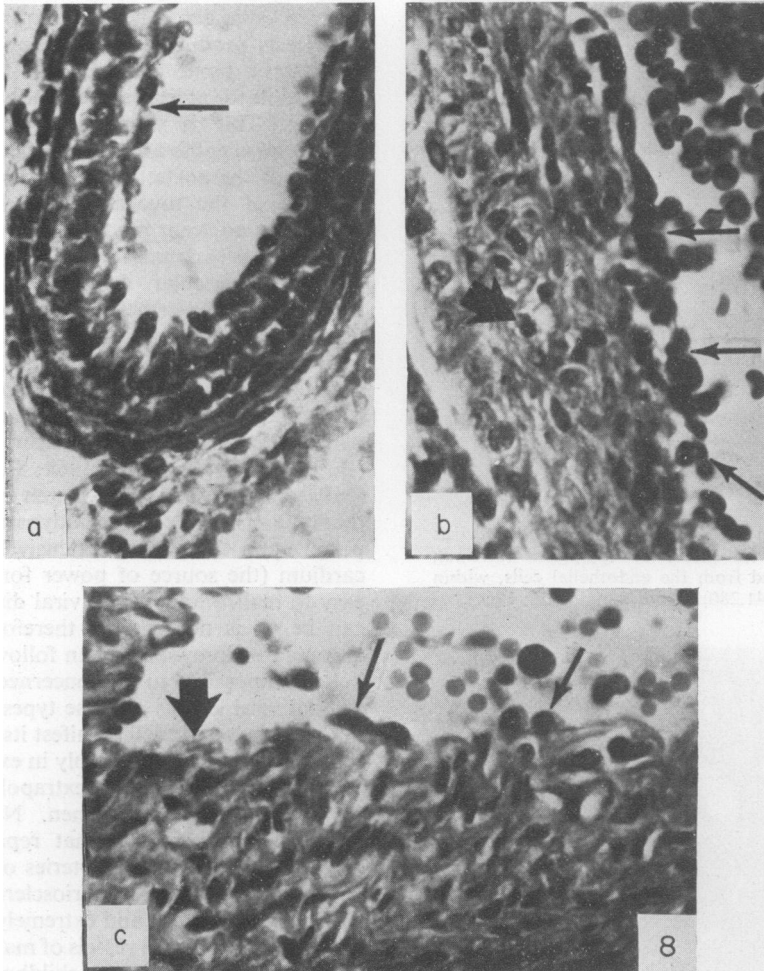


FIG. 8. Sections of aortas of suckling mice infected with Coxsackie B₄ virus showing focal oedema of the aortic wall and subendothelial region. (a) Overlying endothelial cells are swollen (arrow); (b) inflammatory cells infiltrated the subendothelial region (small arrows), and cells with pyknotic nuclei (large arrow) are seen in the media; (c) endothelial cells are swollen (small arrow) and the intimal surface is denuded (large arrow) in this section of aorta. (HE \times 450) (From Burch *et al.*, 1971).

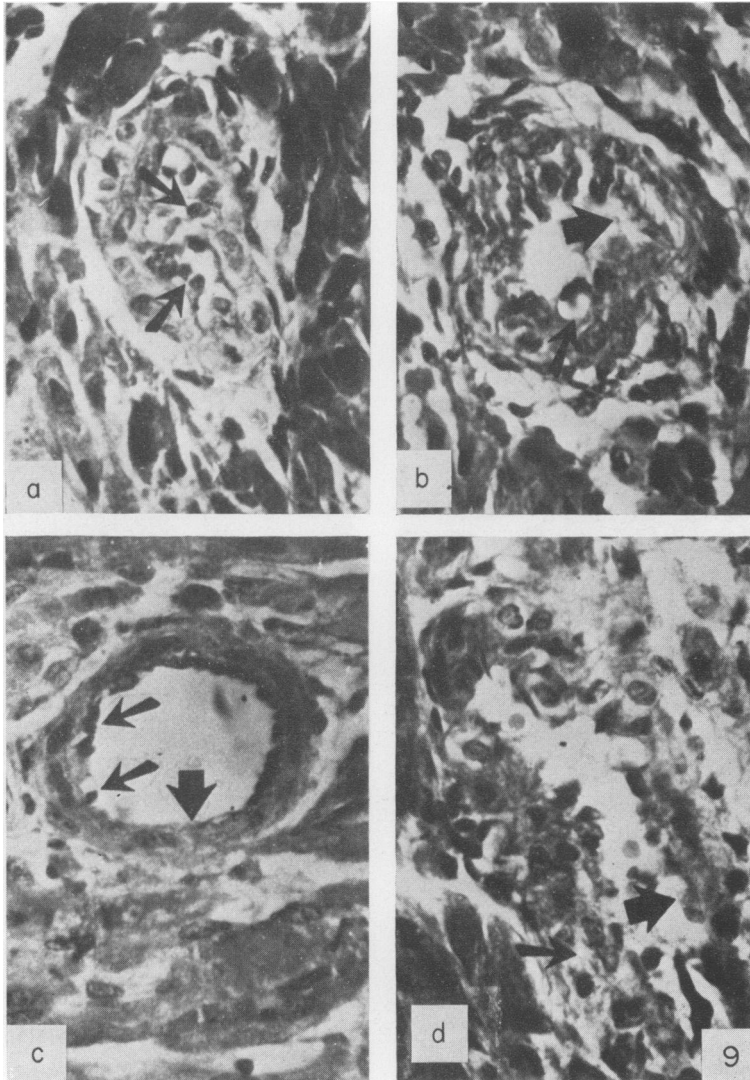


FIG. 9. Sections of aortas of mice infected with Coxsackie B₄ virus. (a) The endothelial cells are swollen and some have pyknotic nuclei (arrows); (b) vacuolated endothelial cells (small arrow) and denuded intimal surface (large arrow) are seen in this section; (c) the intimal surface of this aorta is denuded (large arrow) and the endothelial lining cells are degenerative (small arrows); (d) the intimal surface of this aorta is also denuded (large arrow) and the media is oedematous (small arrow). Necrosis of the adjacent myocardium can be seen in the right lower portion of c and in the right upper portion of d. (H & E \times 450) (From Burch *et al.*, 1971).

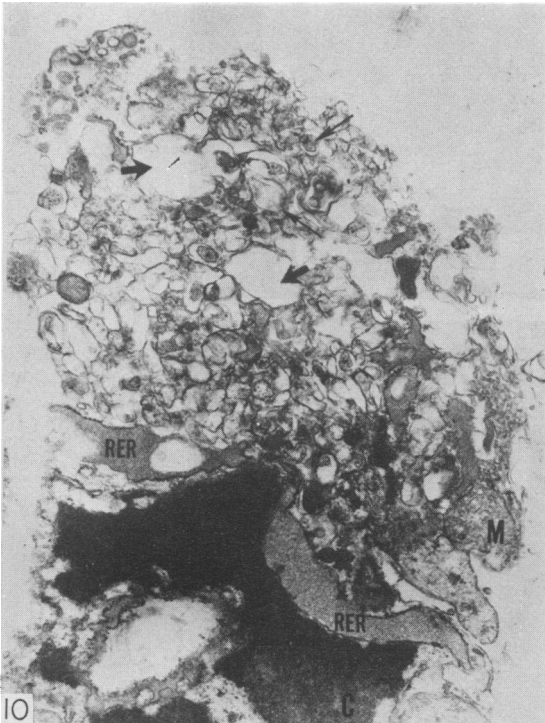


FIG. 10. Extensive necrosis of an adventitial cell of the aorta of a newborn mouse infected with EMC virus. This cytonecrosis is characterized by numerous membrane-bound vesicles (small arrows) and vacuoles (large arrows), dilated rough endoplasmic reticulum (RER) with dense material accumulated within the cisternae, and condensed nuclear chromatin (C). Occasional mitochondria (M) are dilated. ($\times 24,650$) (From Burch and Harb, 1975).

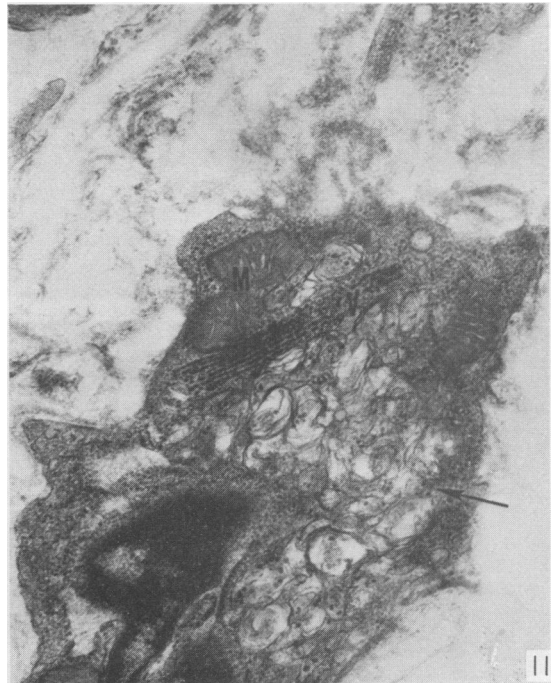


FIG. 11. Adventitial cell of aorta of a newborn mouse infected with EMC virus showing virocytonecrosis. The characteristic cytonecrosis (arrow) is in intimate association with an EMC viral crystal (V). M = mitochondria. ($\times 36,900$) (From Burch and Harb, 1975).

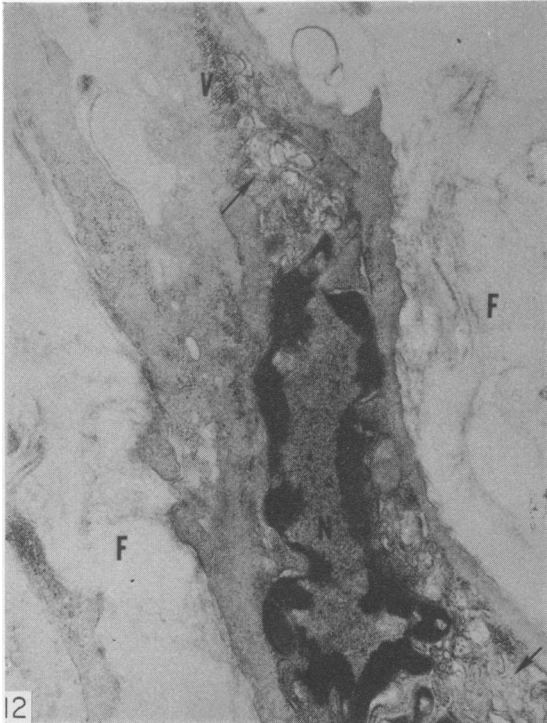


FIG. 12. Smooth muscle cell of aortic media of a newborn mouse infected with EMC virus. Perinuclear areas of virocytotoxicity (arrows) are evident, the area at top containing a viral crystal (V). Elastic fibres (F) border the cell. ($\times 16,150$) (From Burch and Harb, 1975).

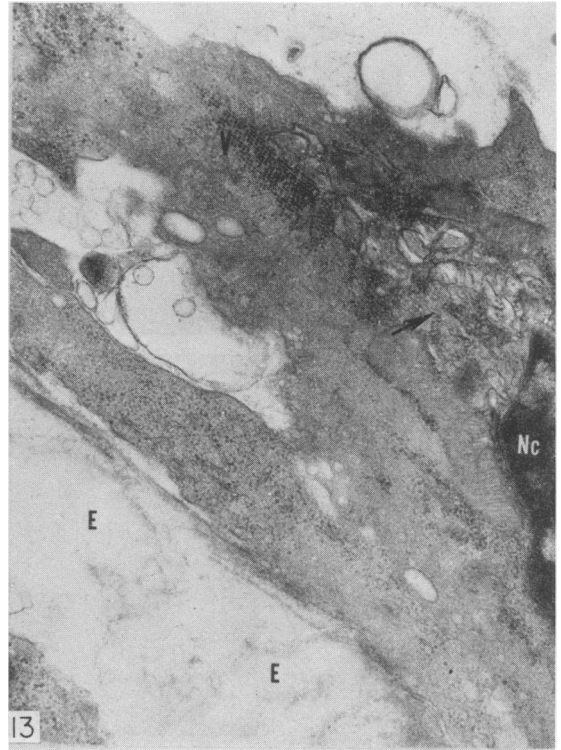
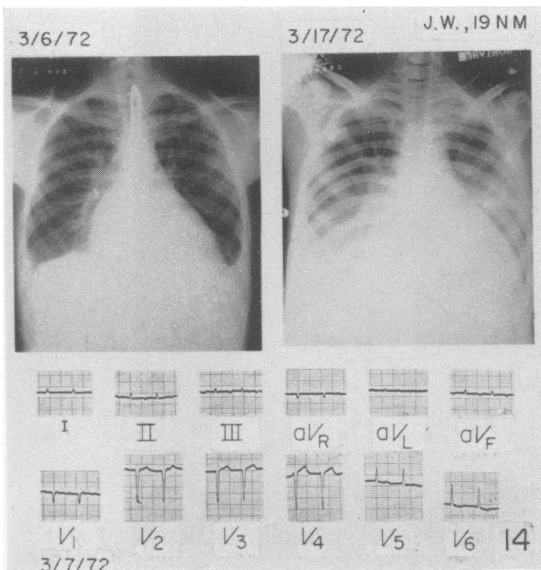


FIG. 13. Smooth muscle cell of media of aorta of EMC virus-infected newborn mouse. A perinuclear area showing characteristic cytonecrosis (arrow) in association with a viral crystal (V) is seen. The nuclear chromatin (Nc) is marginated and elastic fibres (E) border one side of the cell. ($\times 32,370$).



for study was the aorta. The patient had had a rather severe upper respiratory tract infection several weeks before his death from the resultant cardiomyopathy (Fig. 14).

The aorta revealed positive immunofluorescent staining for Coxsackie B₄ viral antigen (Fig. 15). The aorta showed histopathological changes of chronic disease, with oedema, cellular death and fibres with considerable morphological changes (Figs 16–18). Electron microscopic examinations showed cellular damage and large collections of lipid material in smooth muscle cells, macrophages and fibroblasts (Figs 19–21). All of these changes are compatible with atherosclerosis. Whether or not these morphological changes were present before the infection or developed because of the viral infection can only be conjectured; nevertheless, it is

FIG. 14. Serial teleo-X-rays of the chest and electrocardiogram of a 19-year-old man with Coxsackie B₄ viral cardiomyopathy. (From Burch *et al.*, 1973).

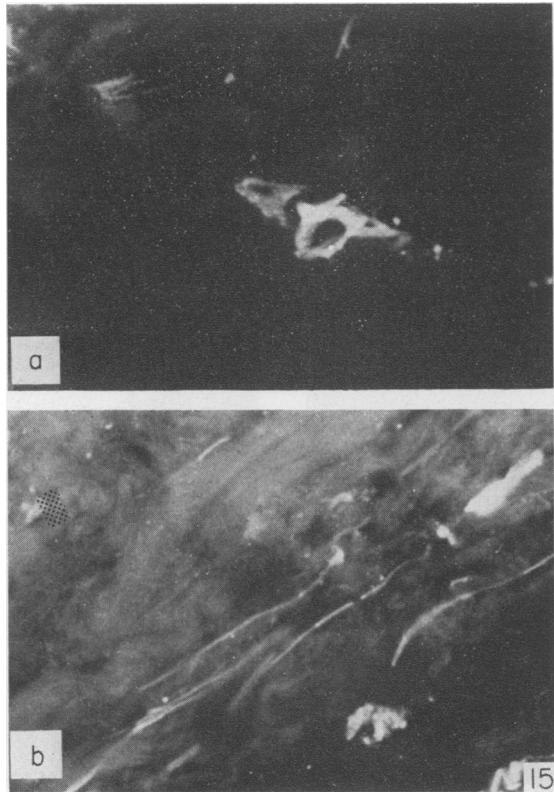


FIG. 15. Sections of aorta of the 19-year-old man with Coxsackie B₄ viral cardiomyopathy showing positive immunofluorescent antibody staining for Coxsackie B₄ virus in cells of the adventitia. ($\times 125$) (From Burch *et al.*, 1973).

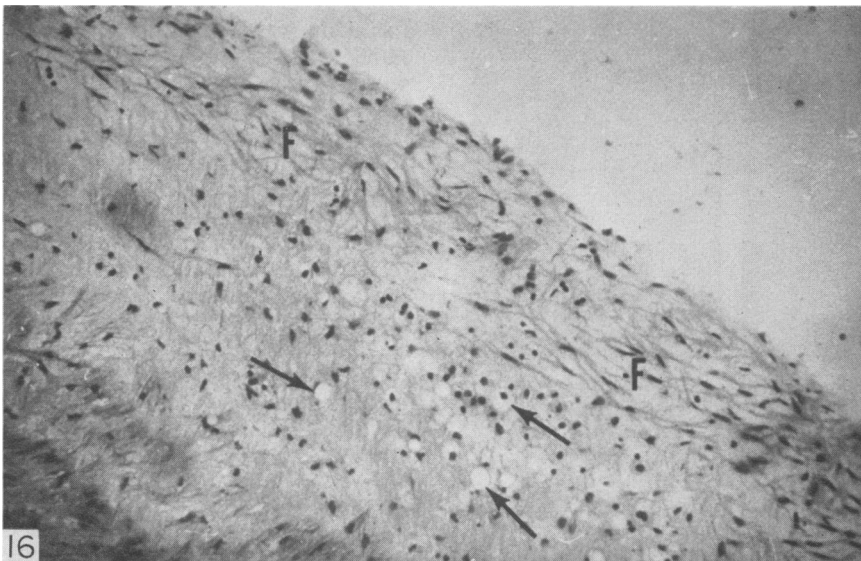


FIG. 16. Photomicrograph of the intima of the aorta of the 19-year-old man with Coxsackie B₄ viral cardiomyopathy. The intima is thickened and oedematous and contains numerous fat droplets (arrows). Fibroblastic proliferation (F) is evident. (HE $\times 100$) (From Burch *et al.*, 1973).

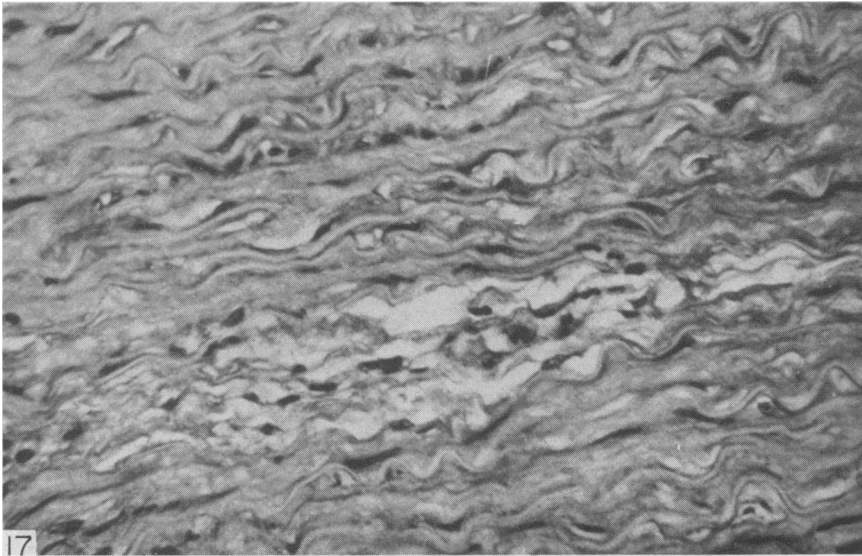


FIG. 17. Photomicrograph of the media of the aorta of the patient with Coxsackie B₄ viral cardiomyopathy showing interstitial oedema. (HE × 200) (From Burch *et al.*, 1973).

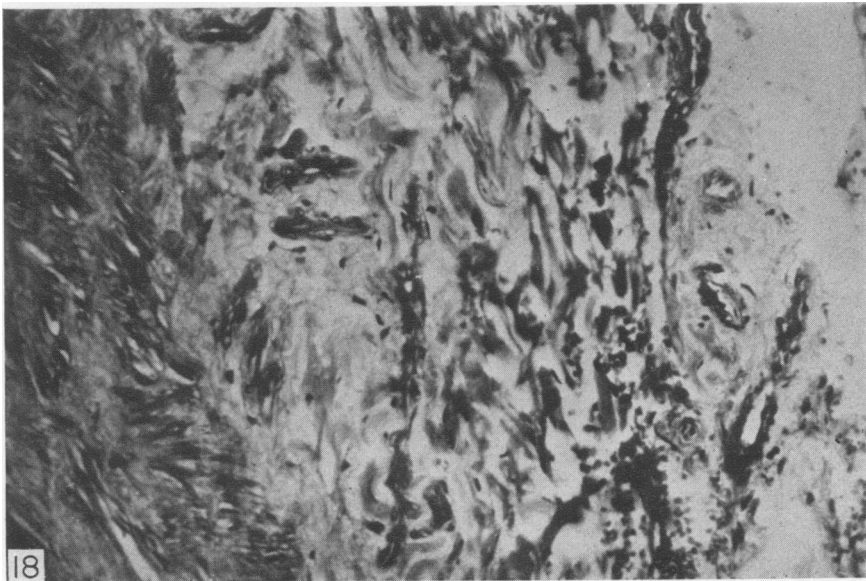


FIG. 18. Photomicrograph of the aortic adventitia of the patient with Coxsackie B₄ viral cardiomyopathy showing collagenous tissue proliferation, interstitial haemorrhage and increased number of small blood vessels. (HE × 100) (From Burch *et al.*, 1973).

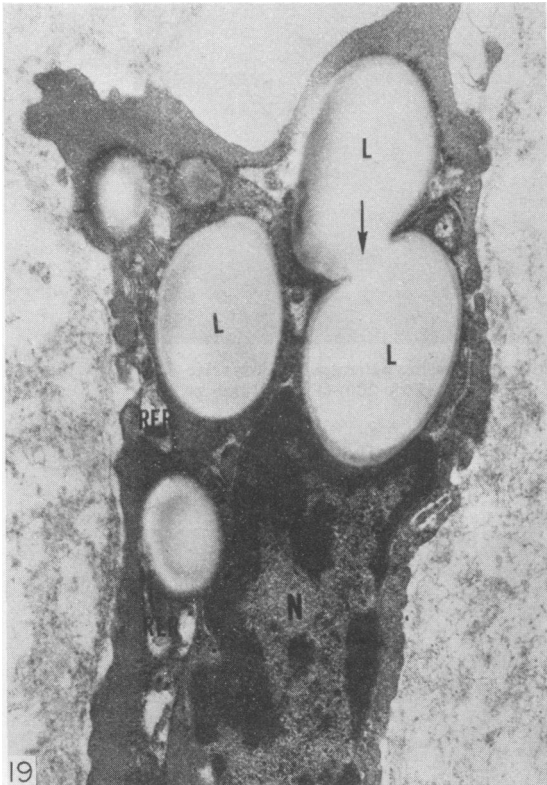


FIG. 19. Electron micrograph of a fibroblast of the intima of the aorta of the patient with Coxsackie B₄ viral infection, showing lipid droplets (L) within the cytoplasm, some of which are coalescing (arrow). One droplet is indenting the nucleus (N). Cisternae of rough endoplasmic reticulum (REP) are seen. ($\times 32,560$) (From Burch *et al.*, 1973).

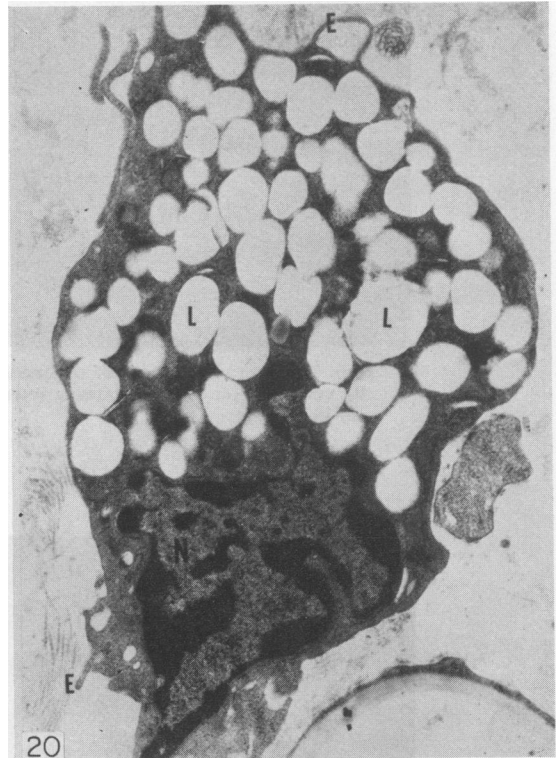

FIG. 20. Electron micrograph of a macrophage of the intima of the patient's aorta. Numerous lipid droplets (L) almost fill the cytoplasm, displacing the nucleus (N). Protoplasmic extensions (E) protrude from the cell. ($\times 18,150$) (From Burch *et al.*, 1973).

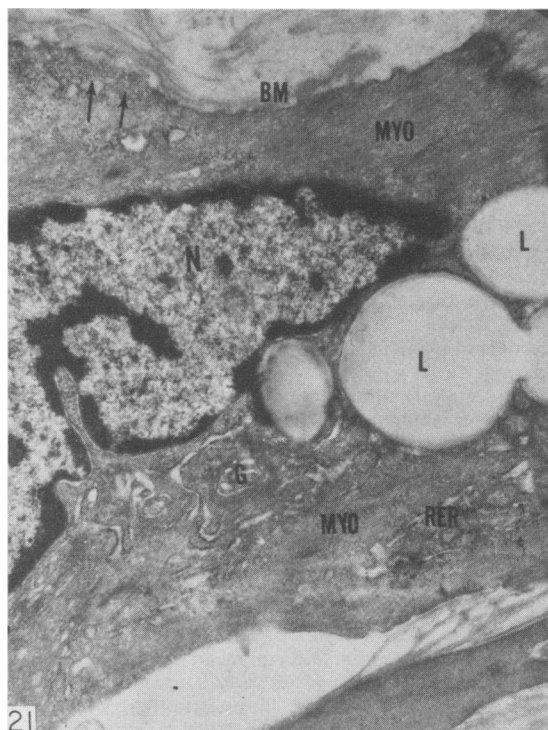


FIG. 21. Electron micrograph of a smooth muscle cell from the intima of the patient's aorta. Lipid droplets (L) are seen in the cytoplasm. The nucleus (N) is centrally located and a Golgi apparatus (G) is close to the nucleus. Pinocytotic vesicles (arrows) are evident. MYO = myofibrils; BM = basement membrane; RER = rough endoplasmic reticulum. ($\times 24,030$) (From Burch *et al.*, 1973)

only through clinicopathological and viral collections such as obtained from this man that the relationship of viral infections in earlier life to arteriosclerosis in later life can be more definitely determined.

References

- BRIGDEN, W. (1957) Uncommon myocardial disease. The non-coronary cardiomyopathies. *Lancet*, **ii**, 1179.
- BURCH, G.E. & DEPASQUALE, N.P. (1964) Viral myocarditis. In: *CIBA Foundation Symposium on Cardiomyopathies* (Ed. by G. E. W. Wolstenholme and M. O'Connor), p. 376. J. & A. Churchill, London.
- BURCH, G.G.E. & DEPASQUALE, N.P. (1966) Cardiomyopathy: Coxsackie viral myocarditis and valvulitis. In: *Proceedings of the Fifth World Congress of Cardiology. Acta cardiologica, Bruxelles*.
- BURCH, G.E. & DEPASQUALE, N.P. (1968) Heart muscle disease (monograph). Disease-A-Month, Year Book Medical Publishers, Chicago.
- BURCH, G.E., DEPASQUALE, N.P., SUN, S.C., MOGABGAB, W.J. & HALE, A.R. (1966) Endocarditis in mice infected with Coxsackie virus B₄. *Science*, **151**, 447.
- BURCH, G.E., GILES, T.D. & COLCOLOUGH, H.L. (1970) Ischemic cardiomyopathy. *American Heart Journal*, **79**, 291.
- BURCH, G.E. & HARB, J.M. (1975a) Encephalomyocarditis (EMC) virus infection of the mouse aorta: An ultrastructural study. *American Heart Journal* (in press).
- BURCH, G.E., & HARB, J. M. (1975b) Characteristic ultrastructural changes in organs of newborn mice infected with EMC virus (to be published).
- BURCH, G.E., HARB, J.M., COLCOLOUGH, H.L. & TSUI, C.Y. (1971a) Encephalomyocarditis infection of the newborn mouse myocardium—An electron microscopic study. *Archives of Internal Medicine*, **127**, 148.
- BURCH, G.E., HARB, J.M., HIRAMOTO, Y. & SHEWEY, L. (1973) Viral infection of the aorta of man associated with early atherosclerotic changes. *American Heart Journal*, **86**, 523.
- BURCH, G.E., TSUI, C.Y. & HARB, J.M. (1971b) Pathologic changes of aorta and coronary arteries of mice infected with Coxsackie B₄ virus. *Proceedings of the Society for Experimental Biology and Medicine*, **137**, 657.
- BURCH, G.E., TSUI, C.Y., HARB, J.M. & COLCOLOUGH, H.L. (1971c) Mural and valvular endocarditis of mice infected with encephalomyocarditis (EMC) virus. *Experimental and Molecular Pathology*, **14**, 327.
- DEPASQUALE, N.P., BURCH, G.E., SUN, S.C., HALE, A.R. & MOGABGAB, W.J. (1966) Experimental Coxsackie virus B₄ valvulitis in cynomolgus monkeys. *American Heart Journal*, **71**, 678.
- EVANS, W. (1961) Alcoholic cardiomyopathy. *American Heart Journal*, **61**, 556.
- GOODWIN, J.F. & OAKLEY, C.M. (1972) The cardiomyopathies. *British Heart Journal*, **34**, 545.
- HARB, J.M. & BURCH, G.E. (1973) Ultrastructural cytopathology of mouse myocardium associated with EMC viral infection. *Journal of Molecular and Cell Cardiology*, **5**, 55.
- HUDSON, R.E.B. (1968) The cardiomyopathies: Order from chaos. *American Journal of Cardiology*, **25**, 70.
- MCMILLAN, G.C. (1973) Development of arteriosclerosis. *American Journal of Cardiology*, **31**, 542.
- MITCHELL, S.C. (1973) Introduction: Symposium on prevention of atherosclerosis at the pediatric level. *American Journal of Cardiology*, **31**, 539.
- PALADE, G.E. (1961) Blood capillaries of the heart and other organs. *Circulation*, **24**, 368.
- SOHAL, R.S. & BURCH, G.E. (1969) Ultrastructural lesions of the myocardial cell in Coxsackie B₄ virus infected mice. *Virchows Archiv für pathologische Anatomie und Physiologie und für Klinische Medizin*, **346**, 361.
- SOHAL, R.S., BURCH, G.E., CHU, K.C., LEIDERMAN, E. & COLCOLOUGH, H.L. (1968) Ultrastructural changes in cardiac capillaries of Coxsackie virus B₄ infected mice. *Laboratory Investigation*, **19**, 339.
- TSUI, C.Y. & BURCH, G.E. (1971) Coxsackie virus B₄ pericarditis in mice. *British Journal of Experimental Pathology*, **52**, 47.
- TSUI, C.Y. & BURCH, G.E. (1972) Lesions of peripheral autonomic ganglia in mice infected with Coxsackie virus B₁. *Archives of Pathology*, **94**, 286.

Discussion

CHAIRMAN: Thank you Dr Burch for your stimulating paper. I think we have time for one or two questions now to be directed to Dr Burch.

PROFESSOR GOODWIN: Do these things make the mice sick?

DR BURCH: The EMC virus does make them sick and kills many mice. There is such a thing as dose relationships and age relationships. If one injects mice that are 8 days old instead of 1-2 days old, the lesions are less severe than in the younger ones. If one injects 14-day-old mice, only a few will die. EMC virus injected into 1- or 2-day-old mice will kill them all within 2 or 3 days. When we are interested in studying the chronic lesions and prolonged changes produced by the virus, we use older mice.

DR BRIGDEN: May I ask, Dr Burch, if you condition these mice in some way? Let us say, give them digitalis, which is pretty toxic, or deplete them of magnesium, and then give them the virus at a stage when they might be resistant at 14 days or 21 days old—what happens then?

DR BURCH: We have done some experiments along those lines, such as the effects of exercise and bacterial conditioning with streptococci. We seem to get a more severe lesion in the presence of the latter.

DR BRIGDEN: You can't break down the resistance that comes with increasing age?

DR BURCH: We think so, but we haven't tried to study this.

VOICE: What do you suggest one does as a clinician when confronted with this problem, as one is again and again? A young man in whom you don't have a viral story, but failure is developing and there is obvious heart muscle disease—if repeated viral antibody tests are negative, what do you do then?

DR BURCH: I'll just tell you what I would do: treat them with bed rest, 100%; that is the main emphasis in management. There are no specific drugs available.

VOICE: I'm sorry, you have mistaken my question. I am really after the aetiology—the possible viral aetiology. I don't think we exclude it by doing the conventional tests.

DR BURCH: No, we do not.

DR BRIGDEN: I am sure we don't. What other action would you suggest? Biopsy? Having got the biopsy, what do we do with it?

DR BURCH: I merely put the patients to bed. We cannot establish a viral aetiology easily. Even after injecting virus into our mice, we don't always recover the virus from the infected mice.

DR BRIGDEN: We are always talking about viral myocarditis in man. This is surely a diagnosis which is rarely proved.

DR BURCH: Immunofluorescent techniques give a higher percentage of positive results than any method so far.

DR OLSEN: Firstly a comment: Dr Burch has asked, at the beginning of his paper, what pathologists thought about his explanations, and of course the evidence that he has shown is convincing.

The question I would like to ask is: in the series where the peculiar degenerative changes in the endothelial cells were seen at electronmicroscopy, you showed a series of aortic lesions in a patient. In these sections you pointed to some areas. Did you mean the balloon cells or the disarray of elastic fibres? My suggestion would be that the disarray of elastic fibres is nothing other than age change which may later develop into Erdheim medionecrosis, but I think the balloon cells may well fit in with your suggestions.

DR BURCH: Well, I don't know the answer to either one of those questions. All I know is that this patient had clinical evidence of viral disease, and the changes noted were found in the cells. Whether the changes were there before the infection or were produced by the infection, we do not know. But there apparently was a relationship to infection. To extrapolate back from animals to man is not always reliable.

CHAIRMAN: Perhaps there will be time for further discussion later on. I think we had better go on with the next paper, which is by Drs Klein and Harmjan, on the influence of alcohol on the ultrastructure of myocardium.