

CASE REPORTS

Malignant mesothelioma invading the spinal canal

D. COOPER
M.B., CH.B.

Department of Histopathology, Central Laboratory, Portsmouth

Summary

A case of diffuse malignant pleural mesothelioma presenting as acute paraplegia is described. Autopsy revealed the presence of metastatic tumour within the spinal cord. An alveolar cell carcinoma coexisting with the mesothelioma and giving a distinct histological pattern was also present. There was no histological evidence of asbestos exposure.

Case report

A man aged 67 years was admitted to hospital in January 1971 giving a history of sudden paralysis, in his right leg, which had occurred 10 days previously; this had been followed by gradual paralysis in his left leg. He had been incontinent of urine for 3 days. Recently he had lost 2 stone in weight, and had developed pains in his right shoulder. He worked in the dockyards of Portsmouth but was not known to have handled asbestos material. He gave no history of previous chest trouble, and was a non-smoker.

He was cachectic, and neurological examination revealed signs of transection of the spinal cord at T8. The chest X-ray revealed marked thickening of the right pleura and coarse mottling of the right lower lobe.

The patient's condition gradually deteriorated until his death 24 days after admission.

Autopsy report

Autopsy was performed after 24-hr refrigeration. The body showed marked cachexia and a right scoliosis. The lower part of the right pleural cavity had been obliterated by a confluent pleural tumour 1-3 cm thick. It had involved the portero-lateral chest wall, diaphragm and right lower lobe. Tumour was adherent to the lower thoracic vertebral bodies, though the bone substance was not invaded. The remaining right pleura was opaque throughout, but the left pleurae were normal.

Present address: Department of Histopathology, Northern General Hospital, Sheffield.

Where the tumour was adherent to the chest wall it was white and hyaline, but there was a gradual transition towards a softer buff coloured tumour near to the lung substance.

The thoracic spinal canal contained a nodular thickening of the dural sheaths over several segments but chiefly over the 8th thoracic segment. In places, separate small nodular deposits of tumour were present on the spinal arachnoid sheath. Irregular deposits were present within the substance of the spinal cord, and at T8 the substance of the spinal cord had been virtually replaced by tumour. Thickening of several posterior nerve roots in this region was also noted. All these deposits were similar to the pleural tumour in colour and consistency.

Around the bronchovascular bundles of the right lower lobe were several soft, cream-coloured tumour deposits varying in size up to 2 cm in diameter. Careful dissection of the bronchi failed to reveal a primary origin. Several right hilar lymph nodes were moderately enlarged.

There was no abnormality apart from mild oedema in the remaining lobes of each lung. Metastatic tumour was not present in any other site.

Histology

Tissues taken for histology were fixed in 4% formaldehyde in normal saline, and processed in paraffin wax.

The pleural tumour consisted of fasciculae and whorls of spindle-shaped cells (Fig. 1). In places, these formed cellular areas. The nuclei were plump and vesicular, each with a prominent nucleolus. The cytoplasm was brightly eosinophilic and non-vacuolated. In other areas, chiefly where the tumour joined the chest wall, there were widely scattered irregular clefts lined with low cuboidal epithelium which appeared to merge with the spindle-shaped cells (Fig. 2). There was no Alcian Green or Periodic Acid Schiff-positive material within these clefts, nor within the cytoplasm of the cells. There was no sharp transition between the cell patterns but only a

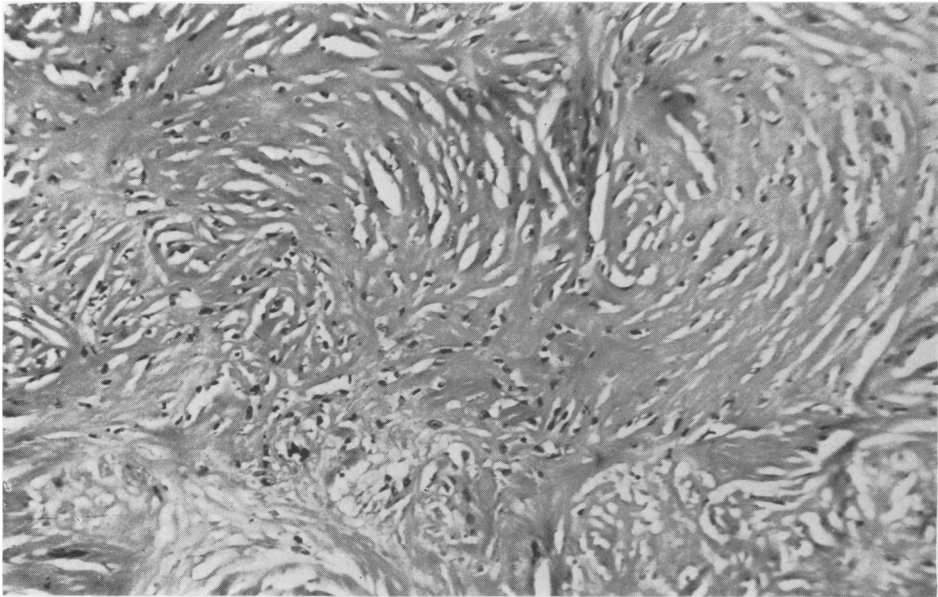


FIG. 1. Pleural mesothelioma showing the sarcomatous component consisting of fasciculae and whorls of collagen fibres in which few nuclei are present. Haematoxylin and Eosin (HE) $\times 240$.

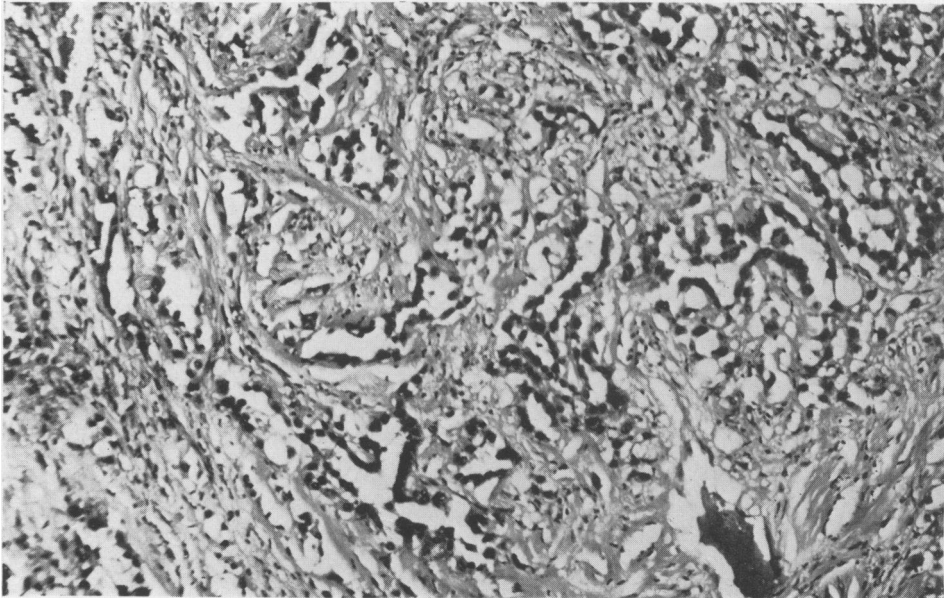


FIG. 2. Pleural mesothelioma showing in another site an epithelial component consisting of clefts lined by low cuboidal cells of epithelial type. HE $\times 240$.

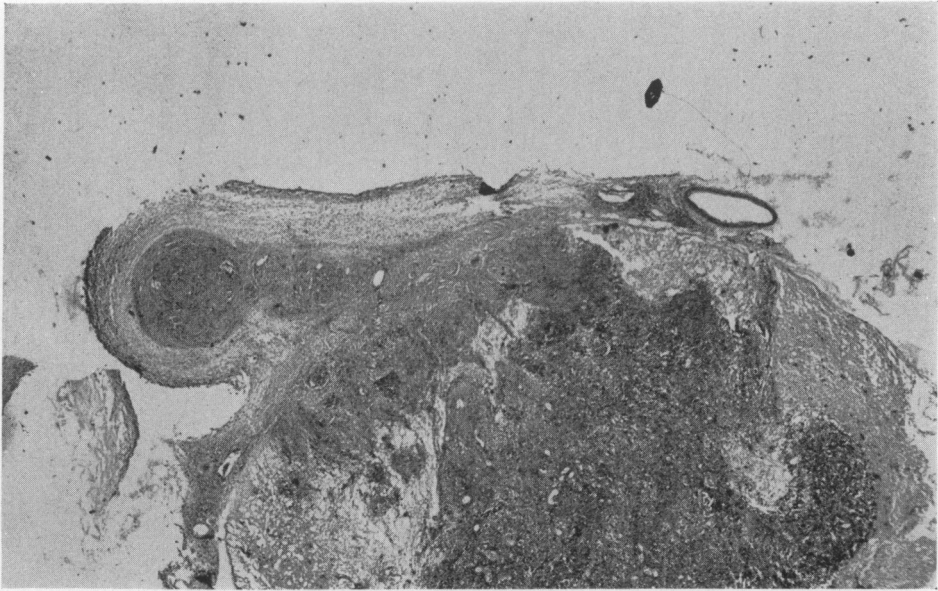


FIG. 3. Spinal cord at 8th thoracic segment showing diffuse infiltration of the central grey matter and posterior nerve root by a sarcomatous mesothelioma. HE \times 9.6.

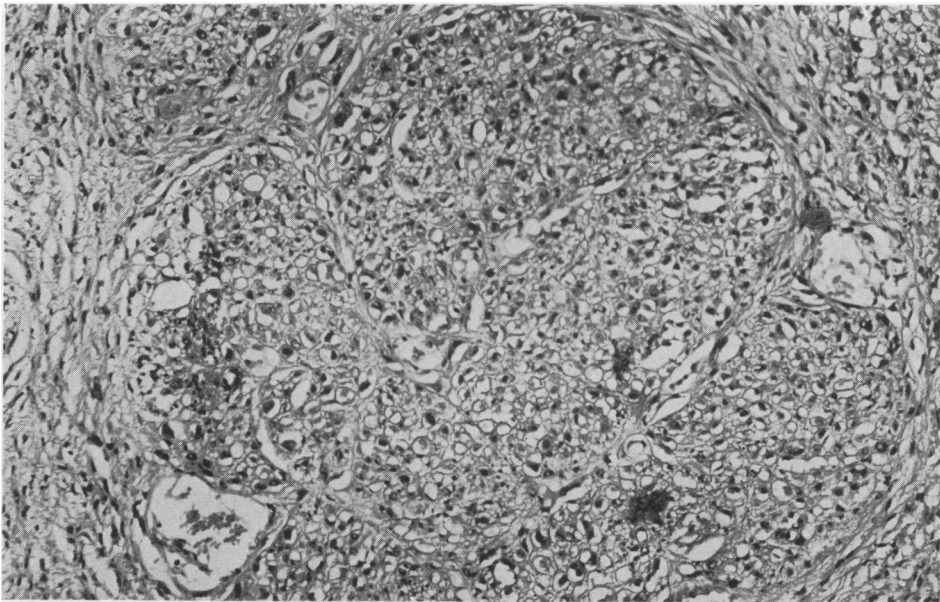


FIG. 4. Spinal cord at 8th thoracic segment showing detail of tumour infiltration, and the presence of a cleft-like space. HE \times 240.

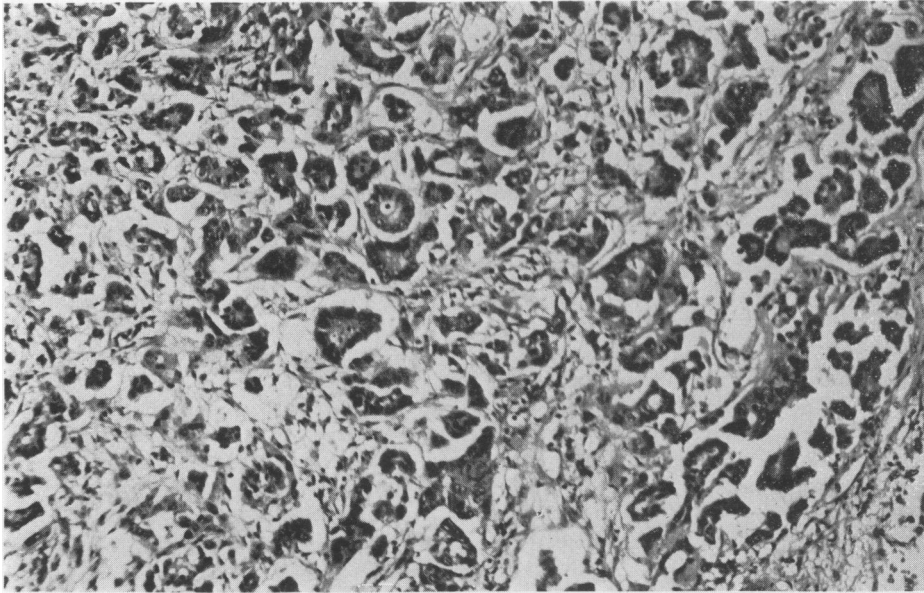


FIG. 5. Part of the pleural mesothelioma infiltrated by an alveolar cell carcinoma, which is clearly distinct from the epithelial lined clefts illustrated in Fig. 2. HE $\times 240$.

gradual transition. Very few mitoses were seen. An attempt was made to demonstrate hyaluronic acid as described by Wagner *et al.* (1962), but without success as the tissues had been fixed in formalin. However, the histological appearances were of a mesothelioma, and it is not always possible to demonstrate hyaluronic acid in such tumours (Whitwell and Rawcliffe, 1971).

The spinal nerve roots were diffusely infiltrated and largely destroyed by a confluent spindle cell tumour similar to that described above in the pleura, though only an occasional epithelial cleft was present in this situation (Figs. 3 and 4). In the 8th thoracic segment of the spinal cord a discrete irregular focus of similar spindle cell tumour had completely replaced the central grey matter. Other foci of spindle cell tumour were present within the central grey matter in adjacent segments. These deposits were surrounded by the remains of posterior and anterolateral columns. Many of the myelin sheaths were ballooned and a slight proliferation of astrocytes was present.

A further cellular pattern was present in parts of the pleural tumour quite distinct from the spindle cell arrangement already described. These consisted of foci of plump polygonal cells of epithelial type forming discrete glandular spaces (Fig. 5). Papillae covered by a single or double layer of similar epithelial cells projected into some of these glandular spaces. Within a few of these spaces, Alcian Green

and PAS-positive material was present indicating mucin of epithelial type. Thus, the appearances of this area of tumour differed from the spindle-shaped areas of the adjacent mesothelioma. It was apparent, therefore, that a second tumour was present having the appearance of an alveolar cell carcinoma of the lung.

An exhaustive search for asbestos bodies was made from sections of each lobe of lung and several blocks of tumour but no asbestos bodies were identified, neither was there any fibrosis or cavitation within the lung parenchyma.

The pulmonary deposits in the right lower lobe and within hilar lymph nodes were similar to the alveolar cell carcinoma. Similar tumour was seen permeating lymphatics including those within peribronchiolar connective tissue.

The appearances of the pleural tumour were those of a diffuse malignant pleural mesothelioma, which had been infiltrated by a multifocal peripheral alveolar cell carcinoma. The mesothelioma metastasized to structures within the spinal cord; the alveolar cell carcinoma had infiltrated lung tissue and hilar lymph nodes.

Discussion

The occurrence of primary malignant tumours of the pleura, though vigorously contested by Willis (1938, 1952, 1967), is now well recognized and there are numerous convincing reports of malignant

mesotheliomas occurring in the pleura (McCaughey, 1958), peritoneum (Winslow and Taylor, 1960) and pericardium (Dawe, Wood and Mitchell, 1953). A benign pleural mesothelioma was described by Klemperer and Rabin (1931).

The case reported here is of special interest both for its mode of presentation and also because of the presence of two primary tumours. Diffuse malignant mesothelioma normally spreads by infiltrating contiguous structures, though extension beyond its cavity of origin and distant metastases do occur (Whitwell and Rawcliffe, 1971). In this case there was extension along spinal nerve roots and spread over the meningeal surfaces within the spinal canal. However, the presence of multiple discrete foci of tumour deposits within the substance of the spinal cord cannot be explained by contiguous spread. It would seem that blood-borne spread, via the spinal branches of the posterior intercostal arteries, had occurred to give this distribution of metastases. Infiltration of structures within the spinal canal is a very rare occurrence. A review of the recent literature has revealed only the three cases of Razer, Pool and Melamed (1967) though no autopsy details were given. Semb (1963) records a case infiltrating the vertebral foramina but not the spinal cord. Nixon, Wolfenden and Hirst (1964) record a case involving the spinal dura, and presenting as acute paraplegia. Whitwell and Rawcliffe (1971) mention a case metastasizing to the meninges of the middle cranial fossa. They also mention thirteen other cases of blood-borne metastases and suggest that the incidence of metastases in mesothelioma appears to be increasing. The view that mesothelioma does not spread via the blood-stream no longer seems tenable.

The occurrence of two readily identifiable tumours arouses special interest in the light of Willis's contention (1938, 1952). As recently as 1967 he asserted that a primary tumour in the lung or an abdominal viscus is present in most cases and that, having metastasized to serosal surfaces, evokes an intense fibrous reaction, thus obscuring the true histological appearance of the tumour. He regards true primary tumours of serosal surfaces as histological curiosities. The view does not explain the association with asbestos dust exposure, the occasional cures effected by the removal of a localized though histologically malignant pleural mesothelioma, or the significantly longer survival of patients with mesothelioma as compared with those with carcinoma of bronchus.

The pleomorphism of mesothelioma is well recognized and has been shown by Klemperer and Rabin (1931) and Stout and Murray (1942) by means of tissue culture to be due to the pleuripotentiality of mesothelial cells. McCaughey (1958) subdivided them into four histological categories, epithelial,

mesenchymal, anaplastic and mixed cell type. This case would fall into the latter type.

It has recently been established that mesotheliomas of the pleura and peritoneum are associated with the occupational exposure to asbestos dust (Hourihane, 1964; Newhouse and Thompson, 1965; Selikoff, Churg and Hammond, 1965; Whitwell and Rawcliffe, 1971). Exposure need not have been heavy and may have taken place many years previously (Owen, 1964). Studies by Cauna, Totten and Gross (1965) have shown that asbestos bodies are present in 40% of the population of industrial areas. Wagner (1962) has demonstrated experimentally that mesotheliomas can be produced by injecting asbestos dust into pleural cavities of mice. This case showed no evidence of asbestos dust exposure, though the thoroughness of searching may be open to question. However, there was no evidence of fibrosis or cyst formation within the lung parenchyma, which are frequently associated with asbestos exposure. Cases of mesothelioma in which asbestos bodies have not been found have been reported (Whitwell and Rawcliffe, 1971). In the Portsmouth area malignant mesothelioma is diagnosed once in 1300 autopsies and asbestos bodies were readily identifiable in only two-thirds of the cases.

The case demonstrates that an alveolar cell carcinoma of the lung and a malignant pleural mesothelioma can co-exist and give distinct histological features. It is known that there is a high incidence of carcinoma of the lung and bronchus among asbestos workers (Selikoff *et al.*, 1965), so in those cases associated with asbestos exposure a common aetiology for mesothelioma and alveolar cell carcinoma does exist. Although this case was not associated with asbestos exposure, an as yet unidentified aetiological factor could have produced the two tumours. Spencer (1962) has recognized the coexistence of mesothelioma and alveolar cell carcinoma of lung.

Acknowledgments

I am grateful to Professor Spencer of St Thomas' Hospital for his confirmation of the histology, also to Mr R. V. Bone for his technical assistance, and to Dr J. Burston of Central Laboratory, Portsmouth, for helpful criticism.

References

- CAUNA, D., TOTTON, R.S. & GROSS, P. (1965) Asbestos bodies in human lungs at autopsy. *Journal of the American Medical Association*, **192**, 5.
- DAWE, C.J., WOOD, D.A. & MITCHELL, S. (1953) Diffuse mesothelioma of the pericardium. Report of a case and a review of the literature. *Cancer*, **6**, 794.
- HOURIHANE, D. O'B. (1964) The pathology of mesothelioma and an analysis of the association with asbestos exposure. *Thorax*, **19**, 268.
- KLEMPERER, P. & RABIN, C.B. (1931) Primary neoplasms of the pleura. A report of 5 cases. *Archives of Pathology*, **11**, 385.

- MCCAUGHEY, W.T.E. (1958) Primary tumours of the pleura. *Journal of Pathology and Bacteriology*, **86**, 517.
- NEWHOUSE, M.L. & THOMPSON, H. (1965) Mesothelioma of the pleura and peritoneum following exposure to asbestos dust in the London area. *British Journal of Industrial Medicine*, **22**, 261.
- NIXON, P.F., WOLFENDEN, W.H. & HIRST, E. (1964) Paraplegia and destruction of the ribs. *Medical Journal of Australia*, **1**, 207.
- OWEN, W.G. (1964) Diffuse pleural mesothelioma and exposure to asbestos dust in the Merseyside area. *British Medical Journal*, **2**, 214.
- RATZER, E.R., POOL, J.L. & MELAMED, M.R. (1967) Pleural mesotheliomas. Clinical experience in 37 patients. *American Journal of Roentgenology, Radium Therapy, and Nuclear Medicine*, **99**, 863.
- SELIKOFF, I.J., CHURCH, J. & HAMMOND, E.C. (1965) Relation between asbestos exposure and neoplasia. *New England Medical Journal*, **272**, 560.
- SEMB, G. (1963) Diffuse pleural mesothelioma. A clinico-pathological study of 10 fatal cases. *Acta chirurgica scandinavica*, **126**, 78.
- SPENCER, H. (1962) *Pathology of the Lung*, p. 730. Pergamon Press: London.
- STOUT, A.P. & MURRAY, M.R. (1942) Localized pleural mesothelioma. Investigations of its characteristics and histogenesis by the method of tissue culture. *Archives of Pathology*, **34**, 951.
- WAGNER, J.C., MUNDAY, D.E. & HARRINGTON, J.S. (1962) Histochemical demonstration of hyaluronic acid in pleural mesotheliomas. *Journal of Pathology and Bacteriology*, **84**, 73.
- WAGNER, J.C. (1962) Experimental production of mesothelial tumours of the pleura by implantation of dusts in laboratory animals. *Nature*, **196**, 180.
- WILLIS, R.A. (1938) A metastatic deposit of bronchial carcinoma in a hydrocoel misdiagnosed 'endothelioma', with a review of supposed 'endotheliomas' of serosal membranes. *Journal of Pathology and Bacteriology*, **47**, 253.
- WILLIS, R.A. (1952) *Spread of Tumours in the Human Body*. First edition, pp. 55. London.
- WILLIS, R.A. (1967) *Pathology of Tumours*. Fourth edition, pp. 181. London.
- WINSLOW, D.J. & TAYLOR, H.B. (1960) Malignant pleural mesotheliomas. A clinico-pathological analysis of 12 cases. *Cancer*, **13**, 127.
- WHITWELL, F. & RAWCLIFFE, R.N. (1971) Diffuse malignant pleural mesothelioma and asbestos exposure. *Thorax*, **26**, 1.

Postgraduate Medical Journal (November 1974) **50**, 723-725.

Antepartum diagnosis of vasa praevia—report of a case causing sudden foetal death

C. S. PALLEWELA
M.B., M.R.C.O.G.

Maternity Hospital, South Shields

Summary

A case of sudden foetal death due to vasa praevia is reported. The main problem is early ante-partum diagnosis. Three methods are discussed.

(1) Tests to recognize foetal blood as a routine in ante-partum haemorrhage;

(2) amnioscopy before amniotomy; in foetal irregularity or bradycardia; in ante-partum haemorrhage;

(3) tests for foetal bradycardia in early labour as a part of the routine abdominal examination.

Introduction

Vasa praevia is a rare obstetric complication which must be kept in mind as a rare cause of ante-partum haemorrhage. Less than a hundred cases

Reprint requests to: Dr C. S. Pallewela, Hemel Hempstead General Hospital, Hemel Hempstead, Herts.

have been reported in the literature. It causes two symptoms—foetal bradycardia when a vessel is compressed, and a haemorrhage when the vessel is torn. Severe bradycardia will lead to Caesarean section for foetal distress of probably 'unknown' origin—the infant may be saved, the cause of the foetal distress only being apparent on inspection of the placenta after the operation.

Haemorrhage is dangerous to the foetus because the blood-loss is of foetal origin. What would be considered an insignificant haemorrhage if the blood-loss was maternal in origin would be lethal to the infant when foetal blood was lost—as illustrated by this case, where the foetal heart failed with the very first bout of bleeding. One difficulty in the management of ante-partum haemorrhage is to exclude the possibility of the blood-loss being of foetal origin.