

## Ulcerative colitis with chronic liver disease, eosinophilia and auto-immune thyroid disease

STEPHEN P. KANE  
M.A., B.M., M.R.C.P.

Royal Postgraduate Medical School, Hammersmith Hospital, London W12 0HS

### Summary

A patient with chronic mild ulcerative colitis is described. Her illness was characterized by fluctuating blood eosinophilia, chronic persistent hepatitis and hypersensitivity to sulphasalazine. She subsequently developed auto-immune thyroid disease. The inter-relationships of these various disorders are discussed.

### Introduction

While there are well established associations between ulcerative colitis and chronic liver diseases, between active chronic hepatitis and thyroid disease, and between ulcerative colitis and blood and tissue eosinophilia, a patient in whom all these features were manifested has not hitherto been described. Although it is possible that she had two or more unrelated conditions, it is proposed that she had a multi-system auto-immune disorder.

### Case report

The patient, an Irish nurse, was 41 when in 1967 she developed ulcerative proctitis. Her symptoms, which were mild, responded to symptomatic treatment with codeine phosphate, and she remained well until May 1972 when she was referred to Hammersmith Hospital with 5 weeks of tiredness, myalgia, arthralgia, night sweats and a skin rash. There was no history of foreign travel. On examination she had widespread urticaria, the liver was not felt but the spleen just palpable. The results of investigations were as follows: Hb 12.3 g/100 ml; WBC 8000/ $\mu$ l (eosinophils 2640/ $\mu$ l); ESR 60 mm/hr; IgG 2600 mg/100 ml (normal 500-1600); IgA 450 mg/100 ml (normal 125-425); IgM 200 mg/100 ml (normal 50-180); smooth muscle antibody was strongly positive. The RA latex test, antinuclear factor, LE cell test, cryoglobulins and C<sub>1</sub>q precipitation were all negative. DNA antibody at 4% and C<sub>3</sub> estimation at 100% were both normal. No parasites were in the stool and antibodies to *Toxocara* were negative. Liver studies included serum albumin 4.1 g/100 ml; bilirubin 0.2 mg/100 ml; SGOT 200 u./l

(normal 7-40); ICD 21 i.u. (normal 3-8); alkaline phosphatase 150 mu./l (normal 30-130); Australia antigen and antibody were negative. Studies of the musculoskeletal system including skeletal radiology and muscle biopsy were all normal.

Liver biopsy showed the histological features of chronic persistent hepatitis (Fig. 1). The patient was given no specific therapy, and over the next few months her symptoms remitted spontaneously. The eosinophil count fell to 800/ $\mu$ l, though the liver tests and the ESR remained persistently abnormal.

In July 1973, the patient's diarrhoea recurred with low grade fever and aching in the right hip, and on sigmoidoscopy she was found to have granular proctitis. Rectal biopsy showed acute non-specific inflammation of moderate severity, with Paneth cell metaplasia, and a marked infiltration of the lamina propria with eosinophils. There was again a mild blood eosinophilia (700/ $\mu$ l). Other relevant investigations included Hb 13.8 g/100 ml; ESR 32 mm in 1 hr; serum albumin 4.5 g/100 ml; faecal wet weight 362 g/day; faecal fat 2.7 g/day; Schilling test without intrinsic factor, 22% excretion in 24 hr (normal); IgG 2800 mg/100 ml; GOT 51 u./l; ICD 16 i.u.; PBI 4.0  $\mu$ g/100 ml. Skin testing to common allergens was negative and barium meal and follow-through examination was normal.

Barium enema examination showed no colonic mucosal abnormalities, but on colonoscopy, granularity, punctate haemorrhages and a few superficial ulcers were seen as far as the caecum. Colonic biopsies once again revealed histological features of colitis, with a notable eosinophilic infiltrate.

The patient was started on sulphasalazine 1 g b.d., but was re-admitted 11 days later with a severe generalized non-irritant macular eruption, a fever of 39.5°C and painful swollen knees. Her eosinophil count had risen to 1970/ $\mu$ l. A diagnosis was made of hypersensitivity to sulphasalazine. The drug was discontinued and the rash and fever subsided after 4 days. Treatment was changed to beta-methasone enemata, on which the patient's colitic symptoms settled completely. Her eosinophil count fell to 280/ $\mu$ l, but rose again to 1700/ $\mu$ l when the enemata were discontinued after 2 months.

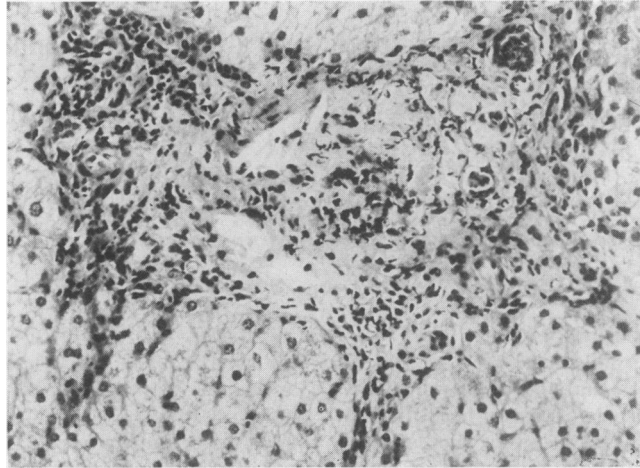


FIG. 1. Needle biopsy of the patient's liver showing infiltration of the portal tracts with plasma cells, lymphocytes and eosinophils. The liver lobules are intact.

In June 1974, the patient complained of weight-gain, tiredness and cold intolerance and of a return of very loose motions. The thyroid gland was impalpable but the tendon reflexes were slow relaxing, consistent with a diagnosis of myxoedema. This was confirmed by the following serological investigations: PBI 2.8  $\mu\text{g}/100$  ml;  $T_4$  43 ng/ml (normal 50–120 ng/ml); TSH  $> 25$   $\mu\text{u.}/\text{ml}$  (normal 1–4  $\mu\text{u.}/\text{ml}$ ). Thyroglobulin precipitins were present and the tanned red cell haemagglutination test for thyroglobulin antibody was positive at a titre of 1/10,000. The smooth muscle antibody test was weakly positive but there were no serum antibodies to gastric parietal cells or to mitochondria.

Haematological investigations showed Hb 11.1 g/100 ml; WBC 7000/ $\mu\text{l}$  (eosinophils 2300/ $\mu\text{l}$ , neutrophils 1470/ $\mu\text{l}$ ); ESR 70 mm in 1 hr. Liver tests were normal apart from ICD 12 i.u. and GOT 48 u./l. On sigmoidoscopy and rectal biopsy there was evidence of exacerbation of her ulcerative colitis.

The patient was treated with nightly betamethasone enemata and with L-thyroxine. Her bowel habit returned promptly to normal and the symptoms and signs of hypothyroidism have resolved. The eosinophil count fell to 870/ $\mu\text{l}$  within 2 weeks and to 440/ $\mu\text{l}$  after 3 months. The patient remains well apart from occasional mild relapses of her ulcerative colitis.

### Discussion

Associations between ulcerative colitis and various types of biochemical and histological liver abnormality are well established. Mistilis and Goulston (1965) and Perrett *et al.* (1971) have emphasized the

frequency of pericholangitis, as well as fatty change, chronic aggressive hepatitis and, more rarely, cirrhosis. On the other hand, Eade (1970) has questioned whether or not true pericholangitis is present in any but a few cases. Many of the hepatic lesions he described would fit into the category of 'chronic persistent hepatitis' and, indeed, Sherlock (1974) considers this histological picture to be a recognized association with ulcerative colitis. While the histological differentiation between chronic 'persistent' and chronic 'active' or 'aggressive' hepatitis is usually clear cut, interpretations of needle biopsies of liver are open to sampling error, particularly from a lesion whose distribution may be patchy (Sherlock, 1974). Although the hepatic disorder in the patient described in this report has run a benign course consistent with the histological finding of chronic persistent hepatitis, it has had some of the serological accompaniments normally associated with chronic aggressive hepatitis—a persistently positive smooth muscle antibody and a substantially raised concentration of serum IgG. Antibodies to thyroglobulin have an increased incidence in women with chronic active hepatitis (Doniach *et al.*, 1966) and there is an increased incidence of thyrotoxicosis and Hashimoto's thyroiditis in these patients (Read, Sherlock and Harrison, 1963; Doniach *et al.*, 1966). This is of particular interest in view of the present patient's myxoedema and the high titre antibody to thyroglobulin in her serum. In series of patients in whom chronic active hepatitis has been the primary problem (Read *et al.*, 1963; Doniach *et al.*, 1966; Mistilis and Blackburn, 1970) ulcerative colitis has occurred in 6–15% of

cases. Other systemic complications shared by some of the patients and the patient reported here include arthralgia and erythematous skin rashes.

The most striking aspect of this patient's illness has been her blood eosinophilia. Her eosinophil count has rarely fallen into the normal range (0–440/ $\mu$ l) and increases in the count have corresponded with exacerbations of her colitis or of her liver disease. There was also a steep rise in the eosinophil count at the time of her presumed hypersensitivity reaction to sulphasalazine; this was similar to the eosinophilia noted with pulmonary allergy to this drug (Jones and Malone, 1972). A mild blood eosinophilia is not uncommon in patients with ulcerative colitis, the counts raising in relapse and falling in remission (Riisager, 1959; Riis and Anthonisen, 1964; Wright and Truelove, 1966) and a blood eosinophilia is seen, but to a lesser extent, in Crohn's disease (Haerberle and Griffen, 1972). Tissue eosinophilia occurs in 80% of patients with ulcerative colitis, and eosinophils are frequently found on cytological examination of the rectal mucus of such patients (Riis and Anthonisen, 1964; Anthonisen and Riis, 1971). In the present case, tissue eosinophilia was marked and the blood eosinophilia was more substantial than that described previously in ulcerative colitis. Other causes of eosinophilia, in particular parasitic infection and immediate type hypersensitivity to common allergens, were excluded. There was no personal or family history of bronchial asthma or allergic rhinitis, and her only manifestations of an allergic diathesis were the widespread urticaria seen on presentation in 1972, and her rash and fever 10 days after starting sulphasalazine.

As well as accompanying many cases of ulcerative colitis, blood eosinophilia is also seen in some patients with chronic active hepatitis, in one case occurring along with a Coombs-positive haemolytic anaemia (Panush, Wilkinson and Fagin, 1973). It has not been noted in chronic persistent hepatitis.

The established associations between thyroid disease and auto-immune liver disease have been discussed. The relationship between thyroid disease and ulcerative colitis is, however, more tenuous. A slight but not statistically significant increase in the incidence of thyroid disease has been noted in patients with ulcerative colitis and their close relatives (Hammer, Ashurst and Naish, 1963). Goligher *et al.* (1968) had ten cases of thyrotoxicosis and none of Hashimoto's thyroiditis among 465 cases of ulcerative colitis. They did not consider that this was any more than a chance association. However, in a recent series of 300 ulcerative colitics and 600 controls (Jarnerot, Azad Khan and Truelove, 1975) there was a significant increase in the incidence of thyrotoxicosis in the colitics. Hypothyroidism, on

the other hand, proved more common in the controls. Antibodies to thyroglobulin were found in the sera of 14% of ulcerative colitics by Taylor (1965) and in 11% by Perrett *et al.* (1971) but these figures do not differ significantly from the incidence of this antibody in a healthy population.

Clearly the occurrence in one patient of two not uncommon disorders, ulcerative colitis and myxoedema, does not justify the assumption that these two diseases are aetiologically related. However, in this instance they were linked with chronic auto-immune liver disease, which has recognized associations both with ulcerative colitis and thyroid disease. It is possible, at least, that a single defect in immune responsiveness predisposed the present patient to develop all the manifestations described here.

#### Acknowledgment

I am grateful to Dr Graham Neale for permission to publish details of this case, and for his helpful advice in the preparation of this report.

#### References

- ANTHONISEN, P. & RIIS, P. (1971) Eosinophilic granulocytes in the rectal mucus of patients with ulcerative colitis and Crohn's disease of the ileum and colon. *Scandinavian Journal of Gastroenterology*, **6**, 731.
- DONIACH, D., ROITT, I.M., WALKER, J.G. & SHERLOCK, S. (1966) Tissue antibodies in primary biliary cirrhosis, active chronic (lupoid) hepatitis, cryptogenic cirrhosis and other liver diseases, and their clinical implications. *Clinical and Experimental Immunology*, **1**, 237.
- EADE, M.N. (1970) Liver disease in ulcerative colitis. I. Analysis of operative liver biopsy in 138 consecutive patients having colectomy. *Annals of Internal Medicine*, **72**, 475.
- GOLIGHER, J.C., DE DOMBAL, F.T., WATTS, J. MCK. & WATKINSON, G. (1968) *Ulcerative Colitis*, p. 114, Baillière, Tindall and Cassell, London.
- HAEBERLE, M.G. & GRIFFEN, W.O. (1972) Eosinophilia and regional enteritis. A possible diagnostic aid. *American Journal of Digestive Diseases*, **17**, 200.
- HAMMER, B., ASHURST, P. & NAISH, J. (1968) Diseases associated with ulcerative colitis and Crohn's disease. *Gut*, **9**, 17.
- JARNEROT, G., AZAD KHAN, A.K. & TRUELOVE, S.C. (1975) The thyroid in ulcerative colitis. II. Thyroid enlargement and hyperthyroidism in ulcerative colitis. *Acta medica scandinavica*, **197**, 83.
- JONES, G.R. & MALONE, D.N.S. (1972) Sulphasalazine-induced lung disease. *Thorax*, **27**, 713.
- MISTILIS, S.P. & GOULSTON, S. (1965) Liver disease in ulcerative colitis. In: *Recent Advances in Gastroenterology* (Ed. by J. Badenoch and B. N. Brooke), p. 227. Churchill, London.
- MISTILIS, S.P. & BLACKBURN, C.R.B. (1970) Active chronic hepatitis. *American Journal of Medicine*, **48**, 484.
- PANUSH, R.S., WILKINSON, L.S. & FAGIN, R.R. (1973) Chronic active hepatitis associated with eosinophilia and Coombs-positive haemolytic anaemia. *Gastroenterology*, **65**, 1015.
- PERRETT, A.D., HIGGINS, G., JOHNSON, H.H., MASSARELLA, G.R., TRUELOVE, S.C. & WRIGHT, R. (1971) The liver in ulcerative colitis. *Quarterly Journal of Medicine*, **40**, 211.

- READ, A.E., SHERLOCK, S. & HARRISON, C.V. (1963) Acute 'juvenile' cirrhosis considered as part of a systemic disease and the effect of corticosteroid therapy. *Gut*, **4**, 378.
- RIIS, P. & ANTHONISEN, P. (1964) Eosinophilia in peripheral blood and inflammatory exudate in non-specific proctocolitis. *Acta medica scandinavica*, **175**, 85.
- RIISAGER, P.M. (1959) Eosinophil leucocytes in ulcerative colitis. *Lancet*, **ii**, 1008.
- SHERLOCK, S. (1974) Chronic hepatitis. *Gut*, **15**, 581.
- TAYLOR, K. (1965) Immune mechanisms in gastroenterology. In: *Recent Advances in Gastroenterology* (Ed. by J. Badenoch and B. N. Brooke), p. 24. Churchill, London.
- WRIGHT, R. & TRUELOVE, S.C. (1966) Circulating and tissue eosinophils in ulcerative colitis. *American Journal of Digestive Diseases*, **11**, 831.

*Postgraduate Medical Journal* (February 1977) **53**, 108-110.

## Behçet's syndrome with perforations of the colon

K. HAAVIK NILSEN†  
M.D., M.R.A.C.P.

S. M. JONES\*  
F.R.C.S.

B. A. SHOREY\*  
F.R.C.S.

*Department of Medicine, and \*Department of Surgery, University of Bristol and  
†Royal National Hospital for Rheumatic Diseases, Bath*

### Summary

A case of Behçet's syndrome with mucosal ulcerations of the ascending colon and three perforations of the caecum is described. It is the first documented case of this syndrome where colitis has occurred without concomitant rectal lesions. The reported cases of Behçet's syndrome with associated colonic lesions make up a heterogeneous group. It is suggested that the different patients may have suffered from pathogenetically different diseases.

### Introduction

Behçet's syndrome consisted initially of recurrent iritis with genital and oral ulcerations. Since Behçet's description in 1937 many other manifestations have been added to the original triad. They include various skin lesions, arthritis, orchitis, epididymitis, venous and arterial thrombosis, pericarditis and various lesions of the central nervous system (CNS) and the gastrointestinal tract (Chajek and Fainaru, 1975). Except for the commonly occurring uveitis, which almost invariably leads to blindness (Watson, 1975), the syndrome usually runs a relatively benign course. The only reported life-threatening manifestations are some of the rare CNS (Fadli and Youssef, 1973) and gastrointestinal (Empey, 1972) lesions.

A case of Behçet's syndrome and right-sided colitis with perforations of the caecum is now described. The colonic manifestations of the syndrome are discussed and an attempt is made to

delineate the nature of colonic involvement in Behçet's syndrome.

### Case report

A 28-year-old welder had suffered over the last 13 years with recurrent, painful mouth ulcers, especially frequently during the last 3 years. In 1973 and 1974 he attended a venereology clinic for associated ulcerations of the penis. Venereal disease was excluded and no cause was found for the penile ulceration. In August 1973 he suffered an attack of right-sided orchitis. A few days after treatment with cephalixin was started, he suddenly developed an erythema nodosum-like rash on the legs and the arms associated with fever and aching joints. This cleared spontaneously. No cause was found for the rash but hypersensitivity to cephalixin was suspected. He had, however, later taken cephalixin without side effects. In March 1974, he developed a left-sided orchitis. An erythema nodosum-like rash appeared this time before any antibiotic was given. It cleared following a course of prednisolone. Since then he suffered several attacks of erythema nodosum. During the months March, April and May 1975 the rash reappeared every second to third week. Each attack lasted 4-5 days, and he was treated intermittently with prednisolone. He started to be troubled with increasing backache and arthralgia of the fingers, wrists, right elbow and right knee both at the times he had the rash and in the periods between. Left-sided sacro-iliitis was found on