

Skeletal abnormalities in homocystinuria

D. P. BRENTON
M.D., M.R.C.P.

Department of Human Metabolism, University College Hospital Medical School, University Street, London

Summary

The skeletal changes of thirty-four patients with the biochemical and clinical features of cystathionine synthase deficiency are described. It is emphasized that there is clinical evidence of excessive bone growth and the formation of bone which is structurally weaker than normal. The similarities and differences between this condition and Marfan's syndrome are stressed and the possible nature of the connective tissue defect leading to the skeletal changes discussed. The most characteristic skeletal changes in homocystinuria are the skeletal disproportion (pubis-heel length greater than crown-pubis length), the abnormal vertebrae, sternal deformities, genu valgum and large metaphyses and epiphyses.

HOMOCYSTINURIA due to deficiency of the enzyme cystathionine synthase is an inborn error of amino acid metabolism affecting the pathway between methionine and cysteine. The sulphur containing amino acids methionine, cysteine and cystine all occur in dietary protein. Cysteine is a sulphhydryl compound and cystine its disulphide derivative. Du Vigneaud (1952) and others proved in mammals that there is a metabolic pathway from methionine to cysteine along which methionine sulphur is converted to cysteine sulphur—the 'trans-sulphuration pathway'—before being catabolized in a series of steps to inorganic sulphate. Homocysteine, another sulphhydryl compound, is an intermediate on the transulphuration pathway. Its corresponding disulphide is homocystine. The accumulation of homocysteine in plasma and urine is a consequence of cystathionine synthase deficiency because homocysteine is not utilized with serine to form cystathionine (Fig. 1). The excretion of homocysteine in the urine also occurs in some other inborn errors affecting the remethylation of homocysteine back to methionine which may also be impaired in vitamin B₁₂ deficiency.

Correspondence: Dr D. P. Brenton, Thorn Senior Lecturer, Department of Human Metabolism, University College Hospital Medical School, University Street, London WC1E 6JJ.

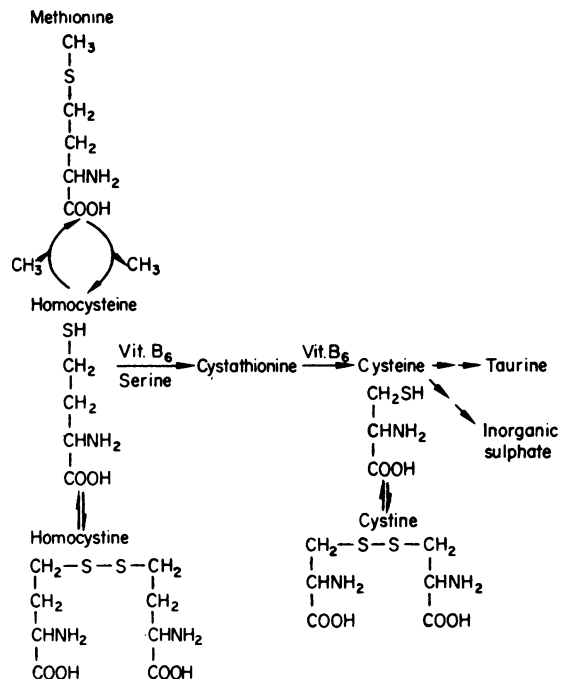


FIG. 1. The conversion of methionine to cysteine via homocysteine. The pathway has been simplified.

The four cardinal clinical features of cystathionine synthase deficiency are lens dislocation, mental retardation, skeletal abnormalities and a thrombotic tendency. Not all the patients show all of these features. Lens dislocation and very similar skeletal abnormalities occur in Marfan's syndrome. Marfan (1896) originally described an unusual girl with bizarre skeletal abnormalities and marked arachnodyctyly. Lens dislocation was not recognized as part of the syndrome until some years later and neither were the aortic complications. The purpose of this paper is to concentrate on the skeletal abnormalities in cystathionine

TABLE 1. Skeletal abnormalities in homocystinuria

Total number of patients	34
High palate	25
Scoliosis (usually mild)	11
Pectus carinatum	9
Pectus excavatum	11
Genu valgum	10
Pes cavus	17
Pes planus	2
Arachnodactyly	5
Joint abnormalities	7

synthase deficiency and to review these in a series of thirty-four patients seen at University College Hospital. Some of the data on the first twenty-two patients have already been reported (Brenton *et al.*, 1972).

The variability of the physical abnormalities

In patients only mildly affected, the lens dislocation may be present possibly associated with a slightly abnormal ratio between the height of the upper and lower body segments. The patient may otherwise appear normal. For example the Indian patient illustrated by Brenton *et al.* (1972) had lens dislocation and mild pes cavus but normal intelligence and no other abnormality. He remains well and illustrates that cystathionine synthase deficiency occurs in other races. Another very normal looking patient is illustrated in Fig. 2. He has a normal IQ, only minimal bone changes and lens dislocation. Family screening of urine samples revealed an affected sister sixteen years old without lens dislocation and of normal IQ.

In severely affected patients lens dislocation occurs with mental retardation of varying severity. Such patients have marked skeletal changes of the kind discussed below. Fair hair and a rather cyanotic malar flush may be present but these are not constant and the cause of the flush is uncertain. Major thrombotic episodes may occur both in arteries and veins. A severely affected patient is illustrated in Fig. 3. In general, the severity of the disease tends to be similar in affected siblings, either both mild or both severe, but this is not entirely true, as illustrated in the two sisters in Fig. 4. The very severely affected sister has a gross scoliosis and loss of extension at the elbows and finger joints. Her IQ is extremely low and she knows only two or three words. The less severely affected sister has an IQ of about 60 and is able to earn her living in a simple job as a packer. Her skeletal abnormalities are much milder. The reason for this difference between siblings is not clear.

Growth and stature

In normal white children the crown-pubis length

is longer than the pubis-heel length in infancy but the legs grow relatively quicker than the trunk so that the crown-pubis and pubis-heel lengths become equal at about the age of 7 years and then remain so throughout life. This equality may be disturbed by some physiological events such as an unusually late puberty when the legs become relatively long or by diseases which affect growth of legs or trunk. Skeletal disproportion is a cardinal feature of older patients with homocystinuria (Fig. 5), the pubis-heel length being invariably longer than the crown-pubis length. The extent of this disproportion is underestimated in Fig. 5 because the data of McKusick were obtained by measuring the standing height, the pubis-heel length in the standing position and the crown-pubis length calculated by difference. Standing tends to shorten the trunk length and so lowers the ratio in normal subjects appreciably below unity. The measurements of the patients with homocystinuria were made in the lying position. Skeletal disproportion is also a cardinal feature of Marfan's syndrome. In both conditions there seems to be an excessive growth of long bones probably more marked in Marfan's syndrome since arachnodactyly does not seem very common in homocystinuria. An excessive growth of long bones in homocystinuria is indicated by the height measurements (Fig. 6). Only five of the thirty-four patients have heights on the 50th centile or below including the patient in Fig. 4 whose height is really meaningless because of the scoliosis. Almost 50% of the patients are on the 95th centile or over. In homocystinuria (unlike Marfan's syndrome) vertebral abnormalities actually shorten the crown-pubis length (see below) and contribute to the skeletal disproportion. The growth curves illustrated in Fig. 7 show the development of the disproportion in a child who did not respond biochemically to pyridoxine and so has remained biochemically abnormal throughout her growth.

Physical deformities and radiological changes

The incidence of the commonest physical abnormalities is listed in Table 1. They are considered here with the radiological changes. No abnormalities are noted in the head and skull except for some large sinuses in one or two patients and a high palate which seems to be a common feature but is a different physical sign and may have been overdiagnosed. Severe scoliosis is not usual but milder degrees of scoliosis are quite common. Radiologically vertebral changes are usually present. The vertebrae are thin indicating that osteoporosis is present. Only in one patient however have crush fractures occurred (see Brenton *et al.*, 1972 for illustration and Fig. 8). The vertebrae commonly appear flatter than usual and elongated anteroposteriorly with a rather

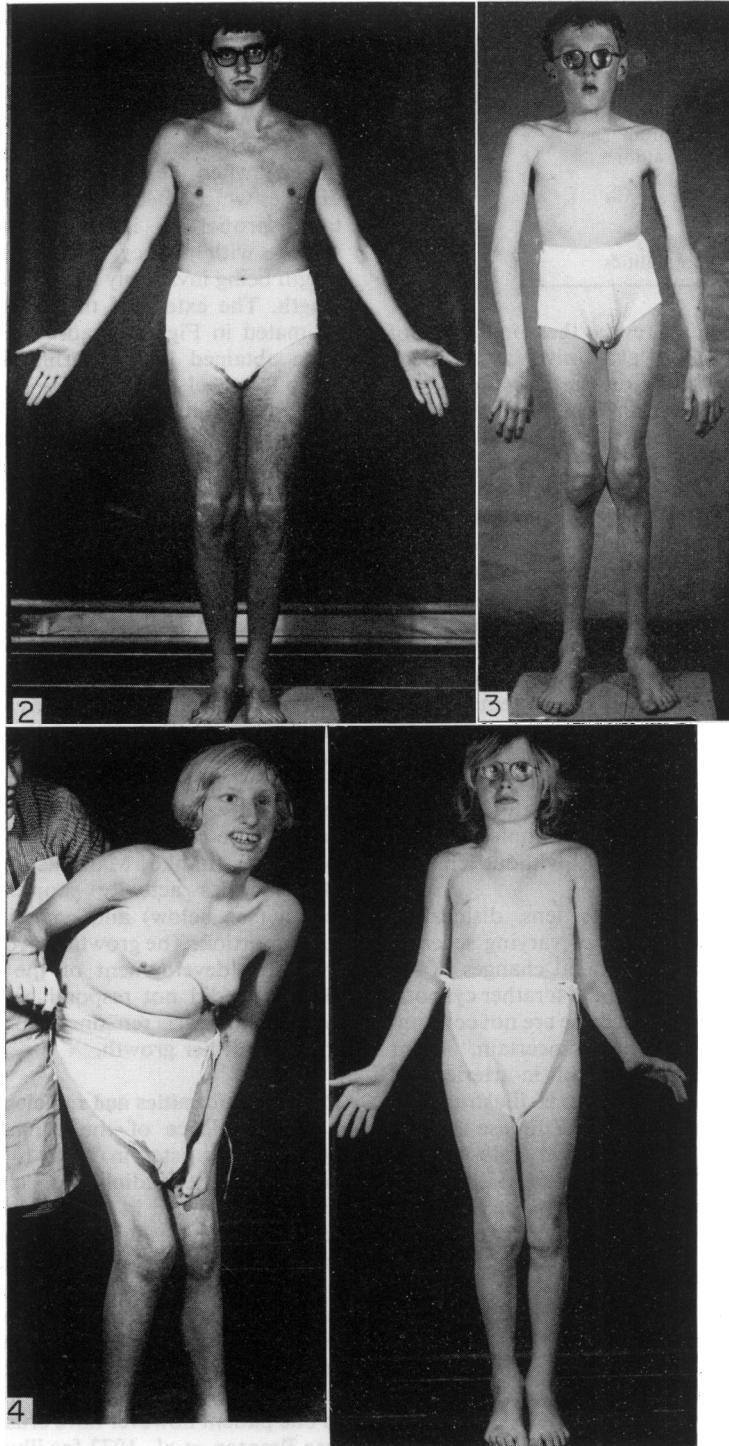


FIG. 2. Patient D.W. Age 23 years.

FIG. 3. Patient J.Cr. Age 11 years. Note the short trunk and long legs.

FIG. 4. Affected sisters H.D. (right) and S.D. (left). Note the much more severe skeletal abnormalities in S.D. compared to her sister.

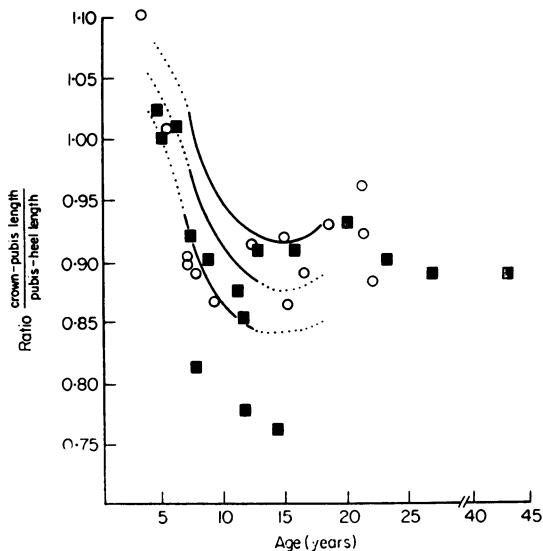


FIG. 5. The ratio of crown-pubis length to pubis-heel length measured in the lying position in patients with homocystinuria. The lines for normal subjects are redrawn from the data of McKusick (1966) and represent the normal mean, -1 and -2 s.d. ■, male patients; ○, female patients.

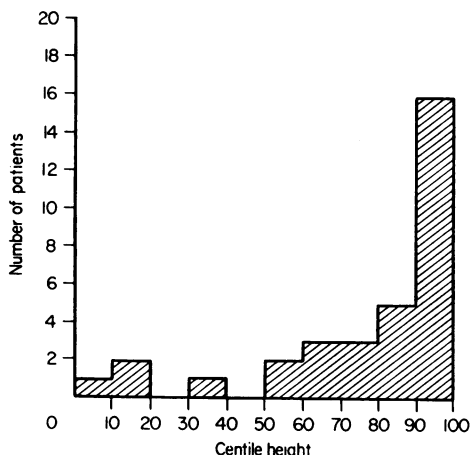


FIG. 6. Distribution of centile heights in the patients with homocystinuria. Since most of the patients are growing children the distribution of their final centile heights is not yet known. The centile height of patient S.D. (Fig. 4) is omitted (see text for explanation).

posteriorly placed biconcave deformity. These are not normal vertebrae which have become osteoporotic and then crushed but vertebrae which do not grow and develop normally in the childhood years. The relative flatness and biconcavity presumably indicate failure to attain normal structural strength and

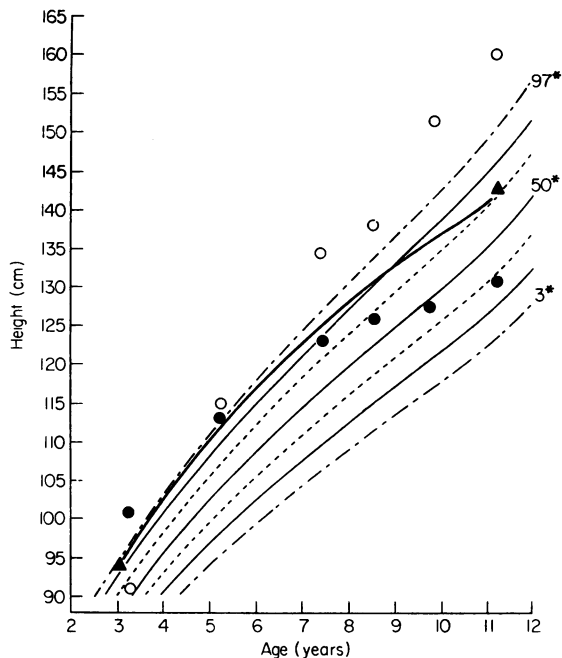


FIG. 7. Growth curve in the patient Ca.G: Note the relatively fast growth of the legs and the poor growth of the trunk. ▲—▲, standing height; ●, crown-pubis length (lying); ○ pubis-heel length (lying).

the long anteroposterior diameter an abnormal degree of growth. Clinically there are no detectable abnormalities in the hips and pelvis but radiologically there are changes which are variable from patient to patient. The femoral heads may appear very large and the femoral necks wide. Sometimes the femoral necks are unduly long (Fig. 9). Widening of the metaphyses of the long bones is a marked feature of cystathionine synthase deficiency (Fig. 10, and also Brenton *et al.*, 1972). This is most easily seen at the knees and parents of affected children sometimes comment that they had noticed the large knees. Genu valgum is common. Surgical correction by osteotomy with subsequent immobilization may lead to serious venous thrombosis as happened in two of the patients in this series. These changes at the hips and knees are also those of abnormal growth. Although in some of the children the long bones show thinness of cortical bone there has been no particular predisposition to long bone fractures so that the degree of osteoporosis has not been severe. Perhaps the sternal changes also reflect excessive growth in the ribs. Excessive growth of the metacarpals and phalanges causes the arachnodactyly which is not a feature of most patients but occurs in some. Other changes in connective

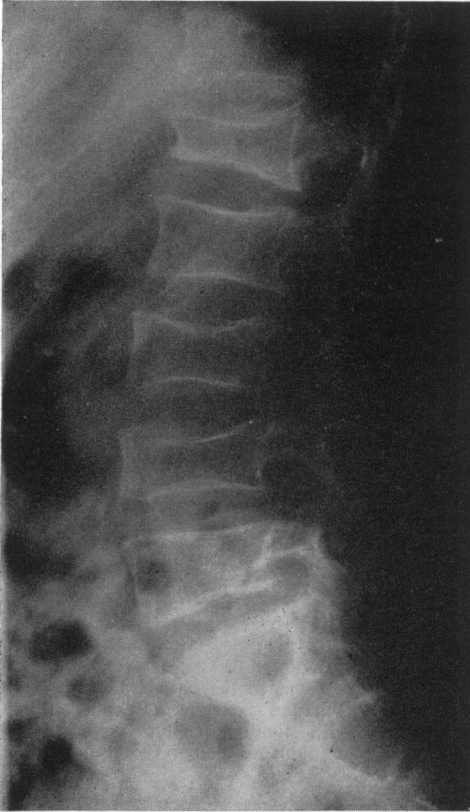

FIG. 8. Lateral lumbar spine in patient J.Cr. Note the wedged L1 vertebra which is a true crush fracture.

tissues presumably cause the joint abnormalities which have been noted, namely limited extension at the elbows, limited supination of the forearms and fixed flexion of the fingers usually slight but sometimes severe (Fig. 4).

Discussion

It is interesting to speculate about the cause of these skeletal changes because Marfan's syndrome and cystathionine synthase deficiency have a number of skeletal features and lens dislocation in common, it is possible that they have some connective tissue defect in common. Such a defect would presumably be the result of quite different primary biochemical abnormalities. The similarities of the skeletal defects should not hide the fact that there are differences particularly in the vertebrae. Moreover life expectation in Marfan's syndrome is less than normal mostly because of serious aortic and cardiac defects (McKusick, 1972). Aortic dissection apparently does not occur in cystathionine synthase deficiency and this might also indicate that the connective tissue defect in the two conditions is dissimilar. This piece of evidence however is difficult to evaluate because of the surprisingly few patients over 30 years of age with cystathionine synthase deficiency reported in the literature. Most patients with Marfan's syndrome do not develop aortic dissection until after this age. It could be that aortic dissection might occur in older patients who are cystathionine synthase-deficient. The lack of such patients both in the literature and in the series discussed here can only mean that either older patients with lens dislocation

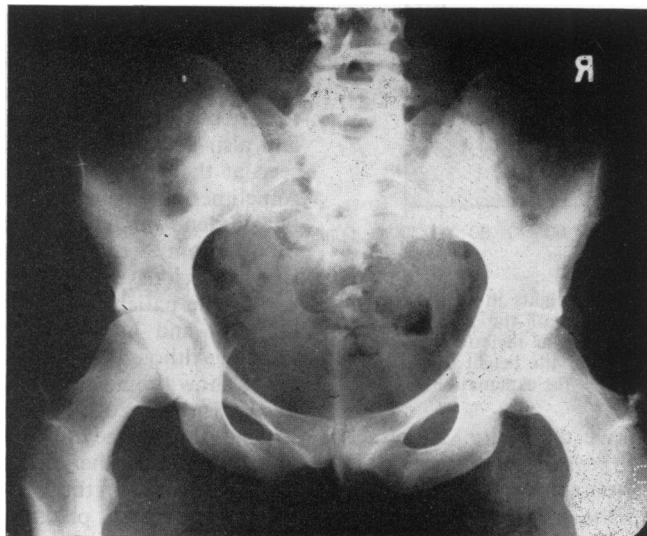


FIG. 9. Pelvis of patient L.Th. The femoral necks are elongated.

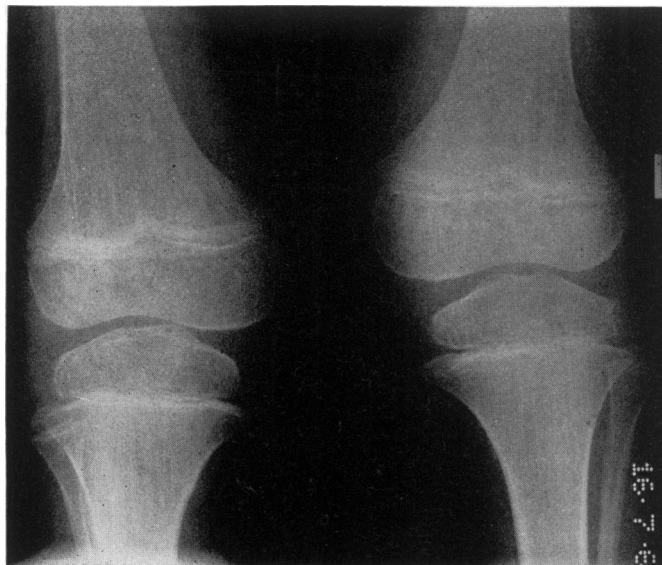


FIG 10. Knees of patient G.C. Note the wide metaphyses.

are not being tested for the presence of homocystine in the urine or the prognosis of the untreated condition is so poor that relatively few survive to the fourth decade and beyond. Thrombosis is undoubtedly the main threat to survival.

There is appreciable experimental evidence that sulphur amino acids with a sulphhydryl group may affect collagen structure. Most of the experimental work has been done with penicillamine which is β,β' -dimethylcysteine and therefore has structural similarities to cysteine and homocysteine. Penicillamine cysteamine and other aminothiols reduce the tensile strength of skin and tendon experimentally and probably do so by reacting with the aldehyde groups formed from hydroxylysine residues in the collagen peptide chain (Pinnel and Martin, 1968). It is possible that homocysteine may act in a similar way. Kang and Trelstad (1973) investigated solutions of collagen which were heated to 37°C to form a gel. The gel forms as cross links are made between the aldehyde groups originally formed from the hydroxylysine residues. The gel is normally stable on cooling. In the presence of homocysteine a stable gel is not formed indicating some interference with the cross-linkage mechanism. The significance of the experiments to the pathology of cystathionine synthase deficiency is uncertain because the concentration of homocysteine used is about 100 times that found in the plasma of affected patients. One disease which

quite definitely interferes with the cross linkage process has been described in which the collagen is hydroxylysine-deficient (Pinnell *et al.*, 1972). These patients have recurrent joint dislocation which is not a feature of cystathionine synthase deficiency and do not have lens dislocation which is usual in cystathionine synthase deficiency. It is therefore reasonable to question whether the skeletal changes of cystathionine deficiency are due to a direct effect of homocysteine on collagen and to remember that a stimulant effect of homocysteine on the formation of sulphated proteoglycans has also been described (Dehnel and Francis, 1972).

References

- BRENTON, D.P., DOW, C.J., JAMES, J.I.P., HAY, R.L. & WYNNE-DAVIES, R. (1972) Homocystinuria and Marfan's syndrome. *Journal of Bone and Joint Surgery*, **54B**, 277.
- DEHNEL, J.M. & FRANCIS, M.J.O. (1972) Somatomedin (sulphation factor)-like activity of homocystine. *Clinical Science*, **43**, 903.
- DU VIGNEAUD, V. (1952) *A Trail of Research in Sulphur Chemistry and Metabolism and Related Fields*. Cornell University Press, Ithaca, New York.
- KANG, A.H. & TRELSTAD, R.L. (1973) A collagen defect in homocystinuria. *Journal of Clinical Investigation*, **52**, 2571.
- McKUSICK, V.A. (1966) *Heritable Disorders of Connective Tissue*, 3rd edn. C. V. Mosby Co. Ltd, St Louis.
- McKUSICK, V.A. (1972) *Heritable Disorders of Connective Tissue*, 4th edn. C. V. Mosby Co. Ltd, St Louis.

- MARFAN, A.B. (1896) Un cas de déformation congénitale des quatre membres plus prononcée aux extrémités caractérisée par l'allongement des os avec un certain degré d'amincissement. *Bulletin mensuel de la Société Médicale des Hôpitaux de Paris*, 13, 220.
- PINNELL, S.R., KRANE, S.M., KENZORA, J.E. & GLIMCHER, M.J. (1972) A heritable disorder of connective tissue: hydroxylysine-deficient collagen disease. *New England Journal of Medicine*, 286, 1013.
- PINNELL, S.R., & MARTIN, G.R. (1968) The cross linking of collagen and elastin: enzymatic conversion of lysine in peptide linkage to α -amino adipic-delta-semialdehyde. *Proceedings of the National Academy of Sciences of the United States of America*, 61, 708.