

Abdominal aortic aneurysms

Ultrasonic measurement of the transverse diameter and its prognostic significance in the light of pathological observations

J. C. MCGREGOR
B.Sc., M.B., Ch.B., F.R.C.S.

Stobhill Hospital, Glasgow

Summary

The risk of rupture of an abdominal aortic aneurysm is related to size. Pathological observations suggest that there is usually an asymmetric formation of mural thrombus in the aneurysm sac and that rupture occurs more commonly through the lateral walls where there would be less. Ultrasonic estimation of the transverse diameter of an aneurysm offers a useful clinical method of monitoring size and likelihood of rupture.

ABDOMINAL aortic aneurysms continue to give rise to diagnostic and management controversy. With the increase in atherosclerotic disease and the average life expectancy of the population, the condition has become more common. Following the first successful surgical repair of an aneurysm by Dubost, Allary and Deconomos (1952) steady improvements in surgical techniques have been made; yet problems still arise regarding the diagnosis and assessment. Linked with this is a lack of understanding regarding the mode of formation, rate of growth, and causation of rupture.

Ultrasonography has been shown to be of considerable value in the diagnosis and assessment of both intact and ruptured abdominal aortic aneurysms (McGregor, Pollock and Anton, 1975a, b). It may not be available in all hospitals, of course, but where it is, it can offer a reliably quick and safe method with accuracy acceptable for most clinical purposes. Using a very simple Kretz scanning device it is possible to depict an abdominal aortic aneurysm in both longitudinal and transverse scans and measure the antero-posterior and corresponding transverse diameter. The antero-posterior diameters were measured by means of the A scan while the transverse diameters were estimated by proportion from the composite transverse B scan picture at the position where the A scan had measured the other

diameter (Figs 1 and 2). One of the possible sources of inaccuracy noted in the technique was the difficulty in measuring the aortic wall thickness due to adjacent non-aortic echoes. It was concluded that the measurement of the intraluminal diameters was accurate and, provided it was assumed that any rupture was more likely to occur through a thin wall, then the errors would be slight. (From a clinical point of view it is, of course, the risk of rupture that is important once an aneurysm has been identified.)

It is now apparent that abdominal aortic aneurysms tend to increase in size with time and when a certain size is attained the liability to rupture is increased greatly (Crane, 1955; Gliedman, Ayers and Vestal, 1957; Sommerville, Allen and Edwards, 1959). Most of the authors of such studies failed to describe exactly which diameters were measured or how they were measured.

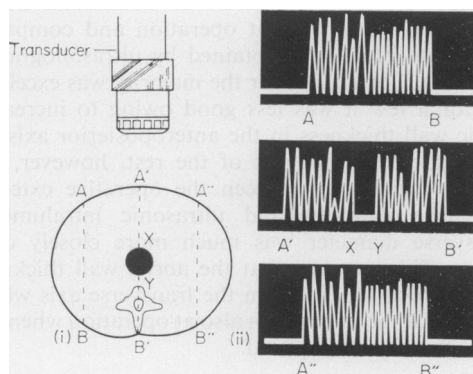


FIG. 1. Diagram in theory of the transverse A scan. (i) Representation of a transverse section of aorta. (ii) Theoretical A scan from which measurements of the antero-posterior intraluminal diameter can be measured. The wall thickness in this axis can be estimated provided clear differentiation can be made between wall and adjacent non-aortic echoes.

As a result of some further clinical and pathological observations on the relative distribution of aortic wall thrombus in aneurysms, it now seems to be reasonable to discuss these together with previous ultrasonic results.

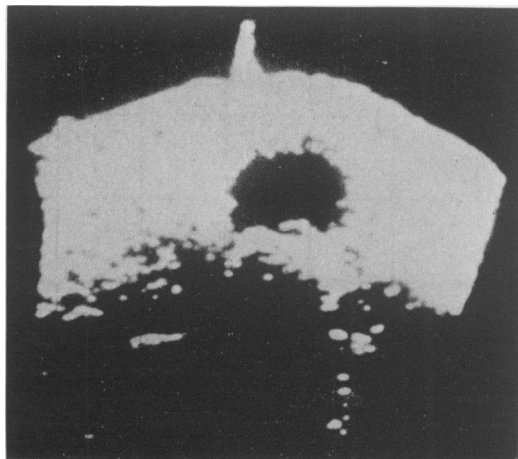


FIG. 2. Transverse B scan of an abdominal aortic aneurysm at 4 cm above the umbilicus. The upward vertical blip represents the position of the midline axis on the anterior abdominal wall. The clear area represents the lumen of a medium-sized abdominal aortic aneurysm lying to the left of the umbilicus. From the corresponding A scan at this level the intraluminal antero-posterior diameter equalled 4.9 cm. By proportion, using this value and the B scan picture, the transverse intraluminal diameter equalled 9.8 cm.

Results

Ultrasonic study

Measurements of a series of abdominal aortic aneurysms were made at operation and compared with those previously obtained by ultrasonography (Table 1). Correlation for the majority was excellent but for a few it was less good owing to increased aortic wall thickness in the anteroposterior axis. In these cases and in most of the rest, however, the overall correlation between the operative external transverse diameter and ultrasonic intraluminal transverse diameter was much more closely consistent. This suggests that the aortic wall thickness tended to be much less in the transverse axis which was indeed the impression also at operation when the aneurysm sac was opened.

Pathological study

1. A retrospective clinicopathological study of unoperated ruptured abdominal aortic aneurysms made over a 10-year period in two large Glasgow hospitals indicated that the most common site for rupture was through the lateral wall (McGregor,

TABLE 1. Abdominal aortic aneurysms: comparison between operative and ultrasonic measurements of diameters (mm). Operative values are for external size while ultrasonic measurements have been taken from intraluminal estimations

Patient	Diameter axis	Operative value (mm)	Ultrasonic difference
1	AP*	42	- 4
	TV	44	- 2
2	AP	45	- 1
	TV	50	- 5
3	AP	60	- 5
	TV	60	- 5
4	AP	50	-12
	TV	50	+ 6
5	AP	70	- 2
	TV	70	+ 5
6	AP	65	- 2
	TV	75	- 5
7	AP	50	-13
	TV	50	+ 2
8	AP	30	+ 2
	TV	30	+ 4
9	AP	45	0
	TV	40	0
10	AP	48	+ 4
	TV	57	- 5
11	AP	75	-30
	TV	70	+ 7
12	AP	65	-12
	TV	58	+ 1
13	AP	45	- 5
	TV	45	- 2
14	AP	64	- 4
	TV	60	0
15	AP	65	-13
	TV	75	0
16	AP	42	- 4
	TV	55	+ 5

* AP = antero-posterior; TV = transverse.

1976). These results are summarized in Table 2. Thick laminated thrombus was noted in many aneurysms but no measurements of wall thickness were made.

2. Two moderately large but intact abdominal aortic aneurysms were obtained from routine post-mortems. They were preserved in formalin for several days and then sectioned transversely so that a consecutive series of sections were obtained. These sections showed asymmetric deposition of wall thrombus (Figs 3a, b and 4) with most in the anteroposterior axis and relatively less in the transverse axis across the lumen. Similar asymmetry of deposition of mural thrombus has been depicted by Edwards (1961).

Discussion

Sumner, Hokanson and Strandness (1970) stated that little was known about the causes of an aneurysm or about the physical nature of the aneurysm wall. Rupture appears to occur at the point where the protein fibres separate or become attenuated as to be unable to withstand the arterial pulse pressure. Peterson, Jensen and Parnell (1960) pointed out that the tangential stress on the arterial wall was directly proportional to the arterial pulse pressure and aneurysm diameter and inversely proportional to the thickness of the arterial wall.

Theoretically then an increase in diameter of an aneurysm or a thinning of some portion of the aneurysm wall should increase the risk of rupture. There is good evidence in the literature that liability to this complication is related to the size of the aneurysm. Crane (1955) first brought attention to the importance of aneurysm diameter in prognosis. The risk was found to be greater in aneurysms more than 7 cm in diameter. Gliedman *et al.* (1957) and Sommerville *et al.* (1959) produced similar conclusions in their studies. Wolffe and Colcher (1966) found that the risk of rupture for an aneurysm less than 4.5 cm in diameter was in the range of 1%. While Baker and Munns (1975) agreed with all these observations, they pointed out that in their own

series a significant number of ruptures occurred in aneurysms with transverse diameters between 5 and 7.5 cm. It would seem likely, therefore, that the risk of rupture is very small for aneurysms less than 5 cm in diameter but does increase steadily above this as the diameter increases.

TABLE 2. Unoperated ruptured abdominal aortic aneurysms—site of rupture at post-mortem

Site of rupture	No. of cases
Anterior	5
Posterior	4
Right lateral	8
Left lateral	17
Unrecorded	7

Most of these observations were obtained from post-mortem material and, although it was probable that the transverse diameters were used, it is not always clear if this was so. Neither is it clear in all instances how the measurements were made and whether the relative wall thicknesses have been assessed. Iyengar, Lynne and Charrette (1973) stated that lateral tomography of the abdomen centred on the lumbosacral spine in patients with aneurysms offered an excellent method of assessing and

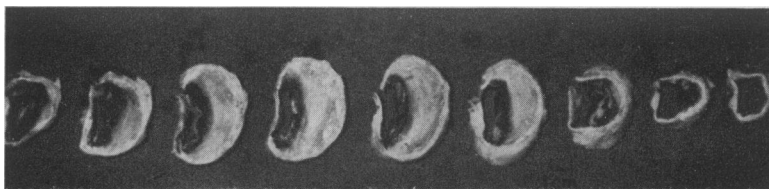


FIG. 3a. Patient I. Autopsy specimen fixed in formalin. Serial transverse sections of unruptured infrarenal aortic aneurysm. The proximal sections lie at the right of the photograph and are each approximately 1 cm thick. The lowest section was obtained just above the aortic bifurcation, the upper just below the renals.

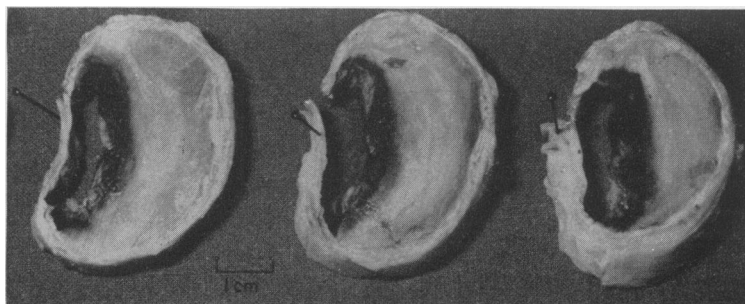


FIG. 3b. Patient I. Close up of middle sections of aneurysm sac. The anterior surfaces lie at the right. Note the asymmetric mural thrombus with thin walls adjacent to lateral aspect of the lumen and marked thrombus in the anterior wall.

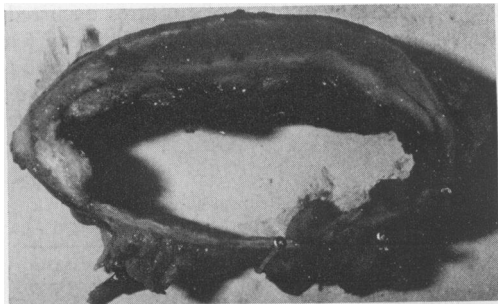


FIG. 4. Patient II. Representative transverse section of a moderate-sized intact abdominal aortic aneurysm obtained at post-mortem. The maximum intramural thrombus is in the anteroposterior axis.

managing this condition. This method estimates the antero-posterior diameter and also suffers from the deficiency that it depends on the presence of calcification in the aortic wall (only present in about 50% of aneurysms). Ultrasonic estimations are not subject to these limitations and offer the same advantages of quickness, safety and non-invasiveness.

From the observations made in this report it is suggested that the measurement of the transverse diameter of an aneurysm by ultrasonography in the clinical situation is extremely valuable with regard to prognosis. This information may then be used in the overall assessment of any particular individual when elective surgery is being considered. Since the measurement of the wall thickness appears likely to be less important in the transverse axis than in the antero-posterior axis due to the asymmetric mural thrombus deposition, the ultrasonic intraluminal transverse estimation may in fact be even more precise and useful.

Acknowledgments

I thank Dr S. Rao, Consultant Pathologist, Stobhill

Hospital, for providing the pathology specimens: Mr J. G. Pollock, Consultant Surgeon, Glasgow Royal Infirmary, for his helpful advice; and Dr Craig Anton, Consultant Radiologist, Stobhill Hospital, Glasgow, for instruction and guidance in ultrasonic techniques.

The Editor of the *Scottish Medical Journal* kindly agreed to allow the use of information already published in 1975.

References

- BAKER, W.H. & MUNNS, J.R. (1975) Aneurysmectomy in the aged. *Archives of Surgery*, **110**, 513.
- CRANE, C. (1955) Arteriosclerotic aneurysms of the abdominal aorta. *New England Journal of Medicine*, **253**, 194.
- DUBOST, U.M., ALLARY, M. & DECONOMOS, M. (1952) Resection of an aneurysm of the abdominal aorta. *Archives of Surgery*, **65**, 405.
- EDWARDS, J.E. (1961) In: *An Atlas of Acquired Diseases of the Heart and Vessels*, Vol. III, p. 1011. W. B. Saunders Company, Philadelphia and London.
- GLIEDMAN, M.L., AYERS, W.B. & VESTAL, B.L. (1957) Aneurysms of the abdominal aorta and its branches. A study of untreated patients. *Annals of Surgery*, **146**, 207.
- IYENGAR, S.R.K., LYNN, R.B. & CHARRETTE, E.P. (1973) The use of lateral tomography in patients with abdominal aortic aneurysms. *Surgery, Gynecology and Obstetrics*, **137**, 235.
- MCGREGOR, J.C., POLLOCK, J.G. & ANTON, H.C. (1975a) The value of ultrasonography in the diagnosis of abdominal aortic aneurysm. *Scottish Medical Journal*, **20**, 133.
- MCGREGOR, J.C., POLLOCK, J.G. & ANTON, H.C. (1975b) Ultrasonography and possible ruptured abdominal aortic aneurysm. *British Medical Journal*, **3**, 78.
- MCGREGOR, J.C. (1976) Unoperated ruptured abdominal aortic aneurysms: a retrospective clinicopathological study over a 10 year period. *British Journal of Surgery*, **63**, 113.
- PETERSON, L.H., JENSEN, R.E. & PARNELL, J. (1960) Mechanical properties of arteries *in vivo*. *Circulation Research*, **8**, 622.
- SOMMERVILLE, R.I., ALLEN, E.V. & EDWARDS, J.E. (1959). Bland and injected arteriosclerotic abdominal aortic aneurysms. A clinico-pathologic study. *Medicine*, **38**, 207.
- SUMNER, D.S., HOKANSON, B.S. & STRANDNESS, D.E. (1970) Stress-strain characteristics and collagen-elastin content of abdominal aortic aneurysms. *Surgery, Gynecology and Obstetrics*, **130**, 459.
- WOLFFE, J.B. & COLCHER, R.E. (1966) Diagnosis and conservative treatment of atherosclerotic aneurysms of the abdominal aorta. *Vascular Disease*, **3**, 49.