

# 'Brugada ECG' elicited by imipramine overdose

M.P. van den Berg, J.E. Tulleken, A.A.M. Wilde

The ECG hallmark of the Brugada syndrome is ST-segment elevation in the right precordial leads. However, a 'Brugada ECG' may also occasionally be caused by other conditions. We report a case of a Brugada ECG due to an overdose of imipramine, a tricyclic antidepressant. The patient, a 66-year-old woman, was admitted to the emergency unit in a comatose state, due to auto-intoxication with imipramine. In addition to other signs of massive sodium-channel blockade, the ECG showed typical ST-segment elevation in the right precordial and the inferior leads. The abnormalities resolved quickly after administration of sodium bicarbonate. (*Neth Heart J* 2004;12:404-6.)

Key words: Brugada syndrome, imipramine overdose, ST-segment elevation

The Brugada syndrome is a clinical and electrocardiographic (possibly) familial entity which may lead to sudden cardiac death due to ventricular fibrillation.<sup>1,2</sup> The ECG hallmark is ST-segment elevation in the right precordial leads, with or without right bundle branch block. However, a 'Brugada ECG' may also occasionally be caused by other conditions, for example acute myocardial infarction, myocarditis and pulmonary embolism. We report here a case of a Brugada ECG due to an overdose of imipramine, a tricyclic antidepressant.

---

**M.P. van den Berg**

Department of Cardiology, Thorax Centre, Groningen University Hospital, Groningen

**J.E. Tulleken**

Department of Internal Medicine, Intensive and Respiratory Care Unit, Groningen University Hospital, Groningen

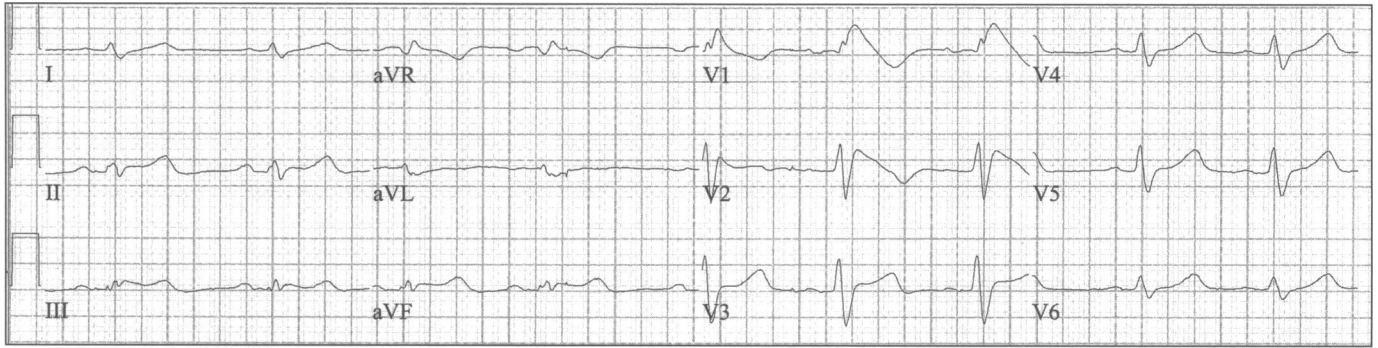
**A.A.M. Wilde**

Department of Cardiology, Academic Medical Centre, Amsterdam

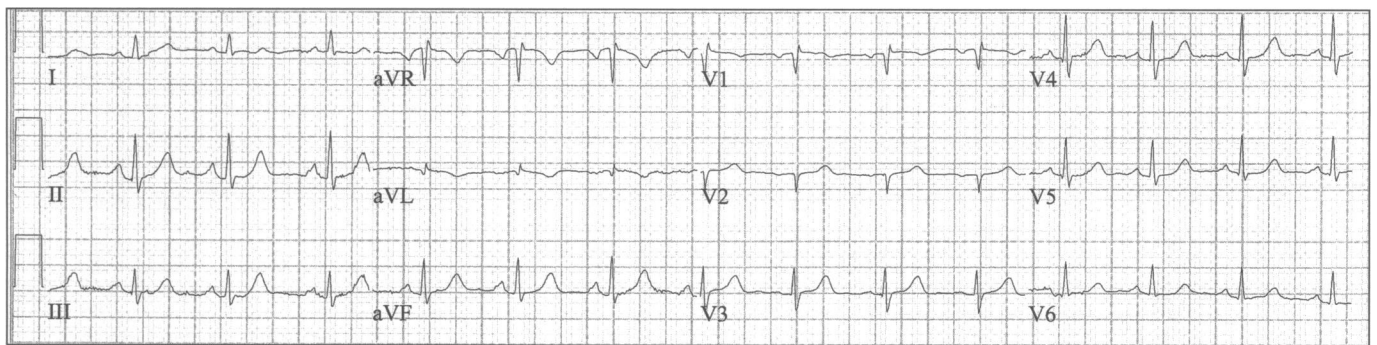
Correspondence to: M.P. van den Berg  
Department of Cardiology, Thorax Centre, Groningen University Hospital, Hanzeplein 1, 9713 GZ Groningen  
E-mail: m.p.van.den.berg@thorax.azg.nl

**Case report**

A 66-year-old woman was admitted to the emergency unit in a comatose state (E-M-V=1-4-2). Besides a history of depression and chronic obstructive pulmonary disease due to heavy smoking, the medical history was unremarkable. Central temperature was 35.8°C, blood pressure was 80/40 mmHg and ventilation was slightly depressed but not sufficient to necessitate mechanical ventilation. Electrolytes (including potassium, magnesium, calcium), cardiac markers (including troponin) and pH were all within normal limits. Echocardiographic findings were also normal; in particular, there were no wall motion abnormalities and no signs of cor pulmonale. The ECG showed sinus bradycardia, low voltage, flat and broad P waves, first-degree AV block, widening of the QRS complex with a right bundle branch-like pattern, ST-segment elevation in the right precordial and inferior leads, and prolongation of the QT interval and the JT interval (figure 1). Because (auto)intoxication was suspected, serum toxicological screening was performed, revealing very high levels of imipramine and desimipramine: values were 1460 µg/l and 1170 µg/l, respectively (therapeutic range imipramine plus desimipramine 150 to 250 µg/l). The patient was treated temporarily with fluid infusion (NaCl 0.9%) and low-dose noradrenaline, which quickly caused the blood pressure to normalise. In addition, magnesium sulphate (2 x 750 mg) and sodium bicarbonate (1.4% 2l/24 hours) were administered. Within a few hours the patient regained consciousness and within the same timeframe the gross ECG abnormalities disappeared. The patient was discharged from hospital in good health two days after admission. Of note, during the entire observation period, no (ventricular) arrhythmias were observed. Six weeks after discharge, the patient visited the outpatient clinic for further investigations. Detailed history taking did not reveal a personal or familial history of syncope or (aborted) sudden death. The ECG (figure 2) was virtually normal with the possible exception of inadequate septal activation and minor right ventricular conduction delay. The flecainide test (2 mg/kg iv) did not reproduce the ST-



**Figure 1.** ECG on admission. Please note: 1) sinus bradycardia, 2) low voltage, 3) flat and broad P waves, 4) first-degree AV block, 5) widening of the QRS complex with a right bundle branch-like pattern, 6) ST-segment elevation in the right precordial and inferior leads, and 7) prolongation of the QT interval and the JT interval.



**Figure 2.** ECG in the outpatient clinic. The ECG is virtually normal with the possible exception of inadequate septal activation and minor right ventricular conduction delay.

segment elevation. Finally, the gene encoding the cardiac sodium channel (SCN5A) was screened (using SSCP); no mutations were found.

### Discussion

When confronted with a patient with a Brugada ECG, the diagnostic evaluation should be directed toward excluding causes of the ST-segment elevation other than Brugada syndrome (table 1).<sup>2</sup> In particular, arrhythmogenic right ventricular cardiomyopathy should be excluded, which may prove difficult given the similarities between this disorder and Brugada syndrome. After excluding the other causes of the Brugada ECG, Brugada syndrome should be strongly considered in case of documented ventricular fibrillation or self-terminating polymorphic ventricular tachycardia, syncope, a family history of sudden cardiac death at young age or family members with a Brugada ECG.

The electrophysiological disorder underlying the Brugada syndrome is a disturbed balance between inward and outward ion currents, leading to transmural heterogeneity in action potential duration, particularly in the right ventricle.<sup>3</sup> A reduced inward sodium current ( $I_{Na}$ ) is deemed to play a central role in this connection. Several mutations in SCN5A have been reported in the Brugada syndrome.<sup>4</sup> Sodium-channel blockers, such as ajmaline and flecainide, may

enhance ST-segment elevation, and they are therefore used to unmask the Brugada syndrome in patients at risk.

Given the above physiology, it is conceivable that other agents with sodium channel blocking properties may also cause ST-segment elevation, in particular when supraphysiological serum levels are attained. These agents include the tricyclic antidepressants, which are known for their 'membrane stabilising' (quinidine-like) properties.<sup>5</sup> Indeed, several cases have

**Table 1.** Most frequent causes of ST-segment elevation in the right precordial leads other than Brugada syndrome.

Right or left bundle branch block, left ventricular hypertrophy
Myocardial infarction
Myocarditis
Pulmonary embolism
Central and autonomic nervous system abnormalities
Hyperkalaemia
Hypercalcaemia
Tricyclic antidepressant overdose
Cocaine intoxication
Arrhythmogenic right ventricular cardiomyopathy
Early repolarisation and other normal variants

been reported showing that tricyclic antidepressant overdose may elicit a Brugada ECG in otherwise healthy subjects.<sup>6,7</sup> In addition, in a systematic review of 98 consecutive cases of cyclic antidepressant overdose in 95 patients, Goldgran-Toledano and co-workers reported that a Brugada ECG was present in as many as 15 cases.<sup>8</sup> Our case, which represents another example of a Brugada ECG elicited by tricyclic antidepressant overdose, warrants several comments, both in terms of diagnosis and therapy. First, the ST-segment elevation was not confined to the right precordial leads, but was also apparent in the inferior leads. This phenomenon has been reported previously in the Brugada syndrome,<sup>9</sup> but it is a relatively rare finding. Second, the other ECG abnormalities were also remarkable. In particular, the ECG findings (flat and broad P waves, first-degree AV block, widening of the QRS complex) were compatible with severe generalised conduction delay secondary to massive sodium-channel blockade. Although the Brugada syndrome may also be associated with some degree of generalised conduction delay, the abnormalities are usually not very marked.<sup>2</sup> Given these severe abnormalities, we argued that administration of sodium bicarbonate would be appropriate.<sup>5</sup> Indeed, the ECG abnormalities resolved quickly, that is, much quicker than would be expected according to the  $T_{1/2}$  of imipramine and desimipramine (20 hours). Finally, there were also signs of potassium channel blockade as indicated by the prolongation of the JT interval. JT-interval prolongation may occur in the Brugada syndrome,<sup>10</sup> but in this instance potassium-channel blockade by (des)imipramine as the main underlying mechanism is not unlikely,<sup>5</sup> in particular given the extremely high serum levels. We therefore decided also to administer magnesium sulphate.

Provocation with flecainide did not reproduce the ST-segment elevation. The degree of sodium-channel blockade as obtained with a 'physiological' dose of flecainide was probably not enough. If anything, the flecainide test supported our notion that the Brugada ECG in this instance was due to the extremely high

serum levels of (des)imipramine, possibly aggravated to some extent by pre-existent minor conduction disease, but that the patient did not have a Brugada syndrome. Of note, the fact that SCN5A was not mutated was not decisive in this connection, since mutations in SCN5A are found in only a minority of patients (approximately 20%) with established Brugada syndrome. ■

#### Acknowledgement

We are indebted to W. Nieuwland and H. Potthoff for providing us with valuable clinical data.

#### References

- 1 Brugada P, Brugada J. Right bundle branch block, persistent ST segment elevation and sudden cardiac death: a distinct clinical and electrocardiographic syndrome. A multicenter report. *J Am Coll Cardiol* 1992;20:1391-6.
- 2 Wilde AAM, Antzelevitch C, Borggrefe M, Brugada J, Brugada R, Brugada P, et al. for the Study Group on the Molecular Basis of Arrhythmias of the European Society of Cardiology. Proposed diagnostic criteria for the Brugada syndrome. Consensus report. *Circulation* 2002;106:2514-9.
- 3 Wilde AAM, Alings AMW, Wever EFD, Derksen R, Hauer RNW. Het ene rechterbundeltakblock is het andere niet. *Cardiologie* 1998;5:380-3.
- 4 Tan HL, Bezzina CR, Smits JPP, Verkerk AO, Wilde AAM. Genetic control of sodium channel function. *Cardiovasc Res* 2003;57:961-73.
- 5 Marshall JB, Forker AD. Cardiovascular effects of tricyclic antidepressant drugs: therapeutic usage, overdose and management of complications. *Am Heart J* 1982;103:401-14.
- 6 Bolognesi R, Tsialtas D, Vasini P, Conti M, Manca C. Abnormal ventricular repolarization mimicking myocardial infarction after heterocyclic antidepressant overdose. *Am J Cardiol* 1997;79:242-5.
- 7 Rouleau F, Asfar P, Boulet S, Dube L, Dupuis JM, Alquier P, et al. Transient ST segment elevation in right precordial leads induced by psychotropic drugs: relationship to the Brugada syndrome. *J Cardiovasc Electrophysiol* 2001;12:61-5.
- 8 Goldgran-Toledano D, Sideris G, Kevorkian JP. Overdose of cyclic antidepressants and the Brugada syndrome. *N Engl J Med* 2002;346:1591-2.
- 9 Potet F, Mabo P, Log G, Probst PV, Schott JJ, Airaud F, et al. Novel Brugada SCN5A mutation leading to ST segment elevation in the inferior or the right precordial leads. *J Cardiovasc Electrophysiol* 2003;14:200-3.
- 10 Pitzalis MV, Anaclerio M, Iacoviello M, Forleo C, Guida P, Troccoli R, et al. QT-prolongation in right precordial leads: an additional hallmark of Brugada syndrome. *J Am Coll Cardiol* 2003;42:1632-7.