

CA15–3: a reliable indicator of metastatic bone disease in breast cancer patients

D P O'Brien MMedSci FRCSI
Surgical Registrar

P G Horgan MCh FRCS FRCSI
Senior Registrar in Surgery

D B Gough MCh FRCSI
Senior Registrar in Surgery

R Skehill AIMLS
Laboratory Technician

H Grimes MSc PhD MBA
Consultant Biochemist

H F Given MSc MCh FACS FRCSI
Professor of Surgery

Departments of Clinical Biochemistry and Surgery, University College Hospital, Galway, Ireland

Key words: CA15–3; Breast cancer; Bone metastases

Carcinoma of the breast is the most common malignancy in women and is frequently associated with metastatic bone disease and its associated osteolytic morbidity and mortality. Traditional radiological methods for mass screening bony secondaries are not cost-effective. We examined the value of the tumour marker 'CA15–3' as an alternative to conventional isotope bone scintigraphy. A total of 218 patients with breast cancer was evaluated over a 4-year period. Venous CA15–3 levels were obtained at 3-monthly intervals and bone scintigraphy annually or if the patient developed locomotor symptoms or exhibited elevated CA15–3 levels.

Of these patients, 33 with metastatic breast carcinoma had an elevated tumour marker level at the time of diagnosis of their metastases; bone metastases alone = 15/17 (88%), soft tissue metastases alone = 2/6 (33%), simultaneous bony and soft tissue metastases = 7/10 (70%). The preponderance of an elevated CA15–3 in metastatic bone disease, be it in isolation or in combination with non-bone metastases, yields a sensitivity, specificity and positive predictive value of 81.5%, 66% and 92%, respectively. Although 22 of the 27 patients had an elevated CA15–3 at the time of diagnosis of their bone metastases, the remaining five patients (with tumour marker levels in the normal range) showed a similar, albeit a delayed, increase (median = 3 months). Thus, all metastatic bone disease patients demonstrated elevated marker levels.

We recommend CA15–3 as a simple, reliable and inexpensive screening method for detecting bone metastases in the patient with breast carcinoma.

Approximately 6% of women with breast carcinoma have skeletal metastases at presentation, but up to 85% of women with breast carcinoma have bony metastases when they die (1). The clinical course in an individual patient with metastatic bone disease is unpredictable, often prolonged, and frequently associated with one or more of the serious complications of bone destruction (2). The detection of bone metastases in a patient accurately reflects the prognosis for that individual and early detection in the asymptomatic case may alert the clinician to the possible complications inherent in skeletal destruction. Preventive measures may thus be taken to avert or decrease the related morbidity and mortality.

Radioisotope bone scintigraphy is the most sensitive and the most common method of screening bony metastatic disease (3–12). The value of such an investigation has, however, been challenged (7–13). Much of the criticism stems from the high financial and labour costs in return for a low yield of 'positive' scans. Yet the high incidence of skeletal metastases with its related morbidity and mortality, and the associated heavy financial burden in caring for these patients, cannot be overlooked. A rational approach would be to identify those patients at greatest risk of developing secondary bone deposits and select them for radiological assessment alone. This would increase the 'positive' scan yield at a reasonable overall cost. The problem remains of finding a simple and inexpensive marker which reliably identifies those patients who are most likely to have bone metastases.

CA15–3 is a circulating human breast tumour associated antigen defined and assayed by two monoclonal antibodies; DF3 which is found on breast carcinoma cells and 115D8 which is found on milk fat globule membrane. CA15–3 levels are known to correlate well with the

disease stage in breast carcinoma (14–18). However, its value as an indicator or predictor of metastatic bone disease has yet to be fully elucidated. The purpose of this study was to evaluate the reliability of CA15–3 as a marker of secondary bony deposits in mammary cancer patients.

Patients and methods

In total, 218 patients with breast carcinoma were evaluated. All patients had a minimum follow-up of 12 months, all had 3-monthly CA15–3 assays and all had radioisotope bone scintigraphy on an annual basis, or if the patient developed either locomotor symptoms or an elevated tumour marker level on two successive occasions. CA15–3 levels were measured by a commercially available radioimmunoassay (CA15–3 from CIS Biointernational, Gif-sur-Yvette, France). The normal level in our laboratory is less than 30 u/ml. Technetium-labelled (^{99m}Tc) phosphonate was the agent used in the isotope scintigraphy. Statistical significance was taken at the $P < 0.05$ level.

Results

Table I illustrates the relationship between the various disease stages and elevated CA15–3 levels. Six patients with stage I disease (5.6%) had an elevated CA15–3 level at presentation, five from stage II (9.6%) and nine from stage III (23.0%). At follow-up, all of these patients' levels had returned to normal, except for one patient from each group. This latter group of three patients subsequently developed bone metastases. There were 19 patients who presented with stage IV disease, of whom 13 (68.4%) had an elevated CA15–3 level and all of whom had bone metastases. The strong association between stage IV disease and an elevated tumour marker level is graphically depicted in Fig. 1. The differences between CA15–3 levels in stage IV disease and the preceding stages is graphically apparent and statistically significant ($P < 0.001$). In addition to the 19 patients who presented *de novo* with stage IV disease, another 14 patients progressed to this stage during the study period. Thus, the final number of patients with metastatic breast disease was 33.

The various types of distant metastases encountered in the series can be conveniently divided into the following three groups: bone metastases alone; soft tissue (non-bone metastases) alone; both bone and soft tissue metastases present simultaneously. The number of patients with an elevated CA15–3 level at the time of diagnosis of their metastases was as follows: bone metastases = 15/17 patients (88%); soft tissue metastases = 2/6 (33%); both bone and soft tissue metastases simultaneously = 7/10 (70%). There appeared to be a strong association between an elevated CA15–3 level and metastatic 'bone' disease (total = 22/27 patients). The reliability and probability values of CA15–3 as an indicator of 'bone' and 'soft

Table I. Elevated CA15–3 levels at presentation and at follow-up in breast cancer patients: stages I, II, III and IV

Stage	CA15–3 elevation		
	Presentation	Follow-up	Bone mets.
I = 108 (49%)	6 (5.6%)	1	1
II = 52 (24%)	5 (9.6%)	1	1
III = 39 (18%)	9 (23.0%)	1	1
IV = 19 (9%)	13 (68.4%)	13	13
Total = 218			

Table II. Elevated CA15–3 levels in stage IV breast disease; bone vs soft tissue metastases

	CA15–3 indicates metastases of	
	Bone	Soft tissue
Sensitivity	81.5%	56%
Specificity	66%	22%
Positive predictive value	92%	37.5%
$P =$	0.023	0.093

tissue' metastases, respectively, is illustrated in Table II. From this data, CA15–3 is a more reliable and statistically significant marker of bone metastases than of soft tissue metastases.

Although 22/27 patients had an elevated CA15–3 level when the diagnoses of bone metastases were made, nine of these patients already had an elevated level before diagnosis (range = 3–12 months, median = 3 months). Though there were 5/27 patients who had normal CA15–3 levels when the diagnoses of bone metastases were made, all developed a delayed increase (range = 3–12 months, median = 3 months). Thus, all of the patients who had bony secondaries exhibited elevated CA15–3 levels.

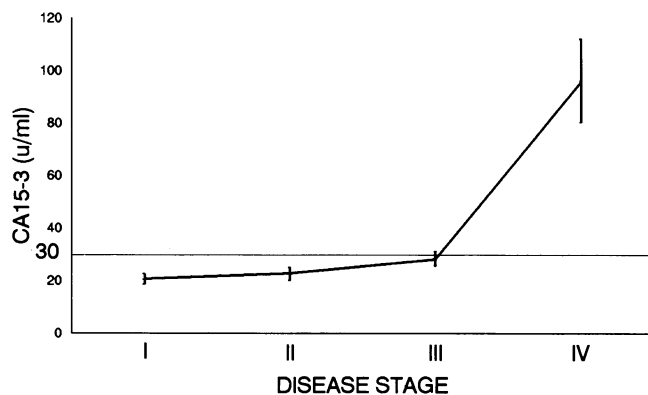


Figure 1. CA15–3 (Mean \pm standard error of the mean) in breast cancer patients: stages I, II, III and IV.

Discussion

There are several commercially available tumour markers which are useful in the follow-up of patients with malignancies. Breast carcinoma is no exception. Various markers have been tried and tested (19,20), but the most promising to date for mammary cancer is CA15-3. Hayes *et al.* (16), in 1986, studied CA15-3 levels in 1050 normal, healthy individuals and found only 14 (1.3%) with an elevated level above a value of >30 u/ml. Numerous studies have indicated that CA15-3 is a reliable marker in breast carcinoma and correlates well with the disease stage (14-18).

Metastatic bone disease in patients with mammary cancer is common and complications frequent (2). The objective of management in these patients is palliation rather than cure. Those patients who develop bone metastases often have a prolonged and unpredictable clinical course (median survival = 24 months) (2). The introduction of ^{99m}Tc-labelled phosphonates and phosphates for the identification of metastatic osseous disease led to the almost routine use of bone scanning in the preoperative staging of breast cancer. It is now well established that isotope scintigraphy is vastly superior to plain radiography for detection of secondary bony disease (21). However, in recent years there has been much disagreement on the value of isotope bone scans in the routine staging of breast cancer at presentation and for follow-up monitoring (8-13). Although isotope bone scintigraphy is the most sensitive method of detecting metastatic disease, widespread non-selective use is both impractical and not cost-effective. A simple, reliable and inexpensive marker which indicates the presence, but not the location, of osseous deposits would be a reliable signal to arrange scintigraphy in those patients most likely to have metastatic disease. This 'selectivity' would result in an increase in the positive scan yield and a sizeable financial saving. Of course, as such a marker cannot localise the deposit(s), it cannot substitute radiological screening.

CA15-3 fulfils this description. It costs approximately one-twentieth the price of a conventional isotope bone scan. It can be requested by the general practitioner for patients who reside in a remote part of the country or whose next hospital appointment is not for some considerable time.

In accordance with others (15-18), we too have confirmed the general reliability of this marker as an indicator of metastatic disease, but in addition we now show that CA15-3 is an excellent indicator of bone metastases in particular. Why the strong association between bone metastases and this tumour marker remains open to speculation. Perhaps it signifies that those mammary tumour cells destined to metastasise to bone display a specific behaviour and exhibit specific properties among which is the secretion of a specific antigen—CA15-3.

We therefore recommend regular CA15-3 assays on all patients with breast carcinoma followed by bone scintigraphy *only* if levels become elevated or if the patient develops locomotor symptoms. Those patients who have elevated marker levels should be categorised as 'high

risk' and screened for bone metastases and the various complications of bone destruction.

References

- Galasko CSB. The anatomy and pathways of skeletal metastases. In: Weiss L, Gilbert HA eds. *Bone Metastases*. Boston, Massachusetts: G K Hall, 1981:49.
- Coleman RE, Rubens RD. The clinical course of bone metastases from breast cancer. *Br J Cancer* 1987;55:61-6.
- Gerber FH *et al.* Efficacy of preoperative and postoperative bone scanning in the management of breast cancer. *N Engl J Med* 1977;297:300-303.
- Campbell DJ *et al.* The value of preliminary bone scanning in staging and assessing the prognosis of breast cancer. *Br J Surg* 1976;63:811-16.
- Citrin DL *et al.* Radioactive technetium phosphate bone scanning in preoperative assessment and follow-up study of patients with primary cancer of the breast. *Surg Gynecol Obstet* 1976;143:360-4.
- McNeil BJ *et al.* Preoperative and follow-up bone scans in patients with primary carcinoma of the breast. *Surg Gynecol Obstet* 1978;147:745-8.
- Coleman RE, Rubens RD, Fogelman I. Reappraisal of the baseline bone scan in breast cancer. *J Nucl Med* 1988;29:1045-9.
- Davies CJ *et al.* Staging breast cancer: role of bone scanning. *Br Med J* 1977;2:603-5.
- Spencer GR *et al.* Is bone scanning of value in patients with breast cancer? *Acta Chir Scand* 1981;147:247-8.
- Forrest APM *et al.* Is the investigation of patients with breast cancer for occult metastatic disease worthwhile? *Br J Surg* 1979;66:749-51.
- Bishop HM *et al.* Bone scanning: its lack of value in the follow-up of patients with breast cancer. *Br J Surg* 1979;66:752-4.
- Perez DJ *et al.* Detection of breast carcinoma metastases in bone: relative merits of X-rays and skeletal scintigraphy. *Lancet* 1983;10:613-16.
- Monypenny IJ *et al.* The value of serial bone scanning in operable breast cancer. *Br J Surg* 1984;71:466-8.
- Kerin MJ *et al.* CA15-3: its relationship to clinical stage and progression to metastatic disease in breast cancer. *Br J Surg* 1989;76:838-9.
- Fujino N *et al.* Clinical evaluation of an immunoradiometric assay for CA15-3 antigen associated with human mammary carcinomas: comparison with carcinoembryonic antigen. *Jpn J Clin Oncol* 1986;16:335-46.
- Hayes DF *et al.* Comparison of circulating CA15-3 and carcinoembryonic antigen levels in patients with breast cancer. *J Clin Oncol* 1986;4:1542-50.
- Ogawa T *et al.* Evaluation of a tumour-associated antigen CA15-3 in the sera of patients with breast cancer. *Jpn J Cancer Clin* 1986;32:27-32.
- O'Dwyer PJ *et al.* CEA and CA15-3 in primary and recurrent breast cancer. *World J Surg* 1990;14:562-6.
- Tormey D, Waalkes T. Clinical correlation between CEA and breast cancer. *Cancer* 1978;42:1507-11.
- Thompson RJ *et al.* Radioimmunoassay of serum creatine kinase-BB as a tumour marker in breast cancer. *Lancet* 1980;2:673-5.
- deSantos LA, Libshitz HI. Adult bone. In: Libshitz HI ed. *Diagnostic Roentgenology of Radiotherapy Change*. Baltimore: Williams and Wilkins, 1979:137-50.

Received 29 April 1991