

Use of pedicled omentum in oesophagogastric anastomosis: analysis of 100 cases

ZHANG KAI

Attending Surgeon, Chief of Division of Cardiothoracic Surgery

YANG YIHUA

Nurse; English Teacher

Department of Thoracic Surgery, Shi Jiazhuang Railway Hospital, Shi Jiazhuang, Hebei, China

Key words: OESOPHAGUS, SURGERY; STOMACH, SURGERY; OMENTUM, PEDICLE GRAFT

Summary

According to reports from our country, leakage occurs in about 5% of oesophagogastric anastomoses despite the numerous improvements in operative techniques, including methods of anastomosis in recent years.

From October 1979 to May 1984, 128 cases of oesophageal or gastric cardiac cancer were operated on, and pedicled omentum was used to reinforce the oesophagogastric anastomosis in 100 cases, without any postoperative anastomotic leakage.

Clinical

Of the 100 patients 79 were males and 21 females. The lesion measured 3 to 5 cm long in 23 cases of oesophageal and 14 cases of cardiac gastric cancer, and over 5 cm in 22 cases of oesophageal and 41 cases of cardiac cancer. The pathological types consisted of squamous cell carcinoma in 43, adenocarcinoma in 55 and undifferentiated carcinoma in 2 patients.

Technique

A meticulous operative technique cannot be over-emphasized, including such basic principles as strict aseptic technique, good exposure, proper mucosal approximation and a tension-free anastomosis with an adequate blood supply.

An end-to-side oesophagogastric anastomosis was performed after resection. Interrupted silk was used for the outer seromuscular layer (Fig. 1), as well as the inner whole thickness layer (Fig. 2), with 0.5 cm bites. The distance between the anterior seromuscular and whole layers was purposely extended to around 3 cm. (Fig. 3), to ensure better approximation.

The greater omentum was then tailored and turned up as a cuff to wrap around the anastomosis (Fig. 4), with its blood supply carefully preserved. In order to obtain an adequate length of pedicled omentum, especially when the anastomosis was above the aortic arch, the omentum was divided close to the transverse colon, if necessary severing the right or left gastroepiploic vessels. For cardiac cancers, the omentum was detached from the resected part of the stomach. When tailoring the omentum, care was taken to avoid mass ligation, twisting, haematoma formation from the gastroepiploic vessels, or tension on the omentum. It was anchored in place by

interrupted seromuscular stitches, usually about 6 in number, spaced evenly around the anastomosis (Fig. 5). In those cases with supra-aortic anastomoses, the interposed omentum also served to completely separate it from the aorta (Fig. 6).

Complications

One case in this series was complicated postoperatively by diaphragmatic hernia which was proved at re-operation, on the 12th postoperative day, to be caused by herniation of the transverse colon into the thorax as a result of inadequate mobilization of the omentum. One patient was re-explored for mediastinal abscess on the 19th day postoperatively. In each of these patients the transplanted omentum was found to be firmly adherent to the anastomosis and difficult to separate from the underlying structures.

Discussion

Pedicled omentum, provided with a rich blood and lymph supply and being freely mobile, is capable of adhering to neighbouring structures, as shown by our two patients who required re-exploration. Goldsmith (1) succeeded experimentally in patching the intestinal anastomotic defect purposely left over after oesophageal resection with pedicled omentum. These examples serve to illustrate that omentum with a vascular pedicle can actually reinforce and thus protect the anastomosis.

Anastomotic leakage, whether primary or secondary, usually occurs as a consequence of infection, necrosis and local abscess formation. Pedicled omentum, once anchored around the gastroesophageal anastomosis, on the other hand, could rapidly form adhesions and new blood vessel networks to the underlying tissue. If infection does take place at the anastomosis, the histiocytes, monocytes and granulocytes in the omentum could play a phagocytic role, serving to absorb the bacterial products and toxins, preventing the infection from developing into a local abscess, thus protecting the anastomosis (2). The findings at re-exploration establish the role of ischaemic necrosis and perforation of gastric remnant as the cause of intrathoracic anastomotic leakage (3,4). The use of pedicled omentum for reinforcement, with preservation of its blood supply, could protect the gastric remnant from the effects of ischaemia.

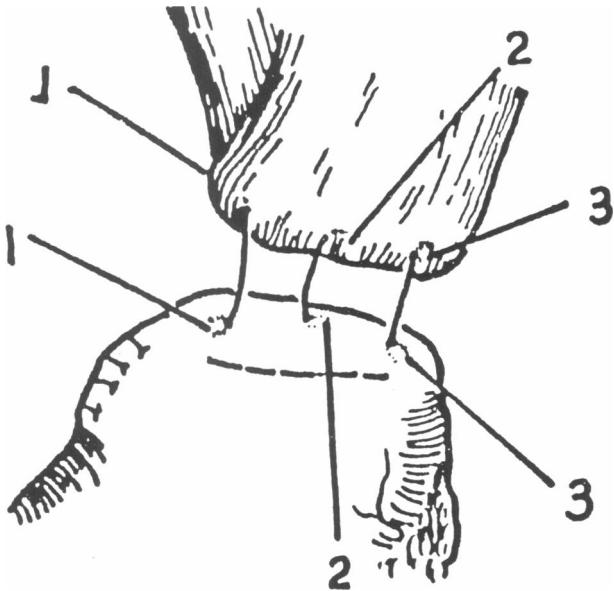


FIG. 1 Place 3 silk sutures connecting the oesophageal muscle layer to the posterior gastric seromuscular layer. Tie and cut the 2nd suture and retain the 1st and 3rd.

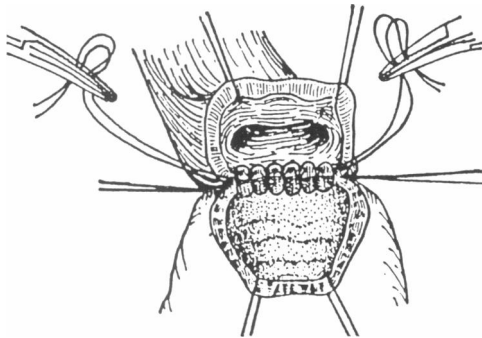


FIG. 2 Interrupted silk sutures are used for the all-coats layer, the ends are tied and cut.

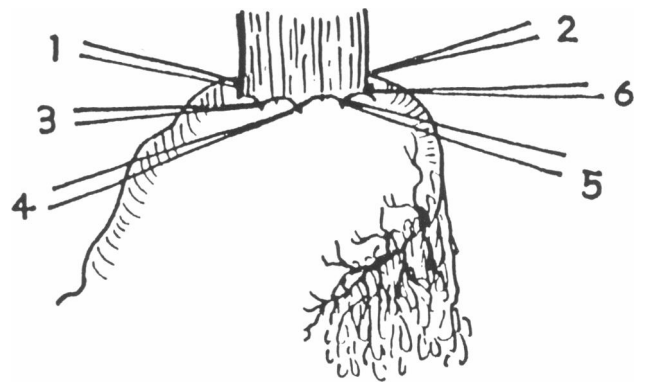


FIG. 4 Turn up the omentum and wrap it around the anastomosis.

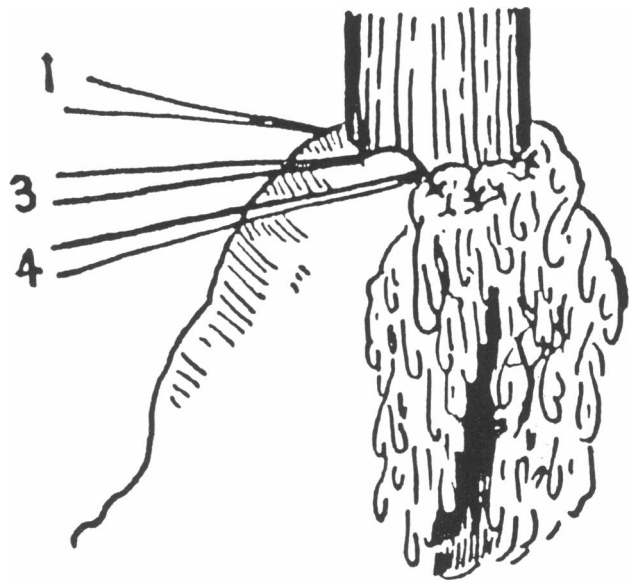


FIG. 5 Anchor the omentum with 6 silk sutures, then cut the anterior second layer stitches.

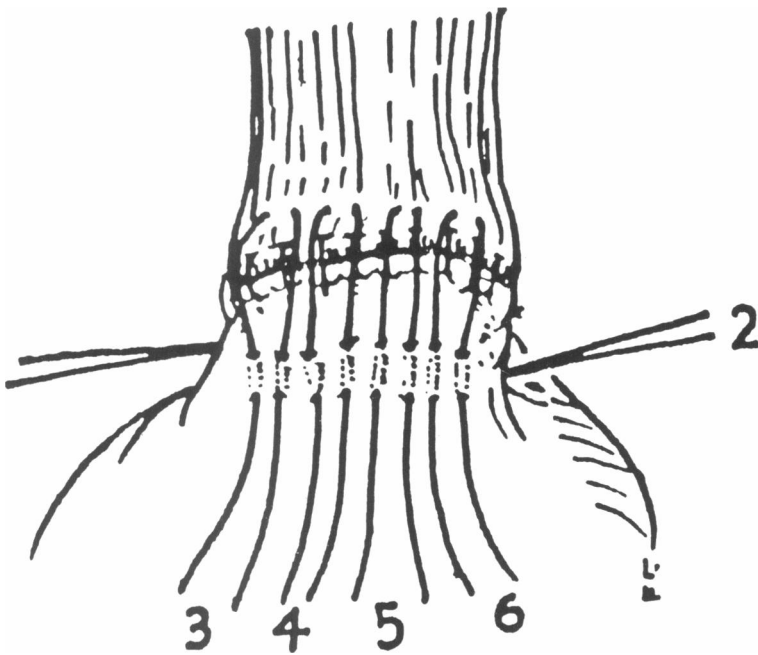


FIG. 3 Insert the anterior outer layer of interrupted sutures (3,4,5,6) joining the oesophageal muscular wall to the anterior gastric seromuscularis. Tie the stitches and retain the ends.

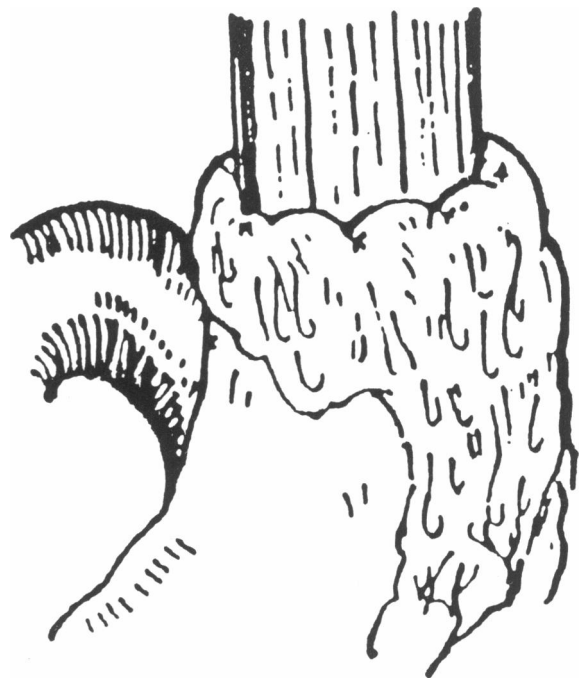

FIG. 6 The interposed omentum completely separates the anastomosis from the aorta.

References

- 1 Goldsmith HS. Protection of intrathoracic esophageal anastomoses by omentum. *Surgery* 1968;63:464-6.
- 2 Gao Shangzhi, Yao Zhen. *Greater Omentum Surgery*. 1st Ed. Beijing: People's Health Publisher. 1982;17-19.
- 3 Zhang Dawei. Early secondary thoracotomy in the treatment of anastomotic leakage following resection for carcinoma of the esophagus and gastric cardia: a report of 7 cases. *Chinese Journal of Oncology* 1980;2:231-3.
- 4 Ping Yumin. Gastroesophageal anastomotic leakage following resection of carcinoma of the esophagus and gastric cardia: an analysis of 159 cases. *Chinese Journal of Oncology* 1982;4:36-8.

Received 25 February 1987

Editor's comment

It is a pleasure to publish this paper from the Peoples' Republic of China. Those who have been fortunate to visit China will know of the expertise of our surgical

colleagues there and this paper attests to it. I believe that the excellent results reported here could be explained by good technique, maintenance of a good blood supply to the gastric conduit and absence of tension, rather than reliance upon omental wrapping. From time to time oesophageal surgeons plan and execute the resection, mobilization and anastomosis with great care, only to find at the completion of the procedure that there is a little more tension than had been anticipated, or the stomach looks a little congested. Incontrovertible tension, venous congestion or ischaemia demand corrective action, if necessary with dismantling of the anastomosis, fashioning of a fresh conduit, or the creation of temporary external stomata. In the presence of minimal tension or congestion that cannot be relieved but does not appear to necessitate drastic action, the use of a well vascularized omental wrap gives added protection and relieves the surgeon's anxiety.

R M KIRK

Book review

Surgical Problems in Clinical Practice edited by John Fry and Hedley E Berry. 142 pages, illustrated, paperback. Edward Arnold, London. £14.95.

I found the concept of this book immediately appealing. Although barriers have begun to break down in recent years, there is still too often a gulf between general practitioners in their relative isolation and the hospital based specialist. Here is a book edited jointly by a general surgeon and a general practitioner and written by a number of surgeons and practitioners.

The book sets out to put surgical problems into perspective with the aim of demonstrating to all those doctors who might be responsible for the care of the patient, that which is significant and the management options that are available. It is, therefore, aimed at surgeons and general practitioners both established and in training and also medical students, who have already covered the more theoretical side of the subject.

How successful the book is in achieving these aims is, I think, rather variable. Although it states in the preface that only selected conditions are discussed, I found the choice of topics strange. There is no coverage, for example, of any urological problems other than occasional reference in differential diagnoses. Rectal and anal conditions such as haemorrhoids, fissures and abscesses are omitted and there is no discussion of general orthopaedic topics. On the contrary, however, there is an excellent chapter on low back pain, which emphasises the small number of these cases which have a surgical solution.

The chapter on children's surgical problems is noteworthy for some curious statistics. In my experience of children with head injuries, I would not expect a mortality rate of 10% and nor would I expect 10% of children to develop epilepsy following head injury (page 5). I also felt that appendicitis being the cause of 18 per 1000 consultations a year is very much an

overestimate. Nowhere in this chapter is there any mention of testicular torsion as a cause of abdominal pain. Testicles will continue to be lost until the consideration of this differential diagnosis is made. Torsion of the testis is discussed under a heading of Acute Scrotal Swellings in another chapter, but to find this topic from the index would lead one to a flow diagram on the diagnosis of hyperthyroidism!

There are other obvious misprints such as the page heading which is repeated several times 'Conditions requiring elective emergency admission' (page 9 *et seq.*). The format is, at times, confusing with a double column layout, which is interrupted at intervals with changes of topic. The style is also variable, reflecting the number of contributions, varying from rather terse notes to a much easier prose in other areas.

On a more general note, however, I was disappointed that I felt that the book failed to draw together the two groups of doctors caring for the surgical patient. Now that most general practitioners have access to radiology departments and laboratory facilities it is often possible to present a fully 'worked up' patient to the surgeon at his outpatient clinic. This must be in the interest of the patient, present savings to the National Health Service and give further understanding and satisfaction to the family doctor. Beyond this there are many problems which can be dealt with by the general practitioner if he knows he has the support of local surgeons. Breast cysts can be aspirated, varicose veins and haemorrhoids injected, perianal haematomata evacuated, ingrowing toenails, cysts and other surface lesions can all be excised.

Although offering a useful review of many surgical topics, I feel the book fails to make the most of the opportunity to draw the family doctor into the joint care of the surgical patient.

DAVID BAINBRIDGE
General Practitioner, East Grinstead