

The practical management of Fournier's gangrene

STUART D SCOTT FRCS

Honorary Senior Registrar

RAY F H DAWES FRCS

Research Registrar

JEREMY J T TATE FRCS

Research Registrar

GAVIN T ROYLE MS FRCS

Senior Lecturer in Surgery

STEPHEN J KARRAN MChir FRCS

Reader in Surgery

University Surgical Unit, Southampton

Key words: FOURNIER'S GANGRENE; NECROTIZING FASCIITIS

Summary

Effective early treatment of this serious condition is necessary to prevent death. Urgent exploration by the most experienced surgeon available should include wide excision of all necrotic or dubious tissue, and adequate drainage of deep fascial planes. Deep and apparently healthy tissues must be exposed and the surgeon must be prepared to proceed to laparotomy, and even diverting colostomy and/or suprapubic cystostomy when necessary. Cross matched blood must be available, and we have found hydrogen peroxide irrigation useful. Pus, tissues, and blood samples for bacteriological culture and sensitivity should always be sent, but broad spectrum antibiotics should be started without delay to prevent systemic complications. In addition to the urgent initial surgery, repeated daily examination of all wounds is necessary, usually under general anaesthesia to allow full inspection, further débridement, irrigation and change of dressings, until the infective process is halted. This is a serious condition with a high mortality which we believe may be reduced by early diagnosis and appropriate aggressive surgery.

Introduction

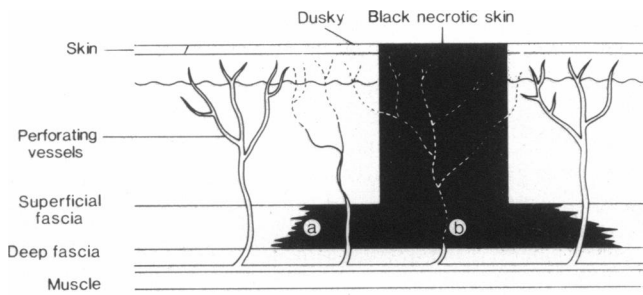
Though widely known as Fournier's Gangrene, after the Parisian specialist who reported over five cases in 1883 (1), the condition of scrotal gangrene had been noted earlier in 1764 by Baurienne (2) and also by Hebler in 1848 (3). Fournier originally described a fulminating genital gangrene affecting otherwise healthy young men, and called the process idiopathic gangrene of the scrotum. He felt that local trauma and diseases of the genital skin and perineum were causative, promoted by systemic debilitating conditions such as diabetes mellitus, alcohol-

ism, and syphilis. However, several cases occurred in healthy young men without apparent cause (4). A review of 267 cases by McCrea in 1945 (5) and further work by Wilson (6) in 1952 reassessed the pathophysiology, and Wilson coined the term 'Necrotising Fasciitis' to describe the disease process which can occur in other parts of the body, in either gender, but which, when affecting the male perineum, still merits the eponym Fournier's gangrene. It is now clear that there is a recognisable cause in the majority of cases (5,7,8).

Despite urgent surgical treatment the mortality remains high (9), figures of 30–50% being common, rising to 80% in diabetics (10,11). This is surprising compared to the 22% mortality in the large series from the pre-antibiotic era (5), and suggests that modern surgeons need to be more aggressive in their initial therapy and make the first surgery definitive. Antibiotics are of lesser importance. They are futile against the fulminating phlegmon, their main role being to prevent secondary infection. Certainly there is no place for conservative therapy (12) and delay in surgery is probably the greatest cause of death (11). Even with 'adequate' surgery, hospital stay is frequently protracted, (13,14) some series averaging 73 days (15).

Pathophysiology

Although concluding that the genital gangrene was 'idiopathic', Fournier himself reported associations with several possible causes, the foremost of which was diabetes mellitus. Fournier had seen cases related to surgical trauma, commonly circumcision, to alcohol and senility, syphilis and typhoid fever, peripheral vascular disease, urethral perforations and calculi, priapism, genital infections and also excessive coitus, though he



- (a) Note wide lateral extension of necrotising process spreading in this deep plane.
- (b) Thrombosis in perforating vessel leading to secondary necrosis of overlying skin.

FIG. 1 Surgical pathology, subcutaneous infarction.

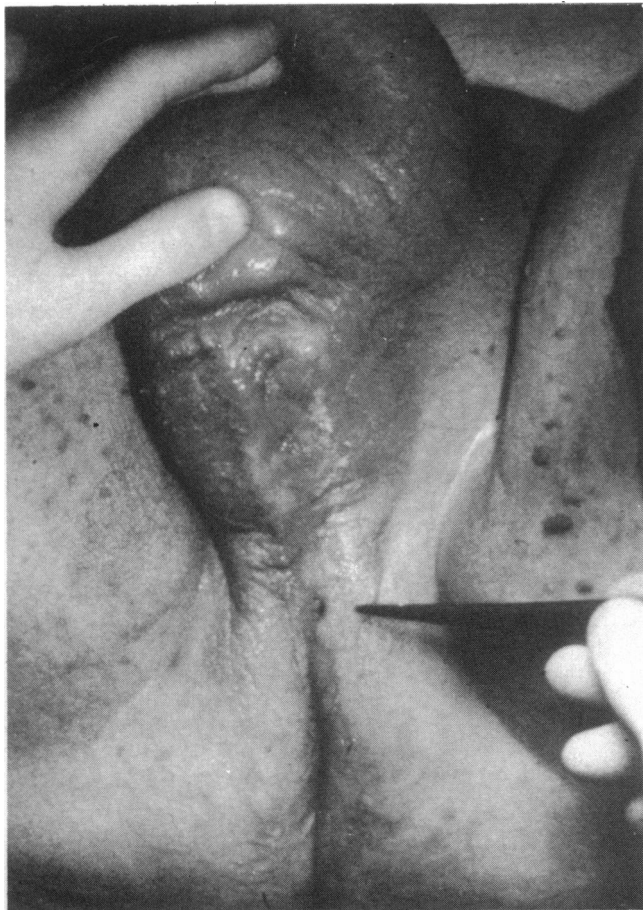

FIG. 2 Gross scrotal oedema, tiny necrotic hole.

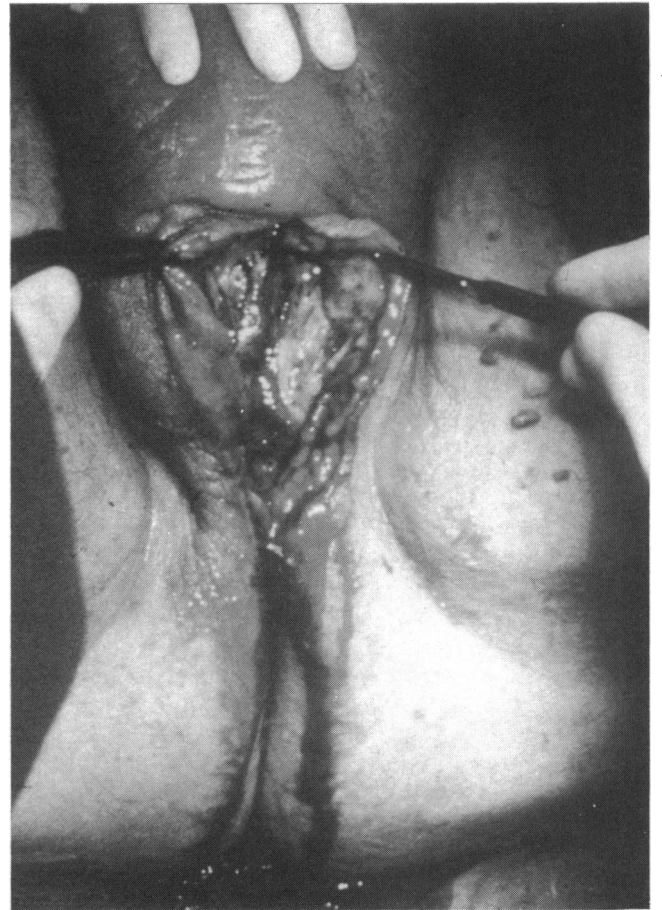


FIG. 3 The deep infective phlegmon.

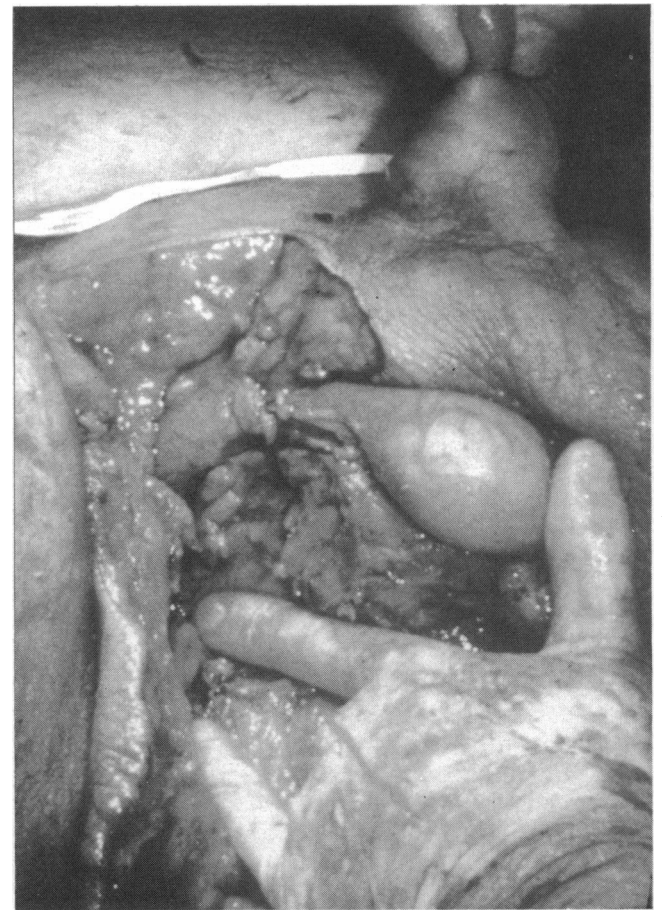


FIG. 4 Wide excision, testis exposed, skin viable.

believed this to be a very rare cause, otherwise the wards would have been full!

We now recognise two main processes; firstly direct local trauma, allowing invasion of micro-organisms into the subcutaneous tissues and secondly extension of infection from within the urinary tract, or from infection in the perineal area. The condition is worse in debilitated patients, especially those who are immunosuppressed by steroids, or cytotoxic therapy.

The gross pathology (Fig. 1) is inflammation, oedema and necrosis of the subcutaneous tissues, with watery pus formation, and later secondary necrosis of the overlying skin due to interruption of its blood supply. Organisms from the infective phlegmon spread far from the primary septic site, to cause extensive thrombosis and endarteritis obliterans in the deep fascial planes, with localised patches of gangrenous skin above. This vascular disaster is thought to originate in the synergistic effect of multiple aerobic and anaerobic organisms. Aerobes cause platelet aggregation and accelerate coagulation by fixing complement, and produce heparinase (16). *Bacteroides* species also inhibit phagocytosis of many aerobes (17). Obligate anaerobes such as *B. fragilis* thrive in the decreased oxygen tension of a closed space, and promote the growth of facultative anaerobes such as *E. coli*. These produce the relatively insoluble gases hydrogen and nitrogen, causing subcutaneous gas collections which may be visible on X-ray and produce clinical crepitus. The anaerobes are responsible for the overwhelmingly repulsive stench; the putrid faeculent odour so pathognomonic of this gangrene.

Clinical aspects

The clinical picture is only the tip of an iceberg. The black spot of gangrenous skin belies the widespread nature of the underlying phlegmon, against which antibiotics alone are futile. There is usually intense perineal pain and tenderness, and the deep infection gives rise to fever and systemic toxæmia. Diabetics may present with ketoacidosis (18). The perineal tissues are swollen, with gross oedema and cellulitis, often with crepitus, and the characteristic smell of anaerobic infection, but initially these classic signs may be absent. The toxæmia responds dramatically to thorough excision of necrotic tissue and drainage of pus.

Recently we have treated five cases, each of which illustrates different practical points in the management of Fournier's gangrene.

Case reports

CASE 1

A 75 year old diabetic with carcinoma of the bronchus, was admitted with 'some cellulitis in his groin'. Within two hours of admission, the cellulitis had spread and an area became frankly gangrenous and urgent radical surgery was undertaken, widely débriding the scrotum, penis, anus, perineum, buttock and abdominal wall. A prophylactic colostomy was raised to prevent faecal soiling of the wide raw area. Prophylactic broad-spectrum antibiotics, including anaerobic cover, were commenced. Postoperative progress was excellent, the wounds healed in six months by secondary intention, and the colostomy was closed at nine months.

CASE 2

A 63 year old man presented with a mild fever and

perineal discomfort. A palpable rectal carcinoma was discovered and a sigmoidoscopy, biopsy and barium enema were performed. Four days later he became toxic and a left sided ischio-rectal abscess was noted. Simple incision and drainage of the pus produced only temporary improvement. He became shocked with scrotal oedema, cellulitis, and a black area of perianal skin. Fournier's gangrene was recognised. Emergency abdominoperineal resection was performed, with radical débridement of the perineum, and lower abdominal wall, and drainage of a large pelvic abscess, with gratifying improvement in his systemic condition. He required eight units of blood, and healed well by secondary intention in 130 days.

CASE 3

A 63 year old obese man (85 kg) had a per-anal resection of a villous adenoma. He developed postoperative urinary retention and was catheterised. Two days later he had spreading cellulitis in the perineum, scrotum, right groin and loin extending up to his renal area. He was commenced on broad spectrum antibiotics and yet within hours he developed the pathognomonic signs of Fournier's gangrene with dusky scrotal skin, necrosis at the anal margin, and he became systemically shocked. He was taken to theatre where the scrotal and perineal skin was widely excised and, as the right testis was infarcted, orchidectomy was performed. The significance of this was recognised at the time, and immediate laparotomy performed, but the retroperitoneal tissues appeared normal. Hartmann's procedure diverted the faeces from the perineum, and the abdominal wall was laid open on the right side. His condition deteriorated, and next day he returned to theatre where a further laparotomy revealed synergistic gangrene in the retroperitoneal space, extending up to the diaphragm. This is extremely deceptive, and was probably present at the previous laparotomy. The wound was left open and at further examination under anaesthesia the next day, the residual rectum was removed to facilitate full débridement of the ischio-rectal space. The bladder remained viable. However, the patient developed renal failure and septicaemia, and after 11 days in the intensive care unit, he died of multiorgan failure.

CASE 4

A 56 year old man with lymphoma, who had received deep X-ray therapy, steroids, and cytotoxic agents, presented with a perineal swelling. When attempted aspiration of pus produced only a dry tap, a presumptive diagnosis of metastatic lymphoma was made, and he was transferred to our hospital. Within 12 hours he became toxic, temperature at 38°C, WBC 25,000, confused and there was the characteristic putrid odour from the perineum. A tiny black spot was visible in the perineum at the site of the attempted aspiration. A diagnosis of Fournier's gangrene was made and he was commenced on broad spectrum antibiotics and taken urgently to theatre. Opening the perineal skin through the black spot revealed a huge phlegmon, with the typical 'dish-water' pus and the characteristic stringy fetid mass of necrotic tissue, extending up to both inguinal ligaments. Wide radical débridement was associated with considerable blood loss, four units being transfused preoperatively. The testes, having their separate blood supply, were

spared the necrotic process and, in the immortal phrase of Randall (19), were "left hanging shamefully exposed". The raw area was washed repeatedly with hydrogen peroxide and then dressed with Eusol and paraffin. Inspection in theatre next day showed no further need for surgery, and his wounds healed remarkably well by second intention over three months.

CASE 5

A 58 year old man weighing over 125 kg presented with a perineal abscess which burst as he struggled to turn over on his bed for examination. The scrotum was enormously swollen and oedematous with gross cellulitis, and a tiny patch of necrotic skin. His blood sugar was 15.3 mmol/l though he was not previously known to be diabetic. He was toxic, temperature 39°C, and taken to theatre immediately for radical débridement of the perineum under broad antibiotic cover. The tiny hole (Fig. 2) in the presence of such gross scrotal oedema, was totally out of proportion to the devastating vascular disaster of infective origin rampant beneath the skin. Once the skin was opened (Fig. 3) the full extent of the spreading subfascial gangrene became apparent. Although the subfascial infection spread up to the inguinal ligaments on each side, the skin itself did not appear necrotic at this stage, and though degloving the scrotum was necessary, the skin of the groins was laid open as flaps and preserved (Fig. 4). Hydrogen peroxide and Eusol and paraffin were used copiously. Recovery was complete in three months.

Discussion

These cases illustrate several specific lessons in management. It is well recognised that early diagnosis is highly beneficial, but that diagnosis is not always easy. If it is suspected, it is far better to explore under general anaesthesia than to await events, as illustrated by our only death, case 3.

Diagnosis All our patients had systemic symptoms out of proportion to their deceptive visible signs of infection. The presence of a black spot or dusky area in the perineal skin surrounded by erythema is pathognomonic of Fournier's gangrene (Fig. 2). There may be no obvious precipitating cause of infection, especially in debilitated or immunocompromised patients (cases 1 and 4). Diabetics are at a greater risk than others, and Fournier's gangrene may be a rare presentation in an undiagnosed diabetic (case 5). Trivial injury, including minor surgical trauma, such as sigmoidoscopic biopsy, or urethral catheterisation, will be the cause in a high proportion of cases (cases 2 and 3). Aspiration of pus is not a reliable diagnostic sign (case 4) as in Fournier's gangrene there is little true pus, but thick tenacious slough, similar to that so frequently seen in diabetic ulcers.

Operation Early surgery is essential—once the diagnosis is made, the only delay should be to obtain cross matched blood. The infection can spread widely in only a few hours (cases 1 and 3). The pathophysiology precludes any role for antibiotics as a primary treatment (case 3). Surgical débridement must be urgent, aggressive and definitive. "If in doubt cut it out" is a truism in Fournier's gangrene. The most experienced surgeon available should be in charge of the operation. Occasionally it may

be possible to preserve flaps of viable skin (case 5), but more often conservation means inadequate débridement. It is always a bloody operation; there is a profuse ooze of inflammatory 'dishwater' fluid which, mixed with blood from a wide raw area, makes the bleeding points difficult to define. Thorough ruthless surgery, cutting back to bleeding viable tissues is often associated with a blood loss of more than four units. A diverting colostomy may be very useful (case 1). The testes may be left exposed, and scrotal skin regenerates extremely well, though some surgeons have used split skin grafts to speed recovery (8,10). Full thickness abdominal wall excision can be plugged with omentum. The bladder and rectum often survive even if other pelvic tissues require excision. If there is a history of rectal surgery, or failure of the patient to respond to the initial débridement, laparotomy is essential and the posterior peritoneum may need to be incised before necrotic retroperitoneal tissues are exposed (case 3). The crucial significance of testicular infarction, implying thrombosis of the testicular artery, must be recognised as an absolute indication for full laparotomy and retroperitoneal exploration. We believe copious lavage with hydrogen peroxide to be of benefit (cases 4 and 5) but is of secondary importance to thorough surgical drainage of the deep fascial planes.

Perioperative management The systemic improvement following surgery is usually dramatic. By the nature of the surgery, blood transfusion will almost certainly be required. Systemic broad spectrum antibiotics, including anaerobic cover should be continued as an adjunct to surgery (20). Frequently seven or more bacterial species can be cultured (10). We feel that metronidazole, gentamicin, and a cephalosporin are appropriate to prevent secondary spread from the primary septic source. Transient hypotension, toxæmia and nephrotoxic antibiotics expose the patient to the risk of renal failure, and preventative measures must be started early. Re-examination of the patient under general anaesthesia at 24 hours, earlier if indicated, is essential to exclude further tissue necrosis, and should be repeated until it is certain that the infective process is eliminated. Wounds may be left to heal by secondary intention or covered by split skin grafting, but there should be no attempt at primary closure. Hyperbaric oxygen was found by Ledingham to be of dubious value (21), but we believe that hydrogen peroxide irrigation is beneficial, despite possible reported hazards (22).

Conclusion

The practical management of Fournier's gangrene must include early recognition of the problem, by clinical awareness and diagnostic suspicion. Full laying open of tissues must accompany radical débridement of any necrotic or suspect tissue, and must be performed as a matter of urgency by the most experienced surgeon available. Cross matched blood will be required, and hydrogen peroxide is useful. Consideration should be given to diverting colostomy and/or suprapubic cystostomy. Several reappraisals under general anaesthesia will be required, and afford an opportunity to change dressings. The testes are usually spared and may be left exposed; scrotal skin regenerates remarkably well. Antibiotics should include anaerobic cover but are of secondary importance to surgery. Mortality is high, especially

in diabetics, but may be reduced by urgent aggressive surgery.

The urgency of that surgery is so admirably reflected in Fournier's own description of this dramatic gangrene—"La début subit et foudroyant; l'extension étonnamment rapide; l'extension toujours considérable; la coexistence fréquent d'un purpura; et, somme tout, l'excessive gravité!".

References

- 1 Fournier JA. Gangrene Foudroyant de la verge. *Semaine Med.* 1883;3:345-7.
- 2 Baurienne. *J de med Chir Pharm.* 1774;20:251-3.
- 3 Hebler. Brand des Hodensaches und vobstandeger Wieder-satzung. *Med Ziets* 1848;4:188-9.
- 4 Fournier JA. Gangrene Foudroyant de la Verge. *Semaine Med.* 1884;4:69-80.
- 5 McCrea LE. Fulminating gangrene of the penis. *Clinics* 1945;4:796-829.
- 6 Wilson B. Necrotising fasciitis. *Am J Surg* 1952;18:416-31.
- 7 Burpee JF, Edwards P. Fournier's gangrene. *Br J Urol* 1972;107:812-14.
- 8 Jamieson NV, Everett WG, Bullock KN. Delayed recognition of an intersphincteric abscess as the underlying cause of Fournier's scrotal gangrene. *Ann R Coll Surg Engl* 1984; 66:434-5.
- 9 Roberts JO, Fenton OM, Peters JL. Necrotising fasciitis. *Update* 1985;Nov:829-42.
- 10 Lamerton AJ. Fournier's gangrene, non-clostridial gas gangrene of the perineum, and diabetes mellitus. *J Roy Soc Med* 1986;79:212-15.
- 11 Oh C, Lee C, Jacobson JH. Necrotising fasciitis of the perineum. *Surgery* 1981;91:49-51.
- 12 Karran SJ, McDonald PJ, de la Hunt MJ *et al.* Principles of prophylaxis and treatment of sepsis in biliary and colorectal surgery. Merck Frosst Canada Inc 1984:20-5.
- 13 Bahlmann CJM, Fourie IJH, Arndt TCH. Fournier's gangrene. Necrotising fasciitis of the male genitalia. *Br J Urol* 1983;55:85-8.
- 14 Stone HH, Martin JD. Synergistic necrotising cellulitis. *Ann Surg* 1971;175:702-11.
- 15 Spirnak JP, Resnick MI, Hampel N, Persky L. Fournier's gangrene: report of 20 patients. *Br J Urol* 1984;131:289-91.
- 16 Bjornson HS, Hill EO. Bacteroidaceae in thromboembolic disease. Effect of cell wall components on blood coagulation *in vivo* and *in vitro*. *Infect Immun* 1973;8:911-18.
- 17 Ingham HR, Sisson PR, Tharaggonnet D *et al.* Inhibition of phagocytosis *in vitro* by obligate anaerobes. *Lancet* 1977;2:1252-4.
- 18 Slater DN, Smith GT, Mundy K. Diabetes mellitus with ketoacidosis presenting as Fournier's gangrene. *J Roy Soc Med* 1982;75:530-2.
- 19 Randall A. Idiopathic gangrene of the scrotum. *Br J Urol* 1920;4:219-42.
- 20 Jones RB, Hirschmann JV, Brown GS, Tremann JA. Fournier's syndrome: necrotizing subcutaneous infection of the male genitalia. *Br J Urol* 1979;122:279-82.
- 21 Ledingham I McA, Tehrani MA. Diagnosis, clinical course and treatment of acute dermal gangrene. *Br J Surg* 1975;62:364-72.
- 22 Sleigh JW, Linter SPK. Hazards of hydrogen peroxide. *Br Med J* 1985;291:1706-7.

Received 23 May 1987

TRANSFER OF ANAESTHETIC RECORDS BETWEEN HOSPITALS

Patients are often transferred from one hospital to another for further surgery with a letter describing only the initial surgical condition and operative surgical management despite having a recent anaesthetic. Sending a photocopy of the anaesthetic record will enable the anaesthetist to select the appropriate drugs and techniques in accordance with the first anaesthetic. A history of a recent general anaesthetic will automatically exclude the use of the inhalational agent, halothane (1), even if it is deemed the most appropriate agent in the situation. Also anaesthetic problems and complications may be diagnosed and avoided more readily by reference to the previous anaesthetic record.

Working for 18 months as an anaesthetic registrar in specialised surgical hospitals (orthopaedics, ENT and ophthalmology), I have seen only one anaesthetic record sent with the referral notes.

May I make a plea for the practice of sending photocopies of the anaesthetic records with the referring notes to become universally accepted?

Reference

- 1 Committee on Safety of Medicines. Current problems No. 18. London: Committee on Safety of Medicines, 1986.

*Moorfields Eye Hospital
London*

B AL-SHAikh MB ChB
Anaesthetic Registrar