

Crohn's disease of the appendix

JANE McCUE MB BS FRCS

Surgical Registrar

M J COPPEN MB BS MRCPATH

Pathology Senior Registrar

Departments of Surgery and Histopathology, Whittington Hospital, London

S A RASBRIDGE BSc MB BS MRCP

Pathology Registrar

M R LOCK MB BS FRCS

Consultant Surgeon

Key words: CROHN'S DISEASE; ACUTE APPENDICITIS

Summary

This study reports eight patients who underwent appendicectomy between 1978 and 1986 for apparently isolated, previously undiagnosed Crohn's disease of the appendix. All patients have since remained well with no sign of disease recurrence. This may represent a less aggressive form of Crohn's disease or be a different entity, namely granulomatous appendicitis.

Introduction

In their original paper on regional enteritis in 1932 Crohn *et al.* (1) stated that "the appendix is always free from guilt and free from blame". It has since become apparent that this is not the case. In 1948 Warren and Sommers (2) found serosal involvement of the appendix in 24% of 120 cases of Crohn's disease, while more recently Larsen *et al.* (3) have reported appendiceal involvement in more than 50% of such cases. Isolated Crohn's disease of the appendix was first described by Meyerding and Bertram in 1953 (4) and has been noted with increasing frequency over the past two decades. The total number of reported cases is now approximately 100.

The finding of an appendix showing the features of Crohn's disease may be either a primary phenomenon or a manifestation of additional disease elsewhere in the gastrointestinal tract. The risk of recurrence appears to be lower when the appendix alone is involved. The diagnosis is rarely suspected at the time of surgery, but should be considered if the history of appendicitis is atypical or prolonged.

We describe eight further patients with primary Crohn's appendicitis, highlighting the salient clinical features and discuss the significance of this diagnosis and its prognosis.

Patients and methods

This retrospective study reviews the case notes and histological specimens of eight patients who were seen at the Whittington Hospital between 1978 and 1987 with a diagnosis of Crohn's disease of the appendix. The pathology slides were re-examined in suspected cases,

including those of all appendices demonstrating chronic inflammation.

The haematoxylin and eosin (H&E) sections of the appendices were reviewed by one pathologist (MJC). If granulomas were detected then further sections were cut at 5 µm and Ziehl-Nielsen, periodic acid-Schiff and Gram stains were performed to detect acid-fast bacilli, fungi and other bacteria respectively.

The histological diagnosis of Crohn's disease was based on a combination of features, the most important being transmural inflammation with thickening of the appendix wall and the presence of epithelioid granulomas. Other features that were sought included the nature of the inflammatory infiltrate, the presence of epithelial ulceration, crypt abscesses, fissuring, giant cells, lymphoid aggregates, fibrosis, neural hyperplasia, abscess formation and perforation.

A total of eight cases were confirmed, two of which were diagnosed only on review. There were a further two patients showing features suggestive, but not diagnostic, of Crohn's disease who have been excluded from our survey. Patients who were noted to have simultaneous Crohn's disease outside the appendix at the time of appendicectomy were also excluded.

The patients were submitted to routine follow-up in the outpatient department. Those who had been discharged from hospital attendance were traced at home and interviewed. Any radiological studies performed were reviewed.

Results

1. CLINICAL FEATURES (see Table I)

There were eight patients, four of each sex, with a mean age of 21.7 years (range 16–27 years). The duration of symptoms varied between 1 day and 2 months.

Symptoms

Right iliac fossa pain was present in all eight patients, in seven it had commenced in the centre before localising to the right. Three patients were anorexic and a further three were nauseated or had vomited. Bowel habit was essentially unchanged although two patients had alter-

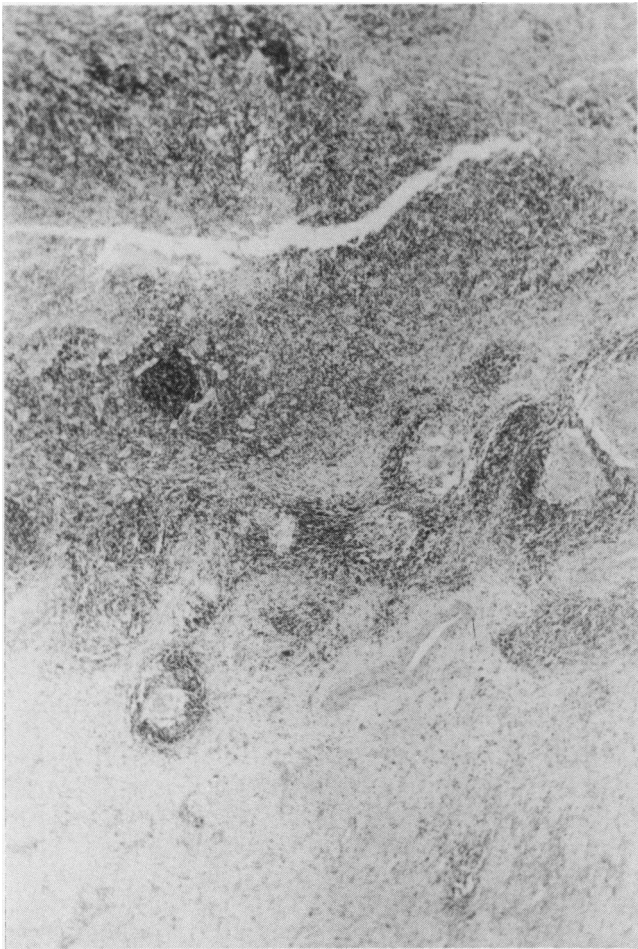


FIG 1 Low power field ($\times 32$) showing features of classic Crohn's appendicitis with a very narrowed lumen and multiple non-caseating granulomata.

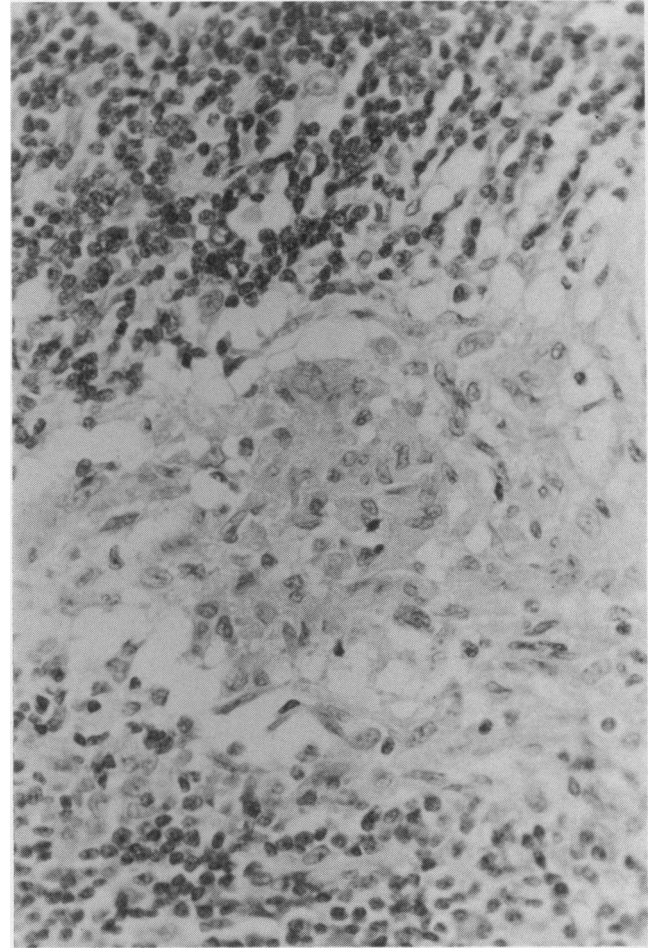


FIG. 2 High power field ($\times 320$) showing a representative granuloma.

TABLE 1 *Clinical features*

	<i>Age</i>	<i>Sex</i>	<i>Pain</i>	<i>Other symptoms</i>	<i>Abdomen</i>	<i>Operation findings</i>	<i>Progress</i>
Patient 1	27	M	1 day	Anorexic	Tender with mass in RIF	Inflamed broad based appendix	Well at 1 year
Patient 2	19	F	14 days	Vomiting diarrhoea/constipation	Tender RIF ? mass	Inflammatory mass around appendix	Well at 11 mths
Patient 3	24	F	7 days	Sweats	Peritonism in RIF ? mass	Huge appendix inflamed in pelvic abscess	Well at 1 year
Patient 4	22	M	3 days	Anorexic	Peritonism in RIF	Thick hard appendix in abscess	Well at 9 yr 2 mths
Patient 5	18	M	5 days	Nausea	Peritonism RIF	Appendicitis in pelvic abscess	Well at 3 yr 4 mths
Patient 6	25	F	2 months	Sweats diarrhoea/constipation	Tender with mass in RIF	Broad based appendix in mass plus small abscess	Well at 2 yrs 3 mths
Patient 7	16	M	3 days	Nausea vomiting	Peritonism RIF	Oedematous appendix	Well at 3 yr 9 mths
Patient 8	22	F	3 days	Anorexic	Tender RIF ? mass	Appendix mass	Well at 9 years

nating episodes of diarrhoea and constipation. Two patients complained of episodes of sweating.

Examination

Six patients were pyrexial with a mean temperature of 38.2°C. All were tender in the right iliac fossa with localised peritonitis in four. A definite mass was palpated in two and suspected in three others. There were no patients with perianal problems or any extra-intestinal manifestations of Crohn's disease, although one patient complained of a recent onset of arthralgia.

Investigation and management

Few preoperative investigations were performed as the clinical diagnosis in seven cases was appendicitis. The patient who had been symptomatic for two months underwent an ultrasound scan which demonstrated a mass in the right iliac fossa and a barium enema which was normal.

All patients underwent appendicectomy. In four cases the appendix lay within an abscess cavity while in three the appendix was surrounded by a mass of bowel and omentum. The remaining appendix appeared oedematous. In two instances the appendix was noted to be broad-based and in two instances it was greatly enlarged and indurated. No mention was made in any of the operation notes about the remainder of the small or large bowel.

2. HISTOLOGY

The appendices of all eight cases were histologically consistent with a diagnosis of Crohn's disease according to the criteria mentioned earlier (see Table II).

TABLE II *Histological findings*

<i>Histological features</i>	<i>Number of cases</i>	<i>%</i>
Thickening of wall	8/8	100
Panmural inflammation	8/8	100
Epithelioid granulomas	8/8	100
Mixed inflammatory infiltrate	8/8	100
Mucosal ulceration	8/8	100
Crypt abscesses	5/8	63
Fissured ulceration	8/8	100
Giant cells	4/8	50
Lymphoid aggregates	8/8	100
Submucosal fibrosis	8/8	100
Serosal fibrosis	8/8	100
Neural hyperplasia	1/8	13
Perforation	2/8	25
Abscess formation	5/8	63
Acid-fast bacilli (Z-N)	Absent	0
Bacterial (Gram stain)	Absent	0
Fungi (PAS)	Absent	0
Helminths	Absent	0

In addition perforation occurred twice, while abscess formation was seen in five. No lymph nodes were identified. No evidence of caseation, foreign body reaction, parasites or organisms were present in any of the cases.

3. OUTCOME

One patient developed a transient small bowel obstruction in the immediate postoperative period which settled

with conservative management. The remaining patients were all discharged within 1 week of operation. Shortly afterwards one developed a faecal fistula which closed on a low residue diet.

The average duration of follow-up has been 3.9 years (range 1–9.3 years). All patients have remained well with no sign of recurrent Crohn's disease. Only one patient underwent postoperative barium studies and these were completely normal.

Discussion

Isolated Crohn's disease of the appendix, along with a true rising incidence of Crohn's disease, has been recognised with increasing frequency in recent years. Including this series, the total number of documented cases is now just over 100. The average age of all recorded patients is 23.8 years, with a slight male preponderance (54.5%).

The clinical presentation is variable, as seen in this series, but the commonest mode of presentation (54%) is with acute abdominal pain which is essentially indistinguishable from acute appendicitis. Approximately 22% complain of right iliac fossa pain which has been present for between 3 days and 3 weeks; in these patients there is frequently an accompanying abdominal mass. A further 24% present with chronic abdominal pain. A change in bowel habit does not appear to be a feature of this disease, neither is weight loss. The systemic complications of Crohn's disease have not been described.

Eighty-four patients have a mean follow-up period of 7.6 years (range 0–16.8 years). The maximum recorded recurrence rate for that period is 13%, although closer scrutiny of the data would suggest it is closer to 6%. Wang *et al.* (5) and Allen and Biggart (6) described alleged recurrence despite noting an abnormal ileum at operation. In addition Yang *et al.* (7) include two cases of recurrent disease when the symptoms began in the immediate postoperative period and one further patient with episodic diarrhoea but neither histological nor radiological evidence of Crohn's disease.

Over one-half the patients subsequently underwent barium small and large bowel series, after a variable postoperative interval. No further areas of Crohn's disease were detected in any asymptomatic patient. All six patients who developed a recurrence had initially undergone appendicectomy; the remainder of the bowel was normal in one, the ileum was normal in two others, while the bowel was not examined further in the remaining three patients. No information was given about the appendix base.

The diagnosis of Crohn's disease is often achieved by a combination of histological features and radiological findings. X-ray investigation has no role to play in disease of the appendix; thus the histological picture has to be accurate to achieve the diagnosis. The characteristic features are transmural inflammation with oedema, fibrosis, fissuring and non-caseating epithelioid granulomata. There is often a predominance of lymphoid aggregates with scattered mixed infiltrates consisting of plasma cells, lymphocytes, eosinophils and neutrophils.

Although distinctive, the presence of granulomata *per se* is not diagnostic of Crohn's appendicitis. Similar granulomata are seen in sarcoidosis; appendiceal sarcoid, however, has only been reported in widespread systemic disease (8). The Kveim test is unhelpful in

achieving a differential diagnosis, being positive in 50% of patients with Crohn's disease.

In tuberculosis the granulomata are more confluent with central caseation, additionally acid-fast bacilli may be demonstrated by staining with the Ziehl-Nielsen technique. Primary appendiceal tuberculosis is nonetheless rare with less than 20 reported cases.

Currently, *Yersinia pseudotuberculosis* infection is probably the commonest differential diagnosis. Although the ileal form is more prevalent, appendiceal involvement also occurs. At operation the most striking feature is of an associated mesenteric lymphadenopathy. Histological examination most often reveals a superficial ulceration but in more severe disease necrotic granulomata or microabscesses may be present (9). Further confirmation of the diagnosis can be obtained by the demonstration of rising serological titres or by nodal culture.

Active granulomatous inflammation has been noted in response to schistosomal infiltration (10). Central viable ova are associated with a pronounced eosinophilic reaction. A similar picture is also seen with *Enterobius vermicularis* (11).

Although not found in this country, fungal diseases, for example histoplasmosis and blastomycosis, form part of the differential diagnosis in areas where these organisms are endemic. Actinomycosis is another possible infective cause.

The presence of a foreign body reaction (for example food particles or barium sulphate) will also excite a granulomatous response, although careful examination for doubly refractile material under polarised light should reveal the causative agent.

Appendiceal diverticulosis should be excluded as this also gives rise to chronic inflammation with induration and fibrosis of the appendix wall (12).

In an extensive review, Ewen *et al.* (13) showed that long-standing inflammation due to pyogenic organisms as in a resolving appendicular abscess does not give rise to the histological appearance of Crohn's disease. However, in his series of cases with granulomatous appendicitis, Allen and Biggart (6) noted that all specimens showed acute inflammation in addition to the underlying chronic changes. It is possible that the granulomatous disease exists in a quiescent form and is merely unmasked by the acute appendicitis.

In view of the reputation for postoperative fistula formation in Crohn's disease, it is interesting to note that the fistula reported in this series is the first recorded following appendicectomy for Crohn's disease of the appendix. In terminal ileal disease, fistulation may occur following appendicectomy as the laparotomy disturbs the adjacent diseased bowel. When there is a broad-based appendix and probably basal involvement in the inflammatory process it may be wiser to recommend a limited ileocaecal resection.

Despite the limited follow-up period there are strong indications that the likelihood of disease recurrence is far lower after surgery for Crohn's appendicitis than for

small bowel or colonic disease. It is customary teaching that if an obviously inflamed appendix is found at operation the remainder of the abdomen is not examined for fear of disseminating infection, a coexistent segment of Crohn's disease might thus be overlooked. It is possible that so-called Crohn's disease of the appendix in fact comprises two separate entities. First, true Crohn's disease in which simultaneously affected portions of the bowel are overlooked at the initial operation, or in which the appendiceal disease acts as a herald to the likely future development of Crohn's disease. Second, granulomatous appendicitis which is a benign condition unrelated to Crohn's disease and which is cured by appendicectomy.

As postoperative barium studies were completely normal in all asymptomatic patients and were of no value in predicting which patients were likely to develop recurrent disease we cannot recommend them for routine usage. The longest recorded interval between initial surgery and recurrence is 4 years, the prognosis after this period of follow-up is therefore excellent. Prior to that the prognosis is optimistic but guarded as a small percentage will go on to develop further evidence of Crohn's disease.

References

- 1 Crohn BB, Ginzburg L, Oppenheimer GD. Regional ileitis: a pathologic and clinical entity. *JAMA* 1932;99:1323-9.
- 2 Warren S, Sommers SC. Cicatrizing enteritis (regional ileitis) as a pathologic entity: analysis of 120 cases. *Am J Pathol* 1948;24:475-501.
- 3 Larsen E, Axelsson C, Johansen A. The pathology of the appendix in morbus Crohn and ulcerative colitis. *Acta Pathol Microbiol Immunol Scand [Suppl]*. 1970;212:161-5.
- 4 Meyerding EV, Bertram HF. Nonspecific granulomatous inflammation (Crohn's disease) of the appendix: case report. *Surgery* 1953;34:891-4.
- 5 Wang TK, Tolnai G, Campbell JS, Sirois J, Liepa E. Crohn's disease of the appendix. *Can Med Assoc J* 1972;106:233-6.
- 6 Allen DC, Biggart JD. Granulomatous disease in the vermiform appendix. *J Clin Pathol* 1983;36:632-8.
- 7 Yang SS, Gibson P, McCaughey RS, Arcari FA, Bernstein J. Primary Crohn's disease of the appendix. Report of 14 cases and review of the literature. *Ann Surg* 1979;189:334-9.
- 8 Macleod IB, Jenkins AM, Gill W. Sarcoidosis involving the vermiform appendix. *J R Coll Surg Edinb* 1965;10:319-23.
- 9 El-Maraghi NRH, Mair NS. The histopathology of enteric infection with *Yersinia pseudotuberculosis*. *Am J Clin Pathol* 1979;71:631-9.
- 10 Satti MB, Tamimi DM, Al Sohaibani MO, Al Quorain A. Appendicular schistosomiasis: a cause of acute clinical appendicitis. *J Clin Pathol* 1987;40:424-8.
- 11 Vinuela A, Fernandez-Rojo F, Martinez-Merino A. Oxyuris granulomas of pelvic peritoneum and appendicular wall. *Histopathology* 1979;3:69-77.
- 12 Clark RM. Microdiverticula: A possible cause of granulomatous ileocolitis. *Can Med Assoc J* 1969;100:1025-31.
- 13 Ewen SWB, Anderson J, Galloway JMD, Miller JDB, Kyle J. Crohn's disease initially confined to the appendix. *Gastroenterology* 1971;60:853-7.

Received 21 January 1988