

The value of angiography in the surgical management of pancreatic disease

GRAHAM V N APPLETON MA FRCS

Surgical Research Fellow

NICHOLAS C G BATHURST FRCR DMRD

Senior Registrar in Radiodiagnosis

JIM VIRJEE FRCR DMRD

Consultant Radiologist

Departments of Surgery and Radiology, Bristol Royal Infirmary

MARTIN J COOPER MS FRCS*

Consultant Senior Lecturer in Surgery

ROBIN C N WILLIAMSON MD MChir FRCS

Professor of Surgery

Key words: PANCREATIC ANGIOGRAPHY; PANCREATIC RESECTION; PANCREATIC CANCER

Summary

Selective visceral angiography should help to determine the nature and extent of pancreatic lesions and their suitability for resection. Between 1980 and 1987 coeliac and superior mesenteric angiograms were obtained in 76 patients considered for pancreatic resection. Anomalous arterial anatomy was delineated in 25%. Among arterial abnormalities observed in 42 patients (55%), increased or decreased vascularity and displacement were of limited diagnostic value, but encasement correctly predicted cancer in 18 of 21 cases and irresectability in nine of these. When present (17%), invasion or occlusion of the portal or superior mesenteric vein was even more accurate, indicating cancer in 12 of 13 cases and irresectability in 11 of these. Hepatic metastases were only detected in 7 of 15 patients (47%). Overall, angiography confirmed the diagnosis in 54%, localised the lesion in 64% and correctly forecast irresectability in 58%. Misleading data were obtained in five patients. There were no complications.

Introduction

Angiographic demonstration of the abdominal vasculature was successfully achieved 46 years ago via the transfemoral route (1). Although abnormal circulation from carcinoma of the pancreas was shown by translumbar aortography in 1954 (2), Seldinger's use of flexible catheters (3) allowed selective cannulation of the coeliac axis and superior mesenteric artery and thus more accurate assessment of pancreatic disorders. The further refinement of subselective angiography has recently been shown to increase the accuracy of the test (4).

Pancreatic arteriography was a useful diagnostic tool until the mid-1970s, when newer techniques usurped its place as a screening procedure. Endoscopic retrograde cholangiopancreatography (ERCP), ultrasonography and computed tomography (CT) are less invasive and

more accurate in this regard (5,6). It has been suggested that angiography is valuable in planning a pancreatectomy because it can delineate anomalous arterial anatomy and the likely feasibility of resection (7,8). The present study is the first British series to evaluate the exact contribution of pancreatic angiography to the surgical management of pancreatic disease.

Patients and methods

Between 1980 and 1987, 76 patients in whom a pancreatic resection was considered in the University Department of Surgery at Bristol underwent simultaneous coeliac and superior mesenteric angiography. Case notes have been examined and the mode of presentation, final diagnosis and type of surgical procedure recorded. For carcinoma of the pancreas our policy has been to perform angiography as the last preoperative investigation in those patients considered potential candidates for resection.

TECHNIQUE OF ANGIOGRAPHY

Arteriography was performed by means of 7G sidewinder catheters (Cordis) inserted into the femoral artery in the groin using the Seldinger technique (3). The superior mesenteric artery (SMA) and the coeliac axis were catheterised in turn. Subselective catheterisation of the splenic artery was carried out when indicated to improve visualisation of the splenic and portal veins. Injections of Omnipaque® 300 (Nyegaard) at 6 ml/s were made using a Siemens injection pump (Simtrac®), with a total dose of 50 ml for the SMA and 60 ml for the coeliac axis. Radiographs were exposed initially at a rate of 2/s for 3 s and then at 3 s intervals up to 15 s for the venous phase. When considered necessary the subtraction technique was used to enhance the images. There were no technical failures and no complications of note attributable to the procedure. Coagulation status was corrected in all jaundiced patients before angiography by means of parenteral vitamin K.

* Present appointment: Consultant Surgeon, Royal Devon and Exeter Hospital, Exeter

Present appointment and correspondence to: Professor R C N Williamson, Department of Surgery, Royal Postgraduate Medical School, Du Cane Road, London W12 0HS

ANGIOGRAPHIC ABNORMALITIES

All arteriograms were reviewed retrospectively by both radiologists who were unaware of the final diagnosis. The presence or absence of arterial anomalies of the major branches of the coeliac and superior mesenteric arteries was noted. Changes in calibre and course of the pancreatic arterial supply were recorded under four headings: hypervascularity, hypovascularity, arterial encasement and arterial displacement. Narrowing or total obstruction of the portal, superior mesenteric or splenic veins was recorded in the radiological report, as well as the presence of any large venous collaterals. A lesion was considered irresectable if there was encasement of a major extrapancreatic artery (hepatic, splenic, superior mesenteric), if there was narrowing or occlusion of the portal or superior mesenteric veins, or if hepatic metastases were seen (7).

Results

PATIENTS AND DIAGNOSIS

There were 46 men (61%) and 30 women (39%), with a median age of 52 years (range 14–75 years). Final diagnoses included carcinoma of the pancreas in 43 patients, chronic pancreatitis in 21 and endocrine tumours in 9 (Table I). There were 29 jaundiced patients (38%).

ARTERIAL ANOMALIES

A major variation to the normal arterial pattern was observed in 19 patients (25%) (Table II). The most common deviant was an abnormal origin of the right hepatic artery from the SMA, which occurred in 14% of all patients (Fig. 1(a,b)). In 6.5% the gastroduodenal artery originated from the left hepatic artery. Other abnormalities were uncommon.

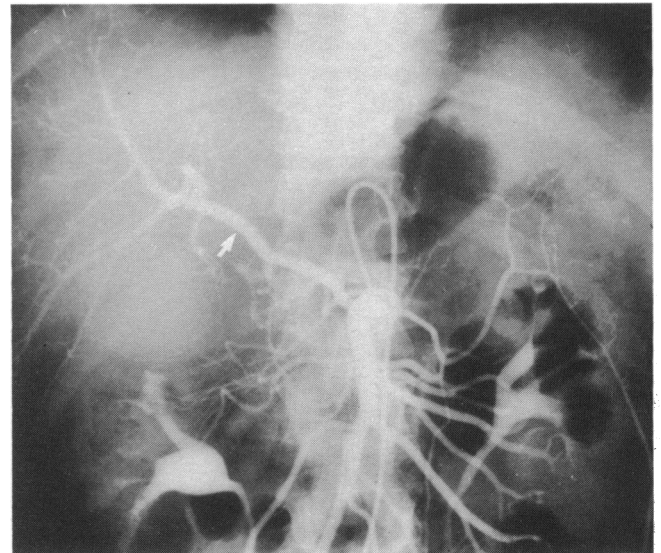
TABLE I Diagnosis in 76 patients undergoing pancreatic angiography

	n=76	%
Carcinoma of pancreas	43	56
Chronic pancreatitis	21	28
Endocrine tumours	9	12
insulinoma	5	
gastrinoma	2	
non-functioning	2	
Cystic neoplasms	3	4

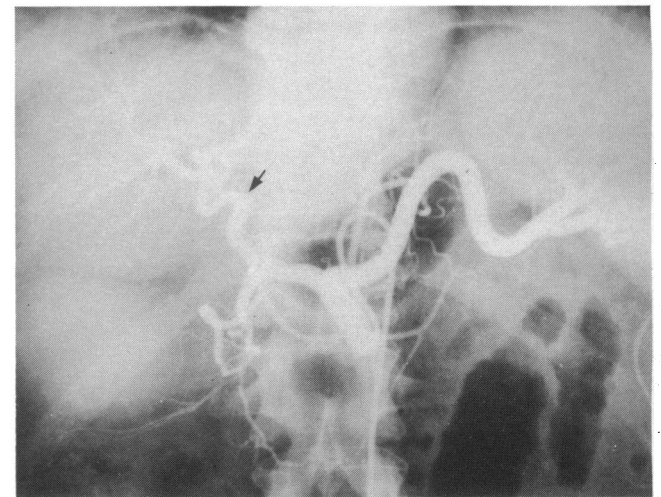
TABLE II Percentage of patients showing arterial anomalies: comparative series

Anomaly	Present series	Mackie et al. (16)	Odnoralov (19)	Redman and Reuter (18)	Michels (20)
RHA from SMA	14	12	Rare	12.5	11
GDA from LHA	6.5	1	—	—	—
CHA from SMA	1	2	2	—	4.5
LHA from LGA	1	4	Rare	—	10
CHA bifurcating at origin	2.5	—	—	—	—
Accessory LHA from LGA	—	—	16	—	8
Total	25	19	18	12.5	33.5

RHA=right hepatic artery. LHA=left hepatic artery. CHA=common hepatic artery. GDA=gastroduodenal artery. LGA=left gastric artery.



(a)



(b)

FIG. 1 (a) Selective superior mesenteric angiogram showing right hepatic artery (arrowed) arising from the superior mesenteric artery. (b) Same patient's coeliac angiogram showing the only hepatic branch is the left hepatic artery (arrow).

ARTERIAL SIGNS

The most useful indicator of pancreatic malignancy was encasement (Fig. 2). Encasement of major extrapancreatic arteries was seen in 10 patients, and encasement of

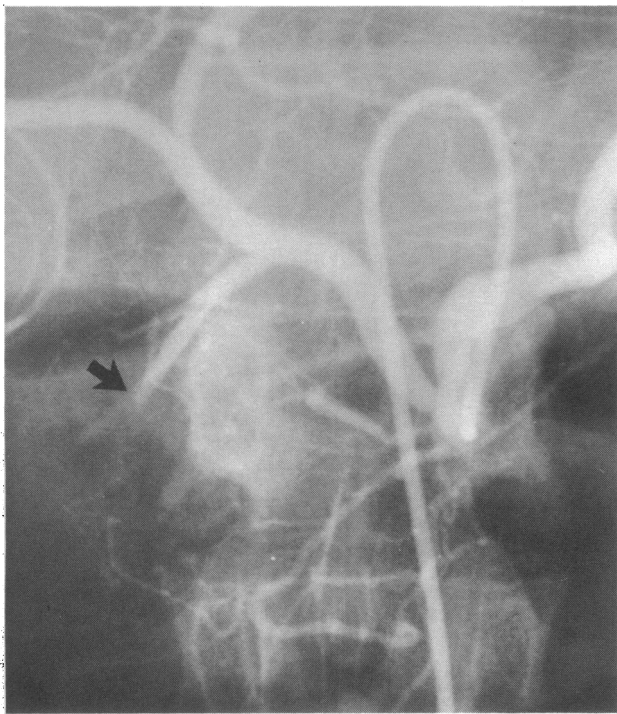


FIG. 2 Enlarged view of coeliac angiogram showing encasement (arrowed) of gastroduodenal artery owing to irresectable carcinoma of pancreas.

intrapancreatic arteries (including the gastroduodenal artery) was seen in 11 patients. Of these 21 patients, 18 (including all 10 with major artery encasement) had pancreatic cancer and one had a malignant insulinoma, but two had chronic pancreatitis; therefore encasement had a positive predictive value of 90% for cancer. Hypervascularity was found in 19 patients (Fig. 3); this sign localised three of five insulinomas, one of two gastrinomas and both the non-functioning islet-cell neoplasms. Thus two-thirds of the neuroendocrine tumours were accurately localised. Only nine of 43 patients with carcinoma of the pancreas had a 'tumour blush', however. Hypervascular lesions were also found in four patients with chronic pancreatitis. Displacement of vessels was seen in 18 patients (Fig. 4) and hypovascularity was present in eight patients, but only 44–50% of patients

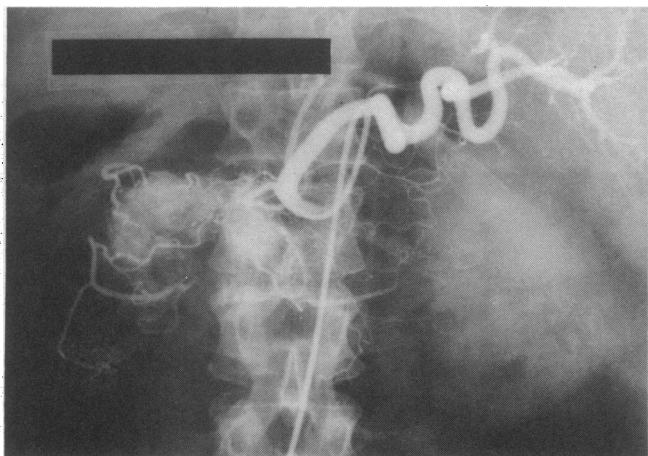


FIG. 3 Coeliac angiogram showing tumour blush owing to large neuroendocrine tumour in head of pancreas.

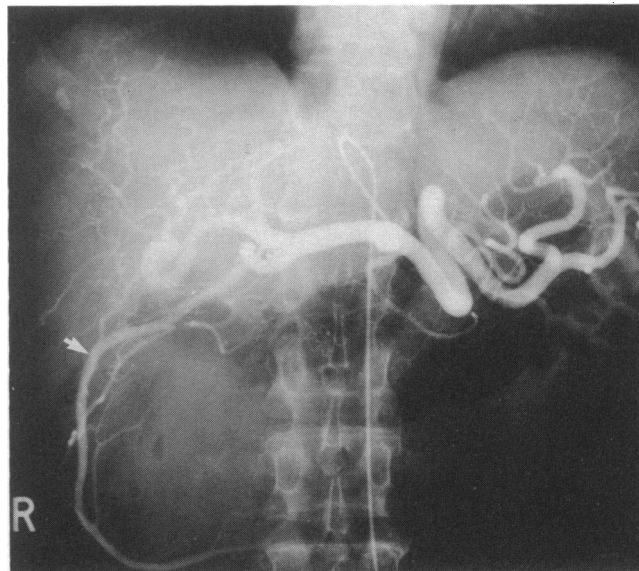


FIG. 4 Superior mesenteric angiogram showing displacement of gastroduodenal artery (arrowed) to right owing to cyst in head of pancreas.

with these signs had cancer. Overall, 16 of the 43 patients with pancreatic cancer had a normal arterial tree, giving a sensitivity of 63%. Chronic pancreatitis had no notable arteriographic features.

VENOUS LESIONS (Fig. 5(a,b))

Invasion, stenosis or occlusion of either the portal vein or superior mesenteric vein was present in 13 patients, 12 of whom had cancer and one chronic pancreatitis. The splenic vein appeared to be compromised in seven patients; five of these patients had cancer and two had chronic pancreatitis. Large collateral veins were seen in seven patients, of whom four had chronic pancreatitis.

HEPATIC METASTASES

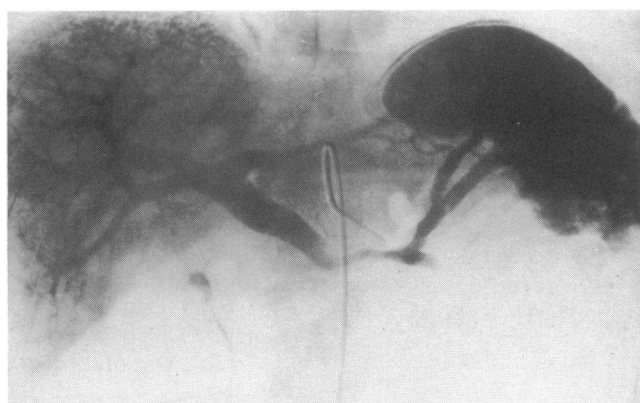
At operation 15 patients were found to have hepatic metastases. These deposits were correctly forecast by angiography in only seven cases (47%). One patient with a normal liver was diagnosed as having metastases.

RESECTABILITY

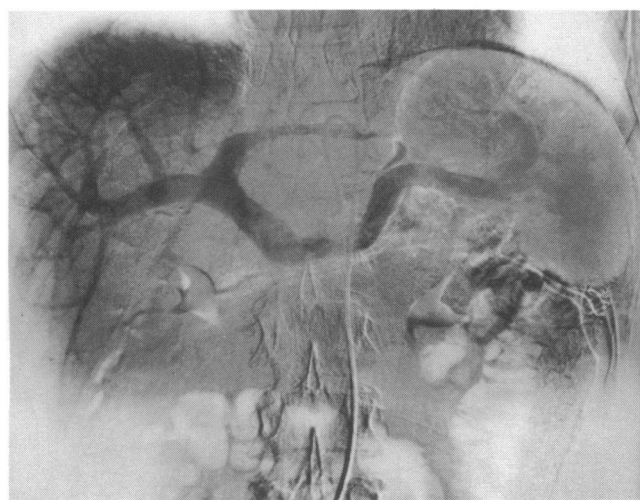At laparotomy 26 of the 43 patients with carcinoma of the pancreas (60%) were judged to have an irresectable lesion. We found that irresectability could be predicted by arteriography in 15 of these (58%). Invasion or occlusion of major veins was present in 11 patients, and nine had encasement of major extrapancreatic arteries in addition to the seven with hepatic metastases; these findings sometimes co-existed. Two patients with resectable pancreatic carcinoma were wrongly classified as irresectable; one was incorrectly judged to have splenic artery encasement and the other one had angiographic evidence of a narrow portal vein. Occlusion of the portal vein was seen in the venous phase of one patient with chronic pancreatitis. Thus pancreatic angiography had a positive predictive value of 83% for irresectability.

OVERALL PERFORMANCE

Angiography correctly diagnosed the lesion in 54%, provided no diagnostic help in 40% and offered misleading data in five patients (Table III). Angiography was



(a)



(b)

FIG 5(a) Subtraction film showing narrowing of splenic vein and origin of portal vein by an irresectable carcinoma of the pancreas. (b) Subtraction film showing normal venous phase. Splenic vein is slightly narrowed owing to flow artefact.

able to localise any lesion present in 49 patients (64%), and in a further 19 (25%) the surgeon was alerted to the presence of major arterial anomalies.

Discussion

We have used a retrospective analysis to try to estimate the potential value of angiography in patients in whom pancreatic resection is contemplated. Previous studies on the value of pancreatic arteriography have shown a widely varying diagnostic sensitivity from 29–100% (7,9–15). Prospective studies generally quote lower detection rates (16) than the more usual retrospective studies. The results support the contention that angiography is of

limited value in the routine diagnosis of pancreatic disease (7,8), especially so since the advent of ERCP and CT scanning. In our series the diagnosis could only be made in 54% of the films studied. However, in proven cases of pancreatic adenocarcinoma we found arterial encasement or hypervascularity in 63% of patients and venous narrowing or occlusion in 26%. By contrast, other series have reported obvious arterial signs in 90–100% of patients with pancreatic cancer and venous changes in 89–98% (9,14,17). Perhaps there was some lack of appreciation of the importance of the venous phase during the early years of the study, though our resectability rate was relatively high (33%).

The five patients with misleading arteriograms bear consideration (Table III). Three with chronic pancreatitis were diagnosed as having pancreatic cancer. Angiographic differentiation between these two conditions can be very difficult (16), and most series contain similar false positives (10,13). All diagnostic techniques are fallible in this regard, but the increased use of subselective catheterisation might bring greater accuracy (4). Of the two patients with resectable carcinomas thought to have irresectable lesions, arteriograms demonstrated that one had encasement of the splenic artery and one had narrowing of the portal vein. Patients with encasement may have resectable lesions (*vide infra*), and venous signs can occasionally be artefactual (Fig. 5b).

The incidence (25%) and distribution of arterial anomalies are in line with most other radiological series (8,18) except that of Odnoralov (19) and reflect Michel's classic cadaveric dissections in the 1950s (Table II) (20). Origin of the right hepatic artery from the SMA is the commonest variant (14%) (Fig. 1), and this information is useful during dissection of the superior mesenteric vessels at the time of pancreaticoduodenectomy (21). In this situation the right hepatic branch generally passes behind the pancreatic head and portal vein; operative injury risks segmental hepatic infarction especially in a deeply jaundiced patient (15).

Arteriograms helped to localise three of five insulinomas which gave a tumour blush. Previous papers report detection rates from 33–80% (7,22). Gastrinomas are notoriously difficult to find with rates as low as 15% (23), probably owing to hypovascularity (7). We were able to demonstrate one large primary tumour. Glucagonoma and somatostatinoma are easier to detect (90%) (7). Both our non-functioning islet-cell tumours were large and hypervascular.

The most reliable sign indicating irresectability of a pancreatic neoplasm was narrowing or obstruction of the portal or superior mesenteric vein. Among 13 patients in whom this sign was positive, 11 had irresectable lesions (85%); it is not our policy to resect and reconstruct the

TABLE III Patients (n=5) in whom angiography was misleading

Angiographic diagnosis	Correct diagnosis
Resectable carcinoma of pancreas (2)	Chronic pancreatitis (2)
Irresectable carcinoma of pancreas (2)	Resectable carcinoma of pancreas (2)
Irresectable carcinoma of pancreas +hepatic metastases	Chronic pancreatitis

portal vein. Like Buranasiri and Baum (14) we feel that careful assessment of the venous phase is most important. Angiographic evidence of splenic vein involvement (Fig. 5(a)) was less helpful—five patients out of seven had cancer (71%) but only three of these were irresectable (43%). Arterial encasement was only associated with irresectability in nine out of 21 patients (43%) (Fig. 2), though nine out of 10 patients with encasement of a major extrapancreatic artery had an irresectable lesion. There is little agreement in other reports about the significance of encasement. Some authors regard pancreatectomy as impossible if the gastroduodenal artery is encased (9), but Tylen and Arnesjo (12) feel that exploration is still indicated; either way the survival time of such patients is very poor (24). It seems that if a major extrapancreatic artery is encased, resection may well be fruitless. Hepatic metastases also indicate irresectability, but they were only identified in one-half of our patients, in line with other reports (15).

Other potential discoveries include the vascular complications of pancreatitis, such as erosion of vessels into the gastrointestinal tract and pseudoaneurysms, but we did not encounter such lesions in this series. When they are present, angiography offers a route for therapeutic embolisation (7).

We believe that routine selective visceral angiography is indicated in all patients in whom pancreatic resection is contemplated. Potentially important vascular anomalies are often detected, many endocrine and a few exocrine neoplasms can be localised, and resectability can be gauged with reasonable reliance. There were no complications directly attributable to angiography in the present study. Indeed Redman and Reuter (18) reported only six complications in 1700 patients examined.

We thank Miss Nicola Ederle for help with retrieving the arteriograms, and Miss Elizabeth Hurst for the illustrations.

References

- 1 Farinas PL. A new technique for arteriographic examination of the abdominal aorta and its branches. *AJR* 1941;46:641–7.
- 2 Rigler LG, Olfelt PC. Abdominal aortography for the roentgen diagnosis of the liver and spleen. *AJR* 1954;72:586–96.
- 3 Seldinger SI. Catheter replacement of the needle in percutaneous angiography. *Acta Radiol* 1953;39:368–76.
- 4 Rosch J, Keller FS. Pancreatic arteriography, transhepatic pancreatic venography, and pancreatic venous sampling in diagnosis of pancreatic cancer. *Cancer* 1981;47:1679–84.
- 5 Freeny PC, Ball TJ. Endoscopic retrograde cholangiopancreatography (ERCP) and percutaneous transhepatic cholangiography (PTC) in the evaluation of suspected pancreatic carcinoma: diagnostic limitations and contemporary roles. *Cancer* 1981;47:1666–78.
- 6 Hessel SJ, Siegelman SS, McNeil BJ *et al.* A prospective evaluation of computed tomography and ultrasound of the pancreas. *Radiology* 1982;143:129–33.
- 7 Freeny PC, Lawson TL. In: *Radiology of the Pancreas*. New York: Springer-Verlag, 1982.
- 8 Mackie CR, Noble HG, Cooper MJ, Collins P, Block GE, Moossa AR. Prospective evaluation of angiography in the diagnosis and management of patients, suspected of having pancreatic cancer. *Ann Surg* 1979;189:11–17.
- 9 Goldstein HM, Neiman HL, Bookstein JJ. Angiographic evaluation of pancreatic disease: A further appraisal. *Radiology* 1974;112:275–85.
- 10 Reuter SR, Redman HC, Bookstein JJ. Differential problems in the angiographic diagnosis of carcinoma of the pancreas. *Radiology* 1970;96:93–9.
- 11 Lunderquist A. Angiography in carcinoma of the pancreas. *Acta Radiol [Suppl]* (Stockh) 1965;235:1–143.
- 12 Tylen U, Arnesjo B. Resectability and prognosis of carcinoma of the pancreas evaluated by angiography. *Scand J Gastroenterol* 1973;8:691–7.
- 13 DiMugno EP, Malegalada J-R, Taylor WF, Go VLW. A prospective comparison of current diagnostic tests for pancreatic cancer. *N Engl J Med* 1977;297:737–42.
- 14 Buranasiri S, Baum S. The significance of the venous phase of celiac and superior mesenteric angiography in evaluating pancreatic carcinoma. *Radiology* 1972;102:11–20.
- 15 Mackie CR, Moossa AR, Frank PH. The place of angiography in the diagnosis and management of pancreatic tumours. In: Moossa AR ed. *Tumors of the Pancreas*. Baltimore: Williams & Wilkins, 1980:355–80.
- 16 Mackie CR, Cooper MJ, Lewis MH, Moossa AR. Non-operative differentiation between pancreatic cancer and chronic pancreatitis. *Ann Surg* 1979;189:480–7.
- 17 Levin D. Pancreatic angiography. In: Brooks JR ed. *Surgery of the Pancreas*. Philadelphia: W B Saunders, 1983: 90–108.
- 18 Redman HC, Reuter SR. Angiographic demonstration of surgically important vascular variations. *Surg Gynecol Obstet* 1969;129:33–9.
- 19 Odnoralov NI. Hepatic arteriography: gross anatomy. In: Schobinger RA, Ruzicka FF eds. *Vascular Roentgenology: Arteriography, Phlebography, Lymphography*. New York: Macmillan, 1964:368–82.
- 20 Michels N. *A Blood Supply and Anatomy of Upper Abdominal Organs*. Philadelphia: J B Lippincott, 1955.
- 21 Braasch JW, Gray BN. Technique of radical pancreatoduodenectomy with consideration of hepatic arterial relationships. *Surg Clin North Am* 1976;56:631–47.
- 22 Clouse ME, Costello P, Legg MA, Soeldner SJ, Cady B. Subselective angiography in localizing insulinomas of the pancreas. *AJR* 1977;128:741–6.
- 23 Mills SR, Doppman JL, Dunnick NR, McCarthy DM. Evaluation of angiography in Zollinger–Ellison syndrome. *Radiology* 1979;131:317–20.
- 24 Susuki T, Kawabe K, Imamura M, Honjo I. Survival of patients with cancer of the pancreas in relation to findings on arteriography. *Ann Surg* 1972;176:37–41.

Received 9 June 1988