

# The transoral approach to the base of the brain and upper cervical cord\*

H ALAN CROCKARD FRCS

Consultant Neurosurgeon  
The National Hospitals for Nervous Diseases, Queen Square  
University College Hospital and The Middlesex Hospital

**Key words:** CLIVUS TUMOUR; BASILAR INVAGINATION; ATLANTO-AXIAL SUBLUXATION; SCHWANNOMA; CORDOMA; BASILAR ANEURYSM

## Summary

*The transoral surgical approach allows access to structures from the sphenoid sinus rostrally to the fourth cervical vertebral body caudally. It is particularly useful for lesions at the anterior aspect of the craniocervical junction. Relief of the spinal cord compression in rheumatoid atlantoaxial subluxation can be achieved by this route. Removal of extradural and intradural tumours is possible using microsurgical techniques and watertight dural closure with the aid of fibrin glue.*

## Introduction

The base of the brain and the anterior aspects of the upper cervical spine continues to challenge despite the steady progress made over the past 60 years. As an example, tumours of the pituitary were approached trans-sphenoidally by Hirsch in Germany (1) and following his 'Wanderjahr', Cushing (2) adopted the technique. It was not until the introduction of the operating microscope, the availability of antibiotics and the use of accurate radiographic localisation that this surgical route was popularised and gained universal acclaim as the approach to most pituitary tumours (3,4). Extension of the transnasal approach has allowed surgical excision of lesions in the sphenoid and upper clivus (5).

The transoral approach to the anterior rim of the foramen magnum and the upper cervical spine was recommended in 1935 by Sherman (6) but popularised for treatment of infection in the area by Fang and Ong in 1962 (7). Since that time the route has been used for the surgical treatment of a variety of lesions, including congenital atlanto-axial dislocation (8), fracture dislocation (9), extradural tumours (10) and obliteration of a vertebrobasilar aneurysm (11).

In Britain, the technique was pioneered in the mid-seventies by Bonney (12,13) and Thompson (14). Over the next decade the method has been applied to many other conditions but there have been problems. Many reports describe complications such as failure of wound healing (15), rejection of bone graft (16), cerebrospinal fluid fistula and meningitis (17), respiratory arrest and tetraplegia (18).

Correspondence to: The National Hospitals for Nervous Disease, Queen Square, London WC1N 3BG

\*Based on the second Dr W F K Morrow Memorial Lecture in Belfast, November 1984

†The group participating in the transoral surgery include: A O Ransford FRCS Consultant Orthopaedic Surgeon, J L Pozo FRCS Senior Orthopaedic Registrar, I C Calder FFARCS Consultant Anaesthetist, L Loh FFARCS Consultant Anaesthetist, J Stevens FFR Consultant Neuroradiologist, B Kendall FFR Consultant Neuroradiologist

The Editor would welcome any comments on this paper by readers

Fellows and Members interested in submitting papers for consideration for publication should first read the Notice to Contributors in this issue

These have tempered many an acolyte's enthusiasm. Recently the routine use of the operating microsurgical instruments and biological tissue glues for dural repair have allowed a safer approach to the anterior brainstem.

The decision to employ the anterior surgical route instead of a more conventional posterior fossa exploration or cervical laminectomy depends on adequate radiological visualisation of the area. The availability of computerised tomography, computed myelotomography (19) and magnetic resonance imaging (20) has provided the surgeon with an unprecedented perspective of the area and revealed previously unconsidered aspects of pathology.

Team work has allowed evaluation and treatment of a wide variety of surgical pathology. Clearly without a combination of skills, anaesthetic, orthopaedic, neurosurgical and intensive care, our experience would have been reduced considerably. The author is reporting on behalf of a group listed below†.

The purpose of this paper is to present some of the conditions which are amenable to this approach.

## Surgical approach

### INTUBATION

In most patients it is not necessary to perform a tracheostomy; a nasotracheal armoured airway (Mallinkrodt) provides an adequate airway and can be retracted out of the surgical field without compromise to its lumen. The tube is left in situ postoperatively for at least 48 hours to provide optimal airway care. In those patients with bulbar palsies, prolonged airway care will require an elective tracheostomy. In a few, the exposure is limited and can be improved only by tracheostomy.

A nasogastric tube is passed to prevent postoperative regurgitation of gastric contents which might compromise the pharyngeal wound. Preoperative hyosine and postoperative antiemetics also reduce this possibility.

### EXPOSURE (FIG. 1)

Various modifications of the Boyle-Davis gag have been advocated (21,24,46) to allow exposure of the upper cervical vertebrae. The craniocervical junction and lower clivus become accessible without a soft palate split by using a Jacques catheter passed nasally and sutured close to the uvula, allowing retraction of the soft palate into the nasopharynx (21). To perform extensive surgery on the clivus it is necessary to divide the soft palate and extend the exposure to the hard palate. Using this extension it is possible to enter the

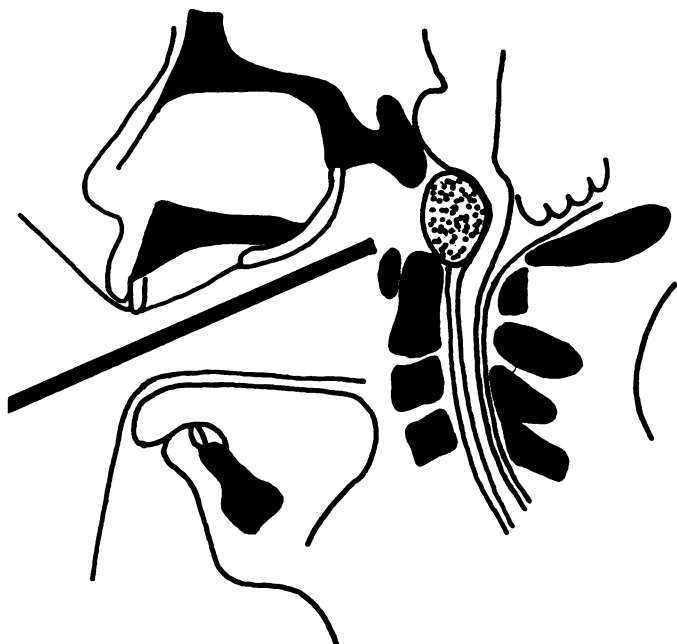


FIG. 1 A line drawing to illustrate the transoral, transclival approach to an anteriorly placed schwannoma which was successfully removed without post-operative cerebrospinal fluid fistula or meningitis (Reproduced from *J Neurosurg* 62:293-295, 1985).

sphenoid sinus anteriorly. At the cervical end of the exposure it is possible to operate on the body of the fourth cervical vertebra by manipulation of the Boyle-Davis gag. Thus the approach provides access for extensive anterior dural decompression. In some patients with rheumatoid arthritis involving the temporomandibular joint the mouth may only open one or two centimetres. Exposure in these cases has been achieved by a midline division of the mandible, lateral retraction of the two halves with depression of the tongue sufficient to permit surgical access. This is a much less vascular approach than the suprahyoid transglossal route.

Following infiltration with 1:200 000 adrenaline, a midline pharyngeal incision exposes the anterior longitudinal ligament. The relevant bone is removed with an air drill.

#### CLOSURE

For intradural procedures, peroperative cerebrospinal fluid drainage with a postoperative conversion to a lumboperitoneal shunt has been used in conjunction with a dural closure using the currently available fibrin glue (Tisseel). Using this technique cerebrospinal fluid fistula and meningitis have been avoided (22).

In contradistinction to other workers, we have used anterior bone grafting very occasionally and then only in the form of cancellous bone chips. Stability has been obtained with a posterior cervical fusion. The pharynx and palate (if incised) has been closed in two layers of interrupted Vicryl (Ethicon).

Meticulous attention to hygiene is provided in the post-operative period and the patient is maintained on tube or intravenous fluid and alimentation for three to five days to allow wound healing. There have been no postoperative complications with the pharyngeal wound to date, although some of the early cases required resuture of the palate.

#### FIXATION

Many of the reports in the literature emphasise external fixation before surgery (23), during the operation (24) and postoperatively (18). For the latter a halopelvic or Minerva jacket has been used for up to 6 months. Whilst this provides good fixation it is quite a burden for the patient particularly in those in whom respiratory function is compromised. Whilst initially skull traction was employed, we have now

moved to a combination of posterior fixation and bone grafting (25,26). A variety of methods of internal fixation have been employed; occipito-atlanto-axial interlaminar wiring, atlanto-axial interlaminar wiring, contoured Luqué rod fixation and O-ring fixation. Details of these are given elsewhere (25,26).

A premoulded collar is constructed for each patient and is applied at the end of the operative procedure.

#### MOBILIZATION

Using our present technique, firm internal fixation is obtained from the time of surgery thus allowing mobilization out of bed on the second or third day. In our experience there are considerably fewer complications, such as pulmonary embolism and chest infection, in these patients who are mobilised early as opposed to those of similar age who have been kept immobile in skull traction in the supine position.

#### Indications for transoral approach

There is an expanding body of literature on surgical pathology suitable for this approach. A table has been compiled to illustrate the extensive application of the technique to lesions at the base of the skull and on the anterior aspect of the brainstem (Table 1). Some will be considered in the following sections with attention focused on personal experience.

TABLE 1 Indications for transoral approach to the skull base and craniocervical junction

Bone
Trauma
Basilar impression
Rheumatoid arthritis
Extradural mass
Primary carcinoma
Metastasis
Abscess
Cordoma
Intradural mass
Schwannoma
Meningioma
Epidermoid
Cerebrovascular
Midbasilar aneurysm

#### FRACTURE DISLOCATIONS C1/2

Most of the fractures in this area are unstable and many are not diagnosed during life. Heulka *et al.* (27) estimated that 20% of *in car* deaths were associated with upper cervical fracture-dislocations. Fractures and/or dislocations in the area have been well illustrated using modern CT techniques. A posterior interlaminar wire and bone fusion has been widely used to good effect. If there is considerable anterior compression associated with the instability a transoral decompression may be combined with posterior fixation. Hall (28) and Harris (29) have described a modification of the Cloward (30) procedure transorally in which a dowel bone graft is placed on each side between adjacent lateral masses, but external fixation may be required if the fracture is unstable.

#### BASILAR IMPRESSION

Brain stem compression may occur if the clivus or the translocated odontoid peg impinge on the anterior cranio-spinal axis. Flexion and extension of the neck will not affect the deformity and there is no compression of the posterior aspect of the craniocervical junction. In this *stable* situation an anterior decompression would seem most logical and there may be no instability following the decompression.

Roberts (31) describes a transoral resection of clivus, anterior arch of C1 and odontoid peg in such a case. Derome *et al.* (5) have reported three cases, and Gilsbach and Eggert (24) describe 6 patients similarly successfully treated. Our experience of four stable basilar impressions has included one patient with profound infolding of the clivus due to osteogenesis imperfecta and in this patient at least half of the clivus was removed to effect a decompression. The importance of extensive anterior bony decompression was emphasised in another patient who required a second transoral procedure to remove most of the body of C2 as well as clivus before there was neurological improvement.

A second form of basilar impression is accentuated by head movements. There is radiographic evidence of compression of the brain stem posteriorly as well as anteriorly. This group of *unstable* deformities must have fixation in addition to wide decompression. Failure to recognise this preoperatively will have profound consequences. In Verbeist's series (18) two of the five cases were tetraplegic following resection of the odontoid peg alone. Posterior fixation without decompression has been associated with disaster. In our patients, the only death in over thirty transoral procedures occurred in a patient in whom an inadequate anterior decompression was performed. During the posterior fixation the cord was compressed further and the patient awoke tetraparetic. Though quickly recognised, a further transoral decompression failed to produce any recovery.

Another subgroup of unstable basilar impressions is described where a stable basilar impression has been treated initially by a posterior fossa decompression and upper cervical laminectomy, an *iatrogenic* unstable basilar impression. The history typically is one of modest or no improvement following the initial procedure and progressive spastic tetraparesis a few months after surgery. In one of the patients referred to us, the condition had progressed to respiratory difficulties, particularly when asleep—an Ondine's Curse\*—together with vertical nystagmus as signs of his severe brainstem compression.

In two such cases an extensive removal of clivus, anterior arch of C1, odontoid peg and body of C2 been combined with contoured loop fixation posteriorly (25).

#### RHEUMATOID ARTHRITIS

The atlanto-axial joint is frequently involved in longstanding rheumatoid arthritis and in a proportion (2–5%) is associated with a rapidly progressive cervical myelopathy which is fatal in half the cases within six months (32). Davis and Markley (33) drew attention to the medullary compression by the backward and upward subluxation of the odontoid peg. The progressive deterioration has not been arrested by collar or by intermittent traction. Posterior fusion was advocated by Newman and Sweetnam (34) and is perhaps the most commonly used procedure worldwide. That it improves some patients is undoubted but in each reported series there are a significant number of early deaths or immediate postoperative tetraparesis (35, 36). These *inevitable* deaths (37) may be due to anterior brain stem and cord compression as the posterior bony fixation is taking place.

With the use of computed myelotomography (19) there is a factor which we consider to be an important compressive agent: the pannus, or granulomatous tissue arising from the synovium. It is our opinion that in some cases this is as important as the bony deformity and would explain the sudden deaths in a proportion of the cases treated by posterior fusion alone. (Fig. 2)

To date we have operated on 17 patients with atlanto-axial problems due to rheumatoid arthritis without mor-

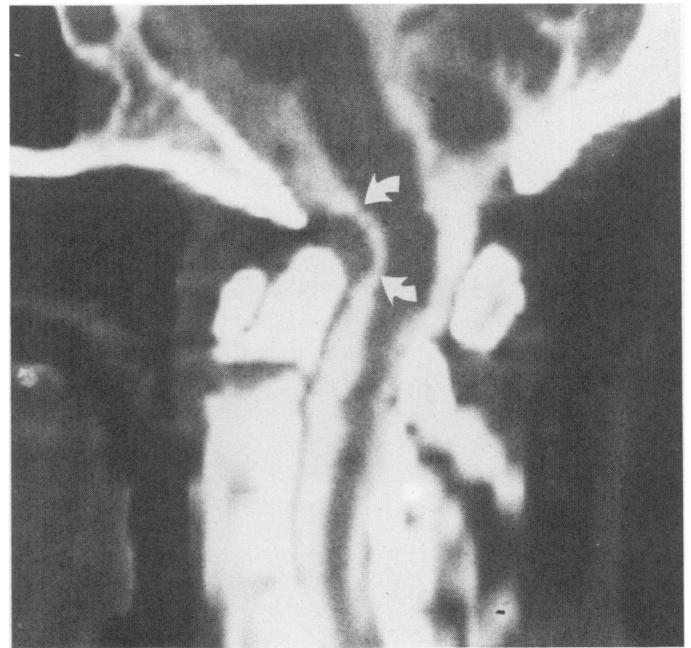


FIG. 2 Computed myelotomography illustrates the importance of the rheumatoid soft tissue pannus as a cause of the brainstem and spinal cord deformity. Note the effect of the pannus alone without bony subluxation.

tality. The assessment, investigation and surgery is described in detail elsewhere (19, 26, 38). The patients are assessed radiologically by computed myelotomography which indicates the bony destruction and the dural deformity caused by bone and pannus. Subluxation and rotational deformities can also be assessed with flexion and extension views. The surgical procedure has been a one stage, transoral odontoidectomy and removal of rheumatoid pannus followed by a posterior fixation and bone grafting. At the beginning we were somewhat hesitant to subject systemically ill patients to such surgical trauma and used a staged procedure with skull traction during and after operation. We were emboldened by the lack of postoperative complications with the one stage procedure in contrast to the incidence of pneumonia and pulmonary emboli associated with prolonged immobilisation in skull traction.

#### EXTRADURAL MASSES

Originally, Fang and Ong (7) popularised the surgical approach for infection at the craniocervical junction, particularly in tuberculosis. Lawrence and Bonney (12) have described longterm survival following excision of a breast carcinoma metastasis replacing the body of the axis. The approach was advocated by Mullan *et al.* (10) for extradural tumours and metastases.

Cordomas often arise in the clivus or upper cervical vertebra and palliative decompression has been achieved in the past by a posterior transdural approach. Part of the problem in the past may have been uncertainty of diagnosis but with current radiological techniques, the surgeon can be sure of the diagnosis before surgery. The transoral approach has allowed a more radical removal and an improved neurological state (39, 40). In our own experience a patient treated elsewhere by a posterior fossa decompression presented with progressive tetraparesis and investigations revealed a lesion emanating from the body of C2 extending upwards to the clivus and caudad to C4. A soft mass in the pharynx was responsible for her dysphagia. An extensive removal of C1 arch, the bodies of C2 and C3 and part of the body of C4 decompressed the dura and a contoured occipitocervical Luqué fixation provided the stability for immediate mobilization.

Metastatic tumours of the clivus or bony involvement by

\* Ondine was a water nymph who, following a transgression, was condemned never to sleep again. In neurology and neurosurgery it has become a very specific term to describe the patient who is afraid to go to sleep because when he does so he stops breathing.

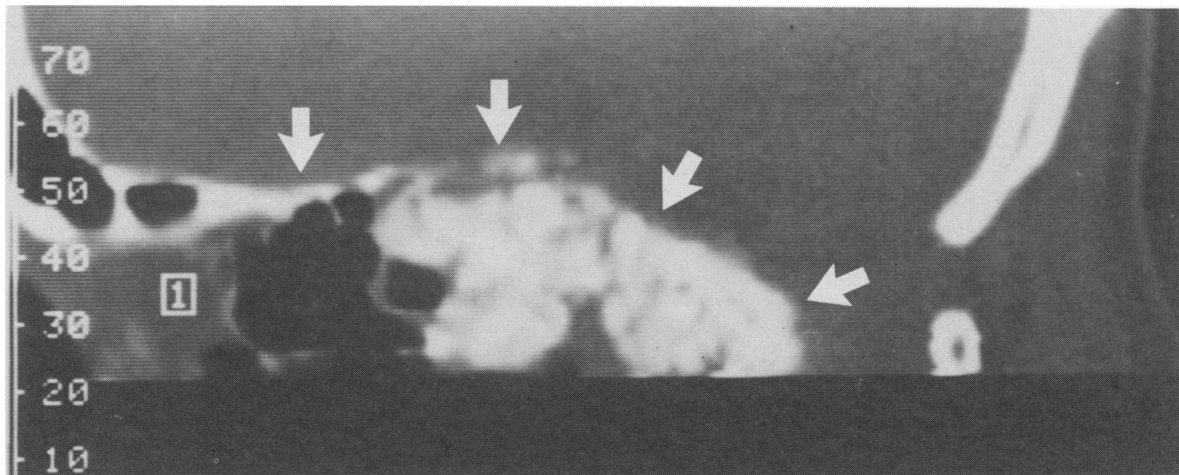


FIG. 3 CT scan of a metastatic lesion involving the whole of the clivus which was radically excised by the transoral route, prior to radiotherapy.

carcinoma of the nasopharynx may be successfully treated in a similar fashion (Fig. 3).

#### INTRADURAL MASSES

Theoretically anteriorly placed intradural tumours (Figs. 1 and 4) such as meningiomas, schwannomas or epidermoids are more amenable to a direct anterior surgical approach as the rootlets of the lower cranial nerves and the major branches of the posterior circulation will lie on their dorsal surface. The problems encountered by various workers have been the cerebrospinal fluid fistulae and meningitis due to the great difficulty in obtaining watertight closure. Reducing cerebrospinal fluid pressure during and immediately after surgery and closure of the dura with fibrin glue have been successful in our hands (22). In our experience the removal of the tumours was technically very much easier than by either the posterior or posterolateral route.

#### VERTEBROBASILAR ANEURYSMS

Five to ten percent of all intracranial aneurysms are on the posterior circulation (41,42) and these appear to have a

particularly high incidence of recurrent haemorrhage with surgery (43). Those situated at the vertebrobasilar junction are particularly inaccessible from a posterolateral suboccipital approach. Sano *et al.* (44) described a transoral approach to such lesions and other Japanese authors have also reported successful occlusion of the aneurysm using this technique. There are problems such as cerebrospinal fluid fistula and meningitis which have been discussed by Yamaura *et al.* (17). A major problem has been the length and shape of aneurysm clip applicators which must be over 20 cms in length. It is for these reasons that the route has been abandoned by Drake (45), although Pia (46) and Hitchcock and Cowie (47) still advocate this approach.

#### Conclusion

It has been the object of this communication to draw attention to the numerous possibilities offered by the transoral route and there is evidence that many conditions are treated better in this fashion. The essence of success is teamwork across the disciplines. The diseases, their investigation, surgery, postoperative care and rehabilitation are a challenge worthy of further exploration.

#### References

- 1 Hirsch O. Endonasal method of removal of hypophyseal tumours, with report of two successful cases. *JAMA* 1910; 55:772-4.
- 2 Cushing H. The pituitary body and its disorders. Clinical states produced by disorders of the hypophysis cerebri. Philadelphia: Lippencott 1912;116-8.
- 3 Hardy J, Wigser S. Transsphenoidal surgery of pituitary fossa tumours with televised radiofluoroscopic control. *J Neurosurg* 1965;23:612-9.
- 4 Wilson CB, Dempsey LC. Trans-sphenoidal microsurgical removal of 250 pituitary adenomas. *J Neurosurg* 1978;48:12-22.
- 5 Derome P, Caron JP, Hurth M. Indications de la voie trans-bucco-pharyngée et malformations de la charniere craniovertebrale. *Neurochirurgie* 1977;23:282-5.
- 6 Scoville WB, Sherman IJ. Platybasia: report of ten cases with comments on familial tendency, a special diagnostic sign and end results of operation. *Ann Surg* 1951;133:469-502.
- 7 Fang HSY, Ong GB. Direct approach to the upper cervical spine. *J Bone Jt Surg (Am)* 1962;44:1588-1604.
- 8 Greenberg AD, Scoville WB, Davey LM. Transoral decompression of atlanto-axial dislocation due to odontoid hypoplasia. *J Neurosurg* 1968;28:266-9.
- 9 Harris P. Atlanto-axial fracture dislocation treated by reduction and transoral bony fusion. *Proc 17th Spinal Cord Injury Conf. New York: V A Hospital, Bronx* 1969;17:40-5.
- 10 Mullan S, Naunton R, Hekmatpanah J, *et al.* The use of an anterior approach to ventrally placed tumours in the foramen magnum and vertebral column. *J Neurosurg* 1966;24:536-43.
- 11 Fox JL. Obliteration of midline vertebral artery aneurysm via basilar craniectomy. *J Neurosurg* 1977;47:115-8.

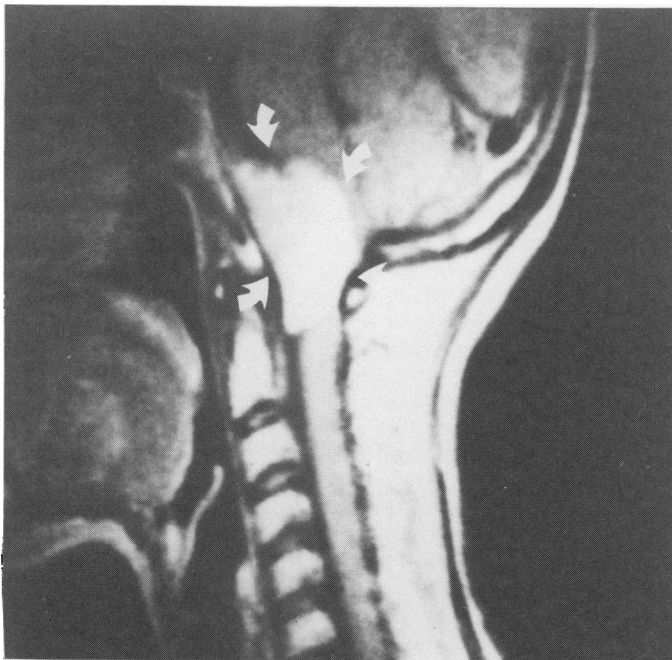


FIG. 4 Magnetic Resonance Imaging of meningioma of the anterior rim of foramen magnum illustrates the value of this investigation in diagnosis. The lesion was not noted on an uninfluenced CT scan of the area and became visible with computed myelotomography.

- 12 Laurence M. Malignant destruction of the axis. Two year survival. *Proc Roy Soc Med* 1969;62:585-6.
- 13 Bonney G. Stabilisation of the upper cervical spine by the transpharyngeal route. *Proc Roy Soc Med* 1970;63:896-7.
- 14 Thompson H. Transpharyngeal fusion of the upper cervical spine. *Proc Roy Soc Med* 1970;63:893-6.
- 15 Hayakaw AT, Kamikaw AT, Ohnishi T, *et al.* Prevention of postoperative complications after a transoral transclival approach to basilar aneurysms. *J Neurosurg* 1981;51:699-703.
- 16 Bonney G, Williams JPR. Transoral approach to the upper cervical spine. *J Bone Jnt Surg* (in press) 1985.
- 17 Yamaura A, Makino H, Isobe K, *et al.* Repair of cerebrospinal fistula following transoral/transclival approach to a basilar aneurysm. *J Neurosurg* 1979;50:83-4.
- 18 Verbeist H. Indications et possibilités de la voie trans-bucco-pharyngée. *Neurochirurgie* 1977;23:513-6.
- 19 Stevens J, Kendall BK, Crockard HA. The spinal cord in rheumatoid arthritis with clinical myopathy: A computed myelotomographic study. *J Neurol Neurosurg Psychiat* (in press) 1985.
- 20 Bydder GM, Pennock JM, Steiner RE, Orr JS, Bailes DR, Young IR. The NMR diagnosis of cerebral tumours. *Magnetic Resonance in Medicine* 1984;1:5-29.
- 21 Spetzler RF, Selman WR, Nash CL, *et al.* Transoral microsurgical odontoid resection and spinal cord monitoring. *Spine* 1979;4:506-10.
- 22 Crockard HA, Bradford R. Transoral transclival removal of a schwannoma anterior to the craniocervical junction. *J Neurosurg* 1985;62:293-5.
- 23 Meijers KAE, Van Beusekom GTM, Luyendijk W, *et al.* Dislocation of the cervical spine with cord compression in rheumatoid arthritis. *J Bone Jnt Surg (Br)* 1974;56:668-80.
- 24 Gilbasch J, Eggert H-R. Transoral operation for craniocervical malformations. *Neurosurg Rev* 1983;6:199-209.
- 25 Ransford AO, Crockard HA, Pozo JL, *et al.* Craniocervical instability treated by contoured loop fixation. *J Bone Jnt Surg* (in press, Jan 1986).
- 26 Crockard HA, Pozo JL, Ransford AO, *et al.* Transoral anterior decompression and posterior cervical fusion in rheumatoid atlanto-axial subluxation. *J Bone Jnt Surg* (in press, 1986).
- 27 Huelke DF, O'Day J, Mendelsohn RA. Fractures of the cervical spine in *in car* deaths following road traffic accidents. *J Neurosurg* 1981;54:316-23.
- 28 Hall JE, Denis F, Murray J. Exposure of the upper cervical spine for spinal decompression by a mandible and tongue splitting approach. *J Bone Jt Surg (Am)* 1977;59:121-3.
- 29 Harris P. Anterior approach to the cervical spine. In: Symon L. ed. *Operative Surgery (Neurosurgery)*. London: Butterworths 1979;458-62.
- 30 Cloward RB. The anterior approach for removal of ruptured cervical discs. *J Neurosurg* 1958;15:602-17.
- 31 Roberts L. Panel discussion III on Stevenson GC. Transcervical transclival craniotomy. In: *Proceedings third International Congress Neurological Surgeons*. Amsterdam: 1966;514.
- 32 Marks JS, Sharp PJ. Rheumatoid cervical myelopathy. *Quart J Med* 1981;199:307-19.
- 33 Davis FW, Markley HE. Rheumatoid arthritis with death from medullary compression. *Ann Int Med* 1951;35:451-61.
- 34 Newman P, Sweetnam DR. Posterior fusion for atlanto-axial subluxation in rheumatoid arthritis. *J Bone Jt Surg (Br)* 1969;51:423-8.
- 35 Meijers KAE, Cats A, Kremer HPH, *et al.* Cervical myelopathy in rheumatoid arthritis. *Clin Exp Rheum* 1984;2:239-45.
- 36 Christophidis N, Huskinsson EC. Misleading symptoms and signs of cervical spine subluxation in rheumatoid arthritis. *Br Med J* 1982;285:364-5.
- 37 Hamblen DL. *Postgraduate textbook of clinical orthopaedics*. Bristol: Wright 1983;487-97.
- 38 Crockard HA, Essigman W, Stevens JM, *et al.* Surgical treatment of cervical cord compression in rheumatoid arthritis. *Ann Rheum Dis* (in press, 1985).
- 39 Windle-Taylor PC. Cervical cordoma: report of a case and the technique of transoral removal. *Br J Surg* 1977;64:438-41.
- 40 Pasztor E, Vajda J, Piffko P, *et al.* Transoral surgery for craniocervical space occupying processes. *J Neurosurg* 1984;60:276-81.
- 41 McCormick WF, Notzinger JD. Saccular intracranial aneurysm. An autopsy study. *J Neurosurg* 1965;22:155-9.
- 42 Locksley HB. Natural history of subarachnoid haemorrhage, intracranial aneurysms and arteriovenous malformations. *J Neurosurg* 1966;25:219-39.
- 43 Troupp H. The natural history of aneurysms of the posterior circulation. *Acta Neurol Scand* 1971;47:350-6.
- 44 Sano K, Jin BOM, Saito I. (Vertebrobasilar aneurysms with special reference to the transpharyngeal approach to the basilar artery aneurysm). *No. To. Shinkel* 1966;18:1197-1203(Jpn).
- 45 Drake CG. Management of cerebral aneurysms. *Stroke* 1981;12:273-83.
- 46 Pia HW. Transoral transclival approach. In: Pia HW, Langmaid C, Zierski J. eds. *Cerebral aneurysms*. Heidelberg: Springer-Verlag 1979;329-31.
- 47 Hitchcock E, Cowie R. Transoral-transclival clipping of a midline vertebral artery aneurysm. *J Neurol Neurosurg Psych* 1983;46:446-8.