

## CROHN'S DISEASE

J. F. BOLTON CARTER, F.R.C.S., M.R.C.P.

*Assistant in the Surgical Unit, University College Hospital Medical School*

Chronic granuloma of the small intestine was first described by Coombe and Saunders in 1813. One hundred years later, Dalziel recognized a condition of chronic interstitial enteritis which was not tuberculous in origin. Regional ileitis, however, did not really come into prominence until 1932, when Crohn, Ginzburg, and Oppenheimer gave it this name, and it is now more popularly known as Crohn's disease. Their paper was so complete, that although the condition is now, much more widely recognized, and there have been many long-term follow-ups recorded, little more has been added to our knowledge of the aetiology, diagnosis, and treatment.

*Definition.* The term Crohn's disease is taken to include acute terminal ileitis, chronic regional ileitis, ileocolitis, regional colitis and jejunitis. It is convenient to separate acute terminal ileitis from the chronic forms of the disease. The acute form may regress completely or may progress to the chronic form, while the disease may manifest itself primarily as a chronic condition. Some writers, notably Armitage and Wilson (1950), doubt that acute terminal ileitis is the same entity and state that ten acute cases, followed-up by them, did not progress to the chronic phase. In the follow-up to be described in this paper, it will be seen that progression was not uncommon.

### Pathology

#### *Acute Ileitis*

The disease begins in the terminal 8 to 10 in. of the ileum, and ends at the ileocaecal valve; it does not, as a rule, involve the caecum or appendix. There may be further isolated lesions higher up the ileum. In the acute stage the diseased area is bright red and hyperaemic, and feels thickened on palpation. There is free sero-sanguineous exudate in the peritoneal cavity and the adjacent mesentery may contain enlarged 'fleshy' glands. There is oedematous thickening of the submucous layer of the intestine with engorgement of vessels. The mucosa is hyperaemic and occasionally contains shallow ulcers.

Homb (1946) describes the microscopic picture of the acute stage as an inflammatory infiltration of all layers with lymphocytes, leucocytes, eosinophils, large mononuclear and plasma cells.

*Chronic forms.* The disease may have progressed from the acute stage or be found as a primary chronic condition. Again the commonest site of origin is the terminal 8 to 10 in. of the ileum. It can, however, occur as a solitary lesion higher in the ileum or jejunum, or in the colon, and there may be multiple areas with healthy bowel in between. The naked eye and palpable change from the healthy to the thickened and stenosed bowel is sudden and obvious, but there is nearly always microscopic evidence of submucous spread beyond this. If there has been secondary infection fistulae and abscess formation may occur. The fistulae present on the exterior through a laparotomy scar or in the anal region, or are internal, to an adjacent loop of bowel. Free perforation has been described, but is rare. The mesentery is strikingly thickened and fatty, but enlarged glands, although the rule, are not always present. The submucosa is thickened and this distorts the normal mucosal pattern, throwing it up irregularly—the so-called 'cobblestone' appearance; there may be shallow ulceration between the cobblestones and it is through this ulceration that the secondary infection occurs. Hadfield, in 1939, described the essential microscopic features. There is a proliferation of the submucosal lymph follicles with lymphoedema, endothelial cell proliferation, and frequently giant cell systems. Caseation is never seen and tubercle bacilli cannot be isolated. Similar microscopic changes are seen in the regional glands, when these are involved. As the disease progresses, the giant cell systems may be completely obscured by the secondary inflammation and fibrosis.

*Aetiology.* The aetiology of the condition remains a mystery. There is no evidence that it is caused by a virus or any specific organism. It is most like tuberculosis, and Hadfield originally suggested that it might be a manifestation of

sarcoidosis, but the other changes associated with sarcoidosis have not been described in Crohn's disease. Felsen (1936) has reported its occurrence as a sequel of acute-bacillary dysentery in three cases. It is possible that the process is initiated by organisms having a predilection for lymphoid tissue, and once the lymphatic block has been effected, the disease is maintained by secondary invading organisms.

The acute phase has the appearance of an allergic reaction, and the possibility of the disease being due to sensitization to a foreign protein has not been excluded. A few cases have been described in which it was noted that the small intestine was abnormally short; if this was shown to be associated with steatorrhoea then faulty fat absorption could be postulated as an important factor. Anxiety states and emotional immaturity are frequently associated with the condition—the disease may be allied to ulcerative colitis—there are numerous examples of a familial incidence. The recent work of Chess *et al.* (1950) is of interest. They produced in the intestines of dogs, lesions characteristic of Crohn's disease, by feeding them with fine sand. It is even suggested that the ingestion of certain types of toothpaste might have a similar effect in man!

*Clinical features.* The acute form simulates appendicitis; a history of diarrhoea and the presence of a mass in the right iliac fossa should suggest the possibility of the disease, but in the majority of cases acute appendicitis can only be excluded with safety, by laparotomy. The manifestations of the chronic forms of the disease are protean. When there is ulceration of the mucosa, the symptoms are those of an enteritis with diarrhoea and sometimes melaena; nutritional defects may be associated. There is nearly always stenosis in the chronic phase, therefore there will be symptoms of chronic small bowel obstruction, which should be differentiated from the recurrent acute obstructive episodes which frequently supervene.

Fistulae in ano, may be associated with the condition, having a high communication with the involved bowel. A persistent faecal fistula following appendicectomy, with a continuance of the symptoms for which laparotomy was performed, should always suggest the diagnosis. Intra-peritoneal abscesses around the involved bowel are not uncommon, but frank perforations are very rare.

*Differential diagnosis.* Intestinal neoplasms, other granulomata and lymphomatous lesions, all have to be excluded. The diagnosis is usually made on the X-ray signs. The typical X-ray appearance of the chronic phase was described by Kantor in 1934. The barium follow-through

shows the stenosed segment of terminal ileum several inches in length, often narrowed to the diameter of a piece of string—hence his term 'string sign' (Fig. 5). An earlier manifestation of the disease seen in the barium follow-through is an indentation of the caecum on its medial wall, caused by the thickened terminal ileum.

The screening of the follow-through has to be performed with diligence as there is always 'intestinal hurry' and unless the radiologist is alert the lesion is easily missed. If the follow-through is negative, a barium enema may outline the diseased terminal ileum. The X-ray changes characteristic of the disease are occasionally discovered in the absence of any symptoms.

*Treatment.* The ensuing follow-up demonstrates the disappointing results of treatment of this condition, and it is the object of this paper to outline a logical approach to the problem.

The follow-up comprises 26 cases which have been treated in University College Hospital since 1935; 14 of these 26 cases presented acutely.

#### *Acute Terminal Ileitis*

All the cases in this group had the signs and symptoms of acute appendicitis, none had a history longer than a week, and only one of the 14 gave a history of diarrhoea. The diagnosis in all these cases was established by emergency laparotomy (Table 1).

The table shows the operative procedures performed on these 14 cases. It is important to note that three cases out of nine, in which appendicectomy was performed, subsequently developed faecal fistulae.

TABLE I  
ACUTE TERMINAL ILEITIS. EMERGENCY LAPAROTOMIES

| 14 Cases   | Operative Procedure Undertaken                  |
|------------|---|
| In 9 cases | Appendicectomy performed—3 subsequent fistulae. |
| In 3 cases | Nothing done. Abdomen closed.                   |
| In 1 case  | Immediate excision.                             |
| In 1 case  | Immediate ileocolostomy without exclusion.      |

Crohn in his book records a series of 12 acute cases, three of which also developed faecal fistulae following appendicectomy. In none of the U.C.H. cases did the appendix show evidence of involvement or inflammation.

The follow-up results of these 14 cases is shown in Table 2. Eight out of the 14 progressed into the chronic phase of the disease.

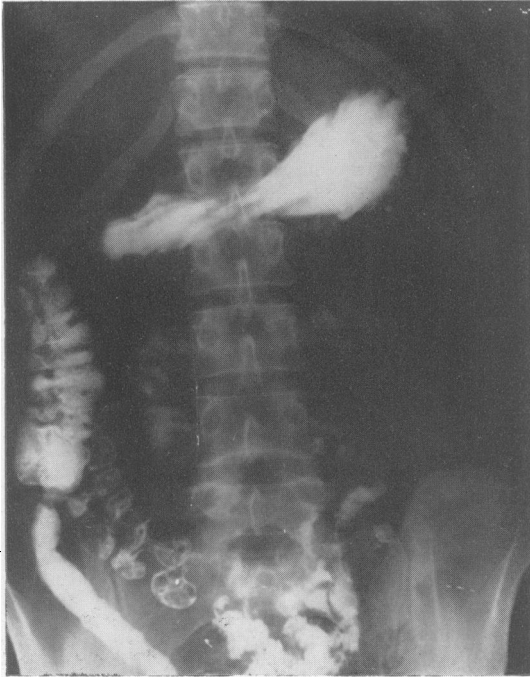


FIG. 1.—Recurrence in terminal ileum immediately adjacent to anastomosis to ascending colon. Barium follow-through performed one year after emergency resection of acute terminal ileitis.

TABLE 2  
FOLLOW-UP RESULTS OF THE 14 CASES OF ACUTE  
TERMINAL ILEITIS

| Treatment                          | Condition Resolved | Condition Pro-gressed | Death |
|------------------------------------|--------------------|-----------------------|-------|
| Appendicectomy ..                  | 3                  | 6                     | —     |
| Nothing done ..                    | 2                  | 1                     | —     |
| Immediate excision ..              | —                  | 1                     | —     |
| Ileocolostomy without exclusion .. | —                  | —                     | 1     |
| Total ..                           | 5                  | 8                     | 1     |

The patient who had an ileocolostomy without exclusion was not relieved. Severe diarrhoea followed the operation—two months later he had a resection and died shortly afterwards from inanition.

The case that was treated by immediate right hemicolectomy showed evidence of recurrence one year later (Fig. 1). The patient suffers from intermittent diarrhoea and occasional attacks of abdominal pain. She is at present being watched.

Four of the five patients whose symptoms were relieved following exploratory laparotomy now

have no X-ray evidence of disease. In the fifth case laparotomy was performed in 1942. The terminal 6 in. of the ileum were found to be acutely inflamed. Appendicectomy was performed, and he made an uneventful recovery. A barium follow-through performed three months after his operation showed slight rigidity and stenosis of his terminal ileum on screening. When seen in 1950, although he had had no more signs and symptoms, a further barium follow-through was done; this still showed the same positive X-ray signs. It is possible that this patient may yet develop a recurrence of symptoms even after this length of time.

*Discussion.* From this small series of acute cases it would seem that appendicectomy in the presence of an acutely inflamed terminal ileum is to be avoided if possible, as there is a danger of faecal fistula. In no case in the series did a fistula occur when the appendix was not removed.

Resection and by-passing operations in the acute stage carry a definite mortality and recurrence rate. This is confirmed in Crohn's series.

A proportion of cases undoubtedly subside if nothing is done. Therefore, once the diagnosis of appendicitis has been excluded by laparotomy, and the diagnosis of Crohn's disease established, the abdomen should be closed. Careful follow-up is necessary.

*Chronic group.* The follow-up of this group comprises cases of regional ileitis, jejunitis and colitis. Those cases of acute ileitis which progressed into the chronic phase are also included.

All the patients gave histories of attacks of chronic, or intermittent subacute, intestinal obstruction, associated in some cases with loss of weight and lethargy.

Table 3 shows the ages of the patients. It can be seen that the majority lie between 20 and 40.

TABLE 3  
AGE OF PATIENTS IN YEARS

|   |    |    |    |    |    |
|---|----|----|----|----|----|
| 9 | 21 | 30 | 40 | 51 | 64 |
|   | 21 | 30 | 42 | 58 | 65 |
|   | 22 | 30 | 45 | 59 |    |
|   | 23 | 33 | 45 |    |    |
|   | 24 | 34 |    |    |    |
|   | 25 | 35 |    |    |    |
|   | 26 | 35 |    |    |    |
|   | 28 | 38 |    |    |    |

The sex distribution was approximately equal.

The associated complications are listed in Table 4. The two faecal fistulae were through the laparotomy scar following appendicectomy, and persisted until the disease was resected. The two fistulae in ano both occurred following resections, and both the patients still show evidence of recurrence of their disease. The polyarthritis

occurred in one of these two patients; it cleared up completely after two years. The pellagra occurred in a male patient who was restricting his diet in order to control his diarrhoea; it responded promptly to vitamin therapy. In one of the two

TABLE 4  
ASSOCIATED COMPLICATIONS IN CHRONIC GROUP

|   |                             |
|---|-----------------------------|
| 2 | Faecal fistulae.            |
| 2 | Fistulae in ano.            |
| 1 | Arthritis.                  |
| 1 | Pellagra.                   |
| 2 | Pulmonary tuberculosis.     |
| 1 | Severe hypochromic anaemia. |
| 2 | Steatorrhoea.               |

cases of tuberculosis an old lesion was found radiographically in the apex of the left lung, prior to intestinal resection. The other case was of more interest. This patient had originally developed a faecal fistula following appendicectomy in 1943. By 1946 he was getting persistent diarrhoea and colic. He had a palpable mass in his right iliac fossa. His barium follow-through showed matted rigid coils of lower ileum. In March 1948 he had a right hemicolectomy and the diagnosis of Chron's disease was confirmed by microscopy. A chest X-ray taken at that time, 1948, showed no abnormality. In 1950 he was seen again. He was complaining of some diarrhoea, but was otherwise well and working. A barium follow-through showed a mildly stenotic recurrence in his terminal ileum (Fig. 2). No treatment was advised at this time. He was next seen in 1952 complaining of epididymitis of acute onset which gradually developed the characteristics of an acid-fast lesion. A chest X-ray taken at this time showed that he also had a tuberculous focus at the apex of his right lung. His right testicle has been excised. He is having sanatorium treatment for his pulmonary tuberculosis. His barium follow-through is now negative, and he is free from diarrhoea for the first time for many years. Although the sections of bowel resected in 1948 have been carefully reviewed, there is no histological evidence that his two conditions are related.

The severe hypochromic anaemia occurred in a female patient aged 37 who had laparotomy for what was thought to be appendicitis in 1950. Acute terminal ileitis was diagnosed and the abdomen closed without appendicectomy. A barium follow-through, performed three months later, demonstrated a slightly stenosed terminal ileum. By 1952 she was complaining of increasingly severe attacks of pain in her right iliac fossa and a general feeling of malaise. Another follow-through showed slight but definite progress in the diseased portion of her terminal ileum (Fig. 3).

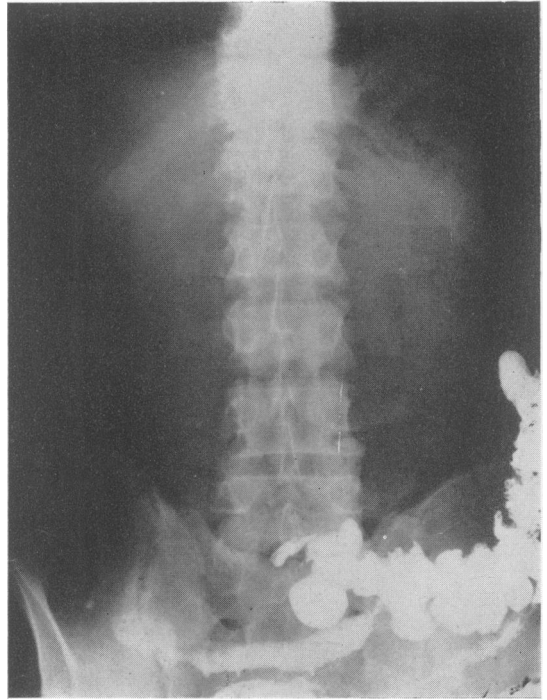


FIG. 2.—Barium follow-through two years after right hemicolectomy for Crohn's disease (1950), showing recurrence in terminal ileum at anastomosis. This patient subsequently developed pulmonary tuberculosis. Another barium follow-through done in 1952 shows the condition to have resolved. The patient is now symptom free (see text).

In view of the severity of her symptoms she was submitted to right hemicolectomy in August 1952. Following this, she was perfectly well until January 1953, when she began to develop palpitations, loss of weight and lethargy. A barium follow-through showed no abnormality, there was no diarrhoea and her faecal fat content was normal, but her haemoglobin was down to 40 per cent., when she was readmitted to hospital a month later. No other abnormality was discovered, her serum proteins and fractional test meal were normal. She had a severe hypochromic anaemia which responded to blood transfusion and iron therapy. It will be interesting to see if she develops radiological evidence of recurrence in the future.

Two of the patients who have had resections have mild steatorrhoea and one of these is being treated with a high protein, low fat diet.

*Treatment.* The various procedures employed in the treatment of the 19 chronic cases are shown in Table 5. No exclusion operations were done in this series.

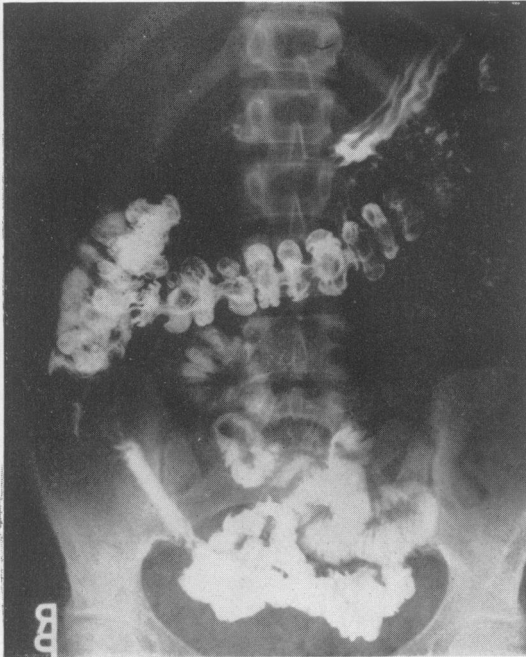


FIG. 3.—Barium follow-through of a case of acute terminal ileitis which progressed to chronic phase. Diagnosed in 1950 at emergency laparotomy, this X-ray was taken in 1952 prior to resection. Patient subsequently developed severe hypochromic anaemia (see text).

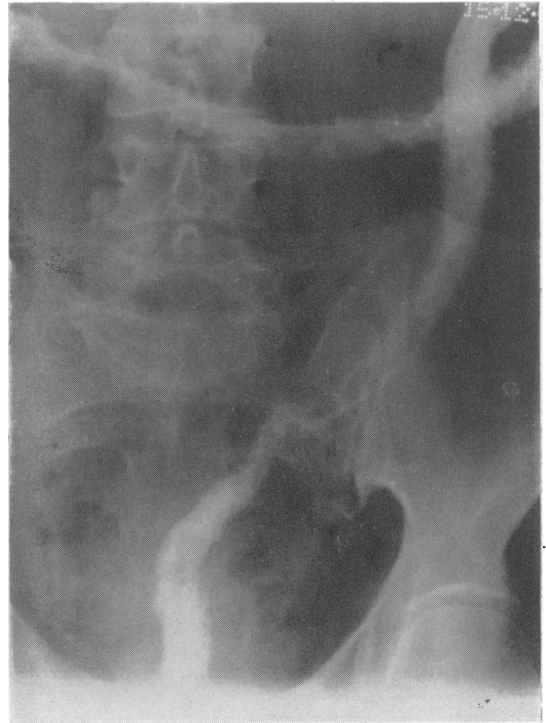


FIG. 4.—Barium enema of patient two years after resection of pelvic colon for regional colitis. The disease has recurred and progressed throughout the colon (see text).

TABLE 5  
OPERATIVE PROCEDURES IN CHRONIC GROUP

| Twelve Primarily Chronic Cases and Seven Progressing from the Acute Stage |              |
|---|--------------|
| Type of Operation   | No. of Cases |
| Ileotransverse colostomy without exclusion ..                             | 2            |
| Exploration and closure .. .. .   | 2            |
| Ileo-ileostomy .. .. .  | 1            |
| Resection of pelvic colon for regional colitis ..                         | 1            |
| Primary one-stage resection .. .. .                                       | 13           |

The two cases that were treated by ileotransverse colostomy without exclusion were not relieved, and were resected within a few months. A study of the literature confirms that by-pass procedures without exclusion are seldom of benefit. The ileo-ileostomy without exclusion was performed in 1944, for a case in which the actual terminal ileum, adjacent to the ileo-caecal valve, was not affected. It is now nine years since the ileo-ileostomy was performed, and the patient has had complete relief. Her barium follow-through

appears normal. It is the only case in the series in which a by-pass procedure without exclusion has been successful.

One case of regional colitis is recorded. The patient had resection of her pelvic colon in 1950 for what was thought to be a carcinoma. It was a ring stricture due to a chronic granuloma, which the pathologist labelled regional colitis. Six months after resection she developed a fistula in ano, and was readmitted. Her barium enema at that time showed loss of haustration at the site of the anastomosis. A barium follow-through was done and showed that the terminal ileum was normal. She has been into hospital twice since. On each occasion a barium enema has shown progression of the disease (Fig. 4). She suffers from anaemia and occasional diarrhoea, but is otherwise well. She would not consent to a further operation, even if it was advised.

Table 6 shows the results in those cases which were treated by resection—two of these had had a previous ileocolostomy without exclusion.

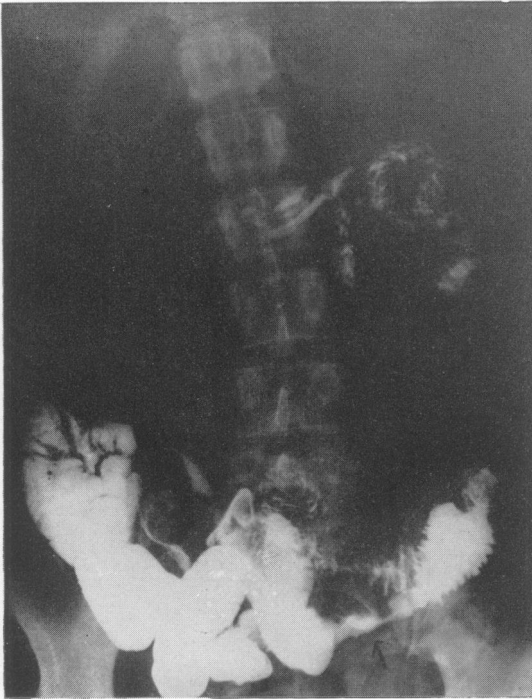


FIG. 5.—Barium follow-through showing two recurrent areas of Crohn's disease, 'skip lesions' in the ileum of a patient who had undergone right hemicolectomy five years previously.

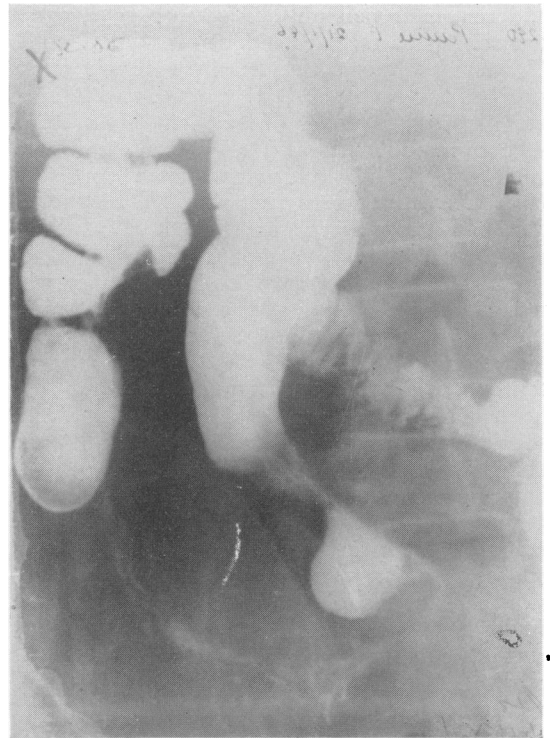


FIG. 6.—Barium follow-through of a patient who had ileocolostomy without exclusion seven years previously. It shows stenosis of the terminal ileum proximal to the ileocolic anastomosis.

TABLE 6

RESULTS OF RESECTION—15 CASES

|  |    |   |
|--|----|---|
| No evidence of disease for five years                              | .. | 2 |
| No evidence of disease for two years                               | .. | 2 |
| Mild symptoms and X-ray signs                                      | .. | 5 |
| Severe diarrhoea without X-ray evidence of disease                 | .. | 1 |
| Ileosigmoid anastomosis subsequent to hemicolectomy without relief | .. | 1 |
| Death  | .. | 1 |
| Further resections   | .. | 3 |

Nine of the 15 showed definite evidence of recurrence. The times of recurrence following resection are shown in Table 7.

TABLE 7

TIME OF RECURRENCE FOLLOWING RESECTION

|                    | Cases |
|--------------------|-------|
| Within one year    | 3     |
| Within two years   | 3     |
| Within three years | 1     |
| Within five years  | 1     |
| Within 13 years    | 1     |

There are five recurrent cases in whom the symptoms and X-ray signs are not severe enough

to warrant further interference at the present time. The patient who had the ileosigmoid anastomosis has had no relief of symptoms. In the other three recurrent cases obstructive symptoms became so severe that further resections were done. The case-histories of two of these are recorded, as the problem of recurrence is a very difficult one.

The first case was a female patient, aged 25, who developed a faecal fistula following appendectomy in 1939. In 1943 there was a palpable mass and fistula in her right iliac fossa. A barium enema was done, it showed a filling defect in the medial wall of the caecum due to the palpable mass of small bowel in her right iliac fossa. The fistula and diseased bowel were resected. Section proved the diagnosis of Crohn's disease. In 1948, five years later, she returned with a six-month history of attacks of intermittent obstruction. Her follow-through showed two strictured areas—'skip lesions'—in the lower ileum (Fig. 5). By 1950 her symptoms were so severe that both strictured areas were resected. She recovered

and remained well until December 1952, when her symptoms recurred. She was readmitted to University College Hospital in February 1953. She had two severe obstructive attacks with faecal vomiting, while under observation in the ward. A barium follow-through showed no strictured small bowel, but several very dilated loops. At laparotomy, two weeks after admission, a further 8 in. of stenosed ileum were excised. At the time of writing she is again symptom free.

The second case is a male patient, aged 42, who was first seen in 1938 with a 15-year history of intermittent obstructive attacks. An ileocolostomy without exclusion was done. His symptoms soon recurred and between 1938 and 1946 he had six severe attacks of obstruction which subsided spontaneously. A barium follow-through done in 1946 showed stenosis of the terminal ileum proximal to the ileocolic by-pass (Fig. 6). It was decided not to operate at this time, but by July 1947 his pain and diarrhoea had increased, and so resection was performed, with a side-to-side anastomosis of ileum to transverse colon. Following resection, his symptoms gradually recurred, and by September 1949 were as bad as ever. A barium follow-through showed definite recurrence just proximal to the site of anastomosis. Operation was not advised, but by 1951 his symptoms and stricture had progressed. A barium follow-through at this time is shown in Fig. 7. In view of the increase in severity of his symptoms, he was submitted to further resection of his terminal ileum and part of his transverse colon, including the site of the previous anastomosis; he made an uncomplicated recovery. In December 1952, just one year after his second resection, he was readmitted to hospital in a severe obstructive attack. A Miller Abbot tube would not pass, and as his obstruction did not relent, laparotomy was performed. The obstruction was due to an adhesion—there was no evidence of recurrence. At the time of writing, eight months later, he is still fit and well.

*Discussion.* In Crohn's disease we are ignorant of the causative agent, and owing to the wide mesenteric glandular involvement it is seldom possible to remove the diseased area completely—that is the basis of the problem of treatment.

Bockus (1945) emphasized that good results are probably not to be anticipated in more than 50 per cent. of resections. He stressed the importance of medical therapy, bedrest, diet and blood transfusion. It is probably advisable to try the effect of medical treatment initially in all cases, unless urgent obstruction, abscess, or fistula formation demand immediate surgical relief. There is no evidence that chemotherapy or cortisone have any lasting beneficial effect.

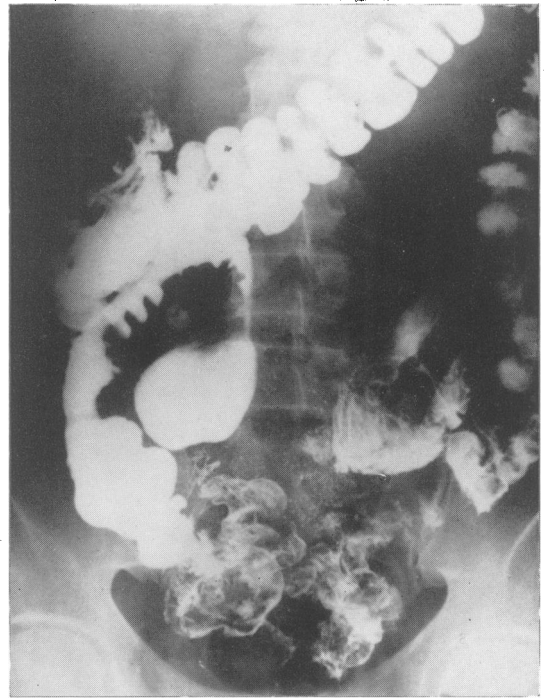


FIG. 7.—Barium follow-through of a patient four years after right hemicolectomy with side-to-side anastomosis. Recurrence is clearly shown at the anastomosis with distension of the blind ileal loop. Same patient as Fig. 6 (see text).

The follow-up of the U.C.H. cases shows the poor results of primary resection. A fact confirmed by Hawthorne and Frobese, who had a 75 per cent. recurrence rate in their series published in 1949. It must in fairness be pointed out, however, that all the U.C.H. patients with recurrent disease, although not in robust health, are up and about and working. The alternative to immediate resection would have been ileocolostomy with exclusion, or two-stage resection. Crohn has shown that in two-stage resections, the specimen, when finally removed, may show complete healing. It would seem, therefore, logical to do a by-pass operation with exclusion as an initial procedure, and only resect those cases in whom the symptoms are not relieved by this. The results of Garlock (1946) and other American surgeons show a slightly lower recurrence rate and mortality following exclusion procedures.

Each case must be assessed carefully and surgery undertaken only on the clearest indications. Grossly scarred, stenotic and fibrosed bowel, in which the pathological change is too far advanced for regression to take place should be resected;

but where abscesses or fistulae are present, these are clear indications for preliminary ileocolostomy with exclusion. If this does not give relief, resection can be done more safely at a second operation.

The danger of the 'blind loop' blowing out following an exclusion operation seems to be more apparent than real, because the deflection of the faecal stream away from the diseased area causes the stricture to relent.

Whatever the form of surgery employed, there is no doubt that the recurrence rate is depressingly high.

### Summary

Crohn's disease is a non-specific granuloma of the gut, commonest in the terminal ileum, sometimes involving other parts.

An acute form of the disease mimics appendicitis and is seldom recognized until the belly is opened. Nothing more should be done; appendectomy is to be avoided as it may be followed by a fistula.

In its chronic stages the disease presents in many ways, but its important features are chronic small intestine obstruction and the complications of subacute perforation. Operation may be neces-

sary, but whatever is done the chance of recurrence is high.

A follow-up study of 26 cases treated at one hospital confirms these generalizations and emphasizes the problem of the recurrent case.

In the chronic phase surgery should be limited to those cases with clear evidence of obstruction, perforation, abscess or fistula formation, or severe intractability.

I wish to thank Professor R. S. Pilcher for his assistance in preparing this paper, and also the consultant staff of University College Hospital for permission to follow-up their patients.

### BIBLIOGRAPHY

- ARMITAGE, G., and WILSON, M. (1950-51) *Brit. J. Surg.*, **38**, 183.  
 BOCKUS, H. L. (1945), *J. Amer. med. Ass.*, **127**, 449.  
 CHESS, S., CHESS, D., OLANDER, G., BENNER, W., and COLE, W. H. (1950), *Surgery*, **27**, 221.  
 COOMBE, C., and SAUNDERS, W. (1813), *Med. Trans. Roy. Coll. Phys. Lond.*, **4**, 16.  
 CROHN, B. B., GINZBURG, L., and OPPENHEIMER, G. D. (1932), *J. Amer. med. Ass.*, **99**, 1323.  
 DALZIEL, T. K. (1913), *Brit. med. J.*, **2**, 1068.  
 FELSEN, J. (1936), *Amer. J. Path.*, **12**, 395.  
 GARLOCK, J. H. (1946), *Amer. J. Surg.*, **72**, 875.  
 HADFIELD, G. (1939), *Lancet*, **II**, 773.  
 HAWTHORNE, H. R., and FROBESSE, A. S. (1949), *Ann. Surg.*, **130**, 233.  
 HOMB, A. (1946), *Acta. chir. scand.*, **94**, 343.  
 KANTOR, J. L. (1934), *J. Amer. med. Ass.*, **103**, 2016.  
 PATEY, D. H. (1949), *Proc. Roy. Soc. Med.*, **42**, 769.

## THE RESULTS OF OPERATIVE TREATMENT OF PROLAPSE

A follow up of 340 cases

By A. P. BENTALL, M.A., M.D., M.R.C.O.G., D.C.H.

*Assistant Obstetrician and Gynaecologist, Norfolk and Norwich Hospital*

### Introduction

At least twice a week the majority of gynaecologists throughout the country come to the stage in their operating lists where, having taxed themselves with the more exacting problems earlier on, they can sit down to deal with one or two cases of prolapse before the hard part of the morning's work is over. They are justified in expecting that the operation, though it may be tedious, especially to the assistant standing with bent back, will run smoothly and according to the usual routine varied but slightly to suit the particular nature of the case. Their experience teaches them to expect their patients to have some difficulty in passing water for a day or two, to be unable to sit down in comfort for about ten days and to be anxious to

return home, usually with thanks for what has been done, at the end of three weeks.

We do not often see a recurrence and when we do the original operation was often done elsewhere and we assume that it was done inefficiently. We feel justified in thinking that the great majority of our own patients get on well and remain eternally grateful, but in reality we know little of the end results of the vast number of operations for prolapse which are done throughout the country every year.

A study of the literature on the subject is not very helpful. Publications on the results have been surprisingly few in recent years and such as are available give a very varied picture of the success which may be expected, the picture usually