

# THE PATHOLOGY OF SARCOIDOSIS

By A. D. THOMSON, M.A., M.D., M.R.C.P.

*Bland-Sutton Institute of Pathology, Middlesex Hospital, London*

## Introduction

Elsewhere in this issue, possible aetiological factors, the diagnosis, the clinical manifestations and the treatment of sarcoidosis are discussed. The purpose of this article is to review the pathology and place it in its proper perspective.

Sarcoidosis can be regarded as a clinico-pathological syndrome which may have diverse causes and certainly presents with protean clinical manifestations. To the morbid anatomist there is but one basic histological appearance underlying all these clinical variations, as the cellular features are similar in every affected tissue. There is, however, much confusion over the use of the terms 'Sarcoidosis' and 'Sarcoid.' It appears that clinicians use the term 'Sarcoidosis' to denote the generalized disease, whereas pathologists, who only see the localized lesion on biopsy, frequently prefer the word 'Sarcoid.' In fact the multiplicity of these localized sarcoids produce the clinical manifestations of generalized sarcoidosis. There is a further source of confusion in that localized sarcoid reactions are frequently encountered in routine histological examinations and yet these patients do not appear to be suffering from generalized sarcoidosis.

## Sources of Material

The accumulated material for this study has reached the laboratory from two sources—biopsy and autopsy. From the relatively benign nature of the disease, autopsy material is scarce, although it is possible that by the time the disease has reached the late stage of non-specific fibrosis some examples coming to post-mortem examinations remain undetected. This may be so, for instance, in the terminal stages of pulmonary heart disease, when active sarcoid tissue can no longer be found in the lungs.

The biopsy material has been submitted from a variety of tissues, particularly lymph nodes, skin, liver, nasal mucosa, tonsil, conjunctiva, spleen, palate, lachrymal gland, parotid gland, and bronchial mucosa. Skin biopsies from Kviem tests and other inoculation sites have also been examined for confirmatory evidence of sarcoidosis. Finally,

serial skin biopsies have been studied, both before and after treatment, to review the activity of the disease and to assess the influence of different forms of therapy.

## Incidence

Sarcoidosis occurs in all parts of the world but there is no agreement as to the frequency of its occurrence. Thus Robb-Smith (1952) reported a rate of 0.66 patients per 100,000 of the general population in Oxfordshire, while in young soldiers, receiving routine medical examinations, the incidence increased to 13 per 100,000 in the Swiss Army (Schönholzer, 1947) and 17.81 per 100,000 Negroes in the United States Army (Michael *et al.*, 1950).

## Age

Sarcoidosis has been reported as occurring in all age groups but the disease most frequently presents between the ages of 20 to 40. In the Middlesex Hospital series, 66 per cent. of the patients were in this age group.

## Sex

The sex incidence of the many published series does not give an accurate assessment of the sex distribution, as many of the investigations have been carried out on Army recruits with, therefore, a high male preponderance. At the Middlesex Hospital the first 200 cases of the series contained 86 males and 114 females.

## Sites

Sarcoidosis is often a widely disseminated disease and, on microscopy, almost any tissue of the body may be involved. The disease, however, shows a predilection for certain organs and these, as assessed during life, are listed below.

### *Sites of Clinical Involvement of 200 Patients*

	%		%
Lungs .. ..	91	Spleen .. ..	13
Skin .. ..	50	Bones .. ..	5
Lymph nodes ..	37	Parotid .. ..	6
Eyes .. ..	25	C.N.S. . . .	4

It is, of course, impossible to know the exact incidence of involvement of the various tissues during life as, at autopsy on patients dying of the disease, sarcoidosis is usually present in many organs which showed no evidence of clinical derangement. Similarly, the technique of blind biopsy of various organs such as scalene nodes and liver has drawn attention to sarcoid involvement in tissues which would otherwise have remained undetected. Thus biopsy of the liver reveals sarcoid tissue in 60 per cent. of cases (Sherlock, 1955). To the pathologist, therefore, the frequency of involvement cannot be assessed on submitted pathological material alone, as this is dependant so much upon the diagnostic enthusiasm of the clinician and the accessibility of the organ.

Other organs not already listed may be involved, and sarcoid tissue has been found in the heart, skeletal muscle, kidneys and the genital tract in this series. The importance of myocardial involvement is that it may result in sudden death, while renal sarcoidosis may be associated with nephrocalcinosis.

The true incidence of intestinal sarcoidosis is unknown as it is entirely dependant upon the criteria used for its inclusion with this disease. Thus Hadfield (1939) regards regional ileitis as a form of sarcoidosis while others (e.g. Cowdell, 1954) deny this. Certainly some examples of regional ileitis show histological appearances in the gut wall and in the mesenteric lymph nodes indistinguishable from sarcoid, and on histological grounds it is possible that sarcoidosis produces one type of regional ileitis. However, Longcope and Freiman (1952) report on the infrequency of intestinal involvement in generalized sarcoidosis and Watson *et al.* (1945), after an extensive search of the literature, could only accept six cases, with two of their own, as true examples of intestinal sarcoidosis.

In spite of the histological similarity of some cases of regional ileitis and sarcoidosis there does appear to be a clinical difference, as I have not as yet seen a case of regional ileitis with a sarcoid histology progress to generalized sarcoidosis. These differences can be tabulated:—

	<i>Sarcoidosis</i>	<i>Regional Ileitis</i>
Lungs	†	—
Liver	+	—
Lymph nodes	+	+
Gut	Rare	Invariable

**Macroscopical**

Sarcoidosis in its earliest recognizable form shows multiple, minute, pale, pin-points of material studded in the area of involved tissue. These foci enlarge as the disease progresses, to

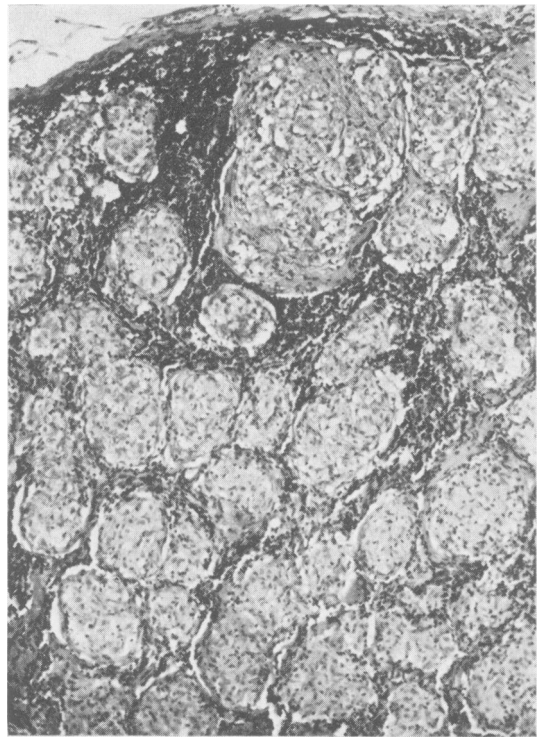


FIG. 1.—Showing the circular aggregations of epithelioid cells in sarcoidosis replacing a lymph node. × 85.

form readily visible nodules of pale tissue, often with scalloped margins. These areas may become confluent in some organs and at a later stage the diseased tissue may become firmer than normal, due to progressive replacement by fibrous tissue.

**Microscopical**

The histological appearances of sarcoidosis remain characteristically similar in all the body tissues, so that a description of one such area of involvement is exactly mirrored in any other tissue. The essential histological features are the focal collections of epithelioid cells, usually arranged in spherical fashion and surrounded by a variable, but frequently scanty, rim of lymphocytes (Fig. 1). These epithelioid cells have pale staining, vesicular nuclei, with pink staining cytoplasm and clearly demarcated cell boundaries. Additional histological features may be present; there are frequently giant cells of either the foreign body or Langhans' type; a variety of inclusions may be visible within these giant cells but they are in no way pathognomonic of sarcoidosis; foci of necrosis may also be present in the epithelioid cell aggregations. This necrosis is never a conspicuous feature, and when present it is

confined to the centres of the epithelioid foci and is of the fibrinoid type.

### The fate of the Sarcoidosis Histology

The fate of the cellular reaction of sarcoidosis is relevant to the eventual outcome of the disease. It is certain on clinical and post-mortem evidence that the process can resolve with disappearance of the cells and a return of the tissues to normal. This statement is based on the frequency of clinical regression in previously diseased areas, the return to normal of the dermis on repeated biopsy examinations of dermal sarcoidosis and the occasional reports of the post-mortem findings of normal internal organs which had previous histological evidence of sarcoidosis during life. When resolution does not occur the area of sarcoidosis may persist for long periods as an active cellular lesion or may eventually fibrose when the diseased area becomes replaced by hyaline acellular fibrous tissue.

Thus sarcoid tissue at any site may persist as active sarcoidosis, resolve, or be converted into hyaline collagen.

### Prognosis

Sarcoidosis can be regarded as a generalized disease with an excellent prognosis in the majority of patients in that disappearance of active sarcoid tissue is the rule. There are, however, five important exceptions to this favourable outcome:—

1. Pulmonary fibrosis—cor pulmonale.
2. Uveal tract fibrosis—eye complications and blindness.
3. Central nervous system and pituitary gland involvement.
4. Hypercalcaemia and nephrocalcinosis.
5. Cardiac involvement.

### Causes of Death

Death is rarely due to sarcoidosis directly, except when the heart, the central nervous system or the kidneys are extensively involved. In the majority of patients the immediate cause of death is due to some totally unrelated pathology. Thus:—

Ricker and Clark (1949), 22 autopsies, three deaths due to sarcoidosis.

Longcope and Freiman (1952), 12 autopsies, five deaths due to sarcoidosis.

Cowdell (1954), 17 deaths, eight deaths due to sarcoidosis.

Danbolt (1947) recorded the autopsy findings on Boeck's original case of skin sarcoidosis and, at death, 44 years after the appearance of the disease, no evidence of sarcoidosis could be demonstrated anywhere in the body.

The commonest cause of death in patients with sarcoidosis is pulmonary fibrosis, and in Leitner's

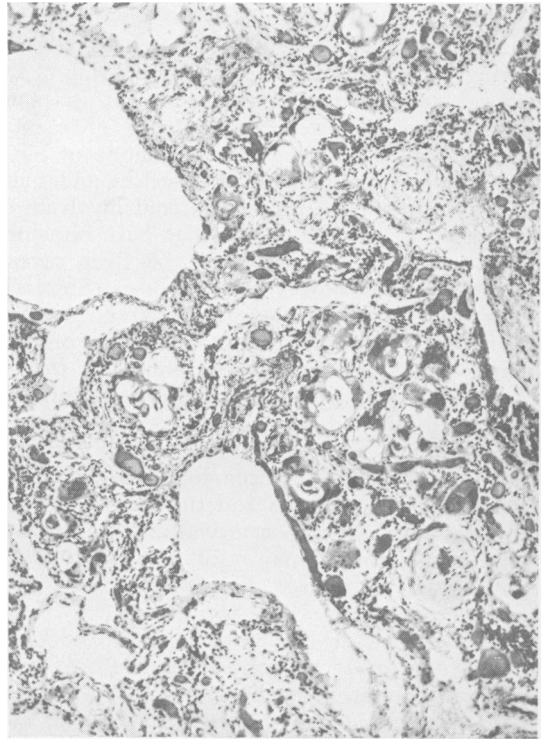


FIG. 2.—Showing fibrosis of the lung tissue due to sarcoidosis in which there are many giant cells with inclusions. Note the 'honeycomb' lung and the vascular thickening.  $\times 85$ .

(1949) series of 72 autopsies, 26 died in heart failure. Pulmonary sarcoidosis resulting in pulmonary fibrosis is, therefore, one of the fatal sequelae of the disease and this fibrosis may take the form of 'honeycomb' lung as seen in Fig. 2 (Heppleston, 1956). In most of the published series, tuberculosis is present at the termination of many of the patients, and Leitner (1949) recorded 12 cases of active tuberculosis in 72 autopsies and Riley (1950) reported six with tuberculosis in 13 fatal cases.

Therefore death from sarcoidosis occurs on the rare occasions when the heart is primarily involved by the disease or, more frequently, when secondarily implicated due to extensive pulmonary fibrosis. Death may also be due to central nervous system involvement or, rarely, from extensive sarcoidosis in the kidneys. In the absence of these, the cause of death is due to coincidental disease of any type with tuberculosis as a fairly commonly recorded termination.

### Tuberculin Reaction

Great stress is frequently made of the failure of sarcoidosis patients to react to intradermal injec-

tions of 1:100 old tuberculin. Indeed, 60 per cent. of the patients in the present series were Mantoux negative, but the presence of a positive reaction does not negate the diagnosis. The fact that by using an oily depot of tuberculin many of the Mantoux negative patients showed evidence of a positive reaction reduces the significance normally attached to the anergic state of these people (James and Pepys, 1956).

**Laboratory Investigations**

*Blood Count*

The changes in the blood in sarcoidosis are inconstant and do not show specifically diagnostic features. Frequently the blood count is normal although the sedimentation rate may be raised especially when erythema nodosum is present (James *et al.*, 1956). The white cell count may be normal or leucopenic while, less commonly, there is a monocytosis or an eosinophilia (Bruschi and Howe, 1950).

*Serum Proteins*

There is a hyperglobulinaemia in about 25 per cent. of the patients, but this finding is present in many other diseases and is of little diagnostic value. Its main importance is as confirmatory evidence of activity in an already established case of sarcoidosis.

*Serum Calcium*

A rare finding in sarcoidosis is the association of a raised serum calcium with calcinuria and nephrocalcinosis. This abnormality is due to a hypersensitivity to the action of vitamin 'D' (Anderson *et al.*, 1954), but it only occurs in about 1 per cent. of sarcoidosis cases (James, 1956).

*Alkaline Phosphatase*

The serum alkaline phosphatase is raised in a minority of patients with sarcoidosis. This is regarded by some as indicating active liver involvement while others suggest that it is due to bone resorption by sarcoid tissue in the bone marrow.

*Histological Diagnosis*

It is important to stress that during the early and active stages of sarcoidosis it is possible to find some accessible tissue involved by the disease in a high proportion of patients. In the present series the following tissues have given histological confirmation of sarcoidosis:—

Lymph nodes	Tonsil
Skin	Eye
Liver	Bronchial biopsy
Lung	Spleen
Nose	Palate

Post-mortem  
Kviem test

Lachrymal gland  
Parotid gland

Of interest is our failure to obtain histological evidence of sarcoidosis on blind biopsy of the conjunctiva as reported by Crick *et al.*, (1955).

**Histological Differential Diagnosis**

Although in typical cases of sarcoidosis the histological appearances are characteristic, there are certain other diseases and lesions in which similar histological features may occur and some of these diagnostic hazards are discussed below.

*Sarcoidosis and Tuberculosis*

The histological features of some examples of tuberculosis may closely simulate those of sarcoidosis and on occasions it is difficult to segregate the two processes on histological appearances alone. Essentially, sarcoid tissue resembles a tuberculous granuloma without the caseation of the latter, but closer inspection reveals other points of detail which may be helpful in deciding whether a tuberculous or a sarcoid pathology is operative.

1. The sarcoidosis foci are more uniformly spherical in shape and size.
2. The sarcoidosis foci tend to remain discrete with a well-defined margin.
3. The epithelioid cells in sarcoidosis have a distinct cell boundary and a more uniform arrangement.
4. Lymphocytes are scanty and may be absent in sarcoidosis.
5. The giant cells of sarcoidosis are inconstant and, when present, tend to be of both Langhans' and foreign body in type.
6. Necrosis in sarcoidosis is not common but, when present, is of the 'fibrinoid' type and is confined to a small area in the centre of the epithelioid cell aggregations.
7. Giant cell inclusions of the 'asteroid' type are rarely (if ever) seen in tuberculous lesions.
8. Ziehl-Neelsen staining is always negative in sarcoidosis.
9. Absence of calcification in the sarcoidosis tissue.

*Sarcoidosis and Sarcoid Reaction*

It is important to stress the frequency with which apparently localized sarcoid reactions are found in various tissues of the body. I have seen sarcoid reactions in the dermis in response to sand and glass particles, around sites of injection of wax and oil, and in areas of fat necrosis. Sarcoid tissue may be found in lymph nodes associated with oil droplets, around carbon particles, and adjacent to Hodgkin's tissue and carcinoma cells. Sarcoid reactions are also found, amongst many other organs,

in the gut wall as a reaction to foreign bodies, and in the Fallopian tube to talc particles.

These sarcoid reactions all show the characteristic sarcoid histology, with the typical aggregations of epithelioid cells, giant cells and lymphocytes, but with the additional features of fat spaces, particles or tumour cells, which give the clue to their causation in these instances. It appears, therefore, that in these particular patients a sarcoid type of reaction is produced by way of an inflammatory response instead of the more usual non-specific inflammatory tissue.

The clinical significance of these sarcoid reactions is more difficult to assess. Are the patients who evoke this type of tissue response already suffering from sarcoidosis or are they more prone to develop the disease subsequently? The evidence suggests that in these patients the sarcoid tissue is a strictly localized reaction produced by any of the stated causes and that generalized sarcoidosis does not supervene. Indeed, it may be that the sarcoid type of regional ileitis is but an example of a histological reaction to a number of different causes confined to the gut wall and its regional lymph nodes.

A localized sarcoid reaction is not to be confused with the prominence that may develop in old traumatic and operation scars during the active stage of general sarcoidosis and which, on histological examination, reveal sarcoid tissue.

#### *Sarcoidosis and the Kveim Test*

Following an injection of the Kveim antigen, a palpable, purple nodule develops at the site in the course of weeks. This clinical nodule, on histological examination, has shown the following tissue responses:—

1. Normal skin with an underlying nodule of firm, non-specific scar tissue.
2. Normal skin covering a non-specific inflammatory cell reaction with fibroblastic, vascular granulation tissue containing polymorphonuclear leucocytes, lymphocytes and histiocytes.
3. A non-specific foreign body giant cell reaction in the dermis, with a mixture of polymorphonuclear leucocytes, lymphocytes and foreign body giant cells in a fibroblastic, granulomatous tissue.
4. An area in the dermis composed of sarcoid tissue, indistinguishable from the sarcoid tissue seen in the natural disease except that giant cell inclusions have not been observed.

The Kveim test demands, therefore, the presence of a palpable nodule following injection of the antigen and, also, confirmatory histological evidence of sarcoid tissue. The histological appearances of 1, 2 or 3 would, of course, imply a negative Kveim test.

In a series of 110 Kveim tests the investigation has proved positive in 75 per cent. of patients with sarcoidosis (James, 1956), and thus has demonstrated its value in cases where there are no readily accessible sites for biopsy. As regards the technique of biopsy, it is relevant to stress that the sarcoid lesion is frequently situated deep in the dermis, so that a superficial biopsy of skin and upper corium is liable to miss the essential pathology. If, on histological examination of the submitted tissue, the section shows no sarcoidosis it is our practise to cut serial sections through the block, when, on occasions, sarcoid tissue will be visualized.

#### *Sarcoidosis and Liver Biopsy*

The technique of aspiration needle biopsy of the liver is increasingly used for histological confirmation of sarcoidosis. The sarcoid tissue, when present, is situated in the portal tracts but, because of the small cylinder of tissue which is inevitably submitted by this method of biopsy, only a minute portion of liver is available for examination. In spite of this, liver biopsy gives confirmatory evidence of sarcoidosis in 60 per cent. of patients (Sherlock, 1955) and is, therefore, of value in cases where other methods of diagnosis have failed. It is, however, sometimes difficult to be dogmatic about the diagnosis of sarcoidosis on the liver biopsy alone, as some cases of tuberculosis, brucellosis, B.C.G. vaccination, and some viral infections may produce miliary granulomata very similar in appearance to sarcoidosis (Klatskin and Yesner, 1950).

#### **Histological Changes in Serial Biopsies**

The appearances of the skin at the site of the Kveim test frequently reflect the activity of sarcoidosis, as there is often a recrudescence of the Kveim reaction during a clinical exacerbation of sarcoidosis. Serial biopsies at the Kveim site may show comparable histological changes with persistence of active sarcoid tissue during clinical activity, and evidence of a healing process during quiescent periods. The healing phase may result in scar tissue with eventual hyaline foci in the dermis, while in other examples the dermal lesion has resolved and the area has returned to histological normality. This resolution has been observed in patients on cortisone therapy, but it also occurs in untreated patients.

The wide variation in the clinical course of sarcoidosis makes it impossible to dogmatize as to the definite effects of the various forms of therapy employed. It does appear, however, that cortisone hastens the disappearance of active sarcoid tissue, while the other tried forms of therapy, including the antituberculous drugs, have no such measur-

# LLOYD-LUKE

*Books that enshrine profound thought*

<p><b>OPHTHALMOLOGY</b>  <b>A Textbook for Diploma Students</b>            by P. D. TREVOR-ROPER            M.B., B.Chir.(Camb.), F.R.C.S.,            D.O.M.S.(Eng.)            (1955) 75s. net</p>	<p><b>PRACTICAL            OBSTETRIC PROBLEMS</b>            by IAN DONALD            M.B.E., M.D.(Lond.), F.R.C.O.G.            (1955) 47s. 6d. net</p>	<p><b>FLUID BALANCE            IN SURGICAL PRACTICE</b>            (2nd edit.)            by L. P. LE QUESNE            D.M.(Oxon.), F.R.C.S.(Eng.)            (1957) 20s. net</p>
<p><b>GENERAL PATHOLOGY</b>            (2nd edit.)            Edited by SIR HOWARD FLOREY            M.D., F.R.C.P., F.R.S.            (1958) 84s. net</p>	<p><b>MEDICAL ETHICS</b>  <b>A Guide to Students            and Practitioners</b>            Edited by MAURICE DAVIDSON            D.M.(Oxon.), F.R.C.P.(Lond.)            (1957) 20s. net</p>	<p><b>POSTURAL DRAINAGE</b>            by E. WINIFRED THACKER            M.C.S.P.            (1956) 8s. 6d. net</p>
<p><b>RECENT TRENDS            IN CHRONIC BRONCHITIS</b>            Edited by NEVILLE C. OSWALD            T.D., M.D.(Cantab.), F.R.C.P.(Lond.)            (1958) 30s. net</p>	<p><b>THE RESPIRATORY MUSCLES            AND THE MECHANICS OF            BREATHING</b>            by E. J. MORAN CAMPBELL            M.D., Ph.D.(Lond.), M.R.C.P.(Lond.)            (1958) 20s. net</p>	<p><b>ANAESTHETIC ACCIDENTS</b>            by V. KEATING            M.B., B.Ch., D.A., F.F.A.R.C.S.(Eng.)            (1956) 25s. net</p>

Descriptive catalogue available on request

**LLOYD-LUKE (MEDICAL BOOKS) LTD., 49 Newman Street, W.1**

able effect in excess of the natural processes seen in spontaneous remissions. Thus in 10 patients who were subjected to serial biopsies from skin lesions, nasal mucosa, or Kveim sites, no histological evidence of healing during a course of anti-tuberculous chemotherapy could be demonstrated.

In summary, therefore, sarcoidosis is a generalized disease involving especially the lungs, liver, skin and lymph nodes, and the diagnosis is made on the clinical picture confirmed by a compatible, histological appearance. No pathological tests are pathognomonic of the disease except the histology of the affected tissue, which is the sole method of diagnostic confirmation. The area of sarcoidosis may persist in the active cellular phase, resolve or fibrose, and the fate of the patient is dependent both on the outcome of this histological lesion as well as the sites of involvement. Death is rarely due to active sarcoidosis, although the late sequelae of fibrosis, especially in the lungs, may be fatal. The histology of the Kveim test gives useful confirmatory evidence of sarcoidosis in those cases where no accessible tissue is available for biopsy, and the Kveim site forms a convenient area for

examination to assess both the activity of the disease and the efficacy of treatment.

#### BIBLIOGRAPHY

- ANDERSON, J., DENT, C. E., HARPER, C., and PHILPOT, G. R. (1954), *Lancet*, **ii**, 720.
- BRUSCHI, M., and HOWE, J. S. (1950), *Blood*, **5**, 478.
- COWDELL, R. H. (1954), *Quart. J. Med.*, **23**, 29.
- CRICK, R., HOYLE, C., and MATHER, G. (1955), *Brit. med. J.*, **ii**, 1180.
- DANBOLT, N. (1947), *Schweiz. med. Wschr.*, **77**, 1149.
- HADFIELD, G. (1939), *Lancet*, **ii**, 773.
- HEPPLESTON, A. G. (1956), *Thorax*, **11**, 77.
- JAMES, D. G. (1956), *Brit. med. J.*, **ii**, 900.
- JAMES, D. G., and PEPYS, J. (1956), *Lancet*, **i**, 602.
- JAMES, D. G., THOMSON, A. D., and WILLCOX, A. (1956), *Ibid.*, **ii**, 218.
- KLATSKIN, G., and YESNER, R. (1950), *Yale J. Biol. Med.*, **23**, 207.
- LEITNER, S. J. (1949), 'Der Morbus Besnier—Boeck—Schaumann,' Basal (Schwabe).
- LONGCOPE, W. T., and FREIMAN, D. G. (1952), *Medicine*, **31**, 1.
- MICHAEL, M., COLE, R. M., BEESON, P. B., and OLSEN, B. J. (1950), *Amer. Rev. Tuberc.*, **62**, 403.
- RICKER, W., and CLARK, M. (1949), *Amer. J. clin. Path.*, **19**, 725.
- RILEY, E. A. (1950), *Amer. Rev. Tuberc.*, **62**, 231.
- ROBB-SMITH, A. H. T. (1952), 'Modern Practice in Tuberculosis,' Vol. 2, p. 265, London (Butterworth).
- SCHÖNHOLZER, G. (1947), *Schweiz. med. Wschr.*, **77**, 585.
- SHIERLOCK, S. (1955), 'Diseases of the Liver and Biliary Tract,' Oxford (Blackwell).
- WATSON, C. J., RIGLER, L. G., WANGENSTEEN, O. H., and McCARTHY, J. S. (1945), *Gastroenterology*, **4**, 30.