

Nerves that say NO: a new perspective on the human rectoanal inhibitory reflex

Terence James O’Kelly MD FRCS

Research Fellow

University Department of Pharmacology, Oxford

Key words: Enteric nervous system; Anal sphincter; Nitric oxide

Anorectal incontinence is a distressing problem which is incompletely understood and, perhaps as a consequence, it is often inadequately treated. Attention has focused previously on the striated muscles of continence as the primary force which prevents faecal leakage, but it is now clear that a number of factors are involved (Fig. 1) and that the smooth muscle internal anal sphincter also plays a vital role (1). Augmentation of internal anal sphincter activity by pharmacological means is an attractive aim as this could reduce symptoms in incontinent patients. Before such advances are possible, however, we must appreciate better the mechanisms and processes which subserve normal sphincter activity and how these are disturbed in abnormal states.

A fundamental component of normal internal anal sphincter activity is relaxation in response to rectal distension, a phenomenon called the rectoanal inhibitory reflex (Fig. 2) (2,3). This reflex permits defaecation and facilitates anorectal sampling but, in spite of its evident importance, we still know little about the mechanisms involved. One explanation for this is that the inhibitory nerves which mediate the reflex have not been identified. It is established that they lie wholly within the wall of the gut and it is presumed that their cell bodies lie in the rectal myenteric ganglia, while their processes traverse the rectal myenteric plexus to gain access to the sphincter (4–6). The neurotransmitter released by these enteric inhibitory neurones is non-adrenergic and non-cholinergic (NANC); however, its true identity is unknown. Adenosine triphosphate (ATP) and vasoactive intestinal

polypeptide (VIP) have been suggested as putative NANC neurotransmitters here, but their involvement has not been substantiated in man (7,8).

Recently, it has been discovered that nitric oxide (NO) is an endogenous bioactive substance and, implausible as it might at first seem, there is now very good evidence that NO is an important inhibitory neurotransmitter in the mammalian gastrointestinal tract (9,10). Nitric oxide is synthesised from L-arginine, in a reaction catalysed by nitric oxide synthase. This enzyme exhibits a high degree of substrate specificity (NO is not produced from D-arginine) and it is dependent upon several co-factors, among which are Ca^{2+} , calmodulin and nicotinamide adenine dinucleotide phosphate (NADPH). Nitric oxide is freely soluble, diffuses rapidly and has a short half-life (3 s), being inactivated by formation of NO_3^- after contact with the superoxide anion, O_2^- . It exerts its effects by binding to cytosolic guanylate cyclase and stimulating the production of cyclic guanosine monophosphate (cGMP). Cyclic guanosine monophosphate has been shown to produce membrane hyperpolarisation in colonic smooth muscle (11). Such membrane changes are the hallmark of NANC nerve-mediated relaxation and are thought to result from an increase in potassium conductance. The

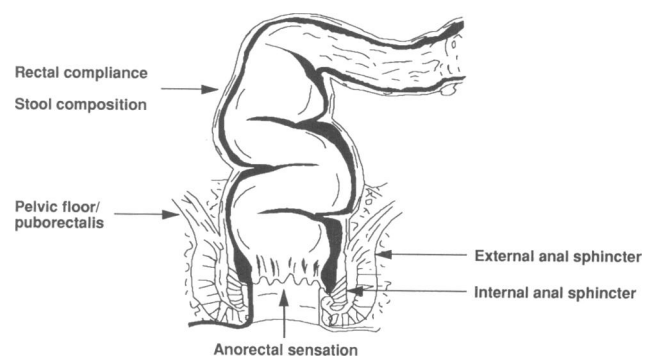


Figure 1. Factors which play an important role in anorectal continence.

Based on an Arris and Gale Lecture delivered during the Coloproctology Section of the Royal Society of Medicine's meeting held at Aberdeen Royal Infirmary on 3 March 1995

Present appointment: Senior Registrar in General Surgery, Aberdeen Royal Infirmary, Aberdeen

Correspondence to: Mr T J O’Kelly, Loretto Cottage, Blairs, Aberdeen AB1 5YQ

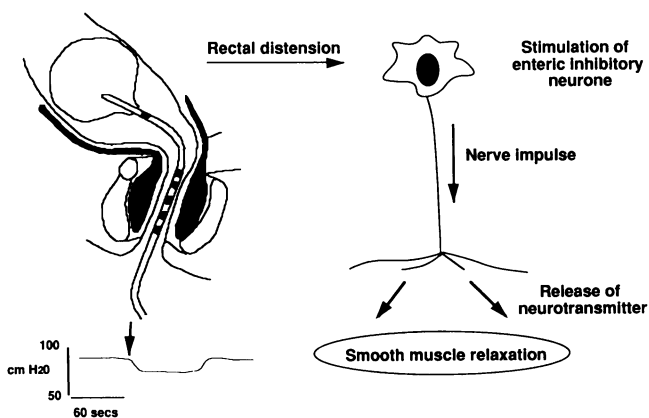


Figure 2. Rectoanal inhibitory reflex in man.

processes responsible for electromechanical coupling have not been determined, but possible mechanisms include enhanced Ca^{2+} sequestration and reduced sensitivity of the contractile apparatus to Ca^{2+} . Involvement of additional second messengers is also possible.

The aim of the experiments described here was to assess if NO could be the inhibitory neurotransmitter which mediates the rectoanal inhibitory reflex in man. In order to do this, involvement of NO in nerve-mediated relaxation of human internal anal sphincter smooth muscle was investigated *in vitro*. Then, morphological studies were performed to determine: (1) the presence and distribution of nerves containing nitric oxide synthase in the human anal canal and rectum and, (2) the occurrence of such nerves in Hirschsprung's disease, a condition in which the rectoanal inhibitory reflex is absent (12,13).

Patients and methods

Tissue was obtained from 20 patients undergoing abdominoperineal resection (median age 65 years; range 40–82 years) and six patients undergoing anterior resection (median age 62 years; range 45–78 years). In addition, the surgical specimens from seven children with Hirschsprung's disease who underwent definitive resection of aganglionic bowel were studied (median age 9 months; range 5–12 months).

Methods

Detailed methodology is not described but all the techniques used are referenced.

In vitro pharmacological experiments

Strips of internal anal sphincter ($10 \times 1 \times 1$ mm; 5–8 mg) containing parallel bundles of smooth muscle fibres were dissected from abdominoperineal resection specimens and were mounted under physiological conditions for isometric tension recording in superfusion organ baths (14). Nerve-mediated relaxation occurred in response to appropriate electrical field stimulation. Drugs and other

agents were added to the superfusate and the effect of these upon muscle strips and their response to electrical field stimulation was recorded.

Morphological experiments

Tissue from the sources described above was processed for cryostat sections and for whole mount histochemistry (15,16). The latter process involves fixing a segment of bowel as a sheet and then dissecting it into its constituent tissue layers, which can then be stained as desired. Cryostat sections were stained immunocytochemically for the presence of nitric oxide synthase, phosphonurofilaments and non-phosphonurofilaments (15,16). Sections were also stained histochemically for the presence of NADPH diaphorase and the degree of co-localisation between this enzyme and nitric oxide synthase was assessed (15,16). In enteric neurones in lesser mammals, nitric oxide synthase has been shown to specifically co-localise with NADPH diaphorase (17–19). The presence of the latter can be revealed by a relatively simple and well-established histochemical technique in which there is good tissue penetration of the reagents involved. NADPH diaphorase histochemistry is an attractive marker for the presence of nitric oxide synthase, but its use in the investigation of the human gut is dependent upon confirmation that co-localisation is consistent. Light microscopy was utilised throughout.

Results

In vitro pharmacological experiments

Response to inhibitory nerve stimulation

When mounted in superfusion organ baths, smooth muscle strips from the human internal anal sphincter contract spontaneously and develop a high level of myogenic tone (20). Once a steady state of tension is achieved, the muscle strips relax in response to electrical field stimulation using a pulse strength of 10 V and a pulse duration of 0.5 ms (14). The relaxations are frequency dependent and can be repeated at 3 min intervals. Relaxations are unaffected by atropine, hexamethonium, phentolamine and propranolol, all present at sufficient concentrations to abolish the response of the tissue to cholinceptor and to adrenoceptor stimulation (Fig. 3). However, the relaxations are abolished by tetrodotoxin, a nerve toxin.

These results demonstrate that the response of human internal anal sphincter smooth muscle to electrical field stimulation (as described here), is neurogenic and is mediated by a NANC neurotransmitter.

Response to sodium nitroprusside

Sodium nitroprusside is an exogenous donor of nitric oxide (21) and its addition to the superfusate caused relaxation of the muscle strips in a dose-dependent manner (14). Sodium nitroprusside was applied for 60 s

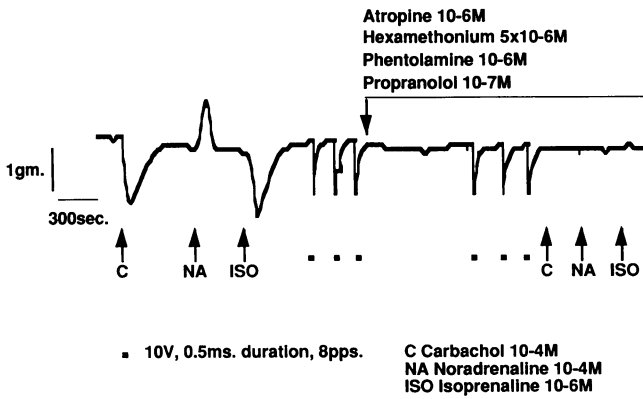


Figure 3. A characteristic trace which illustrates the response of a muscle strip to cholinergic (carbachol) and adrenergic (noradrenaline and isoprenaline) agonists, and to repetitive electrical field stimulation. In the presence of nicotinic (hexamethonium), muscarinic (atropine), α -adrenergic (phentolamine) and β -adrenergic (propranolol) receptor antagonists, the response to electrical field stimulation is unchanged, but the action of the agonists is abolished.

and a maximal response was achieved at a concentration of 5×10^{-7} M, when the residual tone in the strips was equivalent to that present in calcium-free solution (zero tension; Fig. 4).

Effect of inhibiting nitric oxide synthase

L-nitroarginine (L-NOARG) is a synthetic analogue of L-arginine, and a competitive antagonist of nitric oxide

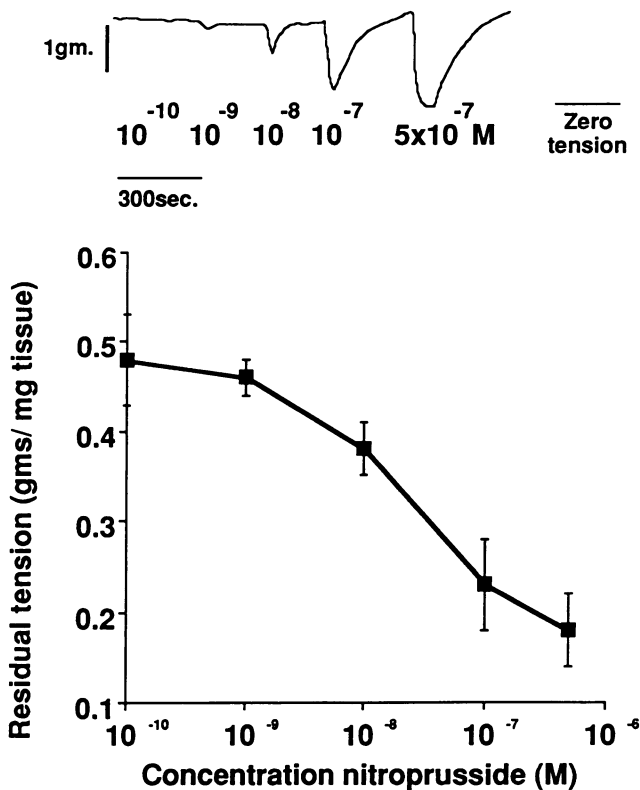


Figure 4. Effect of sodium nitroprusside shown in the form of a characteristic trace and a cumulative dose-response curve.

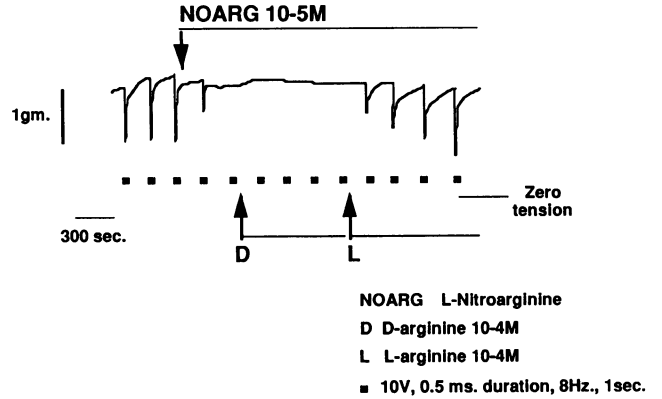


Figure 5. A characteristic trace which illustrates the effect of 10^{-5} M *N*-nitro-L-arginine (L-NOARG) on nerve-mediated relaxation of internal anal sphincter smooth muscle. Neurogenic relaxation disappears in the presence of L-NOARG. Its action is antagonised by L-arginine (L-arg 5×10^{-4} M, but not D-arginine (D-arg 5×10^{-4} M).

synthase (9). Addition of L-NOARG to the superfusate produces a dose-dependent inhibition of electrically induced neurogenic relaxation of human internal anal sphincter smooth muscle (14). When added to the superfusate at a concentration 10^{-5} M, L-NOARG abolished the response of the strips to electrical field stimulation. D-arginine (5×10^{-4} M) has no effect upon this inhibition, but it was reversed by the addition of L-arginine at the same concentration (Fig. 5). D-NOARG had no inhibitory effect upon the response of muscle strips to electrical field stimulation.

Effect of haemoglobin

Oxyhaemoglobin has a high affinity for nitric oxide and scavenges it from extracellular media; methaemoglobin has no such action (22). Addition of oxyhaemoglobin produced inhibition of nerve-mediated relaxation in a dose-dependent manner and the neurogenic response was abolished at a concentration of 5×10^{-5} M (14). Relaxations returned after withdrawal of oxyhaemoglobin and a period of recovery. Methaemoglobin had no effect upon the tissue. These points are illustrated in Fig. 6.

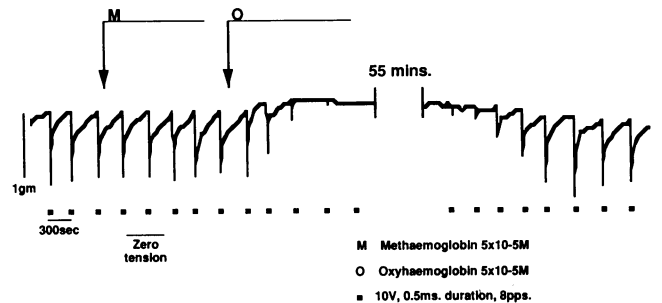


Figure 6. A characteristic trace which illustrates that neurogenic relaxation is reversibly abolished by oxyhaemoglobin (oxy) at a concentration of 5×10^{-5} M. Methaemoglobin (met) has no such action at the same concentration.

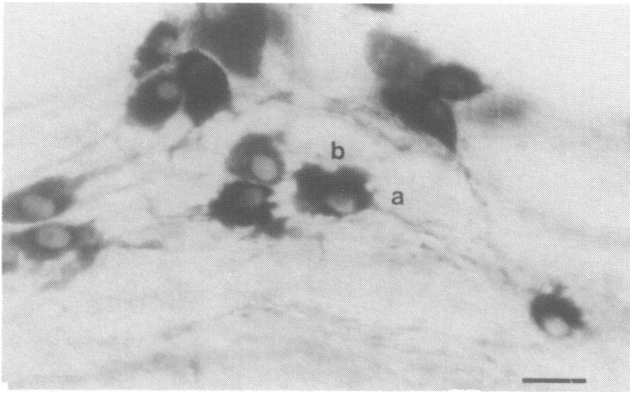


Figure 7. A whole mount of the rectal myenteric plexus stained using NADPH diaphorase histochemistry. This illustrates the appearance of individual nitric oxide synthase containing neurones. These have a single axonal process (a) and broad dendrites (b). This is typical of Dogiel type 1 enteric neurone morphology (23). (Bar = 25 μ m.)

Morphological experiments

Structure and appearance of nitric oxide synthase containing neurones in the human rectal myenteric plexus and anal canal

In the rectum (15), nitric oxide synthase immunoreactive nerve cell bodies are found predominantly within ganglia in the myenteric plexus. There are few nerve cell bodies containing nitric oxide synthase immunoreactivity in the submucosal plexus. The intensity of staining of the neurones is variable but occurs throughout the cytoplasm. Nuclei remain pale. Nitric oxide synthase immunoreactivity was not seen in any other cell and, in particular, smooth muscle cells showed no evidence of immunoreactivity.

The degree to which nitric oxide synthase and NADPH diaphorase co-localise within rectal myenteric neurones was determined (15). Of those neurones which stained positive, 91% contained both enzymes, 7% were immunoreactive for nitric oxide synthase only and 2% contained just NADPH diaphorase activity. These results indicate that NADPH diaphorase histochemistry is an accurate marker for nitric oxide synthase immunoreactivity in myenteric neurones and it was used as such in subsequent experiments.

When cryostat sections of the rectal wall were stained for both NADPH diaphorase activity as well as phosphoneurofilament and non-phosphoneurofilament immunoreactivity, it was apparent that cell bodies which contain NADPH diaphorase activity form a sub-population of the total neurones present within the rectal myenteric plexus, because some nerve cell bodies contain phosphoneurofilament and non-phosphoneurofilament immunoreactivity but not NADPH diaphorase activity.

The morphology of individual rectal myenteric neurones is revealed by NADPH histochemistry performed on whole mounts (15). This is illustrated in Fig. 7. In the proximal two-thirds of the rectum, most reactive neurones lie within or are in close proximity to ganglia

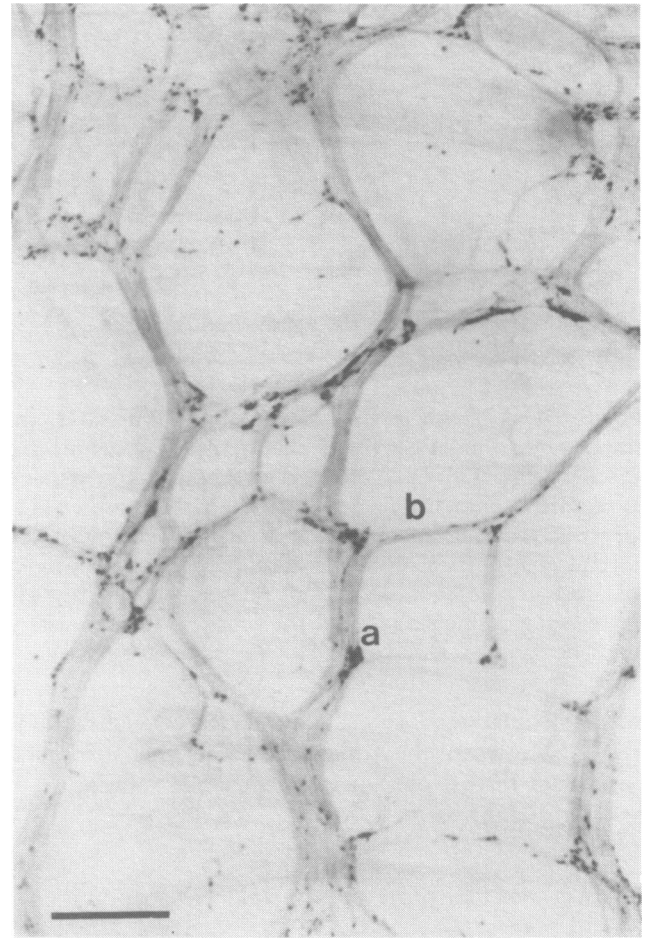


Figure 8. Appearance of the myenteric plexus in the proximal two-thirds of the rectum as stained by NADPH diaphorase histochemistry. Nitric oxide synthase containing neurones aggregate together in ganglia (a) which are joined by internodal strands (b) to form a meshwork (primary plexus) which does not have apparent polarity. (Cranial: top; bar = 1 mm.)

within the myenteric plexus. The geometry of the myenteric plexus in this region varies, but it is continuous and evenly distributed both around the circumference and along this segment of the gut (Fig. 8). In the distal 3–4 cm of the rectum, the appearance of the myenteric plexus changes as ganglia and nerve processes line up along the craniocaudal axis of the gut (Fig. 9). When compared with the proximal rectum, ganglia in the distal rectal myenteric plexus appear densely packed with positively stained neurones. Some axons leave ganglia and communicate with specialised nerve trunks which traverse the plexus along the craniocaudal axis of the rectum. These nerves bypass ganglia and their appearance is similar to that previously described for structures called *shunt fascicles* (Fig. 9) (24). Shunt fascicles are thought to be rapid communication pathways for the transfer of information between gut segments (25). They are prominent features in the distal rectal myenteric plexus and are seen to extend distally into the anal canal.

The meshwork of the myenteric plexus can be followed distally into the anal canal as far as the junction of the

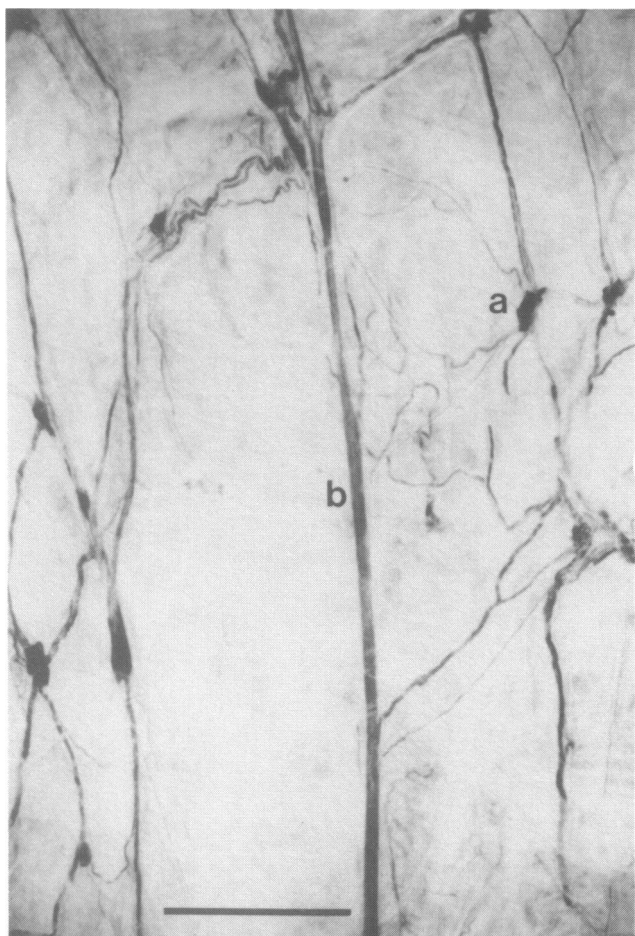


Figure 9. Appearance of the distal rectal myenteric plexus stained by NADPH diaphorase histochemistry. Nitric oxide synthase containing neurones are again clustered in ganglia (a). Some of their axons traverse shunt fascicles (b) to descend to the anal canal. Note the craniocaudal polarity here. (Cranial: top; bar = 1 mm.)

proximal and middle thirds of the internal anal sphincter (15). In this region the plexus consists predominantly of linear nerve trunks which divide distally and disappear as they pass into the body of the internal anal sphincter. There are few ganglia here. Within the internal anal sphincter itself, nerve processes which contain NADPH diaphorase activity are found throughout and both nerve trunks and single axons are seen (Fig. 10).

Presence and distribution of neurones containing nitric oxide synthase in Hirschsprung's disease

When the presence of both nitric oxide synthase immunoreactivity and NADPH diaphorase activity was assessed in cryostat sections, 98% of positively stained infant colonic myenteric neurones appeared to contain both enzymes; 1% demonstrated nitric oxide synthase immunoreactivity only and 1% contained only NADPH diaphorase activity (16). In the infant colon, therefore, NADPH diaphorase histochemistry is a very accurate marker for the presence of nitric oxide synthase immunoreactivity.

In ganglionated colon from infants with Hirschsprung's

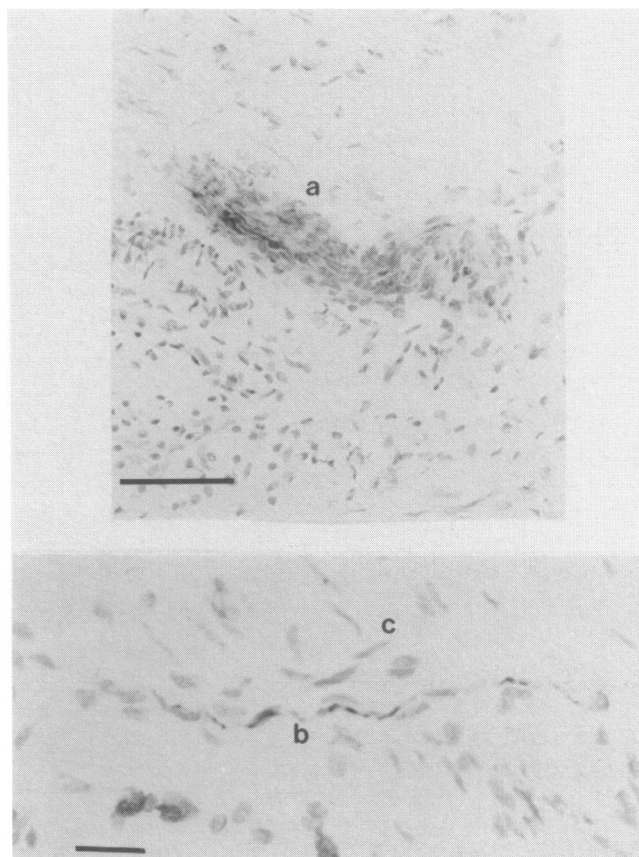


Figure 10. Cryostat sections of the distal internal anal sphincter stained by NADPH diaphorase histochemistry, with a light neutral red counter stain; (top) nitric oxide synthase containing nerve trunk (a; bar = 100 μ m), (bottom) nitric oxide synthase containing axon (b). This is seen passing between smooth muscle cells which have been counter-stained (c) (bar = 10 μ m).

disease, NADPH diaphorase activity is seen in ganglia both in the myenteric plexus and at the submucosal border of the circular smooth muscle layer (submucous plexus) (16). In addition, NADPH diaphorase activity is present within neuronal processes in both the circular and longitudinal muscle layers, where fibres run parallel and perpendicular to smooth muscle cells. Very fine nerves containing NADPH diaphorase activity are also seen passing from the submucous plexus into the mucosa. No other structures stained positive for NADPH diaphorase activity (Fig. 11).

No NADPH diaphorase activity is apparent in the aganglionic segment (Fig. 11) (16). Hypertrophied nerve trunks are present in this region and contain phospho-neurofilament and non-phosphoneurofilament immunoreactivity, but they do not contain NADPH diaphorase activity.

Whole mounts of the myenteric plexus were prepared along the craniocaudal axis of resection specimens and were stained for NADPH diaphorase activity (16). In normally ganglionated colon, positively stained neurones have similar morphological characteristics to those seen in the adult rectum, and are found principally within ganglia. The plexus in this segment is devoid of polarity

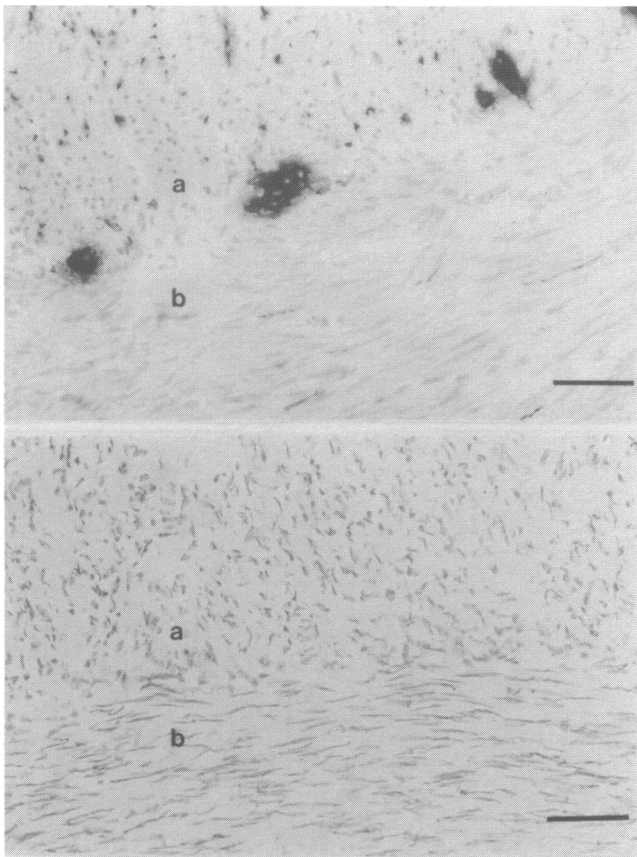


Figure 11. Cryostat sections of the junction between the circular (a) and longitudinal muscle layers (b) of the ganglionated (top) and aganglionic (bottom) segments in Hirschsprung's disease stained to reveal NADPH diaphorase activity and hence the presence of nitric oxide synthase. Note the presence of the positive staining in the former and its absence in the latter (bar = 100 μ m).

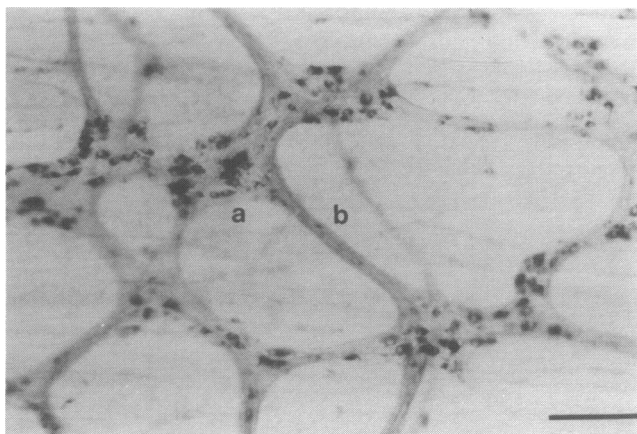


Figure 12. A whole mount of the myenteric plexus in the normally ganglionated colon of a child suffering from Hirschsprung's disease, stained to reveal NADPH diaphorase activity and hence the presence of nitric oxide synthase. The plexus here lacks polarity and consists of ganglia (a) joined by internodal strands (b). (Cranial: top; bar = 100 μ m.)

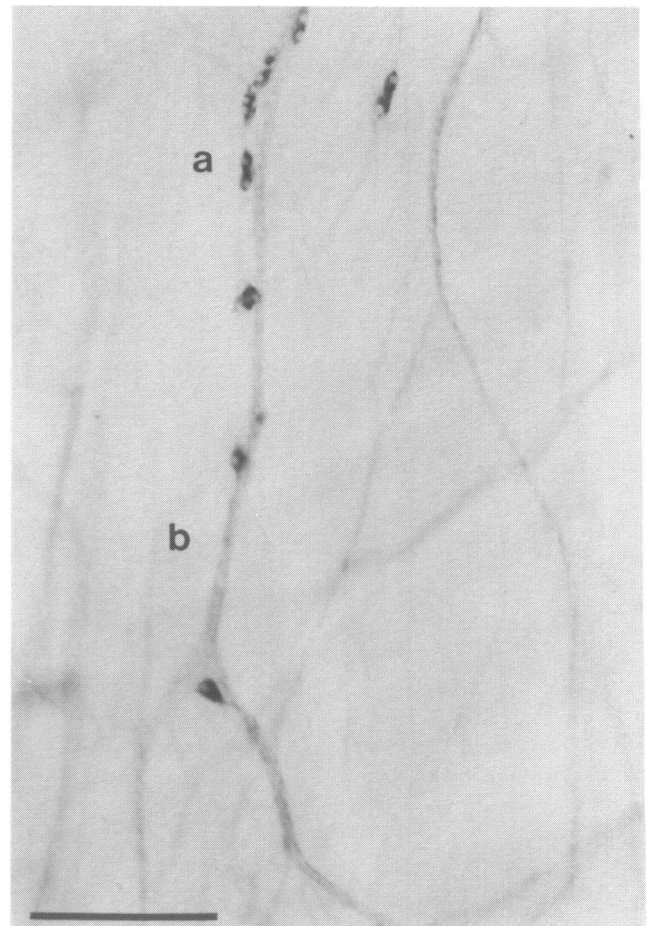


Figure 13. A whole mount of the myenteric plexus in the distal part of the transition zone where discrete ganglia disappear and positively stained neurons (a) lie in series along nerve trunks (b). (Cranial top; bar = 100 μ m)

in that it is evenly distributed both longitudinally and circumferentially around the bowel (Fig. 12).

Passing caudally from normally ganglionated colon into the transition zone, distinct changes in the architecture and orientation of the myenteric plexus are apparent (16). Ganglia and internodal strands are aligned progressively in a linear fashion along the craniocaudal axis of the gut. There are few internodal strands passing circumferentially around the gut. More caudal still, ganglia disappear and individual nerve cell bodies lie in series along stained nerves (Fig. 13). Distally, nerve cell bodies become increasingly sparse and then disappear completely. Their axonal processes pass caudally in nerve bundles for a further 1.5–2.0 cm, but these also disappear, leaving the aganglionic gut devoid of NADPH diaphorase activity.

Discussion

The rectoanal inhibitory reflex is thought to be a modified descending inhibitory peristaltic reflex which is mediated by NANC inhibitory nerves that arise from cell bodies within rectal myenteric ganglia and descend in the myenteric plexus to innervate the internal anal sphincter

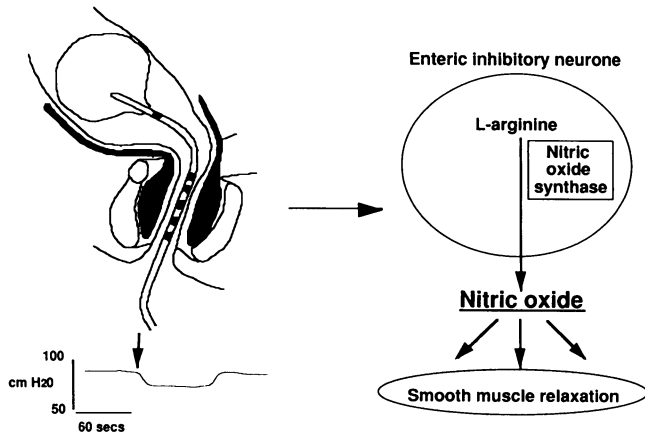


Figure 14. Human rectoanal inhibitory reflex.

(6). In the light of experimental data presented here, there is strong evidence to support the assertion that NO mediates the rectoanal inhibitory reflex in man (Fig. 14).

First, NO appears to be an inhibitory neurotransmitter within the human internal anal sphincter. Although its release was not demonstrated directly, involvement of NO in nerve-mediated relaxation was strongly suggested in *in vitro* studies. Neurogenic relaxations are mimicked by application of NO from an exogenous source and they are inhibited by oxyhaemoglobin, an agent which scavenges NO in extracellular media. Nerve-mediated relaxation is also antagonised and can be abolished by inhibition of nitric oxide synthase with L-NOARG which is an analogue of L-arginine, the specific substrate required for NO production. The action of L-NOARG is enantiomerically specific and it can be reversed by addition of L-arginine itself. In addition, morphological experiments suggest that there is a neuronal source for NO within the human internal anal sphincter and in fact nerves were the only structures demonstrated to contain nitric oxide synthase in this tissue.

Second, nitric oxide synthase containing nerve fibres within the internal anal sphincter appear to originate from nerve cell bodies which lie in rectal myenteric ganglia. The distribution of these nerves is therefore appropriate for them to mediate the rectoanal inhibitory reflex. In addition, the morphological and staining characteristics of individual neurones is similar to those present in the guinea-pig myenteric plexus which have been demonstrated by Costa *et al.* (26) to have the correct projections and neurochemistry to be the inhibitory motor neurones which mediate the descending relaxation reflex in intestinal peristalsis. Finally, in Hirschsprung's disease, a condition in which the rectoanal inhibitory reflex is absent, nitric oxide synthase containing nerves are absent from the aganglionic, non-relaxing segment of the gut but are present in the normally ganglionated segment which peristalses.

Unfortunately, because of ethical considerations, it has not been possible to investigate the role of NO in the human rectoanal inhibitory reflex *in vivo*. This has been examined, however, in the opossum (27). Here internal anal sphincter relaxation was demonstrated to occur in

response to a number of stimuli (rectal distension, local intramural nerve stimulation, sacral nerve stimulation and 1,1-dimethyl-4-phenylpiperazinium), and it was established that relaxant responses were mimicked by sodium nitroprusside and were inhibited in a dose-dependent enantiomerically specific manner by L-NOARG. The action of L-NOARG was reversed by excess L-arginine. D-arginine had no such effect.

The discovery that nerves which produce NO mediate the rectoanal inhibitory reflex in man has provided a new insight into the neurophysiology of the anal canal and rectum. It is hoped that this will be a key step towards a better understanding of the continence mechanism and the processes which lead to incontinence.

The author would like to acknowledge the help of The Wellcome Trust, Dr A F Brading, Mr N J Mortensen, Professor K Sanders, Dr S Ward, Dr P Bolam, Dr J Davies, Mr P Tam and Professor D Smith. The author thanks the Editors of the journals *Diseases of the Colon and Rectum* and *Journal of Pediatric Surgery* for permission to reproduce Figures 7–10 and 11–13, respectively.

References

- 1 Speakman CTM, Kamm MA. The internal anal sphincter—new insights into faecal incontinence. *Gut* 1991; 32: 345–6.
- 2 Gowers WR. The automatic action of the sphincter ani. *Proc R Soc Lond* 1887; 26: 77–84.
- 3 Denny-Brown D, Robertson EG. An investigation of the nervous control of defaecation. *Brain* 1935; 58: 256–310.
- 4 Lubowski DZ, Nicholls RJ, Swash M. Neural control of internal anal sphincter function. *Br J Surg* 1987; 74: 668–70.
- 5 Kamm MA, Lennard-Jones JE, Nicholls RJ. Evaluation of the intrinsic innervation of the internal anal sphincter using electrical stimulation. *Gut* 1989; 30: 935–8.
- 6 Furness JB, Costa M. Influence of the enteric nervous system on motility. In: Furness JB, Costa M, eds. *The Enteric Nervous System*. London: Churchill Livingstone, 1987: 137–89.
- 7 Burleigh DE, D'Mello A, Parks AG. Responses of isolated human internal anal sphincter to drugs and electrical field stimulation. *Gastroenterology* 1979; 77: 484–90.
- 8 Burleigh DE. Non-adrenergic non-cholinergic inhibitory neurons in the human internal anal sphincter muscle. *J Pharm Pharmacol* 1983; 35: 258–60.
- 9 Moncada S, Palmer RMJ, Higgs EA. Nitric oxide: physiology, pathophysiology and pharmacology. *Pharmacol Rev* 1991; 43: 109–42.
- 10 Sanders KM, Ward SM. Nitric oxide as a mediator of nonadrenergic noncholinergic neurotransmission. *Am J Physiol* 1992; 262: G379–92.
- 11 Thornbury KD, Ward SM, Dalziel HH, Carl A, Westfall DP, Sanders KM. Nitric oxide and nitrosocysteine mimic nonadrenergic, noncholinergic hyperpolarization in canine proximal colon. *Am J Physiol* 1991; 261: G553–7.
- 12 Callaghan RP, Nixon HH. Megarectum; physiological observations. *Arch Dis Child* 1964; 39: 153–7.
- 13 Lawson JON, Nixon HH. Anal canal pressures in the diagnosis of Hirschsprung's disease. *J Pediatr Surg* 1967; 2: 544–52.

- 14 O'Kelly TJ, Mortensen NJMcC, Brading AFB. Nerve mediated relaxation of the human internal anal sphincter: the role of nitric oxide. *Gut* 1994; **34**: 689-93.
- 15 O'Kelly TJ, Davies J, Mortensen NJMcC, Brading AFB. The distribution of nitric oxide synthase containing neurones in the human rectal myenteric plexus and anal canal; morphological evidence that nitric oxide mediates the rectoanal inhibitory reflex. *Dis Colon Rectum* 1994; **37**: 350-57.
- 16 O'Kelly TJ, Davies J, Tam P, Mortensen NJMcC, Brading AFB. Abnormalities of nitric oxide producing neurones in Hirschsprung's disease; morphology and implications. *J Pediatr Surg* 1994; **29**: 294-9.
- 17 Young HM, Furness JB, Shuttleworth CW, Brecht DS, Snyder SH. Co-localization of nitric oxide synthase immunoreactivity and NADPH diaphorase staining in neurons of the guinea pig intestine. *Histochemistry* 1992; **97**: 375-8.
- 18 Ward S, Xue C, Shuttleworth CW, Brecht DS, Snyder SH, Sanders KM. NADPH diaphorase and nitric oxide synthase co-localization in enteric nerves of the canine proximal colon. *Am J Physiol* 1992a; **263**: G277-84.
- 19 Dawson TM, Brecht DS, Fotuhi M, Hwang PM, Snyder SH. Nitric oxide synthase and neuronal NADPH diaphorase are identical in brain and peripheral tissues. *Proc Natl Acad Sci* 1991; **88**: 7797-7801.
- 20 O'Kelly TJ, Mortensen NJMcC, Brading AFB. *In vitro* response of the longitudinal muscle layer of the human anal canal to cholinergic and adrenergic stimulation, compared with the internal anal sphincter and rectal smooth muscles. *Br J Surg* 1993; **80**: 1337-9.
- 21 Feelisch M, Noack EA. Correlation between NO formation during degradation of organic nitrates and activation of guanylate cyclase. *Eur J Pharmacol* 1987; **139**: 19-30.
- 22 Salvemini D, Radziszewski W, Korbut R, Vane J. The use of oxyhaemoglobin to explore the events underlying inhibition of platelet aggregation induced by nitric oxide or nitric oxide donors. *Br J Pharmacol* 1990; **101**: 991-5.
- 23 Furness JB, Costa M. Cytoarchitectonics of the enteric nervous system. In: Furness JB, Costa M, eds. *The Enteric Nervous System*. London: Churchill Livingstone, 1987: 26-54.
- 24 Christensen J, Stiles MJ, Rick GA, Sutherland J. Comparative anatomy of the myenteric plexus of the distal colon in eight mammals. *Gastroenterology* 1984; **86**: 706-13.
- 25 Fukui K, Fukuda H. The intramural pelvic nerves in the colon of dogs. *J Physiol* 1984; **354**: 80-98.
- 26 Costa M, Furness JB, Pompolo S *et al*. Projections and chemical coding of neurons with immunoreactivity for nitric oxide synthase in the guinea-pig small intestine. *Neurosci Lett* 1992; **148**: 121-5.
- 27 Rattan S, Sarkar A, Chakder S. Nitric oxide pathway in rectoanal inhibitory reflex of opossum internal anal sphincter. *Gastroenterology* 1992; **103**: 43-50.

Received 12 June 1995