



Original article

# A 'safe' surgical technique for stabilisation of the sternoclavicular joint: a cadaveric and clinical study

DP Thomas, PR Williams, HC Hoddinott

*Department of Trauma and Orthopaedics, Morriston Hospital, Morriston, Swansea SA6 6NL, UK*

**In symptomatic patients with recurrent anterior sternoclavicular dislocation, surgery may be required to stabilise the joint. Posterior sternoclavicular dislocations may also require open reduction and stabilisation due to the complications that may arise. We present a new, 'safe' technique of surgical stabilisation of the sternoclavicular joint that is not technically demanding and does not require exposure of the first rib, as is often the case in other methods described. The repair was tested in cadavers before being employed in three patients and was found to be effective under both static and dynamic loading. The early clinical results prove encouraging.**

*Key words:* Anterior – Sternoclavicular – Dislocation – Stabilisation

Injury to the sternoclavicular joint, although uncommon,<sup>1</sup> can have serious consequences for young active males in which it mainly occurs. In the mature skeleton, the most common injury to this joint is a dislocation, which can be posterior or, much more frequently, anterior.<sup>2</sup> Acute dislocation can be treated by closed reduction. The literature suggests that, even after successful closed reduction and postoperative immobilisation, residual instability often remains.<sup>2</sup> Closed reduction, particularly in posterior dislocations,<sup>3</sup> can become more difficult after 48 h and open reduction may become necessary. In addition, dislocations are frequently overlooked in the accident and emergency department,<sup>4</sup>

resulting in a degree of latency of presentation to the initial precipitating event.

Most authors agree that stabilisation surgery is best avoided in a patient who has an unstable sternoclavicular joint with minimal pain or functional restriction. Those patients who experience severe pain and disability with recurrent anterior dislocation of the sternoclavicular joint present a surgical challenge to the shoulder surgeon. The joint that is unstable posteriorly may pose a risk of serious complication to important underlying anatomical structures.

Numerous surgical procedures have been described to deal with this condition dating back to Sir Astley

Cooper who first described the condition in 1824.<sup>5</sup> Most of the techniques described since 1960 attempt to reconstruct the costoclavicular ligament with either autologous tissue grafts or synthetic material.<sup>6-8</sup> Surgery around the first rib is technically demanding and is associated with a risk of serious complications due to the proximity of major vascular structures. Many advocate that it should only be attempted with the combined expertise and availability of a cardiothoracic surgeon. It was for these reasons that we decided to test a repair that: (i) does not require exposure of the first rib; (ii) avoids drilling through the inner cortex of the clavicle and manubrium; and (iii) produces a direct anatomical restoration of the sternoclavicular joint.

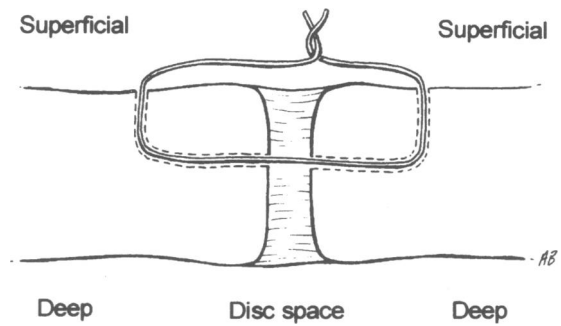
**Cadaveric study**

Bearn's work on cadaveric sternoclavicular joints in 1967 demonstrated the importance of the capsule in preventing dislocation.<sup>9</sup> Since then there has been little research based on testing stabilisation techniques in the anatomy department. The aim of our study was to test the strength of our new repair and compare it to a more conventional suture repair anchoring the medial clavicle to the first rib.

The university anatomy department donated two male cadavers with four normal sternoclavicular joints. Each joint was approached via a transverse incision along the long axis of the clavicle extending to the manubrium. The anterior capsule was divided in full. The intra-articular fibrocartilaginous disc (meniscus) was dissected, leaving a 5 mm space between the clavicle and the manubrium. The interclavicular ligament and the more substantial costoclavicular ligament were then divided. It was then possible to elevate the medial clavicle completely out of joint anteriorly with a towel clip. Our new 'safe' repair and a more conventional suture repair anchoring the medial clavicle to the first rib were compared in each of the cadavers.

*'Safe' repair*

Two 2.5 mm drill holes were made in the same sagittal plane in the clavicle 5 mm from its medial end. The drill holes breach only the outer cortex of the clavicle. Two further 2.5 mm holes were drilled into the medulla of the clavicle from the joint side in order to communicate with the initial holes. The same procedure was carried out 5 mm from the articular margin on the manubrium. The inner cortex of the manubrium is not breached. With all drill holes made,



**Figure 1** Cross-sectional line diagram of the 'safe' repair

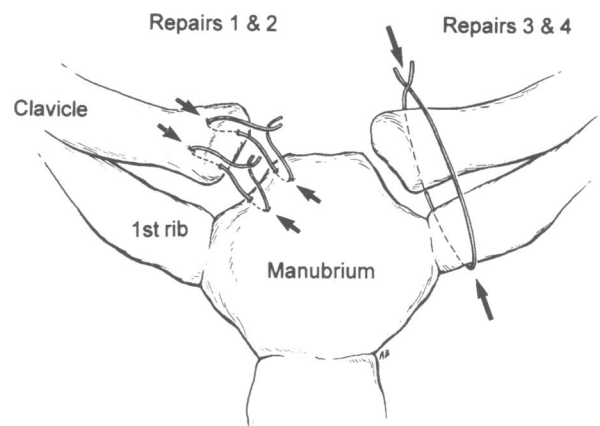
PDS (repair 1) or 5-ethibond (repair 2) sutures were double-looped between the medial clavicle and manubrium and tied under tension. Figure 1 is a schematic illustration of the 'safe' repair.

*'Conventional' first rib suture stabilisation*

A double loop of PDS or 5-ethibond suture was passed around the medial clavicle and the first rib and tied securely under tension. These were repairs 3 and 4. Figure 2 illustrates these repairs schematically.

*Load testing*

From a practical point of view, only anterior stability could be tested. This was performed via a pulley suspended above the cadavers with a traction cord tied lateral to the repair. Weights were added in 5 kg increments until either the repair failed or the medial clavicle dislocated anteriorly. The repairs were also tested dynamically by dropping set weights from a height of 1 m.



**Figure 2** Line diagram of the cadaveric repair methods

## Results

All four repairs withstood a total static load of 50 kg. The cadavers had to be secured after 30 kg as this weight was sufficient to lift the trunk from their trolleys with all repairs holding true.

**Repair 1** (PDS, 'safe') at 50 kg was still intact, but the joint was 50% subluxed anteriorly. It also withstood 50 kg dropped through 1 m.

**Repair 2** (5-ethibond, 'safe') at 50 kg was intact with 50% subluxation anteriorly. On dynamic testing with 50 kg, the clavicle fractured lateral to the repair.

**Repair 3** (PDS, first rib) held 50 kg, but the sternoclavicular joint was 75% subluxed anteriorly. It withstood the 50 kg dynamic weight dropped through 1 m.

**Repair 4** (5-ethibond, first rib) was also 75% subluxed anteriorly at 50 kg static testing. It ruptured on dynamic testing at 40 kg.

The tests demonstrated that our repair was strong in withstanding static and dynamic forces and allowed less subluxation of the joint under load than the conventional repair around the first rib. This may be secondary to a shorter working length effected in the safe repair. Despite the relatively poor bone quality of cadaveric specimens treated with formalin, sutures did not cut out in either repair. When utilised in the living patient with superior bone quality, it should prove even stronger and more durable.

## Clinical cases

### Case 1

A 23-year-old man sustained a heavy tackle whilst playing rugby, landing on his right shoulder. He complained of a painful shoulder girdle in the accident and emergency department. Plain radiographs, including views of the sternoclavicular joint, were reported as normal. Six weeks later, a CT scan revealed a right posterior sternoclavicular joint dislocation. Under general anaesthesia, an attempted closed reduction failed. An open procedure followed. The entire capsule and the costoclavicular ligament were torn with the medial clavicle completely dislocated posteriorly and virtually no intra-articular disc remaining.

The joint was reduced and a 'safe' repair using PDS was performed. Postoperatively, an attempt was made to immobilise the joint with a figure-of-eight technique but the patient found this too uncomfortable and it was disbanded after 5 days. He was reviewed at 6, 12 and 18 months postoperation. He has remained asymptomatic with a stable sternoclavicular joint and has returned to his occupation of bricklaying.

### Case 2

A 25-year-old man was involved in a road traffic accident sustaining multiple injuries. After dealing with his life-threatening injuries, it was noticed that he had an anterior dislocation of his right sternoclavicular joint. An attempt was made 72 h post-injury at closed reduction under general anaesthetic. This was unsuccessful, necessitating an open reduction at which the capsule and costoclavicular ligament was found to be torn. It was impossible to reduce the dislocation without excising damaged intra-articular disc remnants. A 'safe' repair using 5-ethibond sutures was performed.

At review in clinic at 15 months post-injury, his sternoclavicular joint remained stable with full and symmetrical shoulder movement.

### Case 3

A 23-year-old man was referred to the shoulder clinic with chronic recurrent anterior sternoclavicular joint instability. He had sustained his initial anterior dislocation playing rugby three years previously and was now unable to continue work as a roofer due to the joint dislocating when abducting his arm above 70°. He was able to reduce this himself, but found it extremely painful to do so.

At operation, the capsule, costoclavicular ligament and intra-articular disc were deficient. Stabilisation of his left sternoclavicular joint using the repair described was performed. He returned to work as a roofer four months following his procedure, and at 16 months had maintained a stable sternoclavicular joint with full and symmetrical shoulder movement.

## Discussion

In 1986, Eskola *et al.*<sup>10</sup> made a plea for open reduction and stabilisation in dislocation of the sternoclavicular joint due to poor results after conservative treatment. Although a variety of surgical stabilisation techniques have been described, few surgeons have great experience in terms of numbers operated. The use of K wires and wire sutures<sup>15</sup> can not be condoned in this area due to the well-documented complications that wire migration can cause. Salvatore<sup>11</sup> and DePalma<sup>12</sup> advocated excision of the medial clavicle, leaving the costoclavicular ligaments intact. A number of authors have since found this to result in unsatisfactory painful restriction of movement at the shoulder.<sup>7,8</sup> In the clinical cases described, this ligament was found to be deficient.

When dissecting the cadaveric joint, it was virtually impossible to dislocate the joint without excising it. The disc appears to contribute significantly towards joint stability, perhaps more so than the costoclavicular ligament. In 1928, Lowman<sup>13</sup> may have recognised this as he suspended fascia between clavicle and sternum in place of the damaged disc. When operating on the cases above, the intra-articular disc was found to be either irreparably damaged or absent.

A suture repair directly across the joint may induce a fibrous reaction to mimic the functions of the disc. The repair described avoids the need for the more extensive procedure of resection of the medial end of the clavicle and reconstruction of the costoclavicular ligament, as described recently by Rockwood *et al.*<sup>16</sup> The repair is technically easy and quick to perform. It carries a reduced risk of serious complications when compared with other techniques, especially those requiring exposure of the first rib. The early experience in terms of outcome is encouraging.

### Acknowledgements

We wish to acknowledge the help and co-operation of Mr Richard Newell and Mr Omri Morgan at the University of Wales Anatomy Department during the cadaveric study included in this paper.

### References

1. Rowe CR, Marble HC. Sternoclavicular dislocations. In: *Fractures and other Injuries*. Chicago, IL: Chicago Year Book Medical 1958; 258.
2. Rockwood Jr CA. Injuries to the sternoclavicular Joint. In: Rockwood CA, Green DP. (eds) *Fractures*, vol 1, 2nd edn. Philadelphia, PA: JB Lippincott, 1984; 910–48.
3. Post M. *The Shoulder: Surgical and Non-surgical Management*. Philadelphia, PA: Lea & Febiger, 1978; 488–500.
4. Thomas DP, Davies A, Hoddinott HC. Posterior sternoclavicular dislocations – a diagnosis easily missed. *Ann R Coll Surg Engl* 1999; **81**: 201–4.
5. Cooper A. *A Treatise on Dislocations and Fractures of the Joints*, 3rd edn. London, 1824.
6. Burrows HJ. Tenodesis of subclavius in the treatment of recurrent dislocation of the sternoclavicular joint. *J Bone Joint Surg Br* 1951; **33**: 240–3.
7. Booth CM, Roper B A. Chronic dislocation of the sternoclavicular joint: an operative repair. *Clin Orthop* 1979; **140**: 17–20.
8. Lunseth PA, Chapman KW, Frankel VH. Surgical treatment of chronic dislocation of the sternoclavicular joint. *J Bone Joint Surg Br* 1975; **57**: 193–6.
9. Bearn JG. Direct observations on the function of the capsule of the sternoclavicular joint in clavicular support. *J Anat* 1967; **101**: 159–70.
10. Eskola A. Sternoclavicular dislocations: a plea for open treatment. *Acta Orthop Scand* 1986; **57**: 227–8.
11. Salvatore JE. Sternoclavicular joint dislocation. *Clin Orthop* 1968; **58**: 51–4.
12. DePalma AF. *Surgery of the Shoulder*, 3rd edn. Philadelphia, PA: JB Lippincott, 1983.
13. Lowman CL. Operative correction of old sternoclavicular dislocation. *J Bone Joint Surg* 1928; **10**: 740–71.
14. Milch H. The rhomboid ligament in surgery of the sternoclavicular joint. *J Int Coll Surg* 1952; **17**: 41–51.
15. Elting JJ. Retrosternal dislocation of the clavicle. *Arch Surg* 1972; **104**: 35–7.
16. Rockwood CA, Groh GI, Wirth MA, Grassi FA. Resection arthroplasty of the sternoclavicular joint. *J Bone Joint Surg Am* 199X; **79**: 387–93.