



Case report

Locked lateral patellar dislocation with impaction fracture of patella

PM Phaltankar, SH Bridle

Department of Orthopaedics, St George's Hospital, London, UK

Irreducible lateral patellar dislocation is rare. It has previously been described with rotation around a vertical axis. We describe a case of irreducible lateral patellar dislocation in a 66-year-old lady with an impaction fracture of medial facet of patella locked on the lateral femoral condyle. Closed reduction was unsuccessful and the patient was treated by total knee replacement. Such a case has not been described previously in the literature.

Key words: Dislocation – Irreducible – Patellar – Lateral – Impaction fracture

A 66-year-old lady presented to us 2 weeks following twisting injury to knee. The knee was immediately painful and swollen with a feeling of the kneecap being 'out-of-place'. Prior to the injury, she had experienced some pain and crepitus from the knee, but had no previous history of patellar subluxation.

Physical examination of the knee revealed a marked effusion, with the knee locked in 10° flexion. The patella was displaced laterally and any attempted movement of the knee was extremely painful.

Roentgenographic examination including skyline view (Fig. 1) showed that the patella was dislocated laterally. The medial facet of patella was locked on the lateral femoral condyle with an impaction fracture of the medial patellar facet. A shallow trochlear groove was noted. Degenerative changes were noted in all the compartments. Aspiration of the knee yielded blood. Attempts at closed reduction were unsuccessful.

MRI scan of the knee (Fig. 2) showed bruising of the lateral femoral condyle and a high signal intensity in the medial patellar retinaculum adjacent to patella. There was articular cartilage thinning throughout the knee, with a degenerative medial meniscal tear.

It was decided that a total condylar PCL substituting knee replacement with patellar resurfacing should be carried out. A tear of the medial retinaculum was noted, along with damage to trochlear surface of lateral femoral condyle and an impaction fracture of medial patellar facet. A lateral retinacular release, with repair of medial patellar retinacular complex, including advancement of vastus medialis obliquus was required to achieve good patellar tracking. Postoperatively, the patient had a stable knee with flexion up to 90° and good patellar tracking.

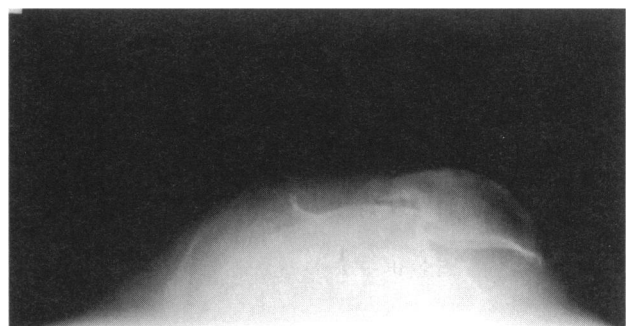

Figure 1 Skyline view showing dislocated patella locked on lateral femoral condyle.

Correspondence to: Mr PM Phaltankar, Specialist Registrar in Orthopaedics, Mayday University Hospital, London Road, Thornton Heath CR7 7YE, UK. Tel: +44 208 401 3000, Fax: +44 208 401 3100

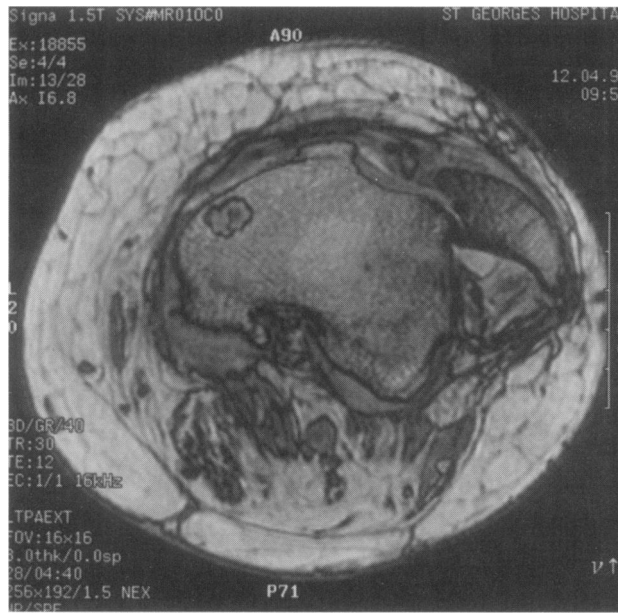


Figure 2 MRI scan showing bone bruising and medial retinacular injury.

Discussion

A variety of patellar dislocations have been described including superior, inferior, medial and intrarticular, apart from the relatively common lateral dislocation.

Though acute lateral dislocation of patella is not uncommon, irreducibility is rare. Irreducibility of patellar dislocation is usually associated with rotation around either a vertical or horizontal axis.¹ Locked lateral patellar dislocation has been reported in a young patient, with patella rotated 90° around its vertical axis and lying lateral to lateral femoral condyle.² Open reduction was required.

In our case, the patella was not rotated. In addition, there was a large impaction fracture of medial patellar facet, with

locking of medial facet on the lateral femoral condyle. Due to degenerative changes in all the compartments of the knee, prosthetic replacement, along with proximal realignment of quadriceps mechanism, was required.

The importance of performing skyline view in acute patellar dislocations has been emphasized.³ Small osteochondral fractures are best demonstrated by the skyline view. This view was also the most useful to show the pathology in our case.

Use of MRI scan in acute lateral patellar dislocations is well documented. MRI findings include a joint effusion, bone bruising to lateral femoral condyle and patella with damage to medial retinacular complex, usually seen as high signal intensity.⁴ The MRI appearance in our case was consistent with an acute injury.

A group of patients have recognized, predisposing factors to patellar dislocation including a shallow trochlear groove, patella alta, and an increased Q angle. Repair of medial retinacular complex with re-alignment of extensor mechanism is important to prevent recurrent dislocation.⁵ Proximal extensor mechanism re-alignment was required to achieve normal patellar tracking in our patient.

References

1. Gidden DJ, Bell KM. An unusual case of irreducible intraarticular patellar dislocation with vertical axis rotation. *Injury* 1995; 26: 643-4.
2. Corso SJ, Thal R, Forman D. Locked patellar dislocation with vertical axis rotation. A case report. *Clin Orthop* 1992; 279: 190-3.
3. Nayak RK, Bickerstaff DR. Acute traumatic patellar dislocation: the importance of skyline views. *Injury* 1995; 26: 347-8.
4. Spritzer CE, Courneya DL, Burk Jr DL, Garrett WE, Strong JA. Medial retinacular complex injury in acute patellar dislocation: MR findings and surgical implications. *Am J Roentgenol* 1997; 168: 117-22.
5. Cash JD, Hughston JC. Treatment of acute patellar dislocation. *Am J Sports Med* 1988; 6: 244-9.