

HERMAPHRODITISM

A Critical Survey

By HUGH JOLLY, M.D., M.R.C.P., D.C.H.

Consultant Paediatrician, Plymouth Clinical Area

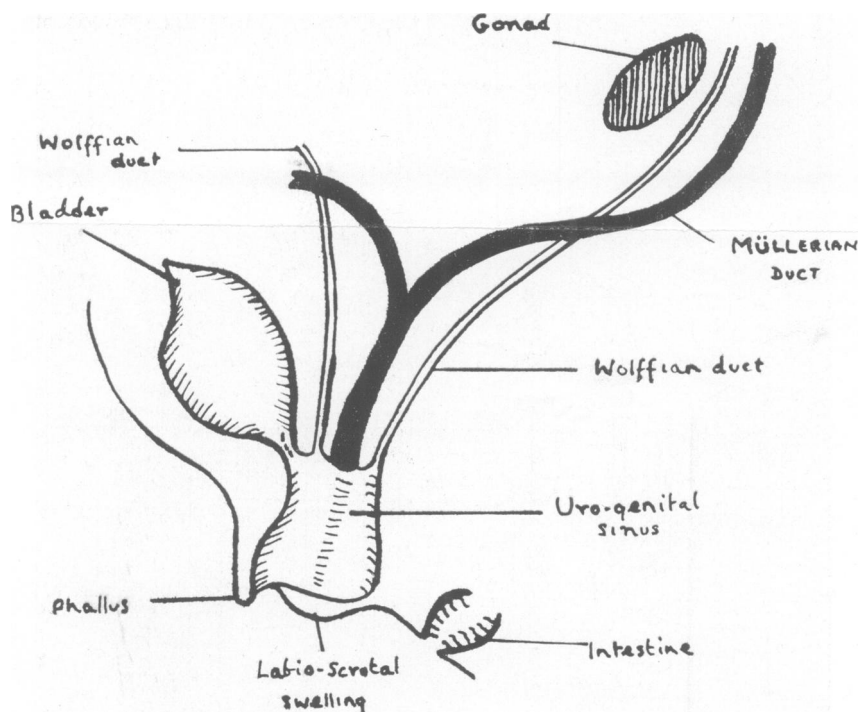


FIG. 1.—The undifferentiated stage of urogenital development.

The problem of hermaphroditism is one which has always attracted attention so that much has been written on the subject. One of the finest works appeared in 1937, with the publication of Young's monograph¹ and this has become a classic. In recent years, Lawson Wilkins and his co-workers at Johns Hopkins have, more than anyone else, furthered our knowledge of the subject and much of the information in the present article is derived from their writings²⁻¹⁵ and from personal communication with Dr. Wilkins. Liberal use also is made of the present author's publications¹⁶⁻¹⁸ on the subject as well as more recent personal experience.

Embryology

The occurrence of hermaphroditism is due to

the complicated method by which the male and female genital tracts and external genitalia are derived, and particularly to the fact that this development is common to both in early embryonic life (Fig. 1).

The Gonads

Up to the sixth week, therefore, the gonads are identical in both sexes and the embryo potentially bisexual. Changes in the gonad take place earliest if the embryo is to become male when, at the seventh week, the elements of the testes appear, being derived from the medulla of the gland. If the foetus is to become female no distinctive features appear until the tenth week when the germinal epithelium, consisting of epithelial nests and primordial follicles containing ova, is

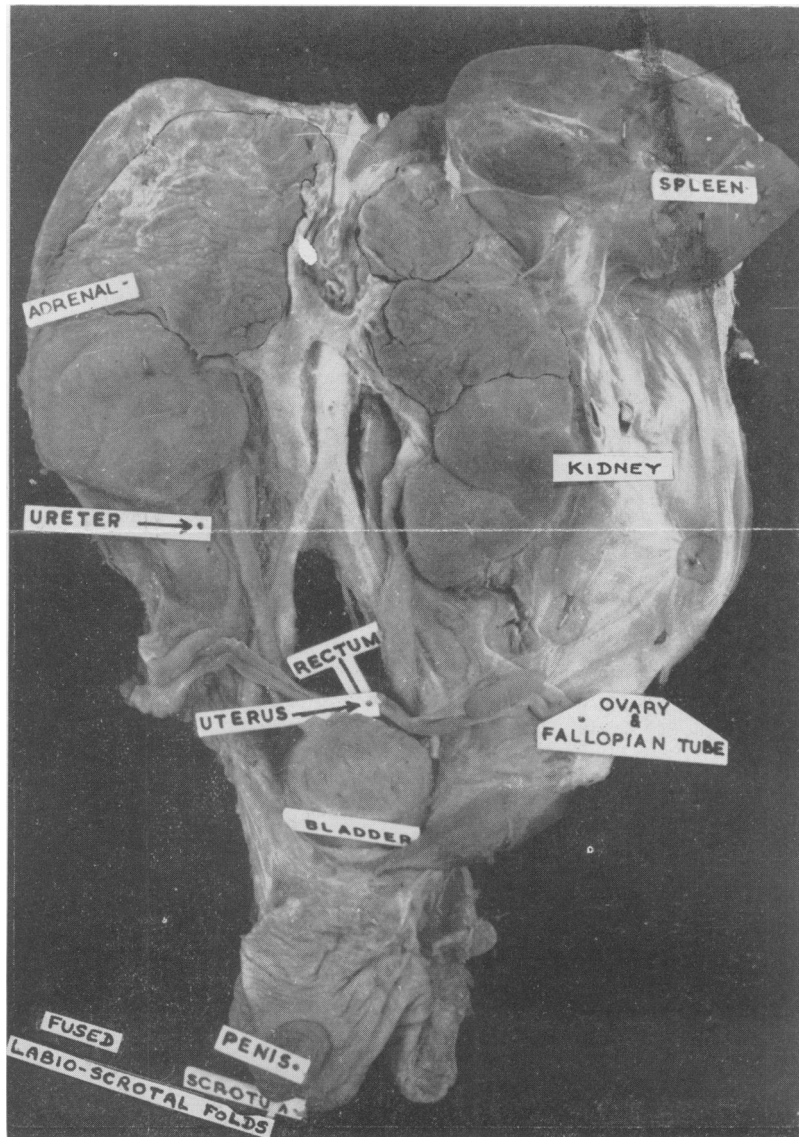


PLATE I.—P.M. specimen showing congenital adrenal hyperplasia. The hyperplastic adrenal glands are seen to be larger than the kidneys. The infantile uterus tubes and ovaries are well shown.

derived from the cortex of the gland. It is apparent therefore, that the testis develops from the medulla and the ovary from the cortex of the gonad, but even this adult differentiation is not complete since the normal testis contains 'female' (cortical) components and the ovary contains 'male' (medullary) components. In this light it is understandable that on very rare occasions the foetal gonad may develop into an ovo-testis, being

part ovary and part testis or that one gonad becomes an ovary and the other a testis.

The Genital Ducts

In the undifferentiated stage (Fig. 1) two pairs of genital ducts lead from the gonad to the urogenital sinus—the male or Wolffian ducts and the female or Mullerian ducts. These ducts are not ambisexual and remnants of the pair

belonging to the opposite sex are to be found in adult life. The Wolffian ducts become the epididymis, vas deferens and seminal vesicles in the male, whereas, in the female, their remnants exist as the epoöpheron, paroöpheron and Gärtner's ducts. The Mullerian ducts become the Fallopian tubes, uterus and vagina, the latter two structures being formed by fusion of the two ducts. Their remnants in the male are the appendix testis, utricule and verumontanum.

The Urogenital Sinus

In the undifferentiated stage the bladder and both sets of genital ducts open into the urogenital sinus. In the male the urogenital sinus becomes the lower part of the prostatic urethra and penile urethra. In the female this sinus becomes the shallow vestibule which contains the orifices of the urethra and vagina. This is separated from the vagina by the hymen whose inner surface is lined by vaginal epithelium derived from the Mullerian duct and outer surface from urogenital sinus epithelium.

External Genitalia

The genital tubercle enlarges in both sexes to form the phallus and as it does so a median groove appears on its caudal surface. The raised margins of this groove are the urethral folds. In the male the phallus lengthens to become the penis and as it does so the urethral folds fuse round the urogenital sinus from behind forwards in such a way as to carry the penile urethra, which has formed from the urogenital sinus, to the tip of the penis. The two labioscrotal folds which have appeared on each side of the base of the phallus become fused in the male to form the scrotum.

In the female the phallus becomes the clitoris, while the genital and labioscrotal folds do not fuse but become the labia minora and majora respectively.

Classification

Two distinct groups of hermaphrodites should first be separated on the basis of aetiology, the one being due to an adrenal disorder and the other not. Thus we have:

- (I) Female pseudohermaphroditism due to congenital adrenal hyperplasia.
- (II) Intersex.

In this latter group there is no endocrine dysfunction and the aetiology is unknown, although genetic factors play a part. It includes the remaining varieties of pseudohermaphroditism and all true hermaphrodites.

In female pseudohermaphroditism with adrenal hyperplasia there is progressive virilization from birth, whereas in intersexes no further changes take place until puberty which occurs at the usual

age. The problems of homosexuality and transvestism will not be discussed in this paper since they are psychological problems only.

(I) *Female Pseudohermaphroditism with Adrenal Hyperplasia*

This is the commonest of all types of hermaphrodites and Money quoted by Wilkins *et al.* (1955)¹¹ in a recent survey of published cases between 1895 and 1950 has shown that the condition occurs as frequently as all the types of intersex.

The hyperplasia of the adrenal cortex (Plate 1) commences in early foetal life and produces a massive masculinizing stimulus from the outpouring of androgens. This action begins in the fourth month by which time the gonads have already differentiated to form ovaries but the Mullerian ducts have only developed as far as the formation of Fallopian tubes and uterus. The further development of the genital ducts now takes place along male lines as a result of the androgenic stimulus, so that the urogenital sinus persists as in Fig. 2, type A, instead of giving way to a separate urethra and vagina. This figure shows the commonest anatomical arrangement in these patients, there being one external orifice only so that the vagina appears to open into the floor of the urethra. The phallus steadily enlarges instead of remaining small as a normal clitoris and the labioscrotal folds fuse to some extent and thereby give the impression of a scrotum rather than labia majora. The ovaries however do not descend so that the 'scrotum' is always empty.

Other varieties of this condition may occur, the next most common being shown as type B in Fig. 2. Here the urogenital sinus opens externally through a funnel-like orifice which is larger than the previous type so that the urethra appears to open into the roof of the vagina. Three other much rarer types have occurred. In type C, there is no communication between vagina and urethra; in type D the urethra has been carried forward by fusion of the urethral folds so that its orifice is at the tip of the clitoris. In type E the vagina and urethra have differentiated to become separate as in the normal female, and one can only presume that in this case the androgenic stimulus did not commence until after the fifth month of foetal life.

At birth then, the child, who is of average rather than large size, will be normal apart from a large clitoris, and in most cases will have a single external orifice serving both urethra and vagina. A varying degree of fusion of the labioscrotal folds will be present and the uterus can usually be felt on rectal examination. After birth the androgenic stimulus continues so that the child grows more rapidly than normal and the epiphysial

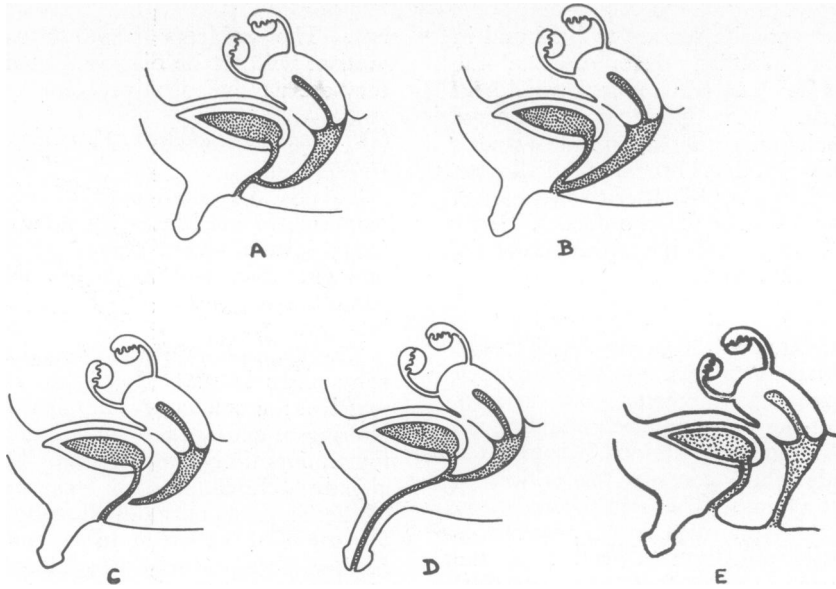


FIG. 2.—Varieties of female pseudohermaphroditism with adrenal hyperplasia.

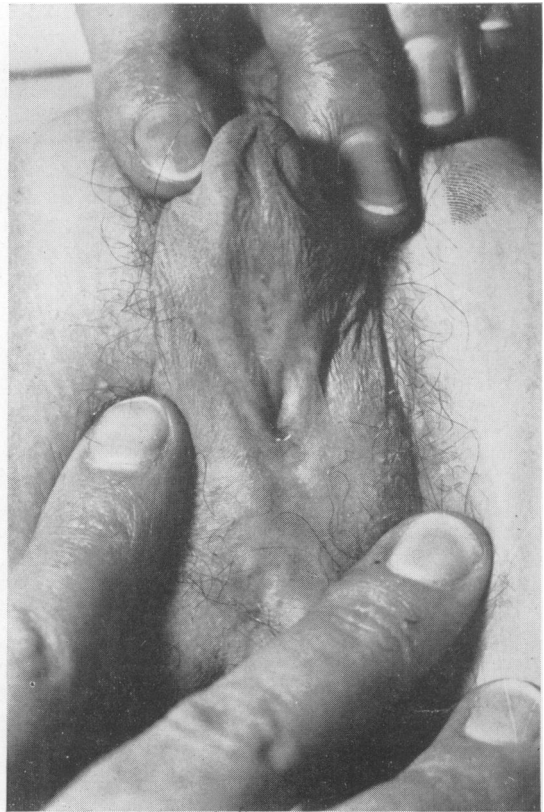
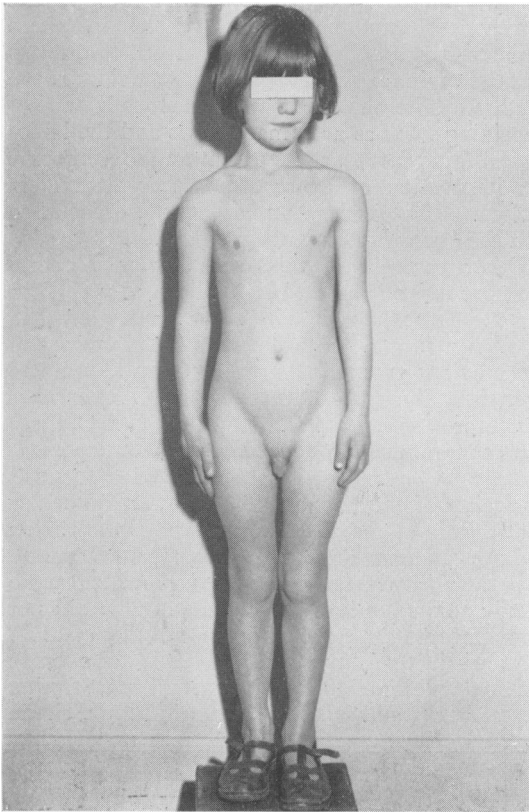


PLATE 2.—Female pseudohermaphrodite with adrenal hyperplasia. These photographs were taken when the child was first seen at the age of five years and before cortisone therapy was commenced. The thickened and enlarged phallus can be appreciated, together with the growth of pubic hair and the single external orifice.

bone age is advanced. The phallus continues to increase in size, being much thicker than a normal clitoris, but not so long as a penis. It is bound downwards in a curve—a condition known as chordee. Gross¹⁹ states that the enlarged clitoris can be differentiated from the penis by the two small folds which run down on either side of its midline to join the labia minora. In the penis there is a single frenulum on the ventral surface. Erections of the enlarged phallus become increasingly frequent and may be painful. The voice deepens as a result of the same changes in the vocal cords that occur in the normal male at puberty. Pubic hair appears between the age of two to five years and is followed by axillary and facial hair with acne of the face a common accompaniment. Muscular development becomes marked although the bodily contours remain predominantly feminine (see Plate 2 and Jolly¹⁸ photos of cases 56 to 60). A few patients have hypertension.

No breast development or menstruation occurs at the time of an expected puberty but by this age epiphysal fusion has occurred to such an extent that further growth is impossible. Therefore, after an initial spurt of growth in early childhood, putting the child head and shoulders above those of her own age, she ends up much shorter than the average.

Diagnosis. This must be made as soon as possible after birth since early treatment is essential. However, at this early age the condition can easily be confused with some varieties of intersex which may have the same anatomical configuration. Further evidence is therefore required in order to prove the presence of adrenal hyperplasia and thereby confirm the diagnosis. This proof is given by the rise in urinary excretion of 17 ketosteroids from the normal of less than 0.5 mg. in 24 hours at birth to a level of 2 to 5 mg. within the first few weeks of life. The level continues to rise as the child grows and by adolescence may reach levels of 25 to 80 mg. In the early weeks of life the 17 ketosteroids may give ambiguous results but in these cases the finding of an increased excretion of pregnanetriol in the urine is diagnostic of congenital adrenal hyperplasia (Bongiovanni and Clayton²⁰).

Laparotomy has frequently been used in the past for confirmation of the diagnosis but is unnecessary and dangerous, since adrenal failure may be precipitated by the operation. Perirenal insufflation to outline the enlarged adrenals has been recommended by some writers, but this also is a dangerous practice, and in any case the rise in 17 ketosteroids is a much better guide to the state of the glands.

Urethroscopy is the only further investigation which should be performed if further confirmation

of the diagnosis is required. The urethroscope is passed into the capacious urogenital sinus until the vaginal opening is visible in the floor of the sinus as a slit-like aperture surrounded by folds. This opening is usually large enough to allow the passage of the urethroscope into the vagina until the cervix can be seen as a smaller slit and into which an ureteric catheter can usually be inserted. If necessary, a radio-opaque dye can be injected and watched under the X-ray screen as it passes along the Fallopian tube and out into the peritoneal cavity through the fimbriated opening (Plate 3).

If the child is not seen until a few years after birth the diagnosis is very much easier on account of the progressive virilization which will have taken place. This is shown by an acceleration of growth and epiphysal development as well as by the presence of sexual hair, the muscular development and the deepened voice.

The condition of 'premature pubarche' (Silverman *et al.*⁹) may cause some confusion with these patients and should be mentioned. It is a constitutional variation of adolescence whereby chil-

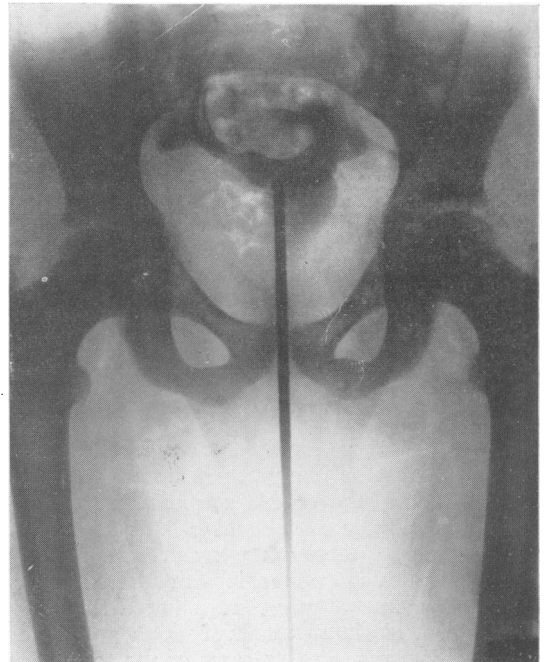


PLATE 3.—Female pseudohermaphrodite. Anterior salpingogram. The urethroscope lies in the vagina with its tip at the cervix, while the ureteric catheter can be seen in the left Fallopian tube. Dye has filled the uterus and passed up both Fallopian tubes, finally spilling over into the peritoneal cavity, where it forms shadows which are less well defined. (Reproduced with permission from the *Proceedings of the Royal Society of Medicine.*)

dren of both sexes, though more particularly girls, develop a premature growth of pubic hair. No other signs of precocity are present, except that skeletal maturation, and 17 ketosteroid excretion may be slightly increased, and a normal puberty will occur at the usual age. Silverman *et al.* suggest that the condition is due either to an undue sensitivity of the hair follicles to androgen secretion or to an early elaboration of adrenal androgens before the gonadotropic mechanism of the pituitary has been activated.

An adrenal tumour may also lead to diagnostic difficulties from its virilizing effect, but the condition occurs after birth and the anatomical development of the genitalia will be normal. There is a similar rise in the 17 ketosteroids, but the administration of cortisone produces no fall in their excretion as compared with the dramatic fall in cases with adrenal hyperplasia.

Heredity. Carter²¹ states that some, and perhaps all instances of congenital adrenal hyperplasia are inherited as an autosomal recessive condition and Grumbach¹⁴ has found that if one patient of the salt-losing type has occurred, all other affected children born into that family will have the salt-losing complication as well. There are certainly many reports (Jolly,¹⁸ p. 74) which illustrate the importance of genetic factors. If congenital adrenal hyperplasia affects a male, the condition of macrogenitosomia praecox results. Consequently, if two members of opposite sex in a family are affected, the girl is a female pseudohermaphrodite and the boy has macrogenitosomia praecox. These facts of heredity should be given to the parent of any child with congenital adrenal hyperplasia.

Prognosis. Cortisone therapy has entirely altered the future for these patients, but it is only fair to say that the prognosis as to life before the days of cortisone was not as bad as was often alleged. The present author (Jolly,¹⁸ p. 76) refers to instances of elderly patients who have never received cortisone and there must be many others unrecorded. At the same time, the risk of adrenal insufficiency during infancy is considerable and in Gross' recent survey¹⁹ there were 27 female pseudohermaphrodites and one male with adrenal hyperplasia, of whom '50 per cent.' showed this complication. This is an unusually high proportion and Wilkins¹³ refers to 15 cases of the salt-losing type out of a total of 67. Adrenal insufficiency in these patients has been explained on the grounds of the hyperplasia of the zona reticulata, which is the principal feature of the enlarged adrenal glands. This hyperplasia takes place at the expense of the zona glomerulosa and zona fasciculata, which are believed to be responsible for electrolyte control. Recent experimental work with ACTH has shown

that the explanation is not as simple as this and Wilkins³ (p. 54) has suggested that the condition may be due to the secretion of types of glyco-genetic hormones (such as 17 hydroxycorticosterone) which increase the excretion of salt.

Treatment. All patients should be given cortisone provided the condition is diagnosed during the first year or two. The exception to this rule is the child who in error has already been brought up as a boy and may be better left unchanged in sex and therefore untreated with cortisone. This problem is discussed more fully in the later section on the psychological aspect of hermaphroditism. Under no circumstances should partial adrenalectomy, a popular operation in the past, be performed. The operation carries a considerable risk and its effects are only temporary.

The aim of cortisone therapy is to reduce the level of 17 ketosteroids as rapidly as possible and then, by trial and error, to find the smallest maintenance dose to keep them at this low level. In older children it may not be possible to reduce the level below 4 to 6 mg., but in small infants it should be possible to reach 0.5 mg. Cortisone may be given intramuscularly or by mouth, but Wilkins prefers the intramuscular route since its action is more predictable, it lasts longer and smaller doses are required than when given by mouth. Moreover, it may be possible to maintain suppression of 17 ketosteroid excretion by an injection of cortisone given every fourth day only. It is important that only the smallest amount of cortisone required for maximum suppression of ketosteroids is given, since an excess of cortisone suppresses growth. During periods of infection there may be a temporary release from cortisone suppression, since the adrenals are still capable of responding to stress, but no immediate change in cortisone dosage is required and this should only be made if the rise in the 17 ketosteroids persists.

Cortisone therapy should be started as early in life as possible in order to prevent the secondary structural changes in the body from taking place. Furthermore, if cortisone is not started until the bone age has reached 10 years or more, a rapid and premature adolescence takes place, breast development and menstruation occurring within a few weeks. In these cases it appears that the pituitary-gonadal mechanism has already reached a stage which on release with cortisone precipitates an immediate adolescence.

Cortisone started shortly after birth will allow normal growth and normal female development to take place. Wilkins *et al.*¹⁵ refer to two instances where pregnancy has occurred. If sexual hair has already appeared, the further rapid skeletal growth can be prevented. Similarly acne, and hypertension if present, disappear, as do the frequent

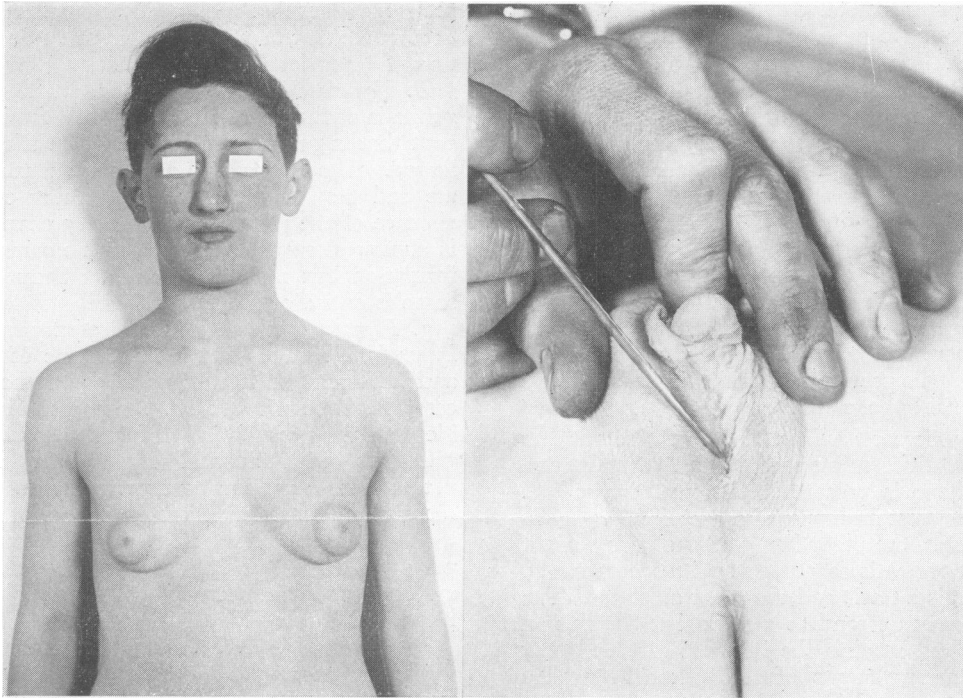


PLATE 4.—True hermaphrodite. This boy had well-developed breasts, as seen in the left-hand photo taken at the age of 15 years. The genitalia, photographed at 12 years, showed a penis with a hypospadiac urethral meatus at its base. An ovotestis was found in the right side of the scrotum and a left ovary in the correct position. Uterus, vagina and Fallopian tubes were present. (This patient was under the care of Mr. Denis Browne and his case has been recorded by Williams (1952), *Brit. med. J.*, i, 1264.)

and sometimes painful erections of the clitoris which occur in many of the children. If the voice has already become deep the cortisone cannot alter it, as permanent structural changes have taken place in the vocal cords.

It is still too early for the assessment of the long-term results of cortisone therapy, but present findings (Wilkins⁹) indicate that the suppression of adrenal activity persists to some extent after the withdrawal of the drug. This possibly indicates that the adrenal disorder may be permanently altered so that no relapse will occur when cortisone is withdrawn, comparable to the treatment of hyperthyroidism with thiouracil.

Some of the patients, particularly infants, may show electrolyte disturbances from adrenal insufficiency and the patient may first present with these symptoms. This adrenal lack manifests itself as a failure to thrive, persistent severe vomiting, diarrhoea and attacks of acute circulatory failure. The child becomes dehydrated and there is a fall in serum sodium and carbon dioxide levels with a rise in potassium.

Wilkins recommends the following line of treat-

ment for the cases of congenital adrenal hyperplasia of the salt-losing type:

1. When first seen the child should be given large doses of sodium chloride (3 to 6 g. daily) in order to correct the dehydration and salt lack.

2. When the immediate emergency is over cortisone should be given and its dose adjusted while continuing with the large doses of sodium chloride.

3. When the dose of cortisone has been adjusted desoxycorticosterone (DOCA) should be given and the dose of DOCA and salt worked out in order to obtain normal electrolyte levels.

4. The calculated dose of DOCA should be given by implantation.

The advantage of giving DOCA is that it reduces the amount of salt required, so that the large doses of salt can be kept for emergencies.

With early treatment the removal of the enlarged clitoris is seldom necessary and even in those diagnosed later the organ should not be removed unless the large size is causing distress, in which case early amputation is desirable. Hampson²² has shown that amputation of the clitoris in childhood does not prove detrimental to subsequent sexual

responsiveness, as stated by some authors, and if the parents have been in doubt about the child's correct sex the removal of the enlarged clitoris will assist their adjustment. A vaginoplasty should be carried out in order to provide an adequate orifice for the vagina and Gross¹⁹ recommends that this should be undertaken when the child is in her 'teens.

(II) *Intersex*

The varieties of this condition have been summarized by Wilkins in the following table (reproduced with permission from *Pediatrics*, 16, 288, 1955), where findings are compared with those in cases of female pseudohermaphroditism associated with adrenal hyperplasia.

1. *True Hermaphrodites*. In these rare patients the gonads differentiate so that both testicular and ovarian tissue is present in the same individual. The commonest finding is that one or both gonads are ovotestes, the other being an ovary or testis if only one ovotestis is present. Less commonly, one gonad is a testis and the other an ovary. The ovotestis may descend as a normal testis, but an ovary seldom reaches the inguinal canal. Many different arrangements of the external genitalia have been reported (Plate 4).

To make the diagnosis both gonads must be biopsied and one cannot predict the type of secondary sexual development which will take place at puberty. No case of true hermaphroditism achieving parenthood in either sex has been reported.

2. *Male Pseudohermaphroditism*. In these patients the gonads are morphologically testes and are sited in the abdomen or in the labioscrotal folds. If they are in the abdomen they lie either in the site of the ovaries or in the inguinal canal. The tubules are immature, being composed of undifferentiated germinal cells, but after puberty Sertoli cells may predominate and numerous Leydig cells are often found in large clumps.

There are two principal types of male pseudohermaphroditism, one in which the external genitalia are male or ambiguous, and the other in which they are female. Familial factors play a part so that more than one case may occur in the same family (Plate 5).

A. Male or Ambiguous External Genitalia. A varying degree of phallic development and labioscrotal fusion exists, while uterus and tubes may be present and fully developed. In other cases the uterus is incompletely developed and one or both tubes absent. Paradoxically, if the genital ducts are predominantly female, the child is likely to develop male secondary characteristics at puberty, whereas those in which the ducts are predominantly

male may develop along either line. Feminine development, when it occurs, is due to the secretion of oestrogens by the testes.

B. Female External Genitalia. The external genitalia of these patients are entirely feminine except that in some the clitoris may be slightly enlarged. The urethra and vagina are usually separate and the latter often ends blindly owing to absence of the uterus. At puberty development is always along female lines with normal breast formation but no menstruation. Sexual hair in some is entirely absent.

3. *Female Pseudohermaphroditism (without adrenal hyperplasia)*. This is the rarest type of intersex and Wilkins *et al.*¹¹ state that only 12 authenticated cases have been recorded. The genital tract is identical with that found in female pseudohermaphroditism with adrenal hyperplasia but the patients differ in showing no virilization. Normal secondary sexual development occurs at puberty with menstruation taking place through the urethral meatus. The ovaries mature and show evidence of ovulation with formation of corpora lutea.

Diagnosis of Intersex. The first step in the diagnosis is to exclude female pseudohermaphroditism due to adrenal hyperplasia. This is done on the basis of the progressive virilization already discussed.

The next step is urethroscopy and dye studies as already described, in order to determine the type and extent of the internal genitalia. This should be followed by laparotomy to examine the internal genitalia and make biopsies of both gonads. As an additional diagnostic aid the chromosomal sex should be determined by means of Barr's technique of skin biopsy (Moore *et al.*²³; Barr²⁴) which is based on the smaller size of the Y chromosome. Females have an XX chromosome combination and the mass of sex chromatin formed by the fusion is sufficiently large to be visible. It forms a planoconvex mass just under one micron in diameter and usually lies against the inner surface of the nuclear membrane but is occasionally free in the nucleoplasm or adjacent to the nucleolus. Males have an XY combination which is too small to be distinguished from the general particulate chromatin.

Barr's results have so far shown that all male pseudohermaphroditism and female pseudohermaphroditism with adrenal hyperplasia tested, have given correct results. True hermaphrodites and female pseudohermaphroditism without adrenal hyperplasia may have either male or female type nuclei. It will be apparent that those giving correct results involve by far the largest group of those with ambisexual development.

It had been hoped that this work would demon-

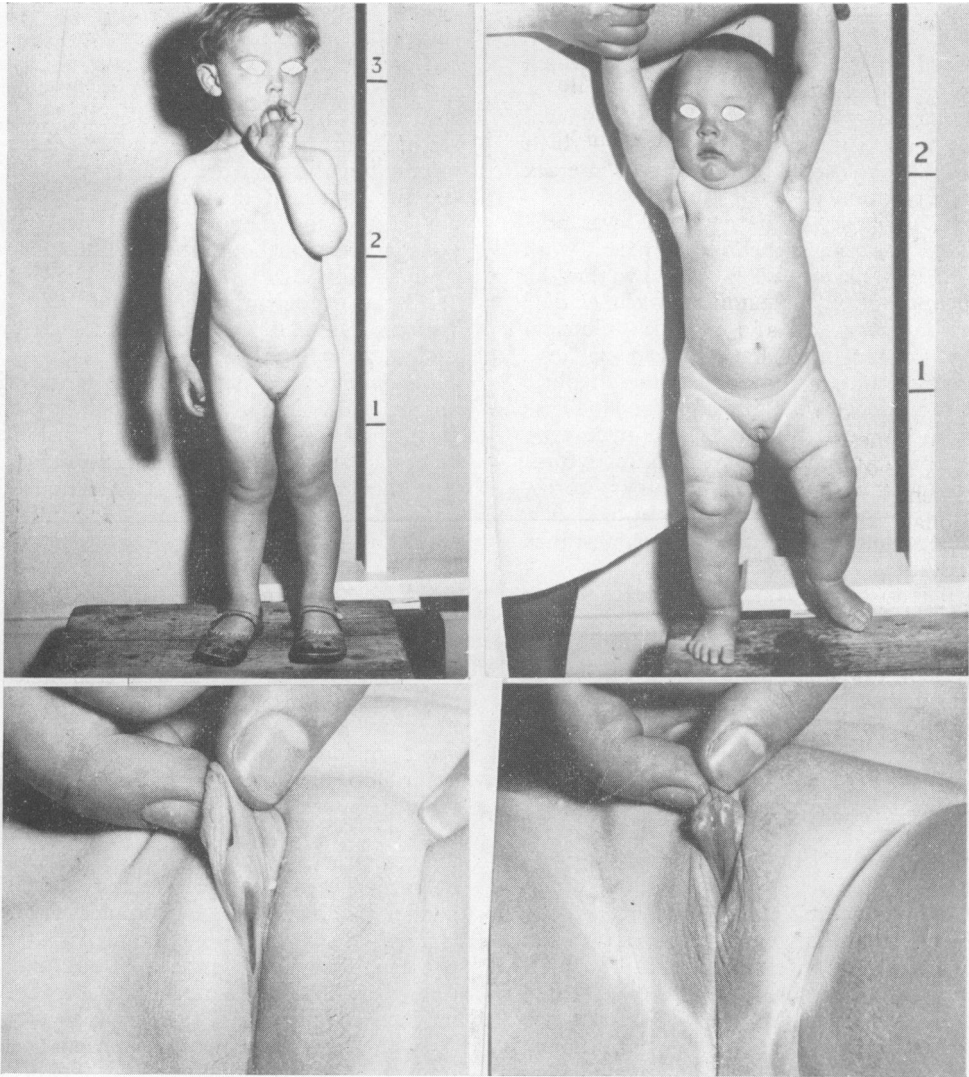


PLATE 5.—Two male pseudohermaphrodite brothers, aged ten months and three years respectively. The gonads, which proved to be testes, were found in the site of the ovaries and surrounded by structures resembling Fallopian tubes, including fimbriated ends. No uterus or vagina was seen.

strate the 'dominant' sex in equivocal cases but this has not proved to be so. For example, male pseudohermaphrodites with strongly feminine characteristics both anatomically and psychologically still show a male chromatin pattern. It is for this reason that Barr, both in his earlier and later writings^{25, 26} has emphasized that the chromatin pattern should not unduly influence clinicians in their decisions as to which sex a child should be brought up. The test is a valuable diagnostic aid but the decision as to the sex of upbringing must be decided on all the available

data and particularly the psychological factors. It is for this reason that Barr pleads for the use of the terms 'chromatin positive' or 'chromatin negative' rather than female or male nuclei, pointing out that much unnecessary distress might be caused to a patient were he or she to learn that the cell nuclei were of a different sex from that in which he or she had been brought up.

Research is continuing to discover other sites in the body from which material can be obtained for the sexing of nuclei and in particular to obviate the need for a biopsy. Davidson and Smith²⁷ have

used the polymorph nuclei in blood films while Moore and Barr²⁸ have recently described a method based on scrapings of oral mucosa which their state are easier to interpret than skin biopsies.

Differential Diagnosis. Two conditions—Gonadal Dysgenesis and Klinefelter's Syndrome—which may enter into the diagnostic problems of intersex remain to be mentioned.

Gonadal Dysgenesis. This condition was previously called 'ovarian agenesis' but recent work (Polani *et al.*²⁹; Wilkins *et al.*³⁰) has shown that the nuclei are most often male. Grumbach *et al.*¹⁰ have therefore suggested the title of 'Gonadal Dysgenesis.' (Dysgenesis rather than agenesis since varying amounts of rudimentary mesonephric elements are present in the genital ridge.) These patients with gonadal dysgenesis and male type nuclei must be regarded as the most extreme form of male pseudohermaphrodite—in other words, genetic males who are completely feminized.

The patients have a normal female appearance but are stunted in growth. Secondary sex characters fail to develop at puberty except that sexual hair develops. Laparotomy shows the presence of an infantile uterus and tubes with a thin strip of tissue in the site of the ovary. This tissue contains no germ cells but is composed of cells resembling ovarian stroma although this is not in fact sex-specific. The diagnosis is confirmed by the finding of a high level of follicle stimulating hormone (FSH). Associated anomalies, particularly webbed neck, cubitus valgus and coarctation of the aorta may be present.

Klinefelter's Syndrome. This condition, which affects males, was described by Klinefelter *et al.*³¹ in 1942. The patients have small testes, azospermia and an increased urinary excretion of FSH. Secondary sexual characteristics may be fairly well developed but the testes are of preadolescent size and the configuration of the body may be feminine. Gynaecomastia is a common accompaniment and it is particularly for this reason that diagnostic difficulties may arise as in the true hermaphrodite recorded by Williams³².

The Psychological Aspect of Hermaphrodites

In deciding the correct sex of upbringing the psychological aspect is probably of more importance than all the other methods used for the determination of sex, namely, the gonadal, hormonal and chromosomal sex as well as the type of internal and external genitalia. This statement is based on my own experience (Jolly,¹⁸ page 80), and is supported by the recent careful and very important studies of Money, Hampson and Hampson.^{22, 33, 34} These workers have carried out extensive studies on many hermaphrodites of different types and emphasize the importance of the 'gender

role.' This term is used to signify all those things that a person does or says to disclose himself or herself as having the status of boy or man, girl or woman respectively. It includes, but is not restricted to, sexuality in the erotic sense. Their research has shown that the gender role and orientation as a male or female closely conforms to the sex to which the patient has been assigned and reared and that it is largely independent of gonadal, hormonal or chromosomal sex or the state of the genitalia.

As part of their work 22 patients, who had lived with a contradictory genital appearance for periods of five to 47 years, were studied. In all but one case these patients had come to terms with their anomaly and had a sexual orientation consistent with their assigned sex and opposite to their external appearance. The conclusion was reached that the psychological aspect of sex is undifferentiated at birth and becomes differentiated as the result of the experience of growing up. The gender role is well established by the age of two and a half years and remains so indelibly printed that not even gross discrepancies between it and the external appearance of the patient will displace it.

Ellis³⁵ in a different type of study reached similar conclusions. Eighty-four cases from the medical literature were studied and it was shown that the great majority assumed a sexual role which accorded with the sex of upbringing rather than with the internal or external genital characteristics.

From the practical point of view, this work indicates that any change in the child's sex must be made before the age of three years, since the gender role is by then established. After this age changes of sex should only be made at the request of the patient and after the most careful consideration. In these cases the decision would only be made after puberty.

In the management of all hermaphrodites it is imperative that the common feeling of the child that he or she is half boy and half girl should be removed. This can be dealt with by an explanation that he or she is a boy or girl and that it is only the genital development which is incomplete.

Selection of Sex of Rearing in Cases Seen in Infancy

1. Congenital Female Pseudohermaphroditism with Adrenal Hyperplasia

These patients should always be brought up as girls and given cortisone unless seen later in childhood and already brought up as boys, when no change should be made and no cortisone given.

2. Intersex

Male Pseudohermaphrodites and True Hermaphrodites. In these cases the best guide is the state of the external genitalia, and particularly the size of

TYPES OF AMBISEXUAL DEVELOPMENT

| | Gonads | Phallus | Labial Fusion | Genital Ducts | Secondary Sex Development |
|---|--------------------------------|---------------------------------|---------------|--------------------------------------|---------------------------|
| I. Congenital adrenal hyperplasia: Female pseudohermaphrodites .. | Ovaries | Large | +++→O | Female | Male precocious |
| II. Intersexes: | | | | | |
| 1. True hermaphrodites | Mixed | Variable | Variable | Mixed | Male or female |
| 2. Male pseudohermaphrodites: | | | | | |
| A. External genitalia simulating male or ambiguous .. | Testes (Abdominal or inguinal) | Large to medium | +++ + + + | Predominantly female (male vestiges) | Usually male |
| B. External genitalia simulating female | | | | Predominantly male (female vestiges) | Male or female |
| 3. Female pseudohermaphrodites .. | Ovaries | Large (may have penile urethra) | +++ | Female | Female |

the phallus or the presence of a serviceable vagina. If the phallus is of a reasonable size the child should be brought up as a boy, but if it is small, and female external genitalia are present, the child should be brought up as a girl, particularly since male pseudohermaphrodites of this type most often become more feminine at puberty.

The question of orchidectomy in these patients is debatable. With true hermaphrodites the ideal is to remove the gonad and the internal organs which do not conform to the assigned sex. If male pseudohermaphrodites are to be brought up as girls, removal of the testes has been recommended on the grounds of an increased risk of future malignant change. On the other hand, this will remove the source of the oestrogens which can be expected in those with female external genitalia and necessitate later oestrogen therapy. However, this is not too serious and in all cases the correct hormone should be given at puberty as required, in order to enhance the secondary sexual characteristics.

Female Pseudohermaphroditism without Adrenal Hyperplasia. These patients should be brought up as girls, since they will later menstruate. A vaginoplasty and possibly amputation of the clitoris will be required.

Summary

A survey of present-day views on hermaphroditism is presented and the different types de-

scribed in the light of embryological knowledge. Particular attention is paid to the psychological aspect, since the sex in which a hermaphrodite is reared is more important than any other feature in determining the 'gender role,' that is, the sex which he or she feels they are. This gender role is firmly established by the age of two and a half years and only very rarely should any change in sex be made after this age.

With the development of newer methods for the detection of sex, such as the examination of cell nuclei, one must beware lest patients are thereby forced to take up a sex contrary to their own desires and inclinations. In general (apart from cases of female pseudohermaphroditism), it is the external genitalia which determine the sex in which the patient can lead the happiest life.

Acknowledgments

I would like to thank Mr. Denis Browne and Mr. D. Innes Williams for permission to reproduce photographs of their patient (Plate 4). I am also grateful to Mr. Derek Martin and the Photographic Department of the Hospital for Sick Children, Great Ormond Street, London, and to the same department of the South Devon and East Cornwall Hospital, Plymouth, for the illustrations.

REFERENCES

1. YOUNG, H. H. (1937), 'Genital Abnormalities, Hermaphroditism and Related Adrenal Diseases,' Williams and Wilkins, Baltimore.

Continued on page 607.

TABLE I

| 1956 | Feb. 27 | March 5 | March 8 | March 12 | March 15 | March 17 |
|--|---------|---------|---------|----------|----------|----------|
| R.B.C.s (n./c.mm.) | 4.3 | 4.2 | — | 3.0 | 3.3 | — |
| Hb. (g. 100 ml.) | 13.5 | 12.3 | — | 9.3 | 10.1 | 10.7 |
| W.B.C.s (n./c.mm.) | 30,000 | 70,000 | 100,000 | 100,000 | 110,000 | 110,000 |
| N. polymorphs (%) | 87 | 81 | 90 | 87 | 90 | 91 |
| Eosinophils (%) | — | 2 | — | — | — | — |
| Band cells (%) | 9 | 5 | 3 | 1 | 4 | 5 |
| N. myelocytes (%) | — | — | — | 1 | 1 | 1 |
| Lymphocytes (%) | 4 | 7 | 3 | 7 | 3 | 3 |
| Monocytes (%) | — | 5 | 4 | 4 | 2 | — |
| Platelet (thousands per c.mm.) (Lempert) | — | 220 | — | 200 | 200 | — |

same histological picture as the primary bronchial carcinoma.

Discussion

Hinshaw *et al.*² have reported a case of severe leukaemoid reaction associated with bronchogenic carcinoma; the leucocyte count reached 144,000 and majority of the cells were mature granulocytes. Several observers have reported leukaemoid blood picture in association with malignancy.^{3, 4, 5} In our patient the diagnosis of leukaemia could not be excluded until the histological examination of the organs at autopsy. Hill *et al.*⁶ have discussed the problem of leukaemoid reactions and have made several useful suggestions in arriving at the correct diagnosis during life.

This case also illustrates the value of angiocardiology in assessing operability of the carcinoma lung.

Summary

A case of carcinoma lung with severe leukaemoid reaction is reported. The absence of leukaemic infiltration in kidney, liver and spleen differentiated the condition from true leukaemia.

Acknowledgments

We are indebted to Dr. Blackburn, the consultant haematologist, for his help and criticism in preparing this paper.

REFERENCES

1. KRUMBHAAR, E. B. (1926), 'Leukaemoid Blood Picture in Various Clinical Conditions,' *Amer. J. Med. Sc.*, **172**, 519.
2. HINSHAW, D. B., and HOXIE, H. J. (1949), 'Leukaemoid Reactions in Carcinoma,' *Calif. Med.*, **71**, 300-301.
3. DOWNEY, H., MAJOR, S. G., and NOBLE, J. F. (1934), 'Leukaemoid Blood Pictures of the Myeloid Type,' *Folia Haematol.*, **8**, 383.
4. MEYER, L. M., and ROTTER, S. D. (1942), 'Leukaemoid Reaction in Malignancy,' *Amer. Clin. Path.*, **12**, 218.
5. KLEEMAN, C. R. (1951), 'Lymphocytic Leukaemoid Reaction Associated with Primary Carcinoma of the Breast,' *Amer. J. Med.*, **10**, 522.
6. HILL, J. M., and DUNCAN, C. N. (1941), 'Leukaemoid Reactions,' *Amer. J. Med. Sc.*, **201**, 847-857.
7. WILKINS, L. (1949), *Pediatrics*, **3**, 533.
8. WILKINS, L. (1950), 'The Diagnosis and Treatment of Endocrine Disorders in Childhood and Adolescence,' Thomas, Springfield.
9. WILKINS, L., LEWIS, R. A., KLEIN, R., GARDNER, L. I., CRIGLER, J. F., ROSEMBERG, E., and MIGEON, C. J. (1951), *J. clin. Endocr.*, **11**, 1.
10. SILVERMAN, S. H., MIGEON, C., ROSEMBERG, E., and WILKINS, L. (1952), *Pediatrics*, **10**, 426.
11. WILKINS, L., GARDNER, L. I., CRIGLER, J. F., SILVERMAN, S. H., and MIGEON, C. J. (1952), *J. clin. Endocr. & Metab.*, **12**, 257.
12. WILKINS, L., CRIGLER, J. F., SILVERMAN, S. H., GARDNER, L. I., and MIGEON, C. J. (1952), *Ibid.*, **12**, 1015.
13. CRIGLER, J. F., SILVERMAN, S. H., and WILKINS, L. (1952), *Pediatrics*, **10**, 397.
14. WILKINS, L. (1952), *J. Pediatrics*, **41**, 86c.
15. GRUMBACH, M. M., VAN WYK, J. J., and WILKINS, L. (1955), *J. clin. Endocr. & Metab.*, **15**, 1161.
16. WILKINS, L., GRUMBACH, M. M., VAN WYK, J. J., SHEPHARD, T. H., and PAPADATOS, C. (1955), *Pediatrics*, **16**, 287.
17. SILVERMAN, S. H., MIGEON, C., ROSEMBERG, E., and WILKINS, L. (1952), *Ibid.*, **10**, 426.
18. WILKINS, L. (1955), Report of 13th M. and R. Pediatric Research Conference.
19. GRUMBACH, M. M., *Ibid.*
20. WILKINS, L., BONGIOVANNI, A. M., CLAYTON, G. W., GRUMBACH, M. M., and VAN WYK, J. (1955), *Ciba Foundation Colloquia on Endocrinology*, Vol. VIII, Churchill, London.
21. JOLLY, H. R. (1950), *Arch. Dis. Childh.*, **25**, 207.
22. JOLLY, H. R. (1951), *Proc. Roy. Soc. Med.*, **44**, 459.
23. JOLLY, H. R. (1955), 'Sexual Precocity,' Thomas, Springfield.
24. GROSS, R. E. (1955), *Pediatrics*, **16**, 303.
25. BONGIOVANNI, A. M., and CLAYTON, G. W. (1954), *Bull. Johns Hopkins Hosp.*, **94**, 180.
26. CARTER, C. O. (1955), in 'Paediatrics for the Practitioner', edited by Gaisford and Lightwood, Butterworth, London.
27. HAMPSON, J. G. (1955), *Bull. Johns Hopkins Hosp.*, **96**, 265.
28. MOORE, K. L., GRAHAM, M. A., and BARR, M. L. (1953), *Surg. Gynec. Obstet.*, **96**, 641.
29. EARR, M. L. (1954), *Ibid.*, **99**, 184.
30. BARR, M. L. (1954), *Lancet*, **1**, 779.
31. BARR, M. L. (1956), *Ibid.*, **1**, 47.
32. DAVIDSON, W. M., and SMITH, D. R. (1954), *Brit. med. J.*, **1**, 1370.
33. MOORE, K. L., and BARR, M. L. (1955), *Lancet*, **ii**, 57.
34. POLANI, P. E., HUNTER, W. F., and LENNOX, B. (1954), *Ibid.*, **2**, 120.
35. WILKINS, L., GRUMBACH, M. M., and VAN WYK, J. J. (1954), *J. clin. Endocr. & Metab.*, **14**, 1270.
36. KLINEFELTER, H. F., REIFENSTEIN, E. C., and ALBRIGHT, F. (1942), *J. clin. Endocr.*, **2**, 615.
37. WILLIAMS, D. I. (1952), *Brit. med. J.*, **1**, 1264.
38. MONEY, J. (1955), *Bull. Johns Hopkins Hosp.*, **96**, 253.
39. MONEY, J., HAMPSON, J. G., and HAMPSON, J. L. (1955), *Ibid.*, **97**, 201.
40. ELLIS, A. (1945), *Psychosomatic Medicine*, **7**, 108.

Continued from page 599—Hugh Jolly, M.D., M.R.C.P., D.C.H.