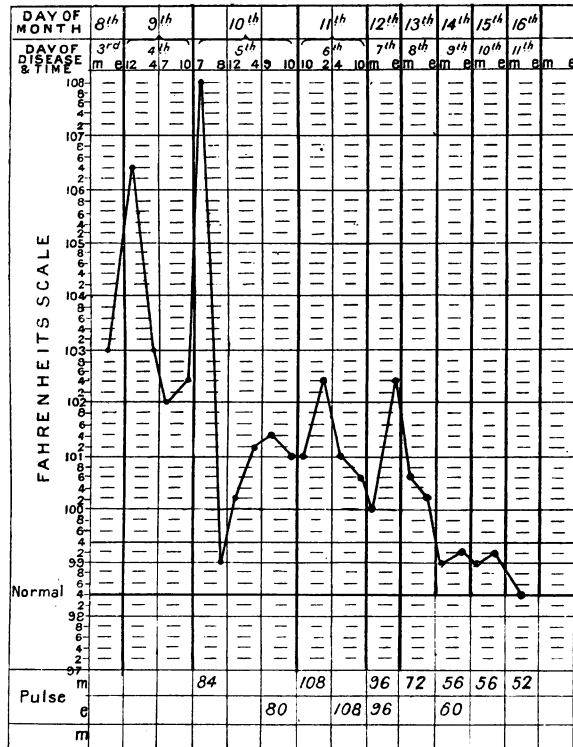


*State on Examination and Treatment.*—I saw him first on April 8th, when he complained of pain in both knee-joints and the right ankle, and they were slightly swollen, but not red. He was sweating a little, and his temperature was  $103^{\circ}$ . I put him on a milk diet, and prescribed 15 grs. of sodium salicylate every hour until its characteristic effects were produced, and thereafter at four-hourly intervals until I saw him again. On April 9th, at 12 noon, I found him delirious and semiconscious, with tremors and a temperature of  $106.4^{\circ}$ . He had taken eight powders before showing the constitutional effects of the salicylate, and has had three others since. No bath being available, I determined on ice-packing to reduce the temperature, but before I had made the necessary arrangements I found that the fever was declining naturally; at 4 P.M. it was  $103^{\circ}$ , and by 7 it had dropped to  $102^{\circ}$ . At this time, except for the deafness and other effects of the salicylate, he was fairly well. He had slept at intervals during the afternoon, and had taken milk well. At 10 P.M. his temperature had risen slightly, and I took the precaution of having plenty of ice at hand in case of necessity.



*Progress.*—April 10th, I was sent for at 7 A.M. by the nurse, who had found his temperature  $108^{\circ}$ . He was again semiconscious and delirious, with tremors and twinges all over his body. I ice-packed him immediately, and in little more than half an hour his mind became quite clear and his temperature came down to  $99^{\circ}$ . He expressed himself as quite comfortable, and the joint pains seemed to have gone. During the rest of the day he kept well, the temperature varying (see chart). At my evening visit I noted a temperature of  $101^{\circ}$ , with no delirium and very little pain in the joints. He was taking the salicylate powders every eight hours, and had consequently lost their disagreeable effects.

April 11th, 11 A.M. Temperature  $101^{\circ}$ , pulse 90, sweating profusely. Had not slept during the night; was somewhat maniacal. The first sound was indistinct at the apex. 2 P.M. Temperature  $102.4^{\circ}$ , pulse 108. 4.30 P.M. Temperature  $100.6^{\circ}$ , pulse 108. Was still wandering in mind, did not know he was in bed; was spitting constantly over the bed and room. The sodium salicylate was stopped and a mixture of potassium iodide and bromide with antipyrin was given instead. 9.30 P.M. Had taken one dose only of his medicine and refused food; he imagined he was being poisoned. He was with difficulty kept in bed, into which he was passing his urine. I injected morphine  $\frac{1}{4}$  gr.

April 12th, 11.30 A.M. Had not slept. Would not lie down, talking constantly, but was somewhat more alive to his surroundings. No pain was complained of unless specially asked for. The right knee was still swollen. The first sound of the heart was slightly muffled; there was no friction or murmur. I found him sleeping at the afternoon visit. 9 P.M. Had slept more or less since 2 in the afternoon; was complaining more of pain in the right knee, and had some pain in the cardiac region; his respiration-rate was 24, mind clear, was taking food again.

April 13th, 11 A.M. Mind quite clear, slept all night, taking food well, no chest pain, no murmur, right knee still swollen, no redness, herpetic eruption on lips; sodium salicylate was begun again at eight-hourly intervals. 9.30 P.M. Very comfortable.

April 14th. Has had a good night, very little pain, bowels moved naturally for the first time since the beginning of his illness, and his temperature almost normal.

April 16th. Convalescent.

April 24th. Although otherwise well, the right knee-joint was still

swollen and painful on movement. Heart sounds normal; skin desquamating very freely.

#### REMARKS.

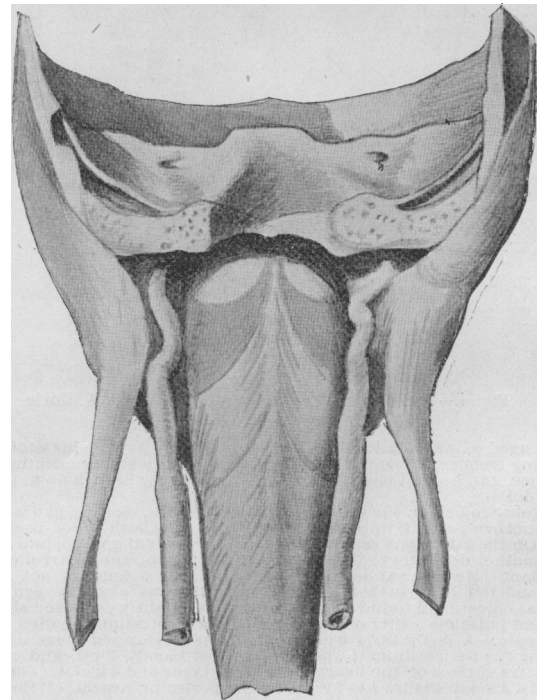
The interest in cases of this character lies chiefly in the question as to whether or not they shed any light upon the causation of hyperpyrexia. I cannot say that there is anything in the facts of this case as I have stated them which does so. It has been noted before that there was an apparent connection between mildness of the arthritic symptoms and this condition, and my case would lend some weight to the observation.

There is a point which does not come out in the report of the case, but may be worth noting. The attack coincided with a marked increase in the number of acute rheumatic cases in this town and district.

### TORTUOSITY OF BOTH INTERNAL CAROTID ARTERIES.

By G. H. EDINGTON, M.D.,  
Glasgow.

THE condition which forms the subject of the present communication was discovered in the course of preparing a dissection of the constrictors of the pharynx. The anterior portion of the base of the skull, including the temporal bones, was removed, along with the soft parts of the neck in front of the prevertebral muscles. On cleaning the surface of the pharynx the abnormal course of the internal carotid artery on either side was observed. The artery arose in the normal way from the common carotid at the level of the upper border of the thyroid cartilage.



On the right side the vessel ran upwards for a distance of 3.5 cm. It then turned sharply forward and slightly inwards for a distance of 1.25 cm., after which it suddenly turned upwards and outwards to the lower opening of the carotid canal. This last portion measured 2 cm. in length (see illustration).

On the left side the first portion of the artery measured 3 cm. in length, and coursed vertically upwards. It then turned abruptly forwards and inwards for 1.5 cm., and again sharply upwards and slightly outwards to the base of the skull, a distance of 2.5 cm.

Previous to the dissection the pharynx had been packed

with cotton wool; and the vessels were in consequence somewhat displaced outwards. Before opening the pharynx, a pin was passed through the second bend of the artery and made to project into the pharyngeal cavity.

A median vertical section of the parts showed that the second bend of the vessel was situated external to the posterior pillar of the fauces at the level of the middle point of the tonsil. From here the horizontal portion of the vessel passed backwards on the lateral wall and then turned downwards. The specimen was obtained from a male subject, aged 34, who was certified as having died from chronic Bright's disease. The common and external carotids were normal in size and position, but the condition of the vessels in other parts of the body was not noted. With the exception of the thyrohyoid, the infrahyoid group of muscles on either side was supplied from the trunk of the vagus; the thyrohyoid received its nerve supply from the hypoglossal, as usual.

With regard to the cause of tortuosity I am unable to speak, but it might perhaps be associated with the arteritis of chronic nephritis. The condition has, as a rule, been found in subjects of an age when tortuosity of the vessels is not uncommon, but its occurrence in a young subject might be explained by abnormal persistence of portions of the embryonic arches.

That the condition noted above is of interest clinically will be seen by referring to a paper, by Dr. Brown Kelly, in the *Glasgow Medical Journal* for January, 1898. Dr. Kelly records four cases in which he had observed large pulsating vessels in the pharynx. His first three observations were all in male patients over 70 years of age, and the pulsation was unilateral. His fourth case was a woman, aged 22, and the condition existed on both sides.

I am indebted to his paper for an account of the literature of the subject, from which it would appear that the bulging of the vessel on the pharyngeal wall takes place behind the posterior pillar of the fauces. As Dr. Kelly points out, a tortuous internal carotid may be a source of danger in performing tonsillotomy, or incising a peritonsillar abscess, or in the removal of adenoid vegetations.

## SUPRARENAL EXTRACT AS A HÆMOSTATIC.\*

By W. THELWALL THOMAS, F.R.C.S.,

Honorary Assistant Surgeon, Royal Infirmary, Liverpool; Assistant Lecturer in Surgery, University College, Liverpool.

In this country the physiological action of suprarenal extract was investigated by Dr. Oliver and Professor Schäfer, and their results recorded in the *Journal of Physiology*.<sup>1</sup> When an intravenous injection was used in dogs and rabbits, an extreme contraction of the arteries was noticed, demonstrated to be of peripheral origin. The effect soon passed off, but could be kept up by repeated small injections. The action of the suprarenal extract is of great physiological importance in maintaining the tonicity of the muscular tissues in general, and especially of the heart and arteries. Therapeutically an extract has been used in a state of solution to construct the small arteries of the conjunctiva before and during operations on the eye, and in the surgery of the nasopharynx. Schäfer has mentioned its usefulness in epistaxis; Harris, of Chicago,<sup>2</sup> uses it to constrict the blood vessels of the mucous membrane and prevent hæmorrhage from the bladder before cystoscopic examination; and Dr. F. Grünbaum<sup>3</sup> recommends it in hæmorrhage from the alimentary canal, bladder, and possibly the uterus, a sterile solution being non-irritating; but he doubts its usefulness in hæmophilia, assuming this condition to be due to congenital hypoplasia of the muscular coats of the arteries. Two cases recently came under my care in which suprarenal extract had the pleasing effect of arresting hæmorrhage when all the ordinary remedies had proved useless.

**CASE I. History.**—The patient was an infant, aged 13 months, who while toddling about a kitchen on November 1st, 1900, stumbled and fell, hitting the upper lip against some heavy furniture, tearing the lip from the upper jaw to the extent of an inch. Bleeding was severe. A medical man attended to it, packing the wound. A few hours later further treatment was necessary, and for the next three days, at periods of twelve

\* Read before the North Wales Branch of the British Medical Association.

hours, the wound had to be cleaned of blood clot and redressed owing to hæmorrhage. Most of the usual applications had been resorted to, still the bleeding recurred.

**State on Examination.**—On November 4th, at 8 P.M., the child was brought to my house by his grandfather, a porter at the infirmary. Blood was trickling out of the mouth; the child's lips were ashy grey, the skin like marble, and the ears almost transparent. He was crying, extremely restless, and profoundly anæmic; a large soft clot protruded from beneath the upper lip. The gauze pack was withdrawn from the wound, and with a good electric light, the patient's head being inverted, an irregular cavity was disclosed, with bleeding walls; two buried catgut sutures checked the hæmorrhage; a gauze pack powdered over with salicylic acid introduced, and a long strip of plaster applied from cheek to cheek, crossing the philtrum of the lip to retain the pack *in situ* and maintain pressure. This seemed satisfactory, and the child was taken home. Early next morning bleeding recurred, and the child was admitted to the Royal Infirmary.

**Treatment.**—The House-Surgeon, Dr. Broad, acting on my instructions, cleaned the cavity and then packed it with gauze impregnated with powdered suprarenal extract, and ordered the administration of 1 gr. of the extract every four hours. No further hæmorrhage occurred. The dressing was changed daily, the general condition of the little patient improved rapidly, and he was sent home on the third day with only a slight granulating line remaining. Two days later the mother brought the child back. A few drops of blood had been seen, but on examination only a few granulation points could be seen, and she was reassured that no harmful bleeding was likely to occur. The child has been quite well since.

**CASE II. History.**—A. T., aged 23, had always bled excessively ever since he could remember on receiving any slight wound; the slightest extra pressure or bruising would immediately be followed by a large blood swelling. Eight years ago, for a period of seven days, he had severe hæmaturia, and again five years ago. Three years ago he was admitted to the infirmary under Mr. Rushton Parker, suffering from a very extensive hæmatoma over the right hip and extending to the popliteal space, the result of twisting himself when jumping on to an omnibus (probably rupturing a few muscular fibres). He remained an in-patient for many weeks and was even now lame from the effects of it. He has a brother 14 years of age who is also a bleeder. Six weeks ago, when working at wood carving as an amateur, a chisel slipped and cut him very slightly over the metacarpo-phalangeal joint of the left index finger towards the palmar side. He bled profusely and went at once to a medical man, who dressed the slight wound by placing a pad of lint wrung out of perchloride of iron on it and covering with a firm bandage. The dressing was kept on for a week; on its removal bleeding occurred, and this happened every time the wound was dressed or the tight bandage slackened.

**State on Examination.**—On December 29th, 1900, he was admitted to the infirmary; he had evidently lost a large quantity of blood, being markedly anæmic, and the pulse feeble. On exposing the wound a watery blood oozed out through and around some soft clot. A tourniquet was applied on the forearm, and the wound, which was cleaned with biniodide of mercury solution, was found to be half an inch in diameter and about the same depth, sloping into the palm. The action of the styptics probably accounted for this increase in size of the original cut.

**Treatment.**—Freshly-powdered suprarenal tablets provided the material to fill the wound with, and a piece of cyanide gauze with some extract powdered into its interstices was bandaged on. Five grains of suprarenal extract were given every four hours, and he was kept in bed. The wound was examined next day, some soft clot washed away, and the dressing renewed, which remained undisturbed for four days, when the now shallow granulating cavity was cleaned out, some blistered epithelium in the vicinity cut away, and a little iodoform added to the extract in the dressing.

On January 4th the dressing consisted of cyanide gauze without "extract," and on the 6th he discontinued taking any. The small granulating area took several more days before becoming soundly healed.

On January 14th he pressed his hand on the back of a chair to assist himself rising, and an extravasation of blood took place into the palmar flexor sheath; he was again ordered gr. v of suprarenal extract every four hours. On the 21st he went home and asked for a prescription to obtain the extract. He was an intelligent young man, a music teacher, and keenly aware of his unfortunate diathesis. After the first dressing on December 29th, although the wound was at that time septic, no further hæmorrhage occurred, and he was so convinced of the value of "the powder" that he intends carrying some in a box in his pocket in case of future emergencies.

The immediate action of the remedy on this patient should encourage a resort to it, notwithstanding any theory as to the pathology of hæmophilia. So impressed was the house-surgeon with the hæmostatic action, that having recently excised a tough, enlarged tonsil from a man aged 24, and the bleeding being too free, he mopped the bleeding area with a piece of sponge freely powdered over with suprarenal extract. The hæmorrhage ceased almost immediately.

### REFERENCES.

- <sup>1</sup> Vol. xvii, p. 9, 1895. <sup>2</sup> *Annals of Surgery*, July, 1900. <sup>3</sup> *BRITISH MEDICAL JOURNAL*, November, 1900.

A NEW CHILDREN'S HOSPITAL IN ST. PETERSBURG.—The foundation of a new children's hospital, intended as a memorial of the Coronation of the Czar and Czarina, has recently been laid in St. Petersburg. The hospital, which is to be built on the pavilion system, will contain 400 beds. The cost, which is estimated at 1,700,000 roubles, will be defrayed by the State.