

# Cardiovascular Effects of Epinephrine Overdose: Case Report

Robert L. Campbell, D.D.S.\*

Drugs that stimulate the sympathetic (adrenergic) nervous system are capable of altering blood pressure, pulse, electrolytes, and blood flow to most organ systems that are under neuro-chemical control. Catecholamines are a class of adrenergic drugs, possessing a basic catechol nucleus (3, 4 dihydroxybenzene), which can either be administered exogenously or secreted endogenously in response to an environmental stress. In a healthy individual endogenous catecholamines such as dopamine, epinephrine, or norepinephrine, are usually released in sufficient amounts to respond to a stressful situation in a self-regulating manner. However, exogenously administered adrenergic drugs require careful titration to achieve the desired effect. Some sympathetic drugs are commonly used subcutaneously or topically to provide local hemostasis. These agents may also be administered intravenously or intramuscularly to increase arterial blood pressure (vasopressor response). The following case report illustrates how severe cardiovascular reactions to excessive amounts of epinephrine can occur at the hands of inexperienced clinicians.

## Case Report

A 14 year old 43 kg female with scoliosis underwent a spinal fusion procedure under general anesthesia in the prone position. After an incision extending from the 4th thoracic to the first lumbar vertebrae, excessive bleeding of the skin flaps prompted the orthopedic surgeon to request the surgical nurse to make a "dilute" epinephrine solution containing one vial of 1:1000 (1 mgm) concentration and four milliliters of water—1:5000 mixture. The use of vasoconstrictors for orthopedic procedures was an unusual request, and the

nurse drew up 5 vials of 1:1000 dilution (5 mgm) of epinephrine in error. The patient had been already anesthetized with a narcotic, muscle relaxant and nitrous oxide technique with a pulse rate of 75-80 beats per minute (BPM) and blood pressure 90/70. Two minutes after the injection of 5 mgm of epinephrine, the blood pressure rose to a peak of 200/160. The patient was immediately ventilated with 100% oxygen and cardiac arrhythmias began to appear.

A normal sinus rhythm of 75-80 bpm changed to sinus tachycardia at 120 bpm with T wave enlargement (fig. 1) when

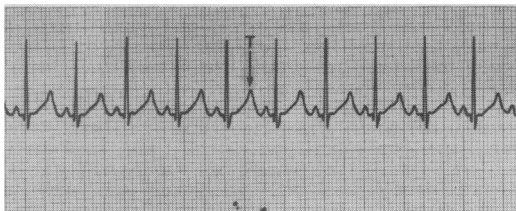


Figure 1.

compared to lead 2 in the pre-operative electrocardiogram. The sinus tachycardia lasted only 6 seconds; and then was rapidly followed by 60 seconds of an idioventricular rhythm with frequent multifocal premature ventricular contractions (PVC's) and ST segment depression (fig. 2). The

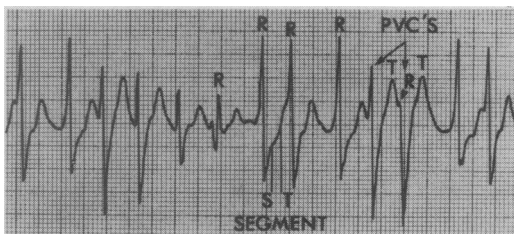


Figure 2.

PVC's are characterized by QRS complexes of varying shapes and sizes. Some occur dangerously close to the previous T wave

\*Associate Professor, Anesthesiology and Oral and Maxillofacial Surgery, Medical College of Virginia.

which could lead to ventricular fibrillation. Sinus tachycardia returned for 30 seconds with left ventricular strain as evidenced by the R smaller than the S wave (fig. 3). A supraventricular tachycardia at a

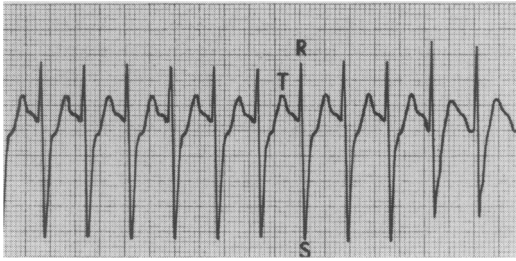


Figure 3.

rate of 200 bpm then developed and lasted for approximately 1 minute. The T waves were still enlarged with ST segment depression and absent P waves (fig. 4). A return to a sinus pacemaker at 120-150 bpm lasted for 10 minutes until the blood pressure returned to pre-operative levels (fig. 5).

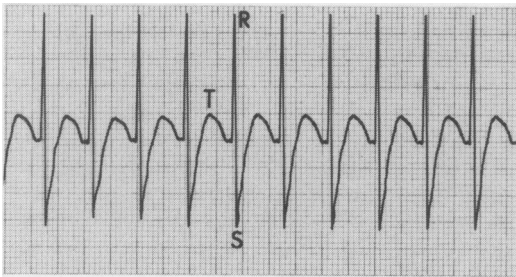


Figure 4.

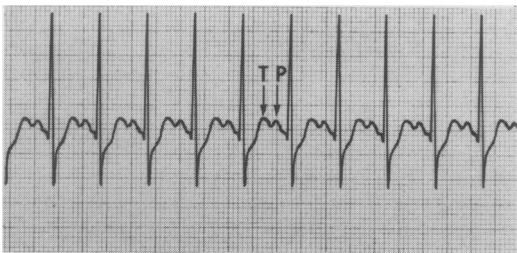


Figure 5.

Arterial blood gas and electrolyte samples drawn 45 minutes after epinephrine injection revealed normal values except the potassium was 2.8 meq/l (normal 4.0-5.5). The surgery was completed without further incident. A 12 lead electrocardiogram and neurological examination in the recovery room did not disclose any residual defects.

## Discussion

Local anesthetics with vasoconstrictors are constantly used in dentistry and the hazards of their administration are extensively taught. However, most clinicians have been confronted with an occasional patient who seems to develop "epinephrine" type reactions even with minimal dosages. A review of the literature seems to indicate that local anesthetic overdose in dentistry is rare.<sup>1</sup> Therefore, it is difficult to accurately document the physiological response to an overdose of epinephrine in a human subject. Fatalities are likely to occur when doses in excess of 4 mgm (4 ml of 1:1000) are used, although a patient has been known to survive 30 mgm intravenously.<sup>1, 2</sup> Aside from the fact that there was an error in communication between the surgeon and the surgical nurse, even a 1:5000 dilution injected into bleeding surfaces may have led to a severe cardiovascular crisis. If the patient had not been anesthetized with cardiovascular depressant drugs such as diazepam, fentanyl and sodium pentothal prior to the epinephrine injection, the hypertension and cardiac arrhythmias which did occur may have been more detrimental to the patient. If general anesthesia with halothane is used, the allowable subcutaneous dose of epinephrine is 1 microgram (.001 mgm) per kilogram of body weight, which can be repeated after 30 minutes<sup>3</sup>. By using general anesthetic agents that are less likely to cause arrhythmias than halothane, greater amounts of vasoconstrictor agents can be used. An adult dose not in excess of 20 ml of 1:100,000 per 10 minute period (.2 mgm) are the present recommendations for hemostasis.<sup>3</sup> The total dose should not exceed 60 ml per hour (.6 mgm).

In addition to the sino-atrial and atrio-ventricular nodes, the heart has other automatic cells that have different thresholds of sensitivity to catecholamines.<sup>4, 5</sup> These extra-nodal automatic cells are responsible for certain cardiac arrhythmias that can occur in response to sufficient amounts of epinephrine (fig. 6). The transient idio-ventricular rhythm (fig. 2) represents aberrant automaticity resulting in varying patterns of widened, slurred, and notched

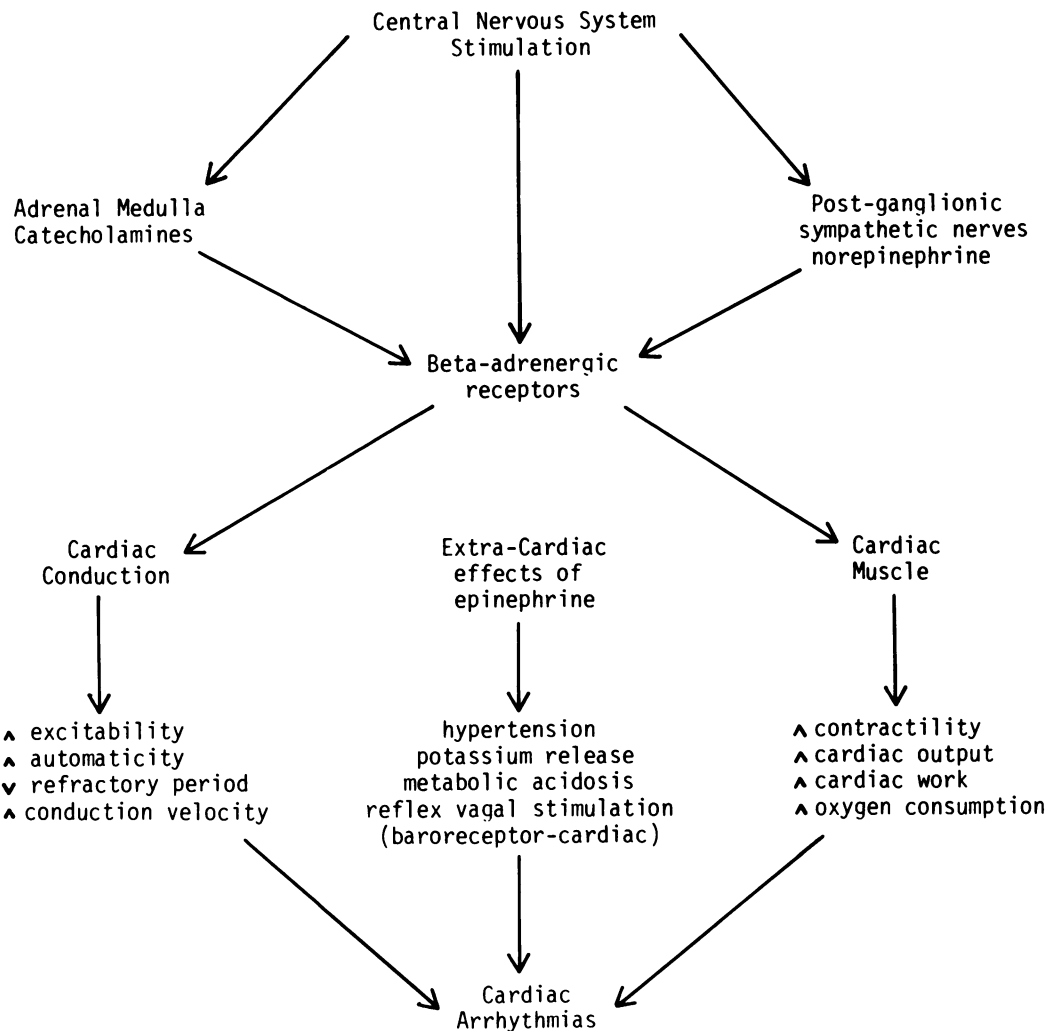


Figure 6.

Extra and intra-cardiac effects of epinephrine overdose leading to cardiac arrhythmias.

QRS waves.<sup>6</sup> Several foci of premature ventricular contractions (multi-focal PVC's) were also present. These are more dangerous than unifocal PVC's because they represent several irritable automatic cells in the heart which could progress to ventricular tachycardia or fibrillation.<sup>7</sup>

The ST segment depression of 5 mm represented myocardial ischemia and oxygen deprivation. The large S waves indicate severe left ventricular strain resulting from the epinephrine and the T wave enlargement is commonly seen with hyperkalemia,

which can occur when potassium is released from the liver in response to epinephrine.<sup>3</sup> However, it is difficult to rationalize a potassium of 2.8 meq/l drawn 45 minutes after the epinephrine crisis, and repeated for verification. There are several causes of hypokalemia—drugs, disease or hyperventilation during anesthesia. An intra-operative arterial blood gas analysis revealed a pH 7.38;  $\text{paCO}_2$  36 torr; and  $\text{paO}_2$  136 torr.\* By comparison, the pre-

\*mm of Hg at standard temperature and gravity.

operative values of pH 7.41 and  $\text{paCO}_2$  39 indicate that the patient was not over-ventilated during surgery. The patient had no known drug intake or disease that could account for the low potassium. Regardless of the cause, hypokalemia will potentiate epinephrine to increase automaticity and could have contributed to cardiac arrhythmia (fig. 6).<sup>5</sup>

The influence of blood pressure may be important in the incidence and severity of arrhythmias. Katz has shown that minimizing the rise in arterial blood pressure during the manipulation of adrenal medullary tumors, the subsequent release of catecholamines reduced the incidence of dangerous arrhythmias.<sup>3</sup> The arrhythmia threshold seems to be higher when blood pressure is controlled. It is likely that an elevation of blood pressure increases the stretching of cardiac muscle resulting in decreasing the amount of epinephrine required to increase automaticity, decreasing resting potential, and increasing the likelihood of multifocal pacemaker activity.

There is a serious risk of ruptured cerebral blood vessels or cardiac failure if the hypertension is protracted. Initially the treatment should be directed toward increasing the oxygenation and decreasing the acidosis of the overworked myocardium. The infusion of increments of thiopental or narcotics may be useful "sympatholytics" until epinephrine which is usually rapidly metabolized by catechol-O-methyl transferase enzyme, can be consumed.<sup>3</sup>

Rapid acting vasodilators (i.e. diazoxide) produce either transient reduction in blood pressure lasting 3-5 minutes, or may last several hours but have no effect on reducing the heart rate. Beta-adrenergic blocking drugs (i.e. propranolol) will reduce heart rate, but usually require slow titration and take 5-10 minutes to produce a response.<sup>4</sup> If the epinephrine is beginning to be metabolized at the same time that the propranolol is taking effect, the danger of severe hypotension should be considered. This drug is to be administered with extreme care and in inexperienced hands should not be considered at all. The supraventricular and sinus tachycardias were transient, but the presence of multi-

focal PVC's could have progressed to ventricular fibrillation. Lidocaine, 1-2 mgm/kgm would be a useful agent not only to treat the tachy-arrhythmia but as a prophylaxis against ventricular arrhythmias.<sup>3</sup> A 50-100 mgm bolus injection is given and followed by a 1 mgm per minute continuous infusion to decrease cardiac automaticity.

### Summary

The pathogenesis and treatment of a patient who accidentally received an overdose of epinephrine is documented. Serial electrocardiograms illustrated several abnormal patterns some of which could have been life threatening. Had the patient been elderly with cardiovascular disease or under halothane general anesthesia, a death could likely have occurred. Since the patient was anesthetized, treatment should consist of increments of intravenous anesthetics or narcotics along with oxygen, ventilation, and lidocaine. Other drugs could be considered acceptable emergency treatment, but the clinician must be aware of the appropriate pharmacophysiology of the interaction of these drugs.

### REFERENCES

1. Verrill P F Adverse reactions to local anaesthetics and vasoconstrictor drugs, *The Practitioner*, 214:380-87, 1975.
2. Davidson S I Systemic effects of eye drops, *Trans Ophthal Soc UK*, 94:487-94, 1974.
3. Katz R L and Epstein R A The interaction of anesthetic agents and adrenergic drugs to produce cardiac arrhythmias, *Anesth* 29:763-84, 1968.
4. Aviado D M Drug action, reaction, and interaction: Iatrogenic cardiopathies, *J Clin Pharm*, 15:641-55, 1975.
5. Hutchison D E Cardiovascular drug interactions, *J Clin Pharm* 15:129-34, 1975.
6. Rollason W N *Electrocardiography for the anaesthetist 3rd Ed.*, J B Lippincott Co Phil, 1975.
7. Vaughan R W Ventricular arrhythmias after topical vasoconstrictor, *Anesth and Analg* 52: 161-5, 1973.

Reprints requests should be sent to Dr. Robert L. Campbell, Dept. of Oral and Maxillofacial Surgery, School of Dentistry, Medical College of Virginia, Richmond, Virginia 23298.