

active bleeding was evident and the findings were consistent with those of a ruptured subcapsular splenic haematoma. Postoperative recovery was uneventful and the patient was discharged on day seven.

Discussion: This case highlights the delay with which an iatrogenic splenic injury can present. The most important indicator in this case, which could relate to splenic injury, was a scar near the splenic region following lung biopsy. Clinical problems after splenic rupture have been classified into three groups characterized by the delay in presentation and type of symptoms⁴. Group one: acute ruptured spleen, Group two: delayed ruptured spleen, and Group three: occult ruptured spleen. Our case was group two, with delayed presentation two months after injury.

Computed tomography is the gold standard for investigating splenic injuries. Grading scales based on computed tomography findings can predict the likelihood of successful non-operative management, which is often possible if the splenic hilum is intact (even when capsular disruption is present)⁵. However, due to haemodynamic instability in this case, percutaneous drainage was not performed. As new cases of diffuse lung disease are being investigated, physicians should be increasingly aware of the possibility of splenic injury after lung biopsy. Splenic injury should be considered if haemodynamic instability occurs even after two months of lung biopsy.

No conflict of interest declared.

*Sana Khan, *General Surgery Senior House Officer*¹

Muhammad I Yousuf, *Vascular Senior House Officer*²

M Bisharat, *Vascular Specialist Registrar*²

Jawed Wali, *Consultant Surgeon*³

¹ Ulster Hospital, Dundonald, United Kingdom,

² Royal Victoria Hospital, Grosvenor Road, Belfast,

³ Causeway Hospital, Coleraine, United Kingdom.

* Flat 1204, Bradbury Court, 10 Jubilee Road, Belfast. BT9 7JL, United Kingdom.

skhannn@hotmail.com

REFERENCES:

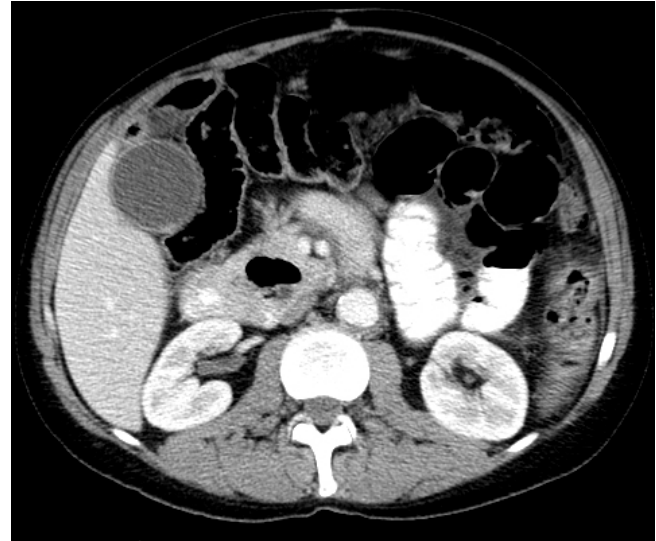
1. Rauch RF, Korobkin M, Silverman PM, Moore AV. CT detection of iatrogenic percutaneous splenic injury. *J Comput Assist Tomogr*. 1983;7(6):1018-21.
2. Rich NM, Lindner HH, Mathewson C Jr. Splenectomy Incidental to Iatrogenic Trauma. *Am J Surg*. 1965;110(8):209-17.
3. Ismail T, McSharry C, Boyd G. Extrinsic allergic alveolitis. *Respirology*. 2006;11(3):262-8
4. Mearns AJ. Iatrogenic rupture of the spleen. *Br Med J*. 1973;17;1(5850):395-6.
5. Williams RA, Black JJ, Sinow RM, Wilson SE. Computed tomography- assisted management of splenic trauma. *Am J Surg*. 1997;174(3):276-9.

CHYLOUS PERITONITIS WITH SMALL BOWEL OBSTRUCTION

Chylous ascites may present with a number of abdominal

complications^{1,2}. We present a case of chylous peritonitis presenting as small bowel obstruction.

Case Report: A 44 year old male presented to the accident and emergency unit with crampy abdominal pain of a two days duration, worse over the previous day. He had a background history of a partial oesophago-gastric resection for Boerhaave's syndrome some months earlier. On examination there was marked abdominal distension with epigastric tenderness. Plain abdominal X-ray showed a large fluid filled loop suggestive of a volvulus. CT scan (fig 1) confirmed a volvulus of the small bowel with a twist of mesentery root and likely venous obstruction.



At laparotomy there was a volvulus around a band from the apex of the anti-mesenteric border of the small bowel to the fourth part of the duodenum. The entire small bowel was dusky with venous engorgement but viable. There was striking engorgement of the lymphatics in the wall of the small bowel and 400ml of milky chylous fluid free in the peritoneal cavity. The patient made an uneventful recovery after surgery.

TABLE I

Causes of Chylous fluid
1. Abdominal surgery
2. Blunt abdominal trauma
3. Malignant neoplasm's - Hepatoma, small bowel lymphoma, Small bowel angiosarcoma, and retroperitoneal lymphoma
4. Spontaneous bacterial peritonitis
5. Cirrhosis - Up to 0.5% of patients with ascites from cirrhosis may have chylous ascites.
6. Pelvic irradiation
7. Peritoneal dialysis
8. Abdominal tuberculosis
9. Carcinoid syndrome
10. Congenital defects of lacteal formation

Discussion: Chylous peritonitis is the extravasation of milky chyle into the peritoneal cavity. This can occur de novo as a result of trauma or obstruction of the lymphatic system. An existing clear ascitic fluid can turn chylous as a secondary event. A true chylous effusion is defined as the presence of

ascitic fluid with high fat (triglyceride) content, usually higher than 110 mg/dL.

Chylous fluid in the peritoneal cavity is a rare clinical condition that occurs as a result of disruption of the abdominal lymphatics. Multiple causes have been described (table I). Congenital chylous ascites is the commonest cause of chyloperitoneum in young children. Other causes in children include idiopathic or obstructive lesions caused by malrotation, intussusception, incarcerated hernia, lymphangioma, blunt trauma, liver disease, and tuberculosis. In children, malrotation and volvulus contribute to chylous ascites³. Volvulus of the midgut may result in several manifestations. Venous and lymphatic obstructions occur first because of lower intravascular pressures. Vascular congestion leads to bowel oedema and possible oozing of blood, causing melaena. Lymphatic congestion causes the formation of a mesenteric cyst and chylous ascites.

Milky ascites is subdivided into three groups: True chylous ascites - Fluid with high triglyceride content, Chyliform ascites - Fluid with a lecithin-globulin complex due to fatty degeneration of cells, and Pseudochylous ascites - Fluid that is milky in appearance due to the presence of pus. Dietary chylomicrons are absorbed in the small intestines and gradually pass along larger omental lymphatics to the cisterna chyli located anterior to the second lumbar vertebra. The cisterna is joined by the descending thoracic, right and left lumbar, and liver lymphatic trunks, and, collectively, these form the thoracic duct, which passes through the aortic hiatus and courses through the right posterior mediastinum and eventually enters the venous system. The thoracic duct carries lymphatic drainage from the entire body, except for the right side of the head and neck, right arm, and right side of thorax. Chylous effusions develop when these channels are injured or obstructed. Abdominal distension is the most common symptom, and rarely, it may present as acute peritonitis.

As chylous peritonitis is a manifestation rather than a disease, the prognosis depends on the treatment of the underlying disease or cause. Few cases presenting as chylous peritonitis are reported in literature

Three cases presenting as acute appendicitis have been reported^{4,5}.

The authors have no conflict of interest.

*Krithika Murugan, *Clinical Fellow*

Prof Roy AJ Spence, *Consultant Surgeon*

Department of General Surgery, Belfast City Hospital Trust, Belfast BT9 7AB, United Kingdom.

krithikam@hotmail.com

REFERENCES:

1. Krizek TJ, Davis JH. Acute chylous peritonitis. *Arch Surg* 1965;**91**:253-62.
2. Madding GF, McLaughlin RF, McLaughlin RF Jr. Acute chylous peritonitis. *Ann Surg* 1958;**147**(3):419-22.
3. Griffith RI, Kanof A. Chylous ascites in infancy: with report of a case with Vitamin A Absorption Studies. *Pediatrics* 1951;**7**(5):632-41.
4. Fazil FM, Khwaja F. Acute chylous peritonitis simulating appendicitis. *Ann Saudi Med* 1999;**19**(3):236-38.

5. Spontaneous chylous peritonitis mimicking acute appendicitis. *World J Gastroenterol.* 2006;**12**(1):154-6,

MESOTHELIOMA – “NOT JUST IN THE CHEST”

Editor,

Malignant deciduoid mesothelioma (MDM) is a rare phenotype of epithelioid mesothelioma, which most commonly occurs in the peritoneal cavity of young females. MDM remains a challenge even to the most astute diagnostician with the differential diagnosis being benign pseudotumoral deciduositis. It carries a dismal prognosis.

Case Report: A previously healthy 31-year-old woman presented with a short history of increasing abdominal girth and shortness of breath without weight loss. She smoked 15 cigarettes per day and had no risk factors for chronic liver disease or prior history of asbestos exposure. There was no family history of neurofibromatosis. Clinical examination revealed ascites in the absence of signs of chronic liver disease, café au lait spots or lymphadenopathy. Diagnostic paracentesis revealed no evidence of bacterial or mycobacterial infection. The serum ascites albumin gradient was 1.1g/dL. Cytology was consistent with benign reactive mesothelial cells although no leucocyte reaction was noted.

Haematological, tumour markers, inflammatory markers and biochemical parameters were in the normal range. A chest radiograph showed no signs of pericarditis, pleural plaques or effusions. Ultrasonographical and CT scanning demonstrated ascites with normal hepatic echotexture and anterograde flow in the portal vein. No thoracic lesions were seen. A diagnostic laparoscopy drained 9L of ascites and numerous small nodules were observed concentrated around the small bowel.

Histological examination of these nodules with conventional stains was consistent with a mesothelial process although it was impossible to differentiate between a benign reactive or neoplastic aetiology. Typical features of epithelioid mesothelioma were not observed. Further expert opinions were sought and immunostaining is shown in Figure 1.

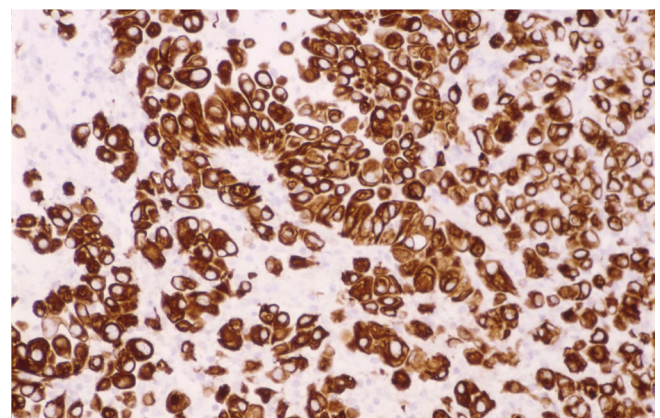


Fig 1. Immunostaining revealed strong positivity for calretinin and cytokeratin which are considered to be sensitive and relatively specific markers for MDM.

These findings were consistent with the diagnosis of MDM. Combination chemotherapy with pemetrexed and cisplatin was initiated but she required multiple hospital admissions