

Published in final edited form as:

J Pediatr Neurol. 2007 ; 5(2): 179–180.

Cerebral arterial gas embolism following cardiopulmonary bypass surgery

Richard E. Frye*

Department of Pediatrics and Neurology, University of Texas Health Science Center, Houston, Texas, USA

A 13-year-old boy with a history of tetralogy of Fallot underwent a pulmonary valve replacement procedure. Gas bubbles were observed in the bypass circuit during the procedure. Trendelenburg position, one of the older standard recommendations when AGE is suspected, was established during the remainder of the procedure [2]. The patient could not support respirations adequately and remained minimally responsive following the procedure. Hyperbaric oxygen therapy was implemented to reduce gas bubble volume and facilitate diffusion of gas back into solution [3]. During the hyperbaric oxygen therapy, the patient experienced three cardiac arrests requiring chest compressions and pressor support. Following the hyperbaric procedure, the patient remained without brainstem reflexes and did not breathe spontaneously. Crepitus was present throughout the abdominal and pelvic areas. The accompanying scan (Fig. 1) was performed six hours after the hyperbaric procedure ended to confirm the diagnosis.

Arterial gas embolism (AGE) is a known complication of underwater diving using compressed air and a rare complication of medical procedures. Iatrogenic causes are more common in procedures that access the arterial circulation, such as cardiopulmonary bypass surgery and angiography, but can also be caused by procedures that access the venous system when accompanied by a cardiovascular defect that results in shunting of blood from the venous to the arterial system [1,2]. Although AGE and the central nervous system complications of AGE have been discussed in the literature, examples of neuroimages associated with central nervous system complications are not well documented. A case is presented to familiarize the neurologist with the conspicuous neuroimaging findings associated with AGE.

Iatrogenic AGE is uncommon, but can occur as a result of pulmonary barotrauma during mechanical ventilation and through direct injection of air into the vascular system [1,2]. Procedures that access the arterial system, such as cardiopulmonary bypass or angiography, can result in injection of air directly into the arterial system. Gas in the venous system can rarely result in AGE when a right-to-left shunt exists. Such shunts are common when an atrial septal defect or patent foramen ovale exists and in congenital cardiac anomalies. Since children are more likely to have untreated congenital cardiac abnormalities and vascular shunts and are at high risk for barotraumas, AGE is an entity with which pediatric specialists should be familiar.

Initial supportive procedures are implemented when AGE occurs. These include administration of 100% oxygen, discontinuation of nitrous oxide and support of vital functions. Although Trendelenburg and lateral decubitus positions have been recommended in the past, since the

*Correspondence: Richard E. Frye, M.D., Ph.D., F.A.A.P., Department of Pediatrics and Neurology, University of Texas Health Science Center, 7000 Fannin St. – UCT 2478, Houston, TX 77098, USA. Tel.: +1 713 500 3245; Fax: +1 713 500 5711; E-mail: drfryemdphd@gmail.com.

buoyancy of gas bubbles is not sufficient to counteract the force of the blood flow towards the head, supine positioning is now recommended [1,2]. In addition, Trendelenburg position can exacerbate cerebral edema [3]. Hyperbaric oxygen treatment or retrograde perfusion can be considered if supportive procedures are not effective [4,5]. A reduction in cerebral metabolism through barbiturate coma, especially when seizures are present, may be effective [1].

Acknowledgements

Dr. Richard Frye was supported by K23 NS046565 from NINDS.

References

1. Muth CM, Shank ES. Gas embolism. *New Engl J Med* 2000;342:476–482. [PubMed: 10675429]
2. Moon RE. Bubbles in the brain: What to do for arterial gas embolism? *Crit Care Med* 2005;33:909–910. [PubMed: 15818131]
3. Benson J, Adkinson C, Collier R. Hyperbaric oxygen therapy of iatrogenic cerebral arterial gas embolism. *Undersea Hyperb Med* 2003;30:117–126. [PubMed: 12964855]
4. Moon RE, Dear GL, Stolp BW. Treatment of decompression illness and iatrogenic gas embolism. *Respir Care Clin North Am* 1999;5:93–135.
5. Sahu MK, Ingole PR, Bisoi AK, Venugopal P. Successful management of a case of massive air embolism from cardiopulmonary bypass with retrograde cerebral perfusion in a child. *J Cardiothorac Vasc Anesth* 2006;20:80–81. [PubMed: 16458220]

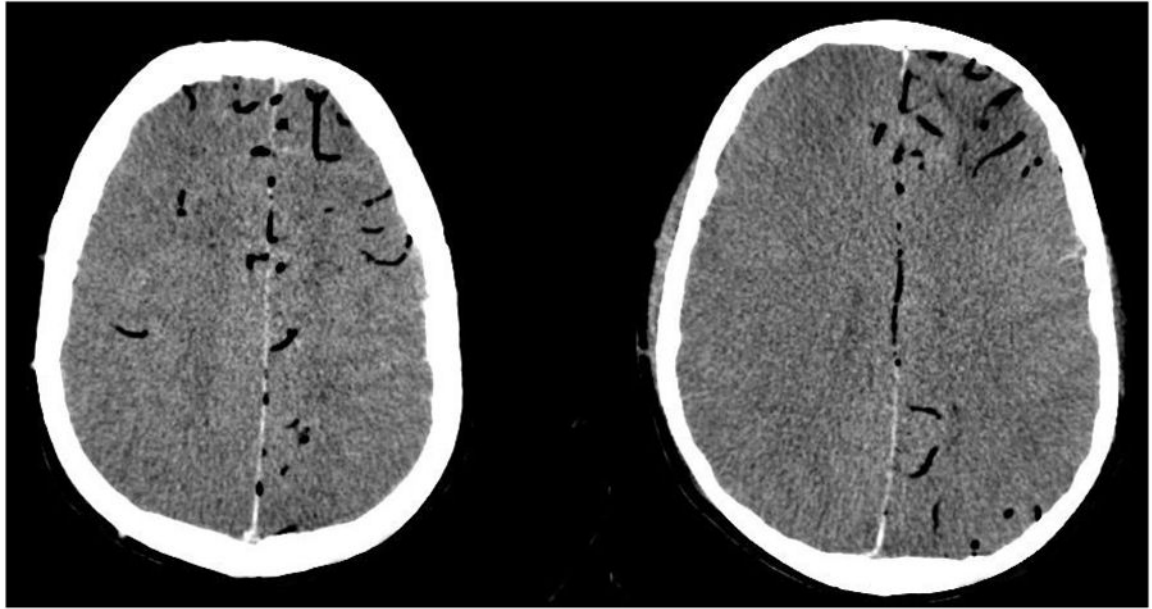


Fig. 1. Computerized tomography scan of the brain after hyperbaric treatment for iatrogenic arterial gas embolism. The white and gray matter differentiation is lost and the sulcal pattern is obliterated. Numerous cortical vessels, especially in the anterior and posterior cerebral artery distributions, are filled with gas. An early left frontal infarct is subtle.