

A case of *Moniliformis moniliformis* (Acanthocephala) infection in Iran

Fariba BERENJI*, Abdolmajid FATA and Zahra HOSSEININEJAD

Department of Parasitology and Mycology, Emam Reza Hospital, Mashhad University of Medical Sciences, Iran

Abstract: Only a few cases of Acanthocephala infections have been reported in humans, and *Moniliformis moniliformis* is the most common species around the world. We report here a case of infection with *M. moniliformis*, which passed in the stool of a 2-year-old girl in Iran. The patient had abdominal pain, diarrhea, vomiting, and facial edema. According to her mother, the patient had habit of eating dirt and once a cockroach was discovered in her mouth. In stool examination, eggs of *M. moniliformis* were not found. She was treated with levamisole and the clinical symptoms reduced within 2 weeks. The specimen contained 2 pieces of a female worm with a total length of 148 mm lacking the posterior end. The spiral musculature of the proboscis receptacle and the shape of the trunk allowed its generic determination. Previously 2 cases of *M. moniliformis* infection were reported in Iran. This is the 3rd case of *M. moniliformis* infection in Iran.

Key words: Acanthocephala, *Moniliformis moniliformis*, beetle, cockroach, Iran

INTRODUCTION

Moniliformis moniliformis is an endoparasite found in the intestine of its definitive host and found in most parts of the world (Ikeh et al., 1992; Roberts and Janovy, 2005). Common definitive hosts include rats, mice, hamsters, dogs, and cats. Humans may be incidental hosts, with the worm in the small intestine. The definitive host is infected by eating the beetle or cockroach (Ikeh et al., 1992).

Human infections with this parasite have been reported in Australia, Asia (Pakistan, Indonesia, Bangladesh, Japan, and Iran), Europe (Russia and Italy), America (Texas, Florida, Alaska, and Honduras), and Africa (Sudan, Nigeria, Egypt, and Madagascar) (Muller, 1975; Beaver et al., 1984; Ikeh et

al., 1992; Baker et al., 2000). In this paper we report a young girl from Taybad (Khorasan-e-razavi province state), Iran, who had a history of eating a cockroach and passed a female *M. moniliformis* worm in her stool.

CASE RECORD

The patient is a 2-year-old girl, who according to her mother's report, passed 6 worms in the stool. The last worm was sent to our laboratory. According to her mother, the patient had habit of pica (eating dirt), and once a cockroach was discovered in her mouth by her mother (Fig. 1). The patient had abdominal pain, diarrhea, and vomiting. Moreover, she had edema in her body and more apparently in the face.

In stool examination, eggs of *Moniliformis moniliformis* were not found, but *Giardia* cysts were detected. CBC (Hb, WBC number, and percentage of

• Received 20 December 2006, accepted after revision 1 May 2007.

*Corresponding author (e-mail: fberenji@yahoo.com)



Fig. 1. The cockroach discovered in the patient's mouth.

eosinophils) was normal. She was treated with levamisole (3 mg/kg/day for 3 days) in lieu of pyrantel pamoate. After the treatment, the patient's clinical symptoms reduced within 2 weeks and there was no more report of passing worms.

Description of the parasite

The submitted specimen contained 2 pieces of a worm with a total length of 148 mm and the posterior end was lost. The spiny head was more or less destroyed, and thus its detailed morphology was not clearly visible. Based on the size (more than 130 mm), this worm was regarded as a female. The worm was white with regular horizontal lines, which imitated segmented appearance. The spiral musculature of the proboscis receptacle and the shape of the trunk allowed its generic and specific determination (Fig. 2).

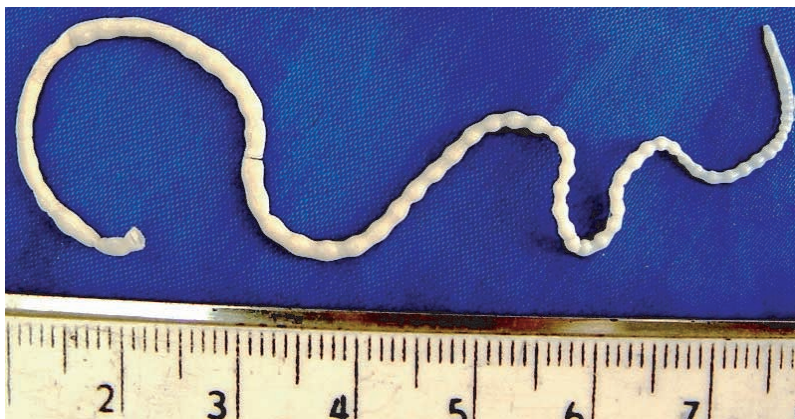


Fig. 2. The specimen contains 2 pieces of a female *Moniliformis moniliformis* with a total length of 148 mm lacking the posterior end, which passed in the stool of the patient.

DISCUSSION

The acanthocephalans (spiny-headed worms) were formerly included in the same phylum as the nematodes (Garcia, 2001). These worms are a small group of pseudocoelomate endoparasites with a number of unique structural and biological features (Marquards et al., 2000). A prominent characteristic of the phylum, from which it receives its name, is a protrusible proboscis that is armed with recurved hooks, by which the worm attaches to the wall of the intestine of the definitive host (Marquards et al., 2000; Garcia, 2001). All members of this phylum are parasites and sexes are separate (Marquards et al., 2000).

Records of Acanthocephala infections in human are rare, but cases of infections by 7 different species have been reported (Roberts and Janovy, 2005). These species include *Acanthocephalus bufonis*, *Corynosoma strumosum*, *Macracanthorhynchua hirudinaceus*, *Moniliformis moniliformis*, *Bolbsoma* sp. (Counselman et al., 1989; Marquards et al., 2000; Roberts and Janovy, 2005), *Macracanthorhynchua ingens* (Counselman et al., 1989; Roberts and Janovy, 2005), and *Acanthocephalus rauschi* (Marquards et al., 2000; Roberts and Janovy, 2005). In these instances, it is probable that the man ate the paratenic host raw (Roberts, and Janovy, 2005).

Moniliformis moniliformis is found in most parts of the world. The male and female worms differ slightly in size with the male averaging 4-13 cm and the females averaging 10-27 cm (Lawlor et al., 1990). The

male has a copulatory bursa (Beaver et al., 1984). Adult worms are white, and because of pitted horizontal lines on the body surface, they appear to be segmented (Beaver et al., 1984; Roberts and Janovy, 2005). The body consists of a proboscis, located on the anterior end of the worm, a neck, and a trunk (Roberts and Janovy, 2005). The cylindrical proboscis is hollowed with a thin muscular wall, and armed with 12-15 rows of recurved hooks, 7-8 hooks to each row (Beaver et al., 1984; Roberts and Janovy, 2005). We regret that the proboscis of our specimen was destroyed and not clearly visible.

Two cases of *M. moniliformis* infection have been reported previously in Iran (Sahba et al., 1970; Moayedi et al., 1971). The first case was an 18-month-old child from a village of Zabol (Sistan-o-Baluchestan province state) in southeast Iran with a history of pica, whose symptoms were abdominal distention, anorexia, weakness, vomiting, and foamy diarrhea. He passed 15 *M. moniliformis* worms after a successful treatment with anthelmintic drugs (Sahba et al., 1970). The second case was a patient from Isfahan in central Iran that was reported by Moayedi et al. (Counselman et al., 1989; Marquards et al., 2000). In the first previously reported case in Iran, laboratory findings included leukocytosis ($16,000/\text{mm}^3$) with high eosinophilia (24%) (Marquards et al., 2000), but in our case all laboratory findings were normal.

The symptoms of *M. moniliformis* infection often include abdominal pain, vomiting, severe fatigue, diarrhea, dizziness, irritability, anorexia, pallor, weight loss, weakness, somnolence, tinnitus, cough, jaundice, protuberant abdomen, retarded development in children, fever, and intermittent burning sensations around the umbilicus (Beaver et al., 1984; Counselman et al., 1989; Ikeh et al., 1992; Marquards et al., 2000; Roberts and Janovy, 2005). In our case, according to the patient's mother, the child complained of loss of appetite and abdominal pain. Moreover, the patient has edema especially in her face. However, the presence of *Giardia* cysts in her stool may have contributed to these symptoms.

The presence of 12-15 rows on the proboscis with 7-8 spines on each row is the main characteristic of this

species (Roberts and Janovy, 2005). In the definitive hosts damage to intestinal mucosa may occur by penetration of proboscis, and is compounded by the worm's tendency to release their hold occasionally and reattach at another place. These damages may cause inflammation, ulcer, and hemorrhages in the definitive host (Marquards et al., 2000; Garcia, 2001; Roberts and Janovy, 2005).

When infected with *M. moniliformis*, most cockroach species move more slowly, and travel shorter distances (Moore et al., 1994; Libersat and Moore, 2000; Roberts and Janovy, 2005). This increases the likelihood of parasite's predation by the definitive host (Libersat et al., 2000).

Due to people's main occupation in this village (Khiyaban), which is animal husbandry, and poor health, lower socioeconomic condition, as well as abundance of the intermediate host of *M. moniliformis*, we believe that the infection may exist in other people, specially the kids of this rural area. Health education for the families particularly mothers to promote better hygiene and prevention of pica is an important preventive method.

REFERENCES

- Beaver PC, Jung RC, Cupp EW (1984) Clinical Parasitology. 9th ed. pp 544-547, Lea & Febiger, Philadelphia, USA.
- Counselman K, Field C, Lea G, Nickol B, Neafie R (1989) *Moniliformis moniliformis* from a child in Florida. *Am J Trop Med Hyg* **41**: 88-90.
- Garcia LS (2001) Diagnostics Medical Parasitology. 4th ed. pp 477-501, ASM press, Washington D.C., USA.
- Ikeh Z, Anosike J, Okon E (1992) Acanthocephalan infection in man in northern Nigeria. *J Helminthol* **66**: 241-242.
- Lawlor B, Read A, Keymer A, Parveen G, Crompton D (1990) Non-random mating in a parasitic worm: mate choice by males? *Anim Behav* **40**: 870-876.
- Libersat F, Moore J (2000) The parasite *Moniliformis moniliformis* alters the escape response of its cockroach host *Periplaneta americana*. *J Insect Behav* **13**: 103-110.
- Marquards WC, Demaree RS, Grieve RB (2000) Parasitology and Vector Biology. 2nd ed. pp 491-499, Harcourt academic Press, San Diego, USA.
- Moayedi B, Izadi M, Maleki M, Ghadirian E (1971) Human infection with *Moniliformis moniliformis* (Bremser, 1811)

- Travassos, 1915 (syn. *Moniliformis dubius*). Report of a case in Isfahan, Iran. *Am J Trop Med Hyg* **20**: 445-448.
- Moore J, Freehling M, Gotelli NJ (1994) Altered behavior in two species of blattid cockroaches infected with *Moniliformis moniliformis* (Acanthocephala). *J Parasitol* **80**: 220-223.
- Muller R (1975) Worm and Disease, a Manual of Medical Helminthology. 1st ed. pp 64, William Heinemann Medical Book Ltd, London, UK.
- Roberts L, Janovy JR (2005) Foundation of Parasitology. 7th ed. pp 493-509, McGraw-Hill, Boston, USA.
- Sahba GH, Arfaa F, Rastegar M (1970) Human infection with *Moniliformis dubius* (Meyer, 1931) in Iran. *Trans Roy Soc Trop Med Hyg* **64**: 284-286.
- Taraschewski H (2000) Host-parasite interaction in Acanthocephala: a morphological approach. *In* Advances in parasitology, Baker JR, Muller R and Rollinson D (eds.). pp 1-179, Academic Press, USA.