

AN OUTLINE OF SOME OF THE MEDICAL USES OF THE RÖNTGEN LIGHT.

By FRANCIS H. WILLIAMS, M.D.,
BOSTON.

MR. PRESIDENT AND GENTLEMEN: In accepting the cordial invitation of your President to read at this meeting, I intended to limit my paper to one disease—pulmonary tuberculosis—but at the very kind suggestion of the President I shall present, instead, a general statement of the medical applications of the x-rays, as being of more interest at this time, and give the results of the clinical observations made in some of my patients, in order to suggest ways in which an x-ray examination may corroborate other evidence or assist us to an earlier or to a more correct diagnosis.

In a general way, x-ray examinations may be said to have thus far been most used to detect foreign bodies, or changes in shape and composition of bones, as in fractures, dislocations, necrosis, tuberculosis, osteosarcoma, deformed pelvis, rickets, and osteomalacia.

Gouty deposits about the joints, as shown by Dr. Arthur L. Fisk, are distinguished from rheumatoid arthritis by means of an x-ray photograph.


In the abdomen the outline of the spleen, the left kidney and the liver may, under favorable conditions, be seen in the fluoroscope.

The stomach may be examined by giving the patient a large dose of subnitrate of bismuth (which the x-rays do not easily traverse) with food, and then looking at the shadow of its contents by means of the fluoroscope (Fig. 1). I have also taken in this way an x-ray photograph of the stomach contents.

Carcinoma. In all the cases of carcinoma of the stomach that I have examined with the fluoroscope, if the growth could be

seen with this instrument it could be felt. I have taken one x-ray photograph of a carcinoma in the stomach, and its thickest portion, as shown at the operation, corresponded to a dark area shown in the photograph and seen in the fluoroscope.

FIG. 1.



Tracing made by means of the fluoroscope from a girl seven years old, showing the outline of the stomach one hour after a meal of bread and milk containing subnitrate of bismuth. The full horizontal line is at the level of the iliac crests; the full lines at right angles to it are the outlines of the body; the other full lines indicate the position of portions of the diaphragm, heart, and stomach during full inspiration. Broken lines show position in expiration. One-half its original size.

Mr. W. B. Cannon, a student in the Harvard Medical School, who has published an excellent article on the movements of the stomach in the cat, as seen by the Röntgen rays, has made, with me, some observations on the size and shape of the stomach in human beings during digestion, which are as yet unpublished.

In *ascites* the surface of the ascitic fluid may be seen in the fluoroscope if the patient is examined lying on his back and

the physician is looking through the body transversely. In the abdominal cavity new growths may sometimes be seen from this same point of view.

Renal or vesical calculi of fair size containing phosphate or oxalate of calcium have been detected by an x-ray photograph. X-ray examinations may be used in other diseases or conditions of the abdomen and pelvis, but I will not discuss them here.

One of their most useful applications is for diseases in or contiguous to the thoracic cavity. I shall consider this subject largely from the stand-point of a practitioner whose special interest is diseases of the chest, for it was the confidence which I had in the possibilities of the fluoroscope to assist in the diagnosis of diseases of the lungs and heart that led me to begin and develop this method of examination.

I think the subject can be most clearly presented by the following cuts (Figs. 2 to 15), that are reduced copies of diagrams which were made by transferring outlines, that I drew on the skin of patients while looking through the fluoroscope, to a skeleton outline copied from one of Luschka's plates. These patients were examined lying down, except the one suffering from pneumohydrothorax.

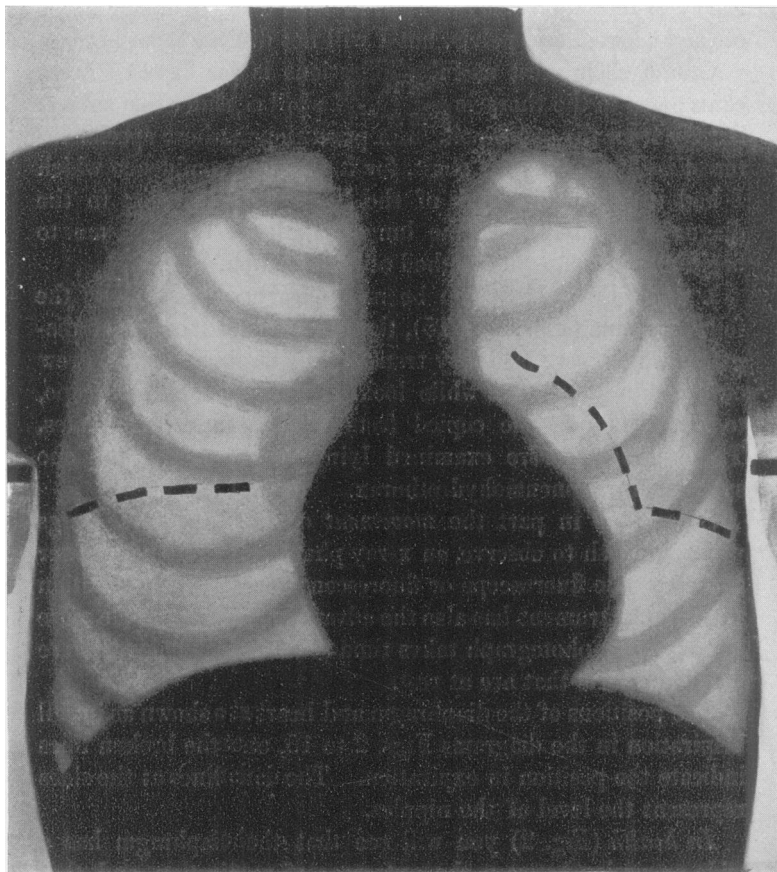
Since it is in part the *movement* of the heart and lungs which we wish to observe, an x-ray photograph does not answer as well as the fluoroscope or fluorescent screen. Examination with this instrument has also the advantage of being made more quickly; the photograph takes time to develop, but gives more details in parts that are at rest.

The positions of the diaphragm and heart are shown as in full inspiration in the diagrams Figs. 2 to 15, and the broken lines indicate the position in expiration. The dark lines at the sides represent the level of the nipples.

In health (Fig. 2) you will see that the diaphragm has a wide excursion between the extremes of respiration, and that the heart also changes its place. In order that you may appreciate what nice distinctions the fluoroscope is capable of making, let me state that the difference in the brightness of the lung-area between expiration and full inspiration may be

perceived in the fluoroscope. In health the lungs are seen to be lighter about full inspiration and darker in expiration, as they then contain more blood per cubic inch. This shows how

FIG. 2.

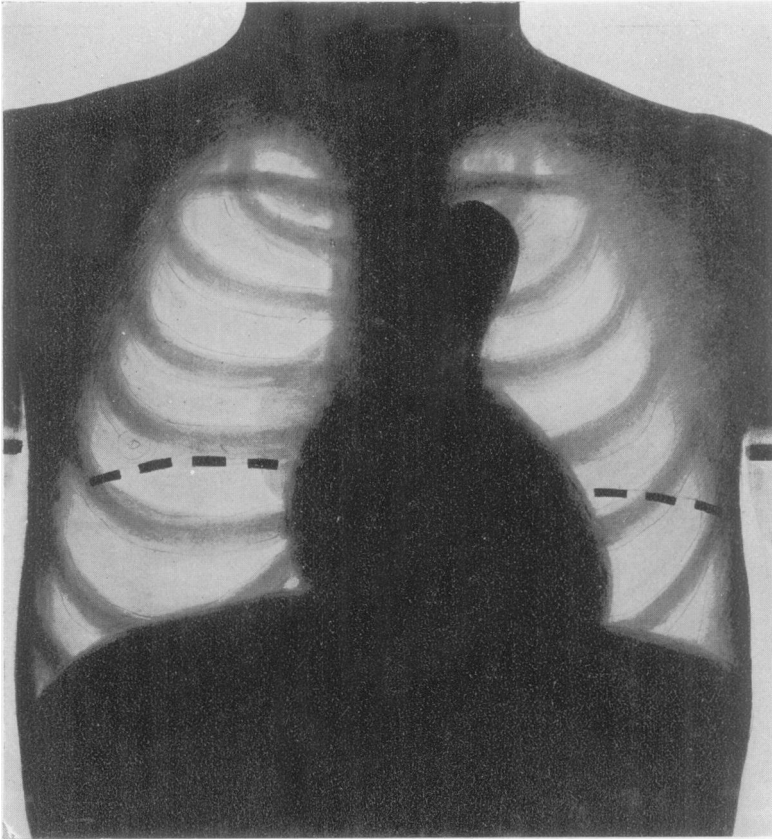


FULL INSPIRATION DURING HEALTH.

The broken lines show the position of the diaphragm and heart in expiration, but the diagram does not indicate that during this time the light area is narrower. The anode of the Crookes tube in Figs. 2 to 15 inclusive, except in Fig. 12, was placed under the median line, where it is crossed by a line joining the nipples. The tube should be two feet or more away from the patient.

conditions involving congestion, as in early tuberculosis or in some forms of cardiac disease, may alter the appearances in the fluoroscope.

FIG. 3.



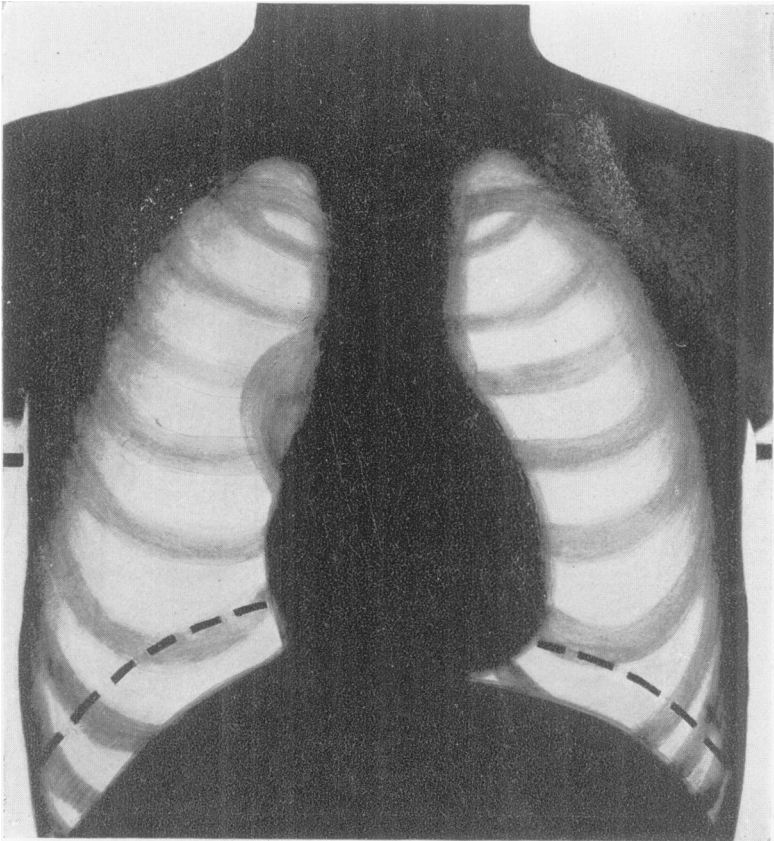
ANEURISM OF THE DESCENDING AORTA.

Broken lines show position of diaphragm in expiration; a dilatation of the ascending portion of the aorta would cast a shadow on the right side of the sternum.

The diagram of health (Fig. 2) is the key to the others, and I shall ask you to use it as a starting-point in studying them. Please compare individually the diagram of each of the diseases

as I take them up with the diagram of health, especially the amplitude of the excursion of the diaphragm and its position in the thorax in certain of them. Usually the excursion of the

FIG. 4.

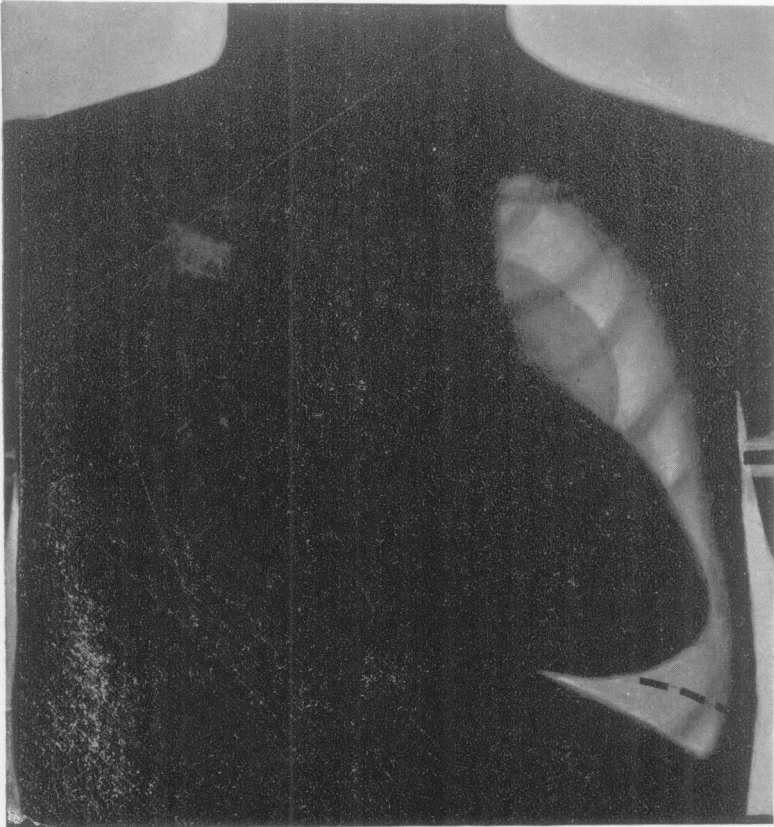

EMPHYSEMA OF BOTH LUNGS IN FULL INSPIRATION.
Broken lines show position of diaphragm in expiration.

diaphragm on the left side is about two and one-half inches, and generally rather more on the right side ; but the excursion

varies with the size of the individual and the shape of the chest. Likewise conditions present in the abdominal cavity may sometimes change the extent and shape of the outline.

FIG. 5.



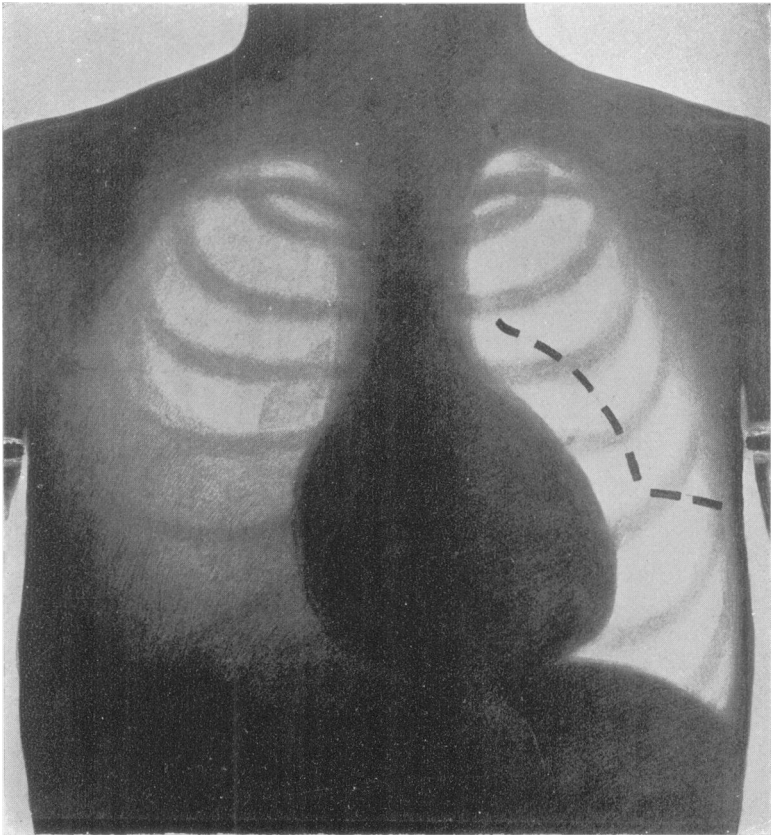
PLEURISY, WITH LARGE EFFUSION.
Broken lines show position in expiration

We will begin with *thoracic aneurism*.

Many thoracic aneurisms (Fig. 3) which were formerly beyond our reach for diagnosis may now be recognized with

certainly, and, further, symptoms due to aneurism are sometimes ascribed to other diseases, and an x-ray examination is required to establish the diagnosis. This diagram represents

FIG. 6.



PLEURISY, WITH SMALL EFFUSION.

the condition found in a patient sent to me in consultation who had a stricture of the oesophagus, and into whose throat an oesophageal bougie had been passed every third day for months.

Another patient, who had a similar aneurism, was thought to have intercostal neuralgia, and had been operated on for this previous to coming to me. In one of my own patients with cardiac disease I was about to give digitalis, but an x-ray examination showed the presence of a thoracic aneurism in an early stage, and I was thus spared from doing him harm. In no other way than by an x-ray examination could these aneurisms have been detected in this early stage.

In emphysema (Fig. 4) you will observe that the excursion of the diaphragm is less than in health, and that it is lower in the chest. The heart is in a more vertical position than in health, and moves less between full inspiration and expiration. In marked cases the right side of the heart, both auricle and ventricle, is larger than normal, and in some cases both sides are enlarged.

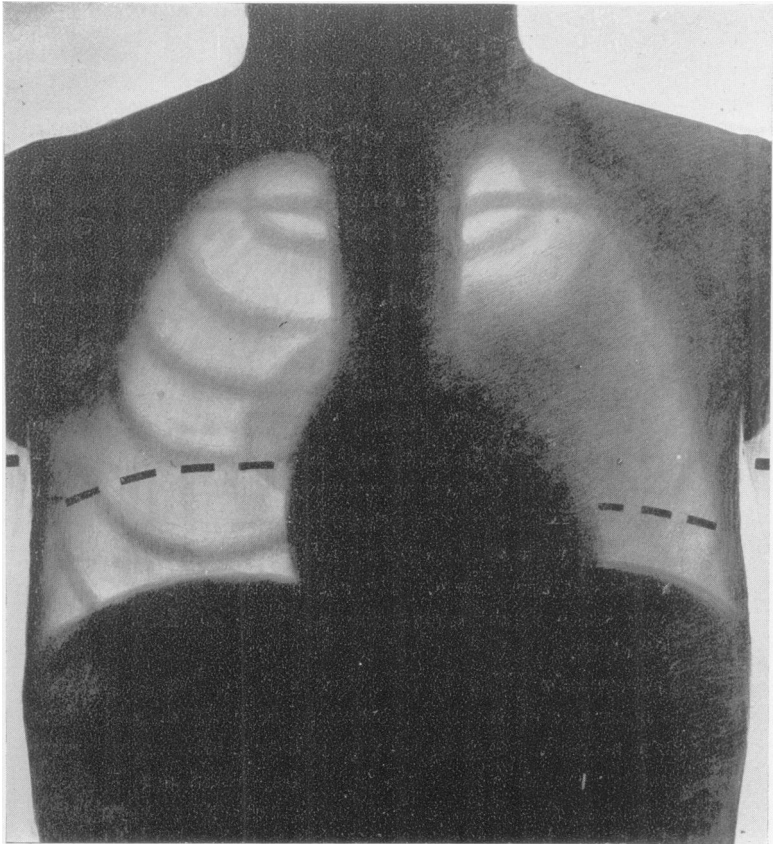
In pleurisy with large effusion (Fig. 5) the heart is much displaced, as indicated by the diagram. I removed a gallon of fluid from this patient's chest. The heart was then seen to be nearer its normal position, and the excursion of the diaphragm on the left side was greater in amplitude and went higher up in the chest—that is, was nearer the normal.

In pleurisy with slight effusion (Fig. 6) the appearances in another patient are shown. By auscultation and percussion there was some doubt about the presence of fluid in this patient's chest.

In pneumonia (Fig. 7) the dark area of the pneumonic process is seen, and, further, the excursion of the diaphragm is less than normal. The appearances in pneumonia are very conspicuous; so much so that I have not chosen a patient in the most active stage of the disease, but rather during its subsidence. This diagram was made from the appearances on the seventeenth day of the disease. No signs were found by auscultation and percussion on this day. This shows that there may be conditions in the chest which are readily seen in the fluoroscope, but which are not patent to auscultation and percussion. On the thirty-second day signs of disease were still seen by the fluoroscope, but the patient was then discharged;

otherwise, an abnormal condition of the lungs might have been followed by means of this instrument for some time longer. In

FIG. 7.



PNEUMONIA. Seventeenth day of disease.

Dark area and restricted movement of the diaphragm on the left side; the movement is also less than normal on the right side. The dark area diminished gradually, and the excursion of the diaphragm on both sides increased from week to week.

cases that I have examined after their discharge from the hospital the lungs attained their normal brightness before the excursion of the diaphragm was normal.

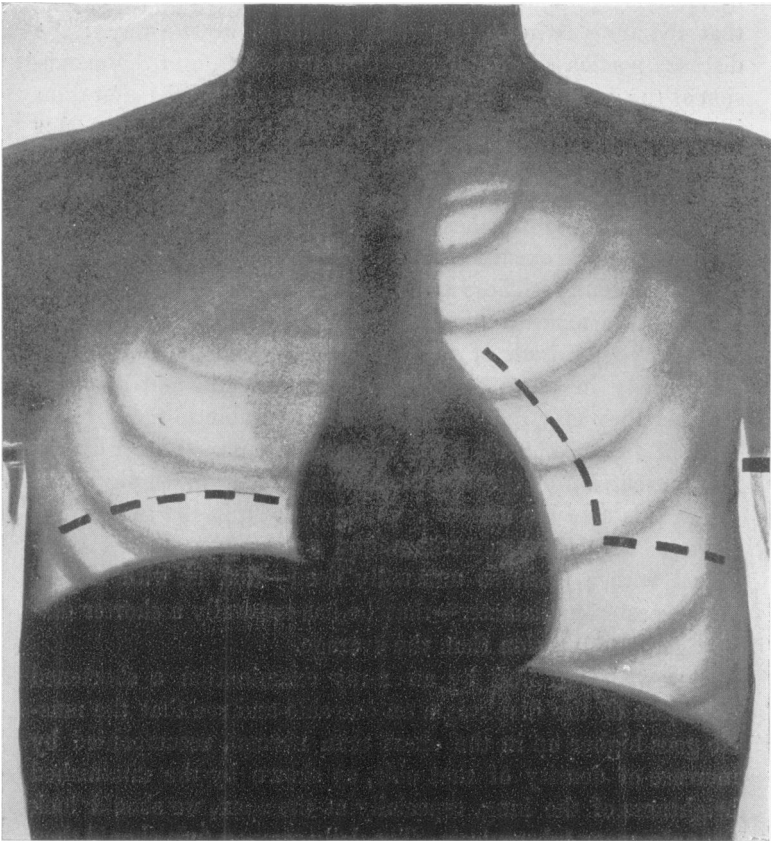
Central Pneumonia. I have recognized the presence of central pneumonia with the fluoroscope before there were any signs by auscultation and percussion.

Pulmonary Tuberculosis. It seems hardly necessary to state that the diagnosis of pulmonary tuberculosis is not made by an x-ray examination alone, but the fluoroscope may show that the lung is in an abnormal condition in two ways: the diseased portion appears darker than in health, and the excursion of the diaphragm in quiet breathing and in full inspiration is restricted, usually on one side in early tuberculosis, and this muscle often goes higher up in the thorax than normal on this side. (The average movement of the diaphragm in the nipple line in health is $2\frac{1}{2}$ to 3 inches in men; it usually goes up higher in the chest, and its excursion is generally greater on the right than on the left side.) These signs lead us to suspect tuberculosis. It is well to make a second examination after an interval of a few days, for both of these signs may sometimes be found temporarily in other conditions, as in anæmia and debility; whether they may then indicate a soil favorable to the development of tubercle bacilli I will not now discuss. Also a diminished excursion of the diaphragm may occur in emphysema; but in this case the muscle goes lower down in the thorax, not higher. Again, we sometimes find a perfectly healthy individual with a chest so unusually deep—that is, with a long antero-posterior diameter—that he has naturally a shorter diaphragmatic excursion than the average.

But when we find by an x-ray examination a shortened excursion of the diaphragm on one side and see that the muscle goes higher up in the chest than normal, accompanied by increase of density of that side, as shown by the diminished brightness of the lung, especially at the apex, we should look for pulmonary tuberculosis. The daily temperature should then be noted and the tuberculin test used. By means of the fluoroscope and the tuberculin test an early diagnosis may be made without waiting for well-defined physical signs, the appearance of cough or the finding of tubercle bacilli; and this is of importance, for delay may deprive the patient of his best

opportunity for recovery. The x-ray examination may give the first warning of tuberculosis, or, if this disease has been already suspected for other reasons, it may add strong supporting

FIG. 8.



PULMONARY TUBERCULOSIS. Right side.

The excursion of the diaphragm is restricted, and restricted to the upper part of its excursion in this disease. In emphysema the movement is restricted to the lower side. In tuberculosis it may be higher in the thorax than in health, in emphysema lower.

In the diagram the apex is darker, and the excursion of the diaphragm is more restricted than in the very early stage of the disease.

evidence. I have taken every opportunity to examine patients with tuberculosis in the early stage, and have usually found the evidences of disease more marked in the fluoroscope than by auscultation and percussion. (When the disease has made some progress the appearances in the fluoroscope are, of course, very conspicuous.)

Further, I have found suggestion of tuberculosis in several patients when auscultation and percussion had not revealed it, whom I examined by the fluoroscope with reference to some other disease. This diagnosis was confirmed by the subsequent development of the case, the presence of bacilli, or by reaction to the tuberculin test.

The dark areas which are found in the lungs in pulmonary tuberculosis are not wholly due, I think, to a consolidation, for a marked congestion may give rise to similar appearances. In some patients, whom I have examined at intervals of a week or two, I have seen these dark areas extend rapidly, and in others diminish in the same way, and as it does not seem probable that other changes in the lung would take place so quickly as the increase and decrease of these dark areas would suggest, a congestion seems to be the natural interpretation of this relatively rapid alteration in the brightness of the lung. Further, in passive congestion or oedema of the lungs in mitral disease the lower portions of these organs may be darker than normal without corresponding physical signs, and, after rest and the administration of digitalis, the lungs soon become clear.¹ Also in patients apparently suffering from debility, and who do not react to tuberculin, we may find a dark area in the lung that clears up after a rest of a week or two. But the recognition of a congestion, especially at the apex, may be valuable in some cases, as an early warning of the beginning of tubercu-

¹ I examined normal lungs, after they were taken from the body, with the fluoroscope, and found they were penetrated by the x-rays with the greatest ease; there was no marked difference in brightness between a fully and a partially distended lung. In life the lungs are brighter during full inspiration than expiration. This greater brightness is due to a diminished amount of blood in an equal volume of lung at this time. These observations, together with others bearing on this subject, are referred to in my article entitled "A Study of the Adaptation of X-rays to Medical Practice," Med. and Surg. Report, Boston City Hospital, January, 1897.

losis, and it should certainly cause us to make a careful investigation with this diagnosis in mind. And in those cases in which our suspicions are excited by a first examination a second should be made to confirm or disprove the first.

In pulmonary tuberculosis the x-ray examination may assist us, first, to make an early diagnosis; second, to estimate the extent of the disease; third, to determine whether it is disseminated or localized; fourth, to recognize a cavity; and in all these cases helps us to decide on the wisest course for the patient to pursue. I wish to emphasize the importance of its first use, for if pulmonary tuberculosis is promptly recognized a considerable proportion of cases can be cured, and cured without change of climate if the patient is able to follow out hygienic treatment intelligently in suitable surroundings. In more advanced cases the knowledge gained by means of an x-ray examination may prevent the patient from being sent on a fruitless and expensive journey in search of health when he should remain at or near his home. I have seen patients who were sent away when a journey was distinctly contraindicated by an x-ray examination, and the result proved the correctness of the indication.

As the x-ray examinations in pulmonary tuberculosis come more into use I am convinced we shall sometimes recognize its presence earlier, and be less apt to overlook the disease in its beginning.

The following cases are chosen to illustrate some of the ways in which x-ray examinations may be useful in pulmonary tuberculosis.

In the first patient the signs in the fluoroscope were more marked than were the physical signs.

CASE I.—Lawrence C., twenty-eight years of age, entered the Boston City Hospital, April 14, 1898. Mother died of phthisis; history of several hæmoptyses. On March 31st, coughed up blood several times; says he lost about a pint.

April 14. Physical examination: Harsh respiration over both fronts, otherwise no physical signs.

X-ray examination: Marked darkness over upper two-

thirds of left chest. Excursion of diaphragm one and one-half inches on left side; two inches on right side. The normal excursion, as already stated, is about $2\frac{1}{2}$ to 3 inches, the right side usually moves rather more than the left.

17th. Physical examination: Respiratory sounds less pronounced than normal on both sides, otherwise no physical signs.

19th. No change in signs by auscultation and percussion. *Second x-ray examination*: Similar to that made on April 14th, but more marked.

The patient was given one-half milligramme of tuberculin, and reacted to it, the temperature rising to 102.4° in eighteen hours.

CASE II.—George S. B., teacher, thirty-two years of age. Lost his mother and one brother by tuberculosis. Hæmoptysis, June 5, 1897. In Dr. Folsom's service in Boston City Hospital for ten days. Nothing found in his chest. Subsequently, to June, had several slight hemorrhages. In July, Dr. Smithwick found a few small râles above the right clavicle.

September 17. Dr. Smithwick found no râles at right apex, but thought he found a few in the right axilla; otherwise, there were no physical signs. Said "the patient might be examined to-day without any signs of tuberculosis being detected;" no rise in temperature; no tubercle bacilli found, though the sputa have been examined several times. Dr. Smithwick brought the patient to see me on September 17th.

17th. *X-ray examination*: Right apex to lower border of second rib was darker than the left apex. Excursion of the diaphragm on right side one and three-eighths inches; on left side, two and three-eighths inches. This, together with what had gone before, led me to state that I had little doubt the patient had tuberculosis.

October 3. Dr. Smithwick found tubercle bacilli.

Bacilli had been found in the following patient (Case III.) just before the x-ray examination was made, but it is of interest to compare the signs found in the fluoroscope with those by auscultation and percussion. This patient had been at the

Boston City Hospital, under the careful observation of Drs. Buckingham, Withington, or Jackson for some months.

CASE III.—B. C., twenty-nine years of age, male nurse in the Boston City Hospital. Patient in Dr. Withington's service. Admitted May 11, 1898. For past two months the patient has had cough with yellowish expectoration; about one week ago the sputum was streaked with blood. Slight dyspnoea after exertion. The patient thinks he has not lost weight or strength. No chilly sensation; no sweating; appetite fair.

May 11. Physical examination: Heart not enlarged to the right or upward; apex in fifth space in nipple line; action regular; lungs normal, save that breathing is somewhat jerky in places, and fremitus is slightly increased all over right chest. Rest of physical examination was normal.

12th. Few râles at inner edge of left scapula; no difference in fremitus or in voice.

14th. An occasional indeterminate râle here and there over the chest, not permanent in character; no abnormality in breathing or voice; resonance good.

15th. Breathing very little modified qualitatively. Occasionally râles as before, and after cough they are more numerous in right axilla than elsewhere. Tubercle bacilli found in sputum.

16th. *X-ray examination:* Whole of the right lung darker than the left, especially at base. Excursion of diaphragm on right side seven-eighths of an inch; on left side, two and five-eighths inches.

August 22. Dulness at both apices and moist, bubbling râles; moist râles also present in both axillæ. Right apex, bronchial breathing, with increased resonance and fremitus. Process is diffuse in both lungs, but most marked in the right.

X-ray examination: Right side much darker throughout than the left. Excursion of the diaphragm one-fourth of an inch on the right side and three-fourths of an inch on the left side.

The fluoroscope afforded evidence of tuberculosis in the following case, where the physical signs were not conclusive:

CASE IV.—Murdock M., carpenter, twenty-three years of age, an out-patient of the Boston City Hospital, September 17, 1896. History of two hemorrhages: one four years ago and one a year ago. Now complains of pain in the right chest, with slight cough and slight expectoration. Physical examination by Dr. Ames was negative, except for a few "clicks" at the junction of the second rib and the sternum on the right side and at left apex behind.

September 17. The patient was brought to me for an *x-ray examination*, which was as follows: Two-thirds of right lung, beginning at apex, darker than normal, as well as apex of left lung. Excursion of diaphragm shorter and higher up than normal on the right side.

October 3. Physical examination by Dr. Tenney: Slight dulness at *left* apex, back and front, with harsh respiration and increased voice sounds. It was learned at this time that the father and three brothers had died of phthisis.

Two examinations for tubercle bacilli had been made with negative results.

CASE V.—H. C., twenty-six years of age, entered the hospital January 24, 1898, in Dr. Shattuck's service. Family history negative. Had not felt well for three weeks; headache, pain in back, anorexia; pain in the stomach for two weeks. Had been in bed three days prior to entrance. Epistaxis four days before entrance. Bowels regular; no cough; pulse, 80; respiration, 20; temperature, 101°. Heart: right border at middle of sternum; left border, three centimetres inside nipple line; apex, two centimetres inside nipple line; sounds normal. Lungs: resonance and respiration good throughout; no chest symptoms whatever. Spleen not felt. Abdomen tympanitic; tenderness more marked on right side. Widal's serum-test was made eight times, always with a negative result. Leucocyte count normal; no arsenic or lead in the urine.

February 12. The patient was in my service from February 1st until his discharge. The finger-ends are markedly clubbed.

X-ray examination: Both sides of the chest darker than nor-

mal; no special area markedly dark, but rather the darkness was uniformly distributed. Excursion of the diaphragm on the right side one and three-fourth inches from the upper border of the fourth rib to the upper border of the fifth rib; on the left side, one and one-fourth inches from the middle of the fourth rib to the upper border of the fifth rib.

25th. Patient is losing ground. Has no pain, no cough; appetite is good.

March 3. Resonance: both front and back unusually good; suggests emphysema rather than consolidation; no râles.

4th. Still losing weight; no improvement.

X-ray examination: Right side darker than left throughout. Upper two-thirds of left chest so dark that the ribs are barely seen, and only during full inspiration; diaphragm barely seen on inspiration on right side; on left side seen only during inspiration.

7th. Resonance over both fronts is increased rather than diminished; respiration normal; expiration not prolonged; resonance and respiration over backs normal.

8th. Since admission the temperature has run an irregular course and the patient has grown weaker and thinner. (Four days after entrance the temperature rose to 104.5° , varied for ten days from 99° to 102° , then from 102° to 103° for six days, after which it was very irregular for several weeks, varying from normal to 103° .)

10th. Respiration over a small area in right front just below clavicle is harsh; tactile fremitus slightly increased; no râles. Resonance not so good over right base behind as elsewhere, and respiratory sounds are diminished.

11th. *X-ray examination*: Right side darker than left during expiration; lung nearly as dark as liver. Only a portion of left border of heart is seen. Diaphragm on right side moves one inch; on left side, one and one-eighth inches.

20th. There has been much improvement; patient is now up.

April 4th. *X-ray examination*: Both chests clearer than at last x-ray examination; ribs can now be seen on both sides; both borders of heart seen. Diaphragm on right side moves

one and one-fourth inches ; on left side, one and one-eighth inches.

19th. X-ray examination : Outlines of the heart and of all the ribs are seen clearly. Excursion of the diaphragm on right side one and three-eighth inches ; left side, one and one-half inches.

Temperature has been between normal and 100° for nine days, and the opportunity was given to try the tuberculin test. One-half milligramme of tuberculin was injected ; temperature rose to 102.8° eighteen hours later, and then fell to 99.5° . Malaise ; patient complained of feeling sore all over.

To recapitulate : This patient's illness began about January 1, 1895. He was first thought to have typhoid fever, but later this diagnosis was regarded with suspicion. During February he failed very much ; had to be fed for about three weeks, was losing in weight and strength, and I gave a very unfavorable prognosis to his relatives. On March 9th the outlook for the patient's recovery was still less hopeful, but on March 20th he was up and dressed. No definite diagnosis was made until February 12th. I then examined him with the fluoroscope, and made the diagnosis of disseminated pulmonary tuberculosis. On April 19th, as already stated in the physical examination, he reacted to the tuberculin test. The patient was discharged from the hospital on April 22d. He had gained in weight and strength, although still rather thin ; color good.

June 24, 1898. Has gained three pounds in the past four weeks.

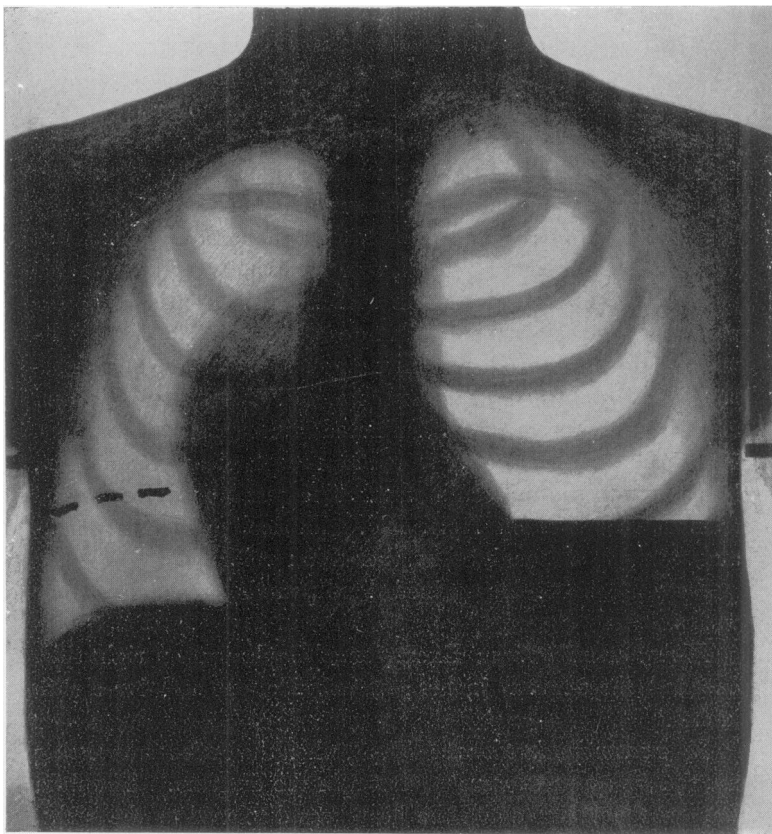
X-ray examination : Excursion of diaphragm on right side, one and three-fourth inches ; on left side, one and five-eighth inches.¹

In pneumohydrothorax (Fig. 9), when the patient was sitting up, the appearances were as shown in the diagram. The fluid was on the left side and the heart was displaced to the right. The level of the fluid changed as the patient bent backward or forward. When he was gently shaken the splashing of the fluid was clearly seen, and while quiet the waves made by the heart-

¹ I have given in *Med. and Surg. Report, Boston City Hospital, January, 1897*, an outline of thirty cases of pulmonary tuberculosis chosen from more than fifty examined in 1896.

beat were clearly visible on the surface of the fluid. In the summer of 1897 I demonstrated this to Dr. Buckingham, who related what he had seen to other medical men, but they could not be induced to believe it was not a joke.

FIG. 9.

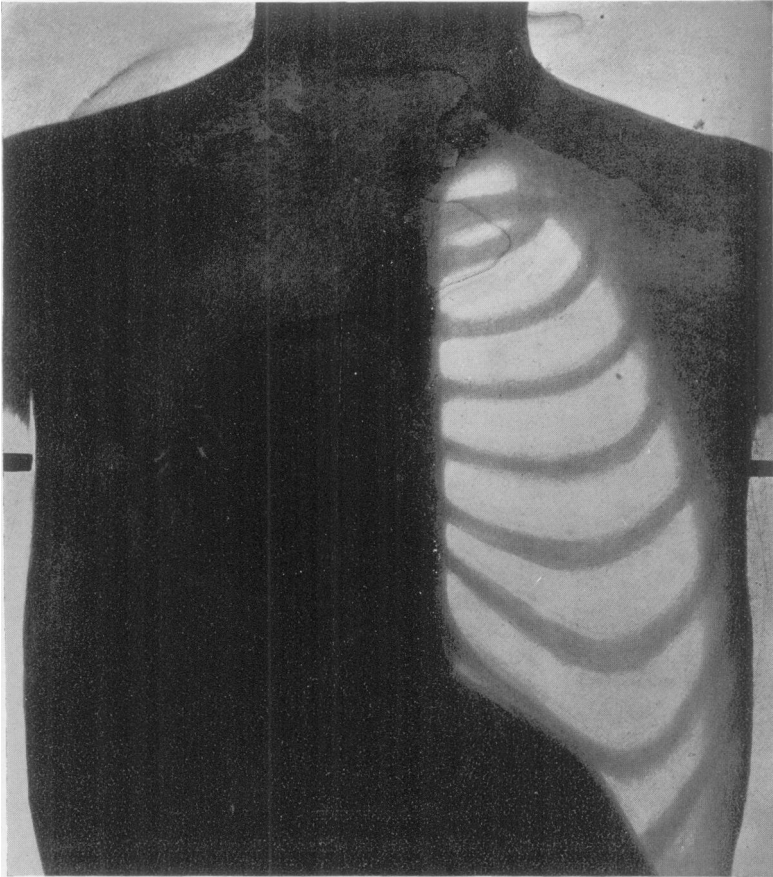


PNEUMOHYDROTHORAX. Left side.

In pneumothorax (Fig. 10) the diaphragm on the affected side is much depressed, and its slight movement during respira-

tion is in the portion near the median line, and is probably imparted by the movement of the right side. The heart is

FIG. 10.

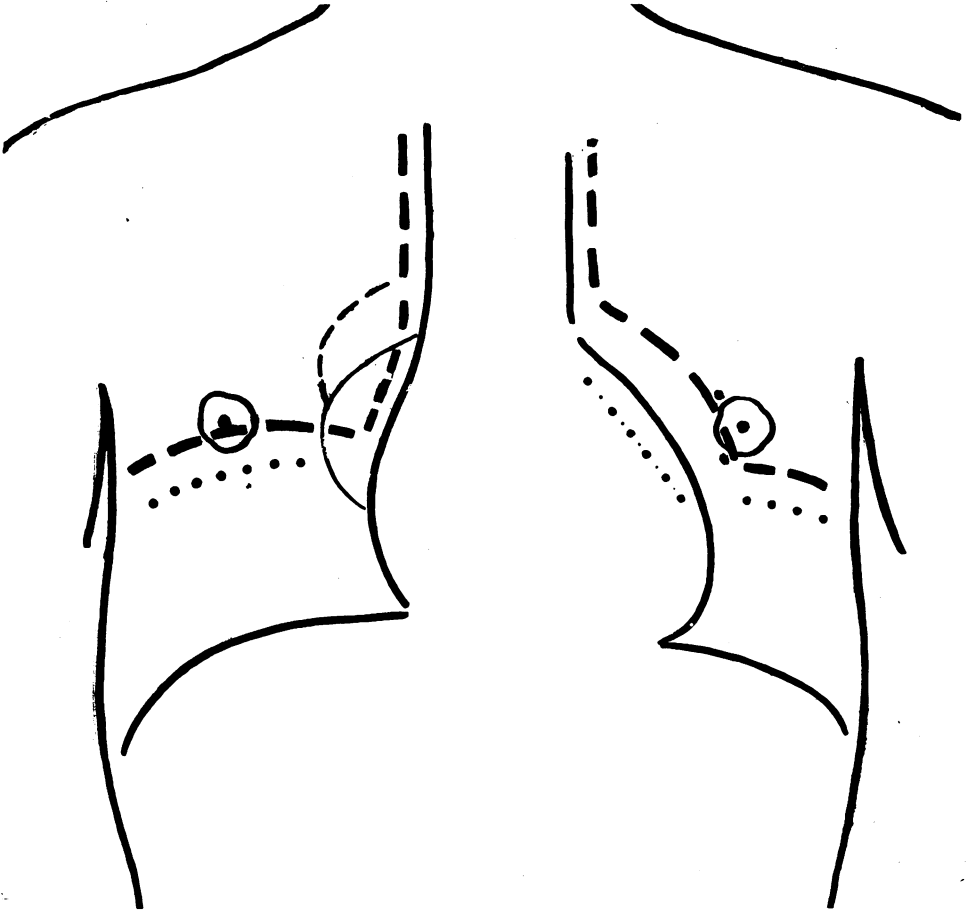


PNEUMOTHORAX ON LEFT SIDE, AND TUBERCULOSIS ON RIGHT SIDE.

pushed to the other side. This patient also had tuberculosis on the right side.

Let us now take up x-ray examinations in disease of the

FIG. 11.



HEART-MOVEMENTS.

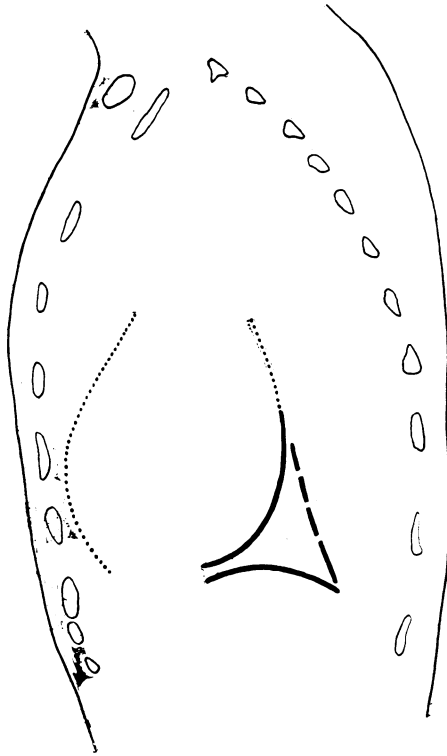
Diagram representing the borders of the bloodvessels, heart, and diaphragm—the full lines in deep inspiration, the broken lines in expiration, the dotted lines just below the broken ones the position of the diaphragm in ordinary inspiration.

The line of large and small dots inside the left border of the heart shows the position of the left border in systole, and the full line in diastole, during full inspiration. The other movements of the heart—namely, those of the apex, the right ventricle, and the right auricle—are not indicated in the diagram.

It is obvious how the fluoroscope may assist to determine the position, size, and mobility of the heart.

heart, and first recall that the normal heart is a very movable organ ; that it varies in size and position within certain limits ; that it is readily pushed out of place, and that the direction of

FIG. 12.



TRIANGLE.

The outline of the body and the ends of the ribs have been traced from an anatomical plate, which represented a section of the body through the left parasternal line. The heart-lines and the outlines of a portion of the diaphragm and spine, or rather what lies in front of the spine form the triangle, and were drawn while looking through the fluoroscope on the left side of a patient during full inspiration and then sketched—in about the proper position—on the drawing from which this diagram was made. This triangle is usually closed at the anterior angle, although it did not happen to be in this patient.

It will be seen that the outline of the heart is indicated partly by a full and partly by a dotted line. The full line shows the extent of the border usually seen in the fluoroscope in health ; the dotted line the additional amount seen in this special individual in health.

its long axis is not always the same. In some persons the axis is more inclined; in others more vertical.

The diagram of the heart-movements (Fig. 11) shows what is seen in the fluoroscope when placed on the front of the chest. The heart is seen to change its position during deep inspiration, being moved downward and inward.

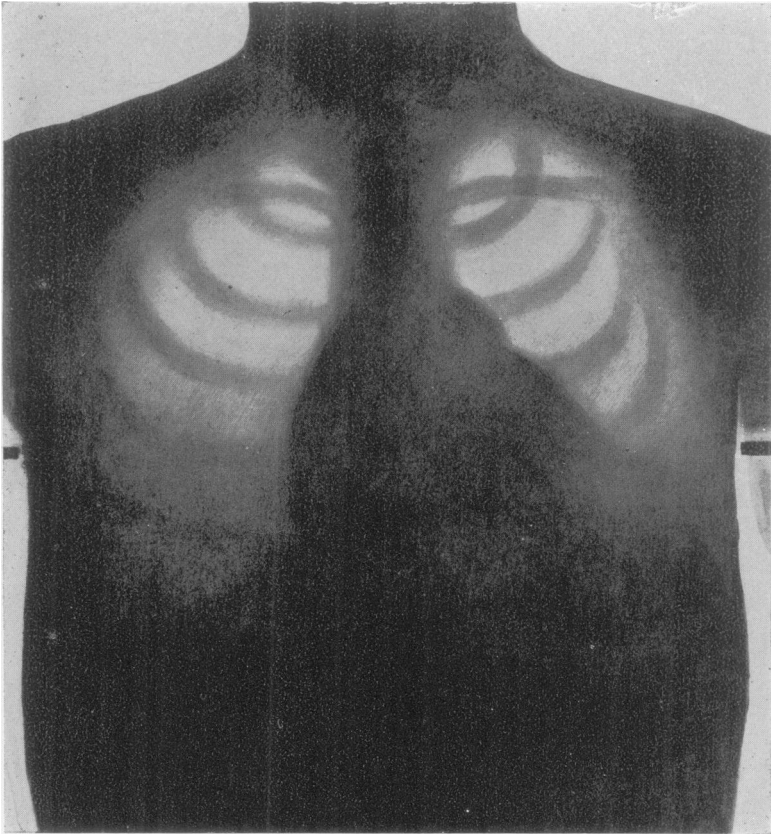
Triangle. While looking through the body from *side to side* during a deep inspiration, a light triangular area (Fig. 12) comes into view, the sides of which are formed respectively by a part of the heart line, of the diaphragm line, and of the spine, or rather what lies anterior to the spine. The last line is less defined than the two others. The triangle varies very much in size and in shape in different individuals, and also varies according to the side on which the observer stands. It is smaller when seen through the fluoroscope on the left side than on the right side. In a patient with a transposed heart this condition was reversed, the triangle being smaller when seen from the right than from the left side. This was due to the fact that the transposed heart was nearer the right thoracic wall than the normal heart, and it is obvious that the nearer the heart to the side of the body where the observer stands with the fluoroscope the smaller will the triangle appear. This triangle should always be seen in health; if not seen, the physician should investigate the cause of its absence.

Let us now return to the usual direction for examining the heart. *The position of the heart* is seen to be changed in diseases affecting the lungs, pleura, or bloodvessels, or by conditions in the abdominal cavity pressing the diaphragm up. A change in cardiac outline, the result of an upward displacement of the heart may be attributed by auscultation and percussion to an alteration in the size of the heart, whereas by the x-ray examination it could be rightly interpreted.

A lessened movement of the heart in deep inspiration may be seen to occur in emphysema, or where the pleura or pericardium is adherent. In one patient I saw the apex tilted up during deep inspiration instead of moving down. This was due, I suppose, to adhesions. We may thus follow some of the

effects on the heart of changed conditions in its vicinity. Some diminished or abnormal movements of the heart during a deep inspiration may be evidence of adhesions.

FIG. 13.



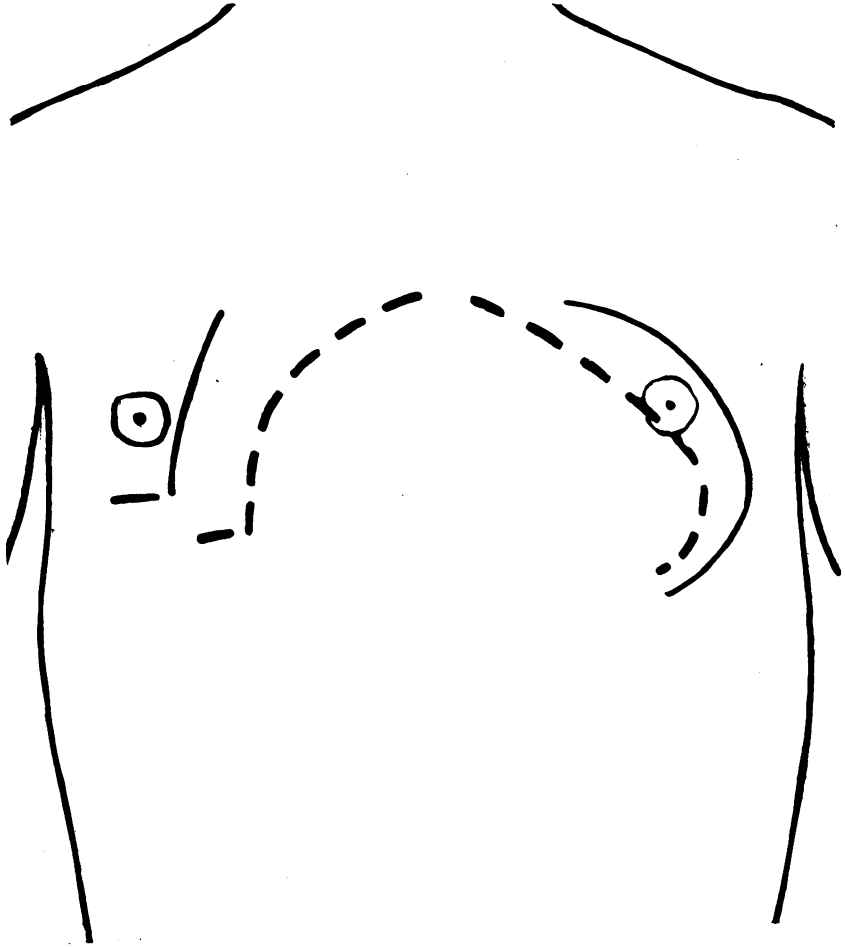
PASSIVE CONGESTION, OR OEDEMA, OF THE LUNGS.:

In valvular disease I have seen much darker lungs than the diagram indicates become clear, and the dyspnoea cease after treatment by digitalis.

Let us consider now some of the changes which affect more nearly the heart itself.

Warning may be given by a passive congestion or œdema of the lungs of a serious condition of the heart or kidneys, as

FIG. 14.



PERICARDIAL EFFUSION.

Broken lines show outline by percussion, full line by fluoroscope.

shown in the diagram (Fig. 13), though it may be more marked than is here indicated. The lower portions of the lungs are

dark, the outlines of the diaphragm cannot be seen, and only a portion of those of the heart. By such appearances as these I was led to warn one of my patients who had renal disease to put his affairs in order; he died suddenly within three months. By auscultation and percussion I had not appreciated the serious condition of his lungs.

In pericardial effusion (Fig. 14) the outlines of the heart may be obliterated, and, instead of the usual pulsating heart, we see a much larger dark area. The size, shape, and position of the pericardial effusion, and the fact that the outline of the pulsating heart cannot be seen, assist in making the diagnosis. New growths about the heart may sometimes be seen.

An enlarged heart, as in arteriosclerosis or valvular disease, may be recognized in the fluoroscope, and also a heart *smaller* than normal, with which anæmia is sometimes associated, may be readily seen in the fluoroscope. It is, I believe, important for the physician to be aware of the existence of a small heart in any of his patients, both as a guide to the mode of life to be pursued when the patient is in health, and as a factor in prognosis in some diseases, pulmonary tuberculosis for example.

A transposed heart (no diagram of this is shown) may easily be seen in the fluoroscope. During my recent service at the Boston City Hospital my senior house physician asked me to explain to him the conditions present in the heart of a patient who had been admitted the day before. I examined the patient, but withheld my opinion until I made an x-ray examination, as the heart-sounds and murmurs were unlike any I had ever heard in that place. On examination with the fluoroscope I found the patient's heart was transposed, the left ventricle could be seen beating to the right of the sternum, and the right auricle was on the left of the sternum. When the patient was turned around and the fluoroscope was placed on her back, the transposed position of the heart was also very evident. This patient was examined by five physicians previous to the x-ray examination, and we all failed to recognize the transposition of the heart.

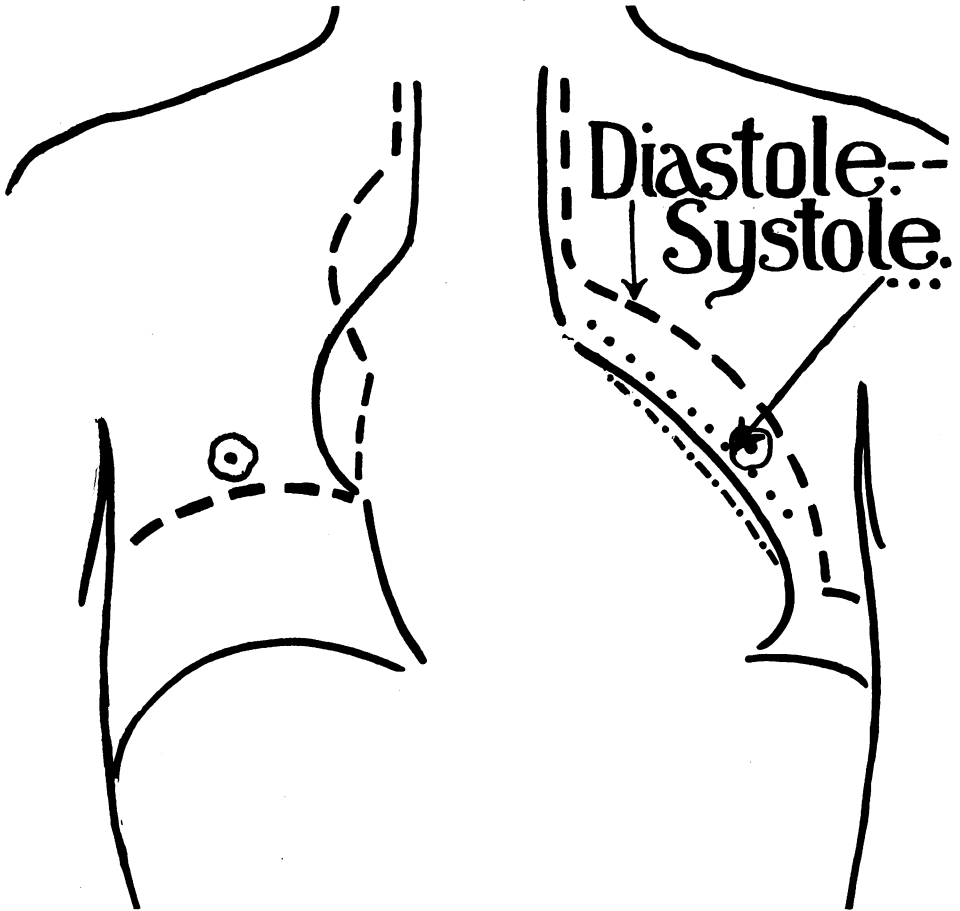
To arrive at a knowledge of the heart's condition in disease

it is of importance to know its size as nearly as possible, and this can obviously be satisfactorily accomplished by means of the fluoroscope, except where pathological conditions partly obliterate the cardiac outlines, as in pleurisy with effusion or oedema of the lungs for instance. Of course, in very stout patients or those with pulmonary emphysema it is often impossible to determine the size of the heart by percussion, but stoutness is no serious obstacle to an x-ray examination, and emphysema is a positive advantage. In fifty-eight patients who were not stout and had no emphysema—that is to say, in whom the conditions were not unfavorable for the use of percussion—I compared the size of the heart as obtained by percussion with that obtained by an x-ray examination. The percussion lines were drawn on the skin in blue and the other lines in black. The outlines drawn by the aid of the fluoroscope were, of course, more complete than those obtained by percussion. The percussion lines varied considerably in a portion of the cases, in some patients an inch or more, from the size of the heart as seen in the fluoroscope; sometimes they indicated a smaller but usually a larger heart than the reality. Twenty-two of the fifty-eight patients had organic disease of the heart, and a more frequent disagreement in regard to one or both borders of this organ, as obtained by percussion on the one hand and an x-ray examination on the other, was found among them than in the remaining thirty-six cases, who were suffering from other than cardiac diseases. I am therefore satisfied that in some—particularly in cardiac cases—we have not determined with exactness the size of the heart by percussion, and, unfortunately, we cannot tell in which of our patients percussion will fail in accuracy. It is well, therefore, that we should realize this in those cases in which we desire precise information about the size of the heart.

Let us compare these two diagrams—namely, *Heart-movements* (Fig. 11) and *Aortic Insufficiency* (Fig. 15)—the first of which was made from a healthy individual and the other from a patient who was unconscious of any cardiac disease, but who had a marked insufficiency of the aortic valve. It is ob-

vious that the left side of the heart in the patient with disease of the aortic valve is much larger than normal. I could see

FIG. 15.



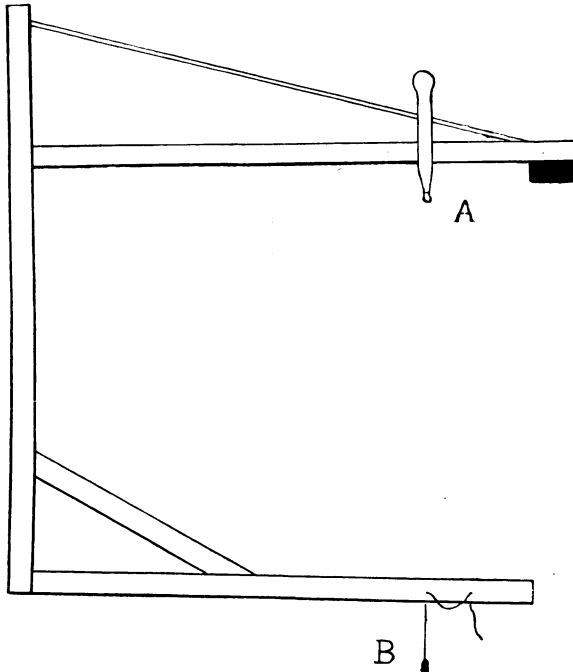
AORTIC INSUFFICIENCY.

Diagram of heart in a patient with aortic insufficiency. Compare with Fig. 11.

Diastole and systole during *ordinary* respiration are indicated by the arrows and the broken and the dotted lines respectively. The line made up of dashes and dots shows where the left border of the heart is in systole during deep inspiration. When a full breath is taken the heart is compressed, and the diastolic excursion is less than in ordinary breathing. The movements of the heart could be followed in this patient unusually well.

the great left ventricle making a large excursion between systole and diastole, and appreciate better than ever before what an extraordinary quantity of blood is delivered into the aorta

FIG. 16.



INDIRECT PLUMB-LINE. Scale one-eighth of an inch to one inch.

An instrument, which is a form of plumb line, to be used when the patient is lying on the stretcher, that I have devised for determining the exact position of the Crookes tube when it is desired to place it directly under the point to be examined. This instrument is especially useful in cases where the median line is not available as a point of reference. I have used it from time to time for more than a year. By it the right and left borders of a large heart may be determined separately.

This instrument is made of strips of cedar one-eighth inch thick and one inch wide. There is a counterpoise of lead on the end of the arm beyond A. The vertical piece from which the arms A and B extend is made of two strips of cedar, fastened at either end and separated three-quarters of an inch in the middle by a piece of cork. This is done to give stiffness.

A piece of thin wood about two inches square with a depression in the centre (not shown in the figure) is placed on the patient so that the depression is over the point to be examined, directly under which it is desired to bring the Crookes tube. The rounded point, A, is placed in the depression, and the rest of the instrument being free to swing, the weight, B will hang directly under A; the position for the anode of the tube is just under B.

with each systole in order to make up for the large amount which was sure to leak back during each diastole. Further, it could be distinctly seen that the excursion of the left side of the ventricle was diminished when a full breath was held, as then the heart was compressed by the lung. I refer to this patient in order to indicate to you that it is now possible to examine more completely than hitherto patients who have or are feared to have cardiac disease.

To carry out this new method of examination properly requires large and expensive apparatus and experience in using it with a considerable number of patients. The x-rays do not burn, and there need be no fear of injury from the accompanying electrical discharge to any individual if the examinations are properly conducted and simple precautions are taken. At the Boston City Hospital I have made about two thousand x-ray examinations, and no one has received any injury or even inconvenience from them. It is easy to burn the fingers if they are put too near a candle, but it is not therefore dangerous to read by its light.

This new method of examining our patients has now passed the stage of mere interest and novelty, and in its own special field, if suitable apparatus is used, can be counted among our trustworthy aids to diagnosis. In some cases it gives us more accurate information, and in certain others information that we have hitherto been unable to obtain.

I desire to record my appreciation of the value of Dr. William H. Rollins' investigations, published in the *Electrical Review*, which have promoted the usefulness of the Röntgen light in medicine and in surgery, and to express my gratitude to him for his untiring readiness to aid me to overcome the obstacles which have beset those who are using x-ray apparatus.

DISCUSSION.

DR. F. I. KNIGHT: I would say that Dr. Williams, before the meeting, told me that he hoped there would be a very free discussion of his paper. I do not consider myself able to discuss it, but announce Dr. Williams' desire to those gentlemen who are. He wants, if possible, criticism, for it is a new field, and he would welcome it.

For my own part, I feel with him that the fluoroscope is a very important addition to our armamentarium. In a case of suspected aneurism, I appreciate its possible great value when I recall the number of cases I have seen in which there has been doubt as to what was compressing the trachea. If we could get such a picture as this on the wall there would be no question but that it was an aneurism; and so in regard to the size of the heart. I was particularly impressed with what Dr. Williams said about emphysema being an aid rather than a hinderance, as emphysema interferes so seriously with the results of percussion, and he also tells us that excessive fatty condition of the chest-walls, which renders percussion in the cardiac region difficult, is very little hinderance to examination with the fluoroscope. And even in tuberculosis, notwithstanding the criticism of my learned brother yesterday, I do think that every aid we can get to an early diagnosis is going to be of much importance. As yet it seems, perhaps, that it is of less advantage in that disease than in others. It is evident, from what I have seen and from what Dr. Williams himself admits, that this art is difficult, and for a time, perhaps, it must rest in the hands of those who have had long experience, like Dr. Williams; but in the end perhaps methods may be simplified so that we can all avail ourselves of it. At any rate, in doubtful cases we can have the aid of our brothers who become expert in it as Dr. Williams has.

DR. QUIMBY: Will Dr. Williams tell us just his rule for placing the x-ray tube behind the patient as regards a definite distance from and its relations to the spinous processes? I would also ask if he has found any fluoroscopic screen which can be made to conform to the chest-wall. It would seem that absolute uniformity in placing the tube, both as to distance from and relation to the spine, would be imperative to avoid relative distortion of the outlines of the heart upon the screen. I understood the doctor to say he had not seen the heart shorten. It was my good fortune recently, through the courtesy of Mr. Tesla, to see a most perfect demonstration of the heart. When the tube was more nearly in the plane of the spine the lateral excursion of the heart was prominent, but when carried more to the left and lower, then the shortening was equally prominent and distinct.

DR. J. E. STUBBERT: I did not have the pleasure of hearing the first part of Dr. Williams' paper, but I believe he wrote the most scholarly article, about a year ago, that ever appeared on the subject, and I am thoroughly familiar with his views. It is hardly necessary to add anything to what he has said, but with reference to a remark of Dr. Quimby's as to the shortening of the heart, I wish to state that I have observed it a number of times. When I first began working in this line it was my custom to bring into the dark-room laymen who would naturally have no knowledge of what they were to see, and they have often described to me the shortening of the heart in action; I have repeatedly noticed a dimpling of the apex.

The doctor referred to some one considering the examination by x-rays a joke; I have gone through the same experience. I remember Dr. H. P. Loomis once came to Liberty and told me he did not believe in the x-rays at all. I brought in a case which neither of us nor my house physician had seen before. I asked Dr. Loomis to examine the case, and he diagnosed it as consolidation of the right apex, with beginning of softening and some infiltration in the lower lobe. He made the rather significant remark that he might not have a cavity, but was beginning to excavate. I then examined the patient and agreed with Dr. Loomis' diagnosis. I sent for the house-doctor, and he made an x-ray examination; after a moment he said, "This man has consolidation of the right apex, he has infiltration of the lower portion of the lung, and while he may not as yet have a cavity, he is going to have one in a short time." Dr. Loomis said: "Well, if it can be diagnosed in that way I will have nothing more to say," and he is now a convert. There is no doubt in my mind that we can diagnose, especially in thin subjects, very slight infiltrations at the apices of the lungs. We all know how difficult it is to educate our ears sufficiently to distinguish indistinct sounds, but with the x-ray the very slightest infiltration is shown in the form of a slight haze.

Four brothers were brought to me, one with laryngeal tuberculosis and infiltration of the apices. There was a bad family history; the examination of the remaining three by the ordinary methods revealed nothing, but with the fluoroscope I was able to distinguish a very slight haze at the top of one lung in two of them. The result was that those boys were left in the country for a winter, and when I examined them some twelve months later the haziness had disappeared, and they were apparently saved from a more serious form of tuberculosis by the examination with the x-rays.

The question of burns is a very interesting one to me, as early in my experiments two patients were rather severely injured. At first I used a coil, and the accident happened in attempting to photograph lesions of the lungs. One of the patients recovered in a very short time, and the other one died from his pulmonary disease before the

skin lesion had healed. We now use the static machine, from which I have never seen bad results.

Another form of tuberculosis that I think is more easily demonstrated by the fluoroscope than by ordinary methods of examination is the disseminated one. The condition of pericarditis with effusion is one that I have never seen. Pleurisy with effusion is very easily marked out.

One more point regarding the remarks of Dr. Butler last night as to the shape of the right side of the heart. I would like to ask Dr. Williams what his experience in that line has been. It never having been brought to my mind, I have not studied the exact outline of the right side of the heart, but, speaking from memory, I remember only three or four cases in which the outline was vertical, as stated by the doctor last night. In most cases the right side of the heart shoots off rather abruptly above the margin of the fifth rib, and I should be inclined to think that the shadow thrown can be more depended upon than the percussion note.

DR. R. G. CURTIN: It occurred to me, when Dr. Williams told us that in one case where the lung was a little cloudy the use of digitalis cleared it up, that the patient might have had œdema of the lung which was cleared up by the treatment. I would like to ask Dr. Williams what the appearance is of old pleural effusions, especially those in which the pleura was thickened. It has occurred to me that it would be difficult to distinguish between the catarrhal process and that of tubercular infiltration, that is, if the sputum on examination yielded no bacilli.

DR. VINCENT Y. BOWDITCH: It is hardly necessary for me to speak on this paper; it is, however, my pleasure and privilege to testify to Dr. Williams' painstaking, careful work in the City Hospital, where I have been associated with him. One point comes to my mind, and that is the apparent ease of recognition of incipient tuberculosis by means of the x-ray machine. It seems hard to realize, knowing the translucency of most tissues, that by the x-ray machines we can discover a very slight beginning tuberculosis when we cannot discover it by auscultation and percussion. I should like to have Dr. Williams enlarge a little more on that subject.

DR. WILLIAMS: I did not take up the methods of examination in this paper because I had described them in previous articles.¹ My patients at the hospital were brought into the x-ray-room on a stretcher, which fits on to supports attached to the stand of the x-ray machine. If a patient is too ill to be moved he cannot very easily

¹ "A Study of the Adaptation of the X-rays to Medical Practice." Medical and Surgical Report of the Boston City Hospital, January, 1898. "X-rays in Medicine." Medical News, May 14, 1898.

be examined, although this is possible by means of a portable x-ray machine. The anode of the Crookes tube should be, at least, two feet away from the patient for examining the thorax, and usually under the point where the median line is crossed by a line joining the nipples; this position should be determined by plumb-lines. The median line is obtained by sighting from a permanent plumb-line, that is fastened to the middle of the support upon which the head of the stretcher is placed, to another fastened to the support at the foot in the same way. The other line is determined by putting a string seven or eight feet long, with a weight on either end, across the chest from nipple to nipple; that is to say, on a level with the fourth ribs. The line hangs down on either side of the patient, and the point is obtained by sighting, as before, from weight to weight, and the anode may then be brought into line with these weights. The patient should be lying on his back when he is examined if the plumb-lines are used, but can be turned afterward if desired. In this reclining position the patient is perfectly comfortable and his strength is not taxed. I tested the correctness of the plumb-lines as a guide to the position of the tube by making two successive examinations, the patient getting up and the tube being moved after the first examination, and both patient and tube being rearranged for the second. The outlines of the heart and ribs, traced by means of the fluoroscope in these two examinations, differed only by the width of the line. (See Fig. 16.)

The essential part of the fluoroscope is the screen, and if the room is properly darkened this may be used alone, as the box part of the fluoroscope, which excludes the ordinary light from the eyes, is not then necessary and prevents them from being brought as near to the screen as is sometimes desirable. This screen should be twelve by fourteen inches, and for making a permanent record of a case may be covered to advantage with a piece of thin glass or a film of celluloid or gelatine—these do not obstruct the light. If the surface of the film is ground an ordinary pencil may be used, but for smooth surfaces a lithographer's pencil is necessary. The outlines of the heart and diaphragm, for instance, that have been drawn on the film, may be traced, after the patient has been taken away, on a suitable sheet of paper placed over the film if both are held up against a window. The patient's name, the diagnosis, date, etc., may be added and the paper filed away for future reference. Some of the examinations¹ I have made were recorded in this way, but more by using tracing-cloth that was placed directly on the patient, and the lines

¹ I have now tracings and notes of more than one thousand x-ray examinations which are classified according to diseases, but thus far I have not had the opportunity of publishing as many of the results as I shall hope to later.

which had been drawn on the skin¹ by means of the fluoroscope were traced upon the cloth.

For purposes of study the best machine is necessary ; but, having learned to identify the appearances in the chest, for instance, under both normal and abnormal conditions, a portable x-ray machine may be used with satisfactory results if the patient is too ill to come to the office or, in case of a hospital patient, to be moved to the x-ray room, but if the physician is not familiar with these appearances a small machine of this kind is unsatisfactory.

I have not discussed the heart's pulsations fully, but I did not mean to suggest that the heart appears to have no motion at the apex, but merely that its most conspicuous motion is on the left side, as shown in the diagram. To show the apex of the heart another position of the tube is better than the one chosen for these diagrams.

The normal heart varies in size and position within certain limits. I have already referred to the great importance of determining whether or not the heart is smaller than normal. We also need to know if the heart is of unusual size, and, if this is the case, in what part the organ is enlarged. The right border of the heart is difficult to determine by auscultation and percussion, but it is seen in the fluoroscope, during full inspiration, about one inch and three-quarters to the right of the median line. In women and boys and girls the distance is less.

We can see the right auricle in both health and disease, and in certain diseases a part of the left auricle also.

Aneurism of the heart may be seen in the fluoroscope ; also aneurism of the aorta. The outlines of an aneurism of the aorta, which appears on the screen as a dark area, may sometimes be seen to move with the pulsations of the heart, but when these pulsations are not seen the diagnosis with the fluoroscope must be based on the position and shape of the dark area.

Let me refer for a moment to the diagram of pericardial effusion taken from a patient in my service in the early part of 1897.² I examined him with the fluoroscope because of this effusion, but while doing so observed that the apex of the right lung was darker than normal. I then made a physical examination of the lungs, but could find no evidence of phthisis. I continued to examine the lungs in the fluoroscope from time to time, and noticed that the diseased area extended and the excursion of the diaphragm on the right side diminished ; finally the left lung also became involved, and the movement of the diaphragm on this side was also shortened. No physical

¹ It is not necessary in most cases to remove the clothes.

² I reported this case in an article entitled "The Röntgen Rays in Thoracic Diseases." *American Journal of the Medical Sciences*, December, 1897.

signs were found on the left side at this time by auscultation and percussion, but they were now marked on the right side. I gave the patient tuberculin, to which he reacted. The excursion of the diaphragm is sometimes seen in the fluoroscope to be restricted before a diminution in the brightness of the lungs is observed.

Among the cases of pleurisy with effusion that I examined with the fluoroscope there were some in which a darkened area of the lung and a diminished excursion of the diaphragm led me to suspect tuberculosis when it had not been detected by physical examination. This suspicion was afterward confirmed in certain cases by the tuberculin test, or by the finding of bacilli, or the development of the case.

Edema of the lungs may be distinguished from early tuberculosis by means of the fluoroscope. In the former the lower part of the chest on both sides is dark, whereas in early tuberculosis the darkness is usually on one side and at the apex.

Adhesions of the pleura without thickening would not obstruct the passage of the rays and, therefore, could not be seen in the fluoroscope, but, if the movement of the diaphragm were restricted, an adhesion might be suspected.

Auscultation and percussion may leave us uncertain whether we have to deal with an adhesion with thickening, or with a pleuritic effusion; but the fluoroscope can tell us certainly if fluid is absent, unless it is encysted. If present the diaphragm line is obliterated on the side of the effusion, especially in the outer portion where this muscle curves down to the side of the chest, because fluid would sink and fill-in this lower and outer angle unless it were encysted. The ability, then, to follow this portion of the diaphragm line proves the absence of fluid, except in the particular case just mentioned. Even in such a case I have suspected the presence of fluid by means of the fluoroscope, and this suspicion was confirmed in one case by an autopsy and in another by tapping. The x-rays enable us to choose the most desirable place for inserting the needle. Calcareous deposits in the pleura are seen as dark areas in the fluoroscope. This is also true of some calcareous deposits in the aorta or in certain portions of the heart.

A suitable outfit for making x-ray examinations will cost at least \$500. I have been obliged to have mine made to order, and thus had the opportunity to devise the various adjustments necessary for a practitioner.

Burns may be produced when either the static machine or the coil is used, but with the simple precautions now known to the practitioner they are wholly avoidable. None of my patients have ever been burned, and I have been making x-ray examinations, sometimes with the static machine and sometimes with the coil, during about two and one-half years. Tesla suggested placing a screen of aluminum wire or a thin sheet of aluminum, which should be grounded, between the tube and

the patient to prevent any risk of burns. The following experiments of an electrical engineer, made upon himself with a static machine, suggest that burns may be prevented by grounding the anode. During the first fourteen days of November, 1896, he exposed his skin to the Crookes tube at a distance of less than two inches. The first exposure was three-quarters of an hour; the second, half an hour; the third, one hour; and the fourth and fifth, half an hour each. These successive exposures were at intervals of about three days. The anode was always grounded, and there were no untoward results. On December 21st he exposed the same portion of his skin in a similar manner for half an hour, without grounding the anode. Twelve days later the skin was blistered, and a severe ulceration followed.

Photography gives more detail than the fluoroscope; for instance, I have taken x-ray photographs which showed normal arteries; these could not be readily seen in the fluoroscope; but the latter has the advantage in examining the thorax, for example, as the movements of the diaphragm and heart can be watched, and the examination with this instrument can be made more quickly. Photography requires a great deal of time, even with the dark room at hand, as it is necessary to wait for the plate to be developed; but I use either the fluoroscope or the x-ray photograph as occasion requires.

I do not know exactly how many hospitals have x-ray machines; I am told that at least thirteen in New York have them. We have them in Boston, and they are also to be found in Philadelphia, Baltimore, Chicago, St. Louis, San Francisco, and, probably, in all the large cities in the country.

One last word about this method of examination. In hospitals it will be always desirable to have a photographer to take the x-ray photographs, to keep everything in order, and manage the apparatus; but it is not practicable for other than medical men, trained in this special work, to make the x-ray examinations with the fluoroscope. You would not send a patient to a man who was not a physician for auscultation and percussion.