

Injection injuries: seemingly minor injuries with major consequences

Dailiana H Z, Kotsaki D, Varitimidis S, Moka S, Bakarozi M, Oikonomou K, Malizos N K

Department of Orthopaedic Surgery, University of Thessalia, Larissa, Greece

Abstract

Background: High-pressure injection injuries are rare injuries, characterized by a small puncture wound that is often underestimated by physicians and patients. The injected substance leads to extensive tissue damage and sometimes to loss of the limb. **Aim:** To underline the severity of these injuries and to alert physicians to recognize them and treat them appropriately.

Methods: Eight patients with injection injuries from lubricants (6) or solvents (2) were treated in a University Orthopaedic Department in a 5-year period. In all patients the mild initial symptoms were aggravated over the next 4-6 hours leading to a severe compartment syndrome of the hand. Five patients were referred with a mean delay of 3.8 days and 3 were treated immediately; all with debridement and compartment release.

Results: The total number of procedures per patient was 2 to 5. In 3 patients a heterodigital flap was necessary whereas in one the second ray was amputated. Results were excellent in 5 cases and good in 3.

Conclusions: In injection injuries, prompt diagnosis and immediate aggressive surgical intervention are necessary to save the patients' digit/limb. Patients should be informed about the severity of their injury, its potential complications and the multiple surgical procedures that may be required for a satisfactory functional result. Hippokratia 2008; 12 (1): 33-36

Key-words: injection injuries; hand; toxic substances; compartment syndrome

Corresponding author: Dailiana Z H, School of Health Sciences, University of Thessalia, 22 Papakiriazi St., Larissa 41222, Greece, Tel: ++30 2410 682722 Fax: ++30 2410 670107, e-mail: dailiana@med.uth.gr

High pressure injection injuries result from the inappropriate operation of equipment that achieve ejection pressures of their contents sufficient to breach the human skin¹.

These injuries are uncommon with an estimated incidence of one in 600 hand injuries presenting to an emergency care unit². They occur predominantly in young men and are mostly occupational injuries³. The majority of the injuries affect the non-dominant index finger and occur usually due to inexperience in operating the high pressure equipment, inappropriate use, insufficient training, carelessness, fatigue at the end of the shift or rupture of the equipment³⁻⁵. The most commonly injected substances are paints, paint solvents, grease, fuel oil (paraffin oils, diesel oil, gasoline) but there has also been reported injection of water, air, cement, and animal vaccines^{6,7}. In order to breach the human skin the ejection pressure has to be at least 100 pounds per square inch (psi)⁸ while most high-pressure guns and injectors reach pressures of 2000 to 12000 psi³.

The puncture wound is small, inconsiderable and not distinct. Initially the toxic substance causes edema and ischemia and later the combination of mechanical and chemical factors leads to compartment syndrome and consequently to fibrosis, adhesions, necrosis and secondary contractures and ulcerations, apart of the risk of systemic intoxication (acute renal failure, air embolism)^{1,9}.

The aim of this study is to point-out the severity of

these apparently innocuous injuries and to raise physicians' awareness for prompt diagnosis and effective treatment.

Material and Methods

In a period of 5 years, 8 patients with injection injuries were treated in the Department of Orthopaedic Surgery of Larissa University Hospital in Greece. The patients were injured on their hands while either using high pressure machinery (6) or repairing hydraulic pumps (2). All patients were male, with mean age of 34.5 years (range 23-49) and manual workers. In 7 cases the injury was occupational while one patient was amateur. Four of 7 occupational injuries occurred at the end of the shift where fatigue played a significant role. The substances involved in the injection injuries were solvents (2 cases) and lubricants (6 cases).

The injury was located at the second ray of the dominant hand in 7 patients (Figure 1A, 2A, 3A) and in the 3rd ray in one, while the site of penetration was mainly detected in the fingertip (6) (Figure 1A, 3A) and more proximally in 2 cases (middle phalanx and head of second metacarpal bone) (Figure 2A).

Regarding the time of admission to the Department of Orthopedic Surgery of Larissa University Hospital, only 3 patients presented at the hospital immediately after injury, while the other 5 came with a delay varying from 36 hours to 12 days (mean: 3.8 days). These 5 patients were treated initially in other medical facilities, 4 conservatively and 1 surgically.

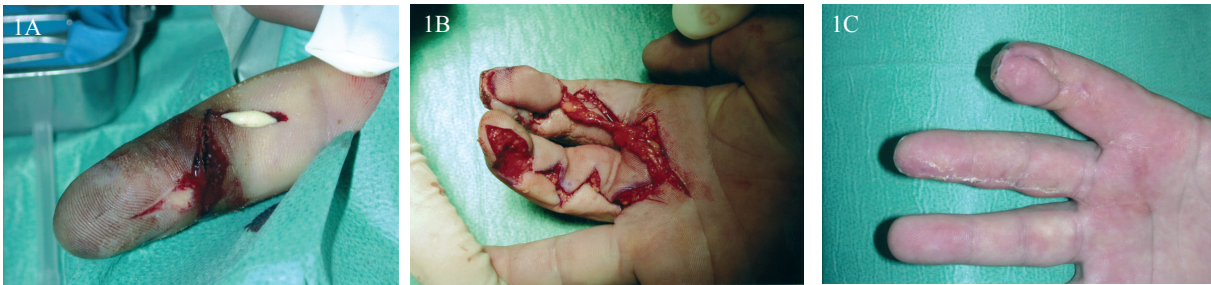

Figure 1.

A. A 32 years old male patient, 12 days after an injection injury of his right index with fuel oil. The patient was treated conservatively in another hospital for the past days and presented to our hospital with a necrotic fingertip and with signs of pyogenic tenosynovitis and septic arthritis of the DIP.

B. The patient underwent arthrodesis of the DIP joint and coverage of the fingertip with a heterodigital island flap.

C. Result 3 months postoperatively.

The mild initial clinical condition of the 3 patients, who came immediately after injury (1-3 hours), deteriorated rapidly in the following 6 hours. All the patients presented with intense pain and widespread edema of the involved digit, one presented with accompanying lymphangitis and 2 patients with delayed admission presented with an infected trauma (Figure 1A). All developed compartment syndrome in the involved digit and in 5 patients the compartment syndrome extended proximally (Figure 3A).

Tissue necrosis was observed around the entrance wound (Figure 1A, 3A, 3B), while one patient, who was admitted 36 hours after injection injury with solvent, presented with generalized symptoms (fever 40,1-41,1 C, leukocytosis and signs of renal failure).

The treatment of these patients in the Department Orthopedic Surgery of Larissa University Hospital was surgical. Under general (1) or regional (7) anesthesia and tourniquet control, surgical exploration of the involved rays, debridement of nonviable tissue and lavage with normal saline solution was performed and repeated, at least once after 2-3 days for each patient, while compartments (of the finger and hand) were released in all patients

(Figure 2B, 3B, 3C). The wound was sutured at a second stage in 5 patients while in the remaining 3 patients further procedures were necessary: amputation of the index finger (1) (Figure 3C, D), arthrodesis of the DIP joint (1), use of heterodigital flaps for fingertip restoration (3) (Figure 1B, C) and full thickness skin grafts (2) (Figure 3D). One patient developed complex regional pain syndrome and was treated with intravenous local anesthetic blockades. All patients received tetanus immunization and intravenous antibiotics (2nd generation cephalosporins and aminoglycosides).

After discharge all patients were evaluated clinically at 6 weeks, 3 and 6 months and at the latest follow-up by measuring the total active and passive range of motion (ROM), and the grip and pinch strength. Pain was evaluated with the visual analogue scale (VAS) with scores ranging from 0 (no pain) to 10 (very severe pain). Patient's subjective opinion was recorded, and the disabilities of the arm, shoulder and hand (DASH) score was also obtained¹⁰. The time to return to previous activities was documented and the functional outcome was ranked as excellent, good, fair or poor.

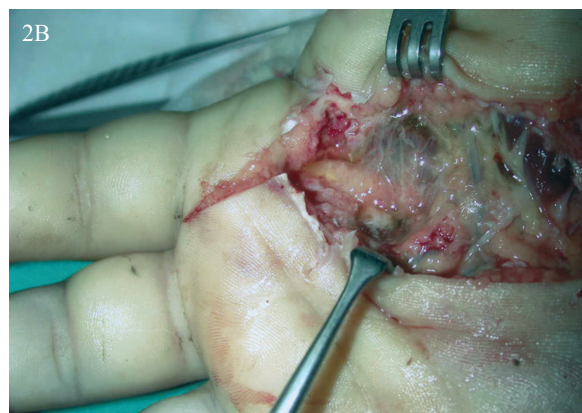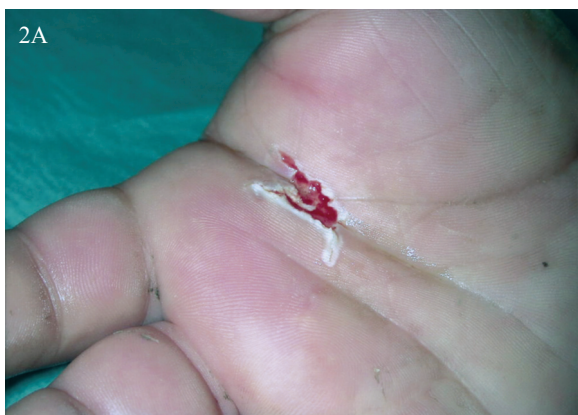


Figure 2.

A. A 49 years old male patient sustained an injection injury with fuel oil from a hydraulic pump and presented with a minor wound of his right palm (2nd ray).

B. The patient was treated immediately with debridement and compartment release. The fuel oil spread proximally and distally following the path of the flexor tendon sheath.

Results

The duration of follow up was 6 to 52 months. The total number of procedures per patient was 2 to 5 (mean 2.7 procedures).

At the latest follow-up (and after reoperations) results were excellent in 5 cases according to the final active ROM. Good results included one arthrodesis of the DIP (Figure 1C), one case of complex regional pain syndrome and one amputation of the index finger, in order to save both the limb and the patient's life, which had a very good functional outcome (Figure 3C, D).

At the latest follow up, the mean VAS score was 0.9 (range 0 to 3) and the DASH score was 8 (0.0-32). All patients returned to their previous occupation and activities 8-16 weeks later (mean 10 weeks).

ger, indicating that the most vulnerable fingers are those contributing to fine motor activity.

The seemingly innocuous initial clinical presentation of injection injuries, with a narrow puncture wound and mild symptoms and signs³, leads to their underestimation not only by the patient, but also by the physicians. This leads to extension of the tissue damage, development of compartment syndrome and finally to functional disability of the limb¹³, or even to amputation⁷, while patients life may also be at risk. The majority (5 of 8) of the patients of the present study presented at the hospital with a significant delay (mean of 3.8 days) and extended damage of the finger or even the palm, confirming the risks of underestimation of these injuries.

The severity of injury and consequently the progn-

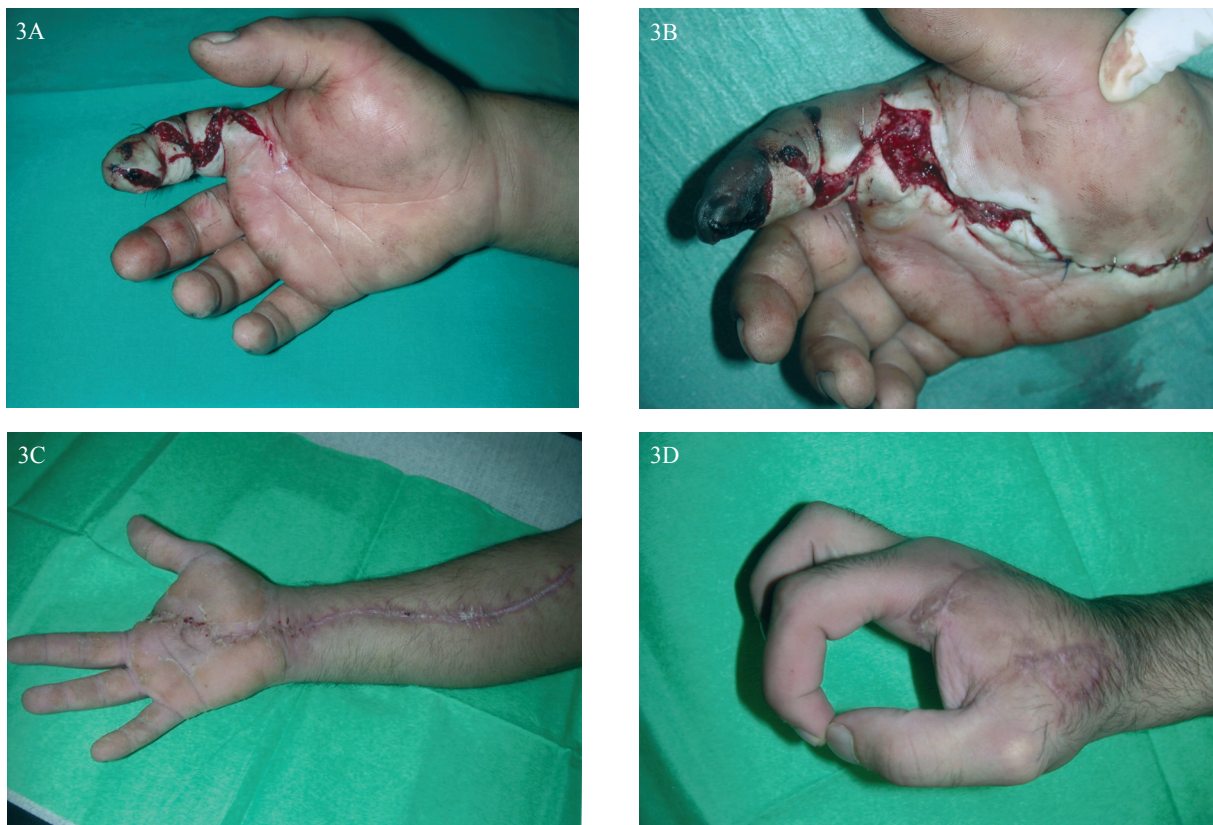

Figure 3.

A. A 25 years old male patient, presented to our hospital 36 hours after an injection injury of his right index with solvent. The patient was treated surgically 20 hours after the injury in another hospital and was transferred to our hospital with signs of systemic toxicity apart of the compartment syndrome of his hand and forearm.

B. The patient underwent extended debridement and compartment release but it was obvious that the index finger was not viable.

C-D. Result 6 months after amputation of the second ray.

Discussion

High pressure injection injuries are uncommon injuries of the hand and according to the literature they affect mainly the non-dominant hand^{1-3,11,12}. However, in all cases of the present series the dominant hand was injured, with the most common site of trauma being the index fin-

ger depend on the toxicity, density, and velocity of the injected substance, the pressure of the appliance, the anatomy and distensibility of the injection site, the possible secondary infection and the interval between injury and treatment¹¹. Amputation rate ranges between 16% and 48% and can even reach 80% in injection injuries

by paint solvents^{2,14}. The amputation risk is lower if wide surgical debridement occurs within 6 hours of injury¹⁴. In the present study the worse clinical presentation, which led to amputation, was due to paint solvent injection. Secondary infection occurred only in cases with late presentation and treatment.

Prompt and correct diagnosis is crucial for the reduction of the catastrophic results^{12,14}. Due to their potential morbidity injection injuries are characterized as “the most urgent of all emergencies of the hand”¹⁵. Physicians must be aware of the emergency of this condition, and must regard all patients who report digital injection as potential amputees at the time of the injury¹¹ and refer them to the appropriately specialized hospital. Almost all of these injuries require expeditious surgery and nonsurgical treatment is exceptional¹. Usually multiple procedures are needed and late reconstruction of the salvaged digit may include the use of flaps to restore good quality pulp tissue to the index finger¹⁶. Antimicrobial therapy including tetanus prophylaxis¹² and use of anticoagulants is recommended, whereas the use of steroids is controversial^{1,9}. Patients and their relatives should be informed of the nature and severity of this injury. Wide surgical exploration, including decompression of tissue compartments, debridement of nonviable tissue and high-volume saline irrigation under general or regional anesthesia is recommended whereas digital blocks should be avoided.

It is suggested that education of high-risk population in the use of high-pressure equipment and of health care workers, would help to reduce the number of these injuries³. These seemingly innocuous injuries should not be underestimated but should alert physicians, so that their destructive consequences are limited.

References

1. Smith GD. High pressure injection injuries. *Trauma* 2005; 7:95-103
2. Schoo MJ, Scott FA, Boswick JA. High-pressure injection injuries of the hand. *J Trauma* 1980; 20:229-238
3. Hart RG, Smith GD, Haq A. Prevention of high-pressure injection injuries to the hand. *Am J Emerg Med* 2006; 24:73-76
4. Jebson PJ, Sanderson M, Rao VK, Engber WD. High-pressure injection injuries of the hand. *Wis Med J* 1993; 92:13-16
5. Valentino M, Rapisarda V, Fenga C. Hand injuries due to high-pressure injection devices for painting in shipyards: circumstances, management, and outcome in twelve patients. *Am J Ind Med* 2003; 43:539-542
6. Lewis HG, Clarke P, Kneasfey B, Brennen MD. A10-year review of high-pressure injection injuries to the hand. *J Hand Surg [Br]* 1998; 23:479-481
7. Wong TC, Ip FK, Wu WC. High-pressure injection injuries of the hand in a Chinese population. *J Hand Surg [Br]* 2005; 30:588-592
8. Neal NC, Burke FD. High-pressure injection injuries. *Injury* 1991; 22:467-470
9. Gutowski KA, Chu J, Choi M, Friedman DW. High-pressure injection injuries caused by dry cleaning solvents: case reports, review of the literature, and treatment guidelines. *Plast Reconstr Surg* 2003; 111:174-177
10. Hudak PL, Amadio PC, Bombardier C. Development of an upper extremity outcome measure: the DASH (disabilities of the arm, shoulder and hand) [corrected]. The Upper Extremity Collaborative Group (UECG). *Am J Ind Med* 1996; 29:602-608
11. Vasilevski D, Noorbergen M, Depierreux M, Lafontaine M. High-pressure injection injuries to the hand. *Am J Emerg Med* 2000; 18:820-824
12. Fialkov JA, Freiberg A. High-pressure injection injuries: an overview. *J Emerg Med* 1991; 9:367-371
13. Cristodoulou L, Melikyan EY, Woodbridge S, Burke FD. Functional outcome of high-pressure injection injuries of the hand. *J Trauma* 2001; 50:717-720
14. Hogan CJ, Ruland RT. High-pressure injection injuries to the upper extremity: a review of the literature. *J Orthop Trauma* 2006; 20:503-511
15. Ebelin M. High pressure injection accident of the hand. *Rev Prat* 1994; 44:2461-2463
16. Pai CH, Wei DC, Hou SP. High-pressure injection injuries of the hand. *J Trauma* 1991; 31:110-112