

## Effects of Intraventricular Locus Coeruleus Transplants on Seizure Severity in Genetically Epilepsy-Prone Rats Following Depletion of Brain Norepinephrine

R.W. Clough<sup>1</sup>, R.A. Browning<sup>2</sup>, M.L. Maring<sup>2</sup>, M.A. Statnick<sup>2</sup>, C. Wang<sup>2</sup> and P.C. Jobe<sup>3</sup>

*Departments of Anatomy<sup>1</sup> and Physiology<sup>2</sup>, Southern Illinois University School of Medicine, Carbondale, IL and Department of Basic Science<sup>3</sup>, University of Illinois College of Medicine-Peoria, Peoria, IL, USA*

### ABSTRACT

Audiogenic seizures (AGS) in genetically epilepsy-prone rats (GEPR) of the moderate-seizure substrain (GEPR-3s) were investigated to determine whether norepinephrine (NE) depletion induced by 6-hydroxydopamine (6-OHDA) microinfusion into the locus coeruleus (LC) could alter the efficacy of intraventricular NE tissue grafts in promoting reductions in seizure severity in AGS. GEPR-3s were stereotaxically infused with 6-OHDA (4µg/side/rat), or vehicle into the region of the LC. Following 6-OHDA treatment all animals were subjected to 3 AGS tests. GEPR-3s seizure severities were increased in 39.5% of the animals after microinfusion of 6-OHDA into the region of the LC. Following the third AGS test, each rat was stereotaxically implanted with 17 gestational day rat fetal tissue obtained from the dorsal pons and containing the primordia of the LC or with tissue obtained from the neocortex or were sham-grafted. Subsequent to grafting, rats were subjected to 3 additional AGS tests. 53% (10/19) of 6-OHDA treated GEPRs showed a significant reduction in seizure severity following transplantation of fetal LC tissue. In contrast, only 20% (1/5) of GEPRs infused with saline rather than 6-OHDA showed a reduction of seizure severity following fetal LC transplantation. NE content in the cortex and pons/medulla was decreased by 78% and 46%

respectively following 6-OHDA microinfusion into the LC. Prominent grafts with numerous TH positive neurons and neurites were present within the third ventricle of grafted animals, while cortex grafts contained no TH immunostained structures. These findings suggest that the efficacy of fetal LC tissue to promote reductions in seizure severity in GEPRs is increased following depletion of central NE by microinfusion of 6-OHDA.

### KEY WORDS

audiogenic seizures, neurotransplantation, locus coeruleus, 6-hydroxydopamine, norepinephrine, epilepsy, rats

### INTRODUCTION

Therapeutic potential in transplantation neurobiology is being explored in several animal models of neurological disorders including models of Parkinson's disease /17,28,31,39/, Huntington's disease /13,18/, Alzheimer's disease /33,35/, and epilepsy /1,10,11,25/. For Parkinson's disease, progression of research on the potential beneficial effects of neurotransplantation has entered, perhaps prematurely /15,34/, the human clinical arena /24,26/. The hypothetical potential of neurotransplantation as a therapeutic approach to several neurological disorders is appreciable.

The genetically epilepsy prone rat (GEPR) represents a natural animal model of epilepsy /19/. Currently, there are two independently derived strains of GEPR: GEPR-3s which consistently display an audiogenic seizure (AGS) score of 3, and GEPR-9s which consistently display an AGS score

---

Reprint address:

Rich Clough, Ph.D.

Department of Anatomy

Southern Illinois University School  
of Medicine-Carbondale

Carbondale, IL 62901, USA

of 9 according to the seizure-rating scale developed by Jobe /20/. GEPR-3s have running-bouncing clonic seizures and GEPR-9s exhibit severe tonic seizures with full hindlimb extension. Seizure predisposition in these animals is manifested by enhanced susceptibility to a variety of seizure-invoking stimuli, including sound, heat, convulsive drugs and electroshock /9,32/. The basis of seizure predisposition and the determinants of severity of seizures experienced by GEPRs are presently unknown, but are hypothesized to result from regionally-specific aberrant neurotransmitter profiles in the brains of these animals /14,21/.

The noradrenergic neurotransmitter system appears to serve as a determinant of seizure severity in the GEPR brain /20,23/ and pharmacological evidence supports the hypothesis that there is an inverse relationship between AGS severity and the concentration of norepinephrine (NE) in the synaptic cleft. Treatments that decrease the availability of NE at its receptors enhance both seizure susceptibility and severity in the GEPR. For example, drugs which deplete brain NE by interfering with the vesicular storage (i.e., reserpine) are demonstrated to cause an increase in seizure severity /20/. Inhibition of NE synthesis plus displacement of NE from its storage vesicle can further intensify AGS /20/. Similarly, inhibition of NE synthesis coupled with cold stress to produce depletion of NE also will increase AGS severity in GEPRs /20/. We and others have reported that depletion of central NE using the catecholaminergic neurotoxin, 6-hydroxydopamine (6-OHDA), increases the severity of seizures in a significant percentage of GEPR-3s /5,8/. Conversely, treatments that are designed to increase the concentration of NE at its receptors appear to exert anticonvulsant effects on AGS. For example, excessive formation of NE by precursor (L-dopa) administration is known to reduce seizure intensity in GEPRs /22/, and blocking re-uptake of NE, which leads to an increase in synaptic cleft NE concentration, also reduces seizure severity in the GEPR /20,21/. Widespread decrements in NE content are found in GEPR brains /21/ and deficiencies in NE are present in naive (i.e., never having experienced a seizure) GEPRs as well as premature GEPRs (15 days of age) prior to development of seizure susceptibility /12/. These

data suggest that the deficiency in NE content is due to an innate disorder and not to the seizures *per se*. Clearly, there exists a deficiency in the noradrenergic system which parallels propensity for seizures in the GEPRs /20,21/.

We have previously reported that transplantation of fetal tissue containing the locus coeruleus (LC), a pontine nucleus where the majority of brain NE is synthesized, into the third ventricle results in a reduction in seizure severity in a limited number of GEPR-9s and GEPR-3s /11/. Immunohistochemical analyses of the grafted animals in this study /11/ revealed an abundance of neurons staining for tyrosine hydroxylase (TH, the rate-limiting enzyme in catecholamine biosynthesis) within the grafted tissue. Other investigators /1,25/ have shown that fetal LC grafts can effectively reduce seizure susceptibility in rats whose susceptibility to kindled seizures was increased by prior NE depletion. Moreover, functional responsiveness of LC tissue grafts has been demonstrated during kindled seizures /2/. In another model, the induction of seizures by pentylentetrazol in fimbria-fornix lesioned animals is facilitated by grafting acetylcholine-rich basal forebrain cell suspensions into the hippocampus /10/. These studies /1,2,10,11,25/ clearly demonstrate the modulatory potential of fetal grafts in three distinct models of epileptiform activity.

There is evidence which suggests that the degree of integration between fetal grafts and host animals may in part depend on a synaptic void in the host animal /29/. For example, NE axons from fetal LC grafts in the anterior chamber of the eye hyperinnervate co-grafts of hippocampal tissue when the host superior cervical ganglion (SCG) is lesioned /29/. Typically, axons from the host SCG invade and innervate intraocular-grafted hippocampal tissue; however, when the SCG is lesioned, there is a resulting synaptic void in the grafted hippocampus. Without competition from host NE fibers from the SCG, co-grafts of fetal LC innervate the hippocampal co-grafts with NE axons to a much greater extent /29/. Additionally, it has been shown that neurite outgrowth *in vitro* from catecholaminergic explant cultures is much reduced in the presence of exogenously administered L-dopa, a precursor of NE /36/. These findings support the hypothesis that there is a type of

feedback inhibition on neurite outgrowth and axon arborization from fetal grafts in the presence of synaptic competition or neurotransmitter feedback from the host. Therefore, inasmuch as LC grafts have been shown to reduce seizure severity in limited numbers of GEPR-9s and GEPR-3s /11/, NE depletion has resulted in increased propensity for seizures in rats /5,8/ and fetal grafts have been shown to exhibit greater neurite growth in the absence of synaptic competition /29/, the present study was designed to determine whether the incidence of reduced seizure severity following neurotransplantation of fetal noradrenergic neurons could be increased in GEPR-3s after depletion of brain NE.

## MATERIALS AND METHODS

### Animals

Adult male genetically epilepsy-prone rats (GEPRs) were obtained from the colony at the University of Illinois College of Medicine, Peoria (Peoria, IL). After arrival, each rat was pretested on three separate occasions for audiogenic-induced seizures (AGS) to confirm that they were GEPR-3s. The seizure severity was scored using the seizure-rating scale described by Jobe /20/, which assigns scores from 0 (no seizure) to 9 (generalized tonic-seizure with complete hindlimb extension) with each score above 0 representing an increasingly severe seizure. GEPR-3s display seizures characterized by two running phases culminating in clonus of the forelimbs and hindlimbs. Testing for AGS involves placing each rat into a round (40 cm) Plexiglass arena and exposing them to a bell tone of 100 db intensity for 60 seconds. This procedure induces consistent seizures of intensity 3 in GEPR-3s and 9 in GEPR-9s. Only GEPR-3s were used in the present study. The latency to onset of running behavior and convulsion was timed and the seizure severity was scored and recorded for each rat.

### Experimental protocol

After preliminary AGS-testing of each rat for confirmation of seizure display, rats were divided into the following two groups: 6-OHDA microinfused (n=38), and saline microinfused (n=7).

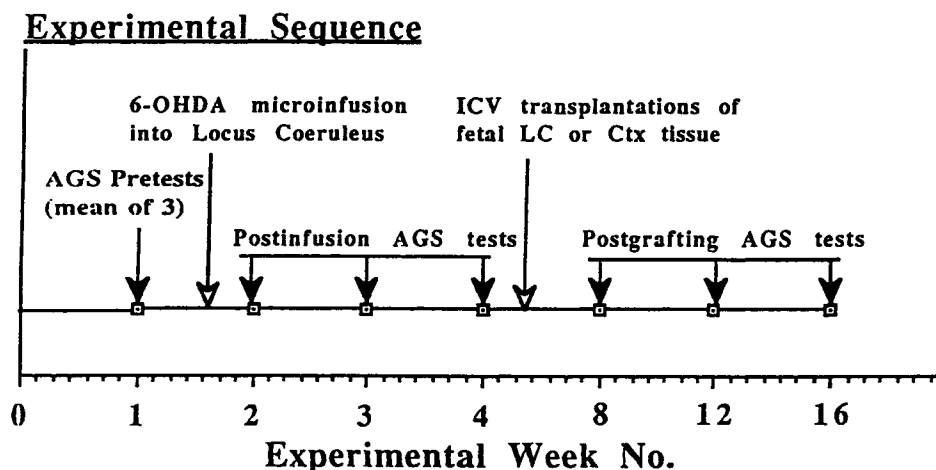
Animals from each of these two groups were subsequently divided into the following subgroups: 6-OHDA-infused, LC-grafted (n=19); 6-OHDA-infused, cortex-grafted (n=10); 6-OHDA-infused, sham-grafted (n=9); saline-infused, LC-grafted (n=5); saline-infused, sham-grafted (n=2). The timing of pretests, microinfusions, post-microinfusion tests, grafting and post-grafting tests are shown in schematic form in Figure 1. Briefly, animals were pretested upon delivery to insure that they were GEPR-3s. After pretesting, rats were microinfused with either saline or 6-OHDA as described below. After microinfusions, animals were again tested on three separate occasions to determine whether seizures were more severe than the pretest seizure scores. After the third test, animals received grafts from either the fetal LC, the fetal neocortex, or were sham-grafted. After grafting, animals were again AGS tested three times to determine whether grafting would alter the severity of seizures after central noradrenergic depletion. At the end of the study, animals were processed for either general histology (n=20) with morphometric measurement of graft sizes, neurochemistry (n=14) or immunocytochemistry of tyrosine hydroxylase (n=11) as described below.

### NE depletion

Following pretesting, animals were anesthetized with chloral hydrate (400 mg/kg, i.p.) and subjected to bilateral stereotaxic microinfusion of 6-hydroxydopamine (6-OHDA, Sigma Chem., St. Louis, MO; 4µg/side in 0.5 µl vehicle) or vehicle (0.09% saline, 0.1% ascorbic acid) into the LC using a Harvard infusion pump. Coordinates for microinfusions were taken from a rat brain atlas /14/ and were: anterior-posterior from the interaural line (IAL) = -2.3 mm; lateral from midline = 1.2 mm; ventral from dura = -6.6 mm.

### Grafting

Following decapitation of pregnant Sprague-Dawley rats, uteri containing pups (17 days gestation) were removed and placed into a Petri dish containing a balanced salt solution (Hank's, GIBCO Labs, Grand Island, NY) on ice. Under a dissecting microscope, each fetal brain was removed



**Fig. 1:** Temporal sequence of experimental procedures for the present study. First, a series of 3 audiogenic seizure pretests were evaluated in order to confirm that the animals were GEPR-3s. The means of these three tests are represented as AGS test number 1. Following these tests, animals were infused with 6-OHDA directly into the LC. A series of three AGS post tests were evaluated at 2, 3 and 4 weeks after 6-OHDA. After the fourth test, animals were subjected to ICV grafting of fetal LC or CTX tissue or were sham grafted. Subsequent to grafting, rats were again AGS tested three times at 4, 8 and 12 weeks after grafting.

and the anterior lip of the pontine flexure on each side or small pieces of occipital cortex were excised similar to the surgical procedure described by Björklund /3/. Fetal tissues were aspirated into spinal needles for subsequent transplantation. Adult GEPR-3 hosts were anesthetized with chloral hydrate (400 mg/kg, i.p.) for neurosurgery. After reflection of the scalp and drilling a small burr hole through the calvaria, a spinal needle containing fetal LC or cortex tissue was stereotaxically directed into the third ventricle using coordinates: AP=7.0 from IAL; L=0 from midline; V=9.0 from dura; incisor bar set at -3.3 mm /30/. Tissue was pressure ejected very slowly (over a 5 minute interval). Sham grafts consisted of an identical infusion of the balanced salt solution into the third ventricle. After infusion, the spinal needle was left in place for 5 minutes before removal. The burr hole was then covered with gelfoam, and the scalp sutured with 9 mm wound clips. After surgery, GEPRs were allowed to recover under supervision.

#### Immunohistochemistry

Subsequent to final AGS testing, the brains of 11 rats from either the 6-OHDA/LC grafted, the

saline/LC grafted or the 6-OHDA/ctx grafted groups were subjected to immunohistochemistry to determine whether noradrenergic neurons were present in the grafted tissue. Rats were deeply anesthetized with sodium pentobarbital (50 mg/kg, i.p., Butler labs, Columbus, OH) and transcardially perfused with phosphate buffered saline (PBS, pH 7.4) followed immediately by perfusion of 200 ml, ice-cold paraformaldehyde (4%) in PBS. Brains were removed and post fixed in fixative for 1.5 h, and transferred to cold 25% sucrose for 48 h. Brains were sectioned at 40  $\mu$ m thickness on a cryostat and free-floating sections were immunohistochemically processed for localization of tyrosine hydroxylase (TH) using a biotin-avidin method (ABC kit, Vector Labs, Torrance, CA). A polyclonal primary antiserum for TH was obtained from Eugene Tech Int. (Allendale, NJ) and used at a dilution of 1/15,000 (in 0.1M PBS, 0.1% Triton-X, 0.1% BSA, pH 7.4). After 48 h incubation at 4°C and subsequent processing with the ABC kit, the reaction was visualized using 3,3'-diaminobenzidine tetrahydrochloride in the presence of hydrogen peroxide. The presence of TH-positive neuron somata and fibers in the host and grafted tissues was recorded for each animal so processed.

### NE determination

Norepinephrine content was measured in order to assess the degree of depletion of central NE following 6-OHDA or saline microinfusion. In 14 animals not used for immunohistochemistry, the content of NE in the brains of 6-OHDA treated and control rats was determined by high performance liquid chromatography (HPLC) with electrochemical detection. Brain regions were dissected on an ice-cold plate, wrapped in aluminum foil and frozen in liquid nitrogen until assay. The pons/medulla was isolated as a representative brainstem sample and the cerebral cortex was isolated as a representative forebrain sample. Brain samples were homogenized in 4 ml 0.2N perchloric acid (PCA) containing 80 ng/ml 3,4-dihydroxybenzylamine (DHBA) and transferred to glass centrifuge tubes. After centrifugation, 2.0 ml of the supernatant from each sample was shaken with 10 ml of 0.5 M TRIS buffer (pH 8.6) containing 50 mg of acid-washed alumina and 10  $\mu$ l of sodium metabisulfate. After centrifugation and removal of the supernatant, the alumina was washed with 1.0 ml TRIS buffer (pH 7.0). Finally, the NE was eluted from the alumina by shaking in the presence of 0.5 ml 0.2N PCA for 20 min. The eluate was then centrifuged at 13,000 g for 3 min and 50  $\mu$ l was injected into a rheodyne injector connected to a bioanalytical HPLC system. The concentration of NE was determined by comparing peak heights of NE in samples to those of NE in standards (20 to 80 ng/ml) run through the assay simultaneously. The HPLC system consisted of a 5  $\mu$ m biophase C18 reverse-phase column (15 cm by 4.6 cm, Beckman) and a glassy carbon electrode with the applied potential set at 460 mV vs a Ag/AgCl reference electrode. The mobile phase contained citric acid (14.6 mM), Na<sub>2</sub>HPO<sub>4</sub> (4.9 mM), octane sulfonate (100.8 mM) and ethylenediaminetetraacetic acid (EDTA, 55.3 mM) in 3.0% methanol.

### Data analysis

Statistical analysis of changes in seizure severity was carried out using non-parametric tests. The incidence of changes in seizure severity following microinfusions of 6-OHDA or saline was analyzed by a coded chi-squared test. The incidence of

changes in seizure severity preceding and following grafting treatments was analyzed by a contingency table analysis. Differences in NE content in either the cortex or the pons-medulla of randomly selected animals were analyzed by Student's t-test. The presence of TH positive perikarya and fibers within grafted LC tissues of selected animals was noted. Comparisons of graft sizes between Ctx and LC tissue grafts were made by Student's t-test.

## RESULTS

### NE content after 6-OHDA infusions

NE content in the brainstem and cerebral cortex is shown in Figure 2. There was a 78% reduction of NE in the forebrain ( $p < 0.05$ ) and a 46% reduction of NE in the brainstem ( $p < 0.05$ ) of animals receiving an LC microinfusion of 6-OHDA.

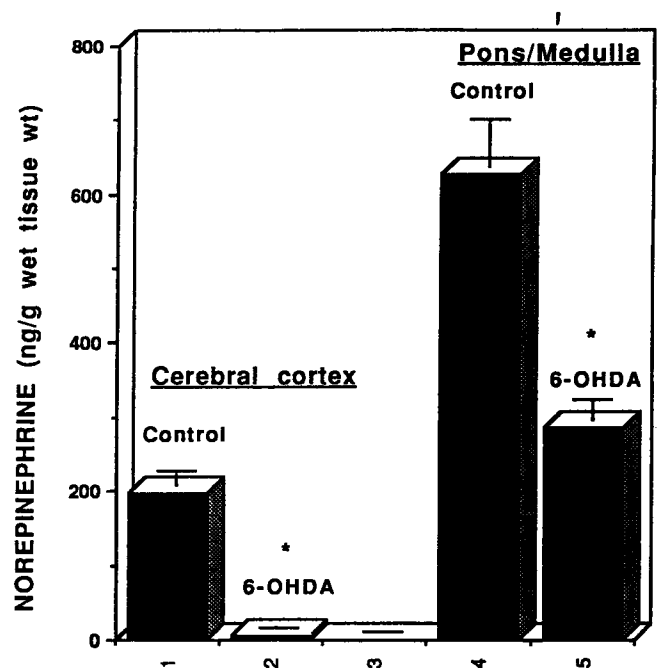


Fig. 2: The concentration of norepinephrine in the cerebral cortex and the combined pons/medulla in animals treated with intra-LC, 6-OHDA or saline. NE content was significantly reduced in both the cortex and the pons/medulla in rats receiving 6-OHDA. (Mean  $\pm$  S.E.M. \*=difference between controls and 6-OHDA group in each respective brain area,  $p < 0.05$ .)

Although only about 40% of the animals treated with 6-OHDA experienced a subsequent increase in seizure severity (see below), all of the examined brains of 6-OHDA treated animals were consistently depleted of NE (Fig. 2).

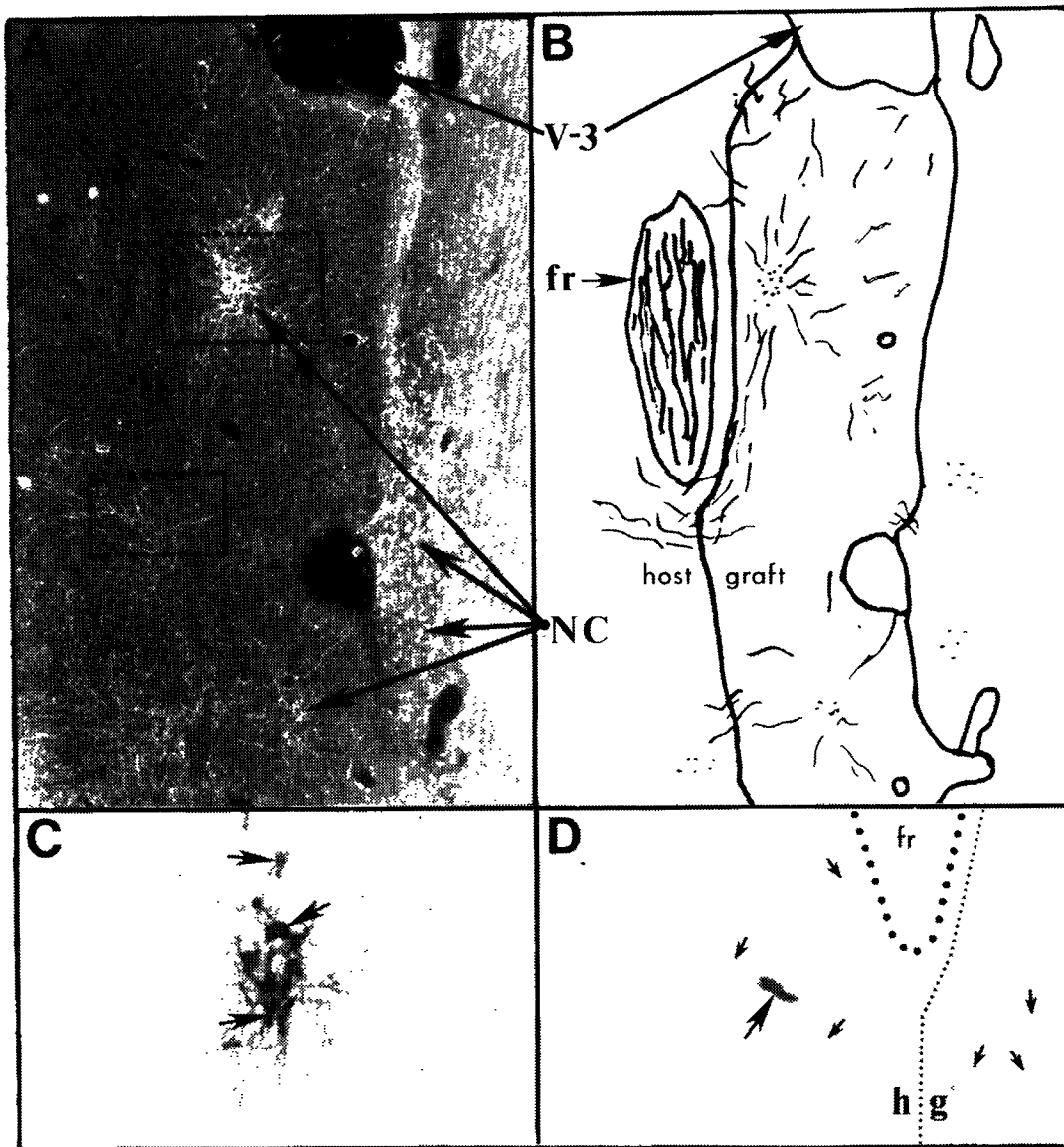
### Histology of grafts

An example of an LC graft in an animal of the present study is shown in Figure 3. Immunohistochemical examination of grafted brains revealed that LC grafts within the third ventricle contained numerous TH positive perikarya and dense plexuses of TH positive fibers while Ctx grafts were devoid of TH positive profiles. In some of the LC grafted animals, the cytoarchitecture of TH positive areas within the grafts resembled that of the LC *in situ*. LC or Ctx grafts were found in the third ventricle of all 11 rats analyzed with immunohistochemistry (ICC) and all the LC grafts analyzed by ICC were found to contain numerous TH-positive somata and neurites. A morphometric analysis was conducted on 5 cortical-tissue grafts and 8 LC-tissue grafts from grafted animals not processed for ICC or neurochemistry. Grafts derived from the occipital cortex were significantly larger than those from the region of LC (Table 1).

### Seizure scores

There were four typical behavioral responses across the treatment groups: 1) rats which displayed an increase in seizure severity following 6-OHDA microinfusion, and a subsequent reduction in seizure severity following grafting (Figure 4a). This response was called exacerbated/corrected; 2) rats which demonstrated an increase in seizure severity following 6-OHDA microinfusion with no reduction in seizure severity following grafting (Figure 4b). This response was called exacerbated/noncorrected; 3) rats which showed no increase in seizure severity after 6-OHDA treatment, but who did show a reduction in seizure severity after grafting (Figure 4c). This response was called nonexacerbated/corrected; and 4) rats which demonstrated no increase in seizure severity following 6-OHDA microinfusion and no reduction in seizure severity after grafting (Figure 4d). This response was called nonexacerbated/noncorrected. The number of

animals in each treatment group displaying each of these four responses are indicated in Table 2. With reference to change in seizure severity following microinfusions of 6-OHDA into the LC, 15 of the 38 animals (39.47%) displayed a significant increase in seizure severity following 6-OHDA treatment ( $p < 0.0418$ ). In the control group, 0 of the 7 had altered seizure severity following saline microinfusion. Figure 5 shows the percentage of animals in which grafting resulted in a reduction of seizure severity. As shown in Figure 5, only 1 of the 10 GEPR-3s microinfused with 6-OHDA and transplanted with cortex tissue showed a decrease in seizure severity subsequent to grafting. Similarly, 1 out of 9 6-OHDA microinfused and sham-transplanted GEPR-3s showed a slight decrease in seizure severity after surgery. The difference in the incidence of change of seizure severity between the cortex- and sham-transplanted groups was not significant ( $p = 0.5957$ ). In contrast, 53% (10/19) of the 6-OHDA treated animals transplanted with fetal LC tissue showed a significant decrease in seizure severity after transplantation. The incidence of change in seizure severity of the LC transplanted group compared to the cortex- and sham-treated groups was significant ( $p < 0.0167$ ). Of the 5 saline-infused GEPR-3s transplanted with LC tissue, no rats showed increased severity following saline microinfusion; however, 1 of 5 LC-transplanted rats showed a marked reduction in seizure severity following grafting of fetal LC. Finally, although the incidence of reduction in seizure severity in LC transplanted animals receiving 6-OHDA compared to those receiving saline was not significantly different ( $p > 0.05$ ), 53% (10/19) of the 6-OHDA treated animals showed post-LC-grafting reductions in seizure severity while only 20% (1/5) of saline treated animals showed post-LC-grafting reductions in seizure severity. Of the two rats microinfused with saline and sham transplanted, there were no effects of either treatment on seizure severity. Figure 6 shows the actual degree of the seizure reduction following LC grafting in 6-OHDA treated rats. Panel A shows the data for all animals grafted with fetal LC ( $n = 19$ ), while panel B shows data only from those animals that had a reduction in seizure severity following grafting (i.e., corrected animals only,  $n = 10$ ). In both groups, the pretest score



**Fig. 3:** Panel A shows a darkfield photomicrograph of a third ventricular graft of fetal LC at 16 weeks post-transplantation (45x magnification). Panel B represents a camera lucida drawing of Panel A. The graft fills the majority of the third ventricle except for the dorsal aspect (labeled V-3). Numerous tyrosine hydroxylase-positive neuron clusters (NC) were observed in both the host and the grafted tissue. Panel C is an enlarged brightfield photomicrograph of a boxed insert in Panel A (dotted rectangle labeled C). This photomicrograph shows typical neurons (arrows) within these neuron clusters. Panel D is an enlargement of another boxed insert in Panel A (labeled D), which shows the host (h)-graft (g) interface, depicted by the fine dotted line, immediately subjacent to the fasciculus retroflexus (fr) which is indicated by the heavy dotted line. Numerous axons (small arrows) and one neuron (large arrow) are seen in Panel D (Panels C and D are approximately 150x magnification).

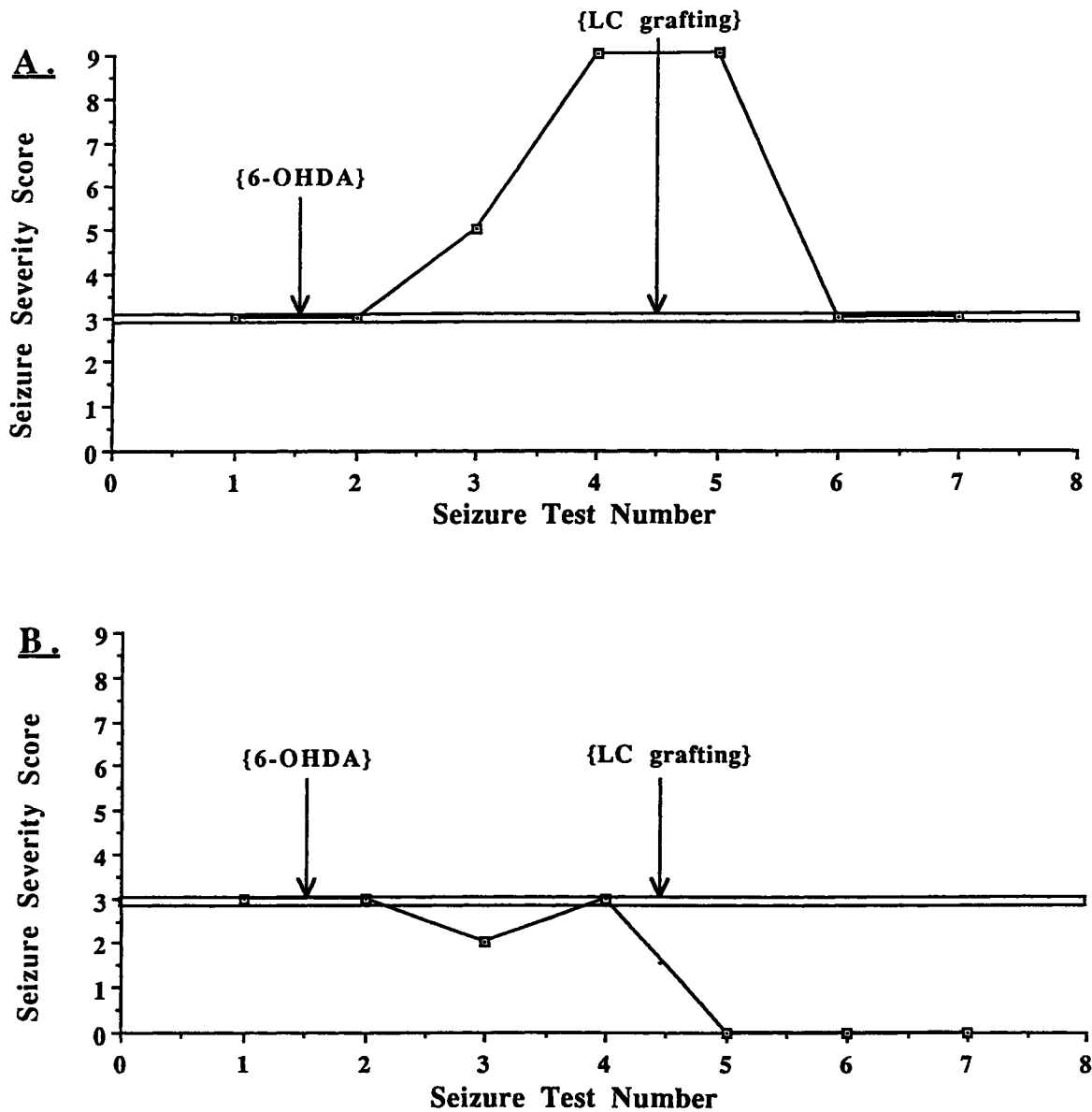
**TABLE 1**  
Approximate sizes of cortical tissue (Ctx) or locus coeruleus (LC) tissue grafts within the third ventricle (mean  $\pm$  S.E.M.)

Brain region	n	Cross sectional area ( $\mu\text{m}^2$ )	Antero/postero diameter ( $\mu\text{m}$ )
LC	8	516 $\pm$ 70	455 $\pm$ 67
Ctx	5	1,783 $\pm$ 629*	730 $\pm$ 137*

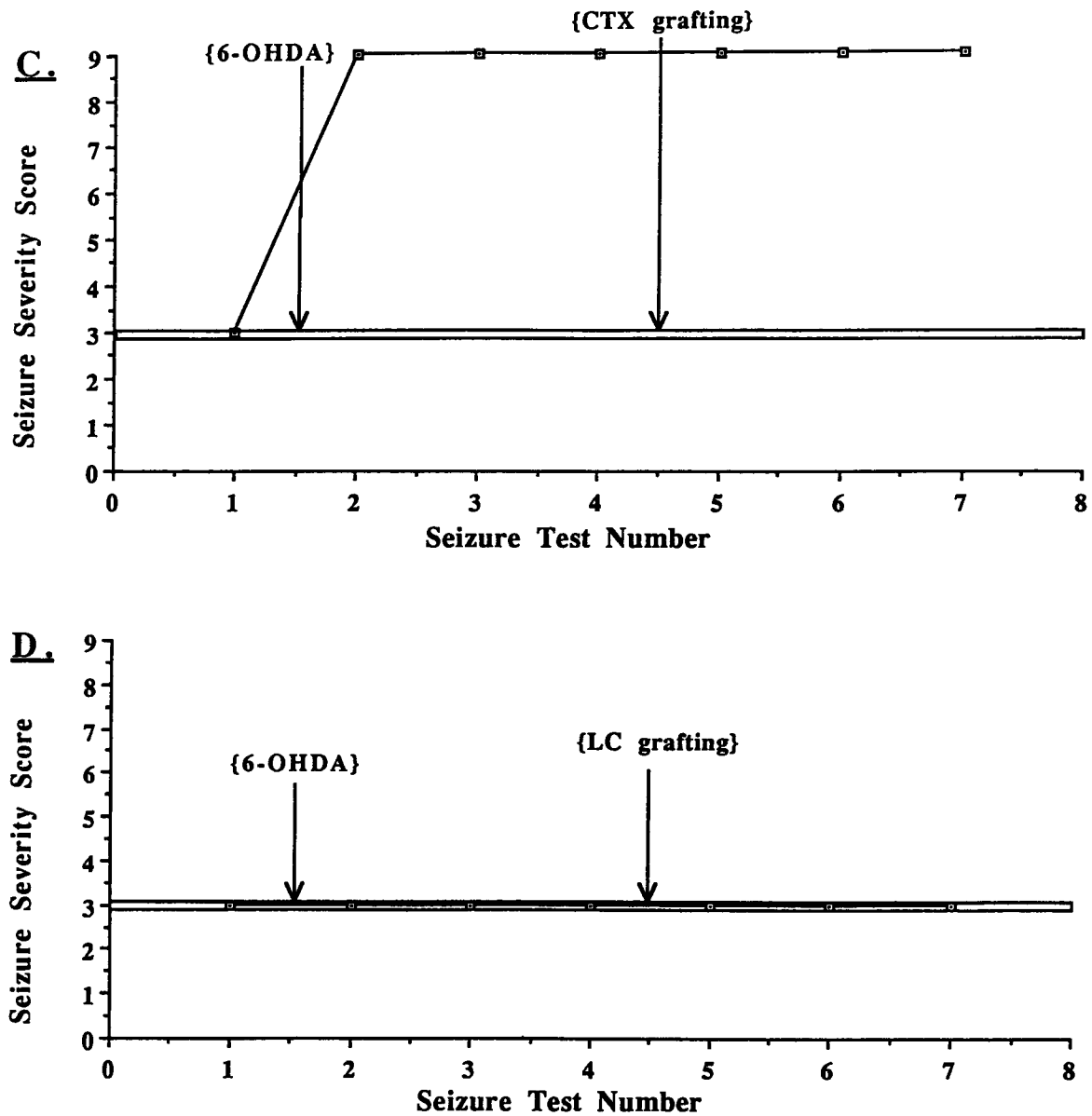
n = number of rats analyzed (the number of sections of Ctx and LC grafted animals were 73 and 91 respectively)

\* =  $p < 0.05$

means were 3. As shown in panel A, following 6-OHDA, the seizure mean scores were significantly elevated to 4.7 across all animals (however, only 39% were elevated in seizure severity,  $p < 0.05$ ). After grafting, the mean seizure score of all animals receiving LC grafts was 4.2 (again, this reflects that only 53% of the animals were corrected in seizure severity). The post-grafting scores were not significantly different from either the pretest or the post-6-OHDA treatment scores. Panel B shows the degree of seizure severity reduction for those animals that were corrected ( $n=10$ ). The degree of exacerbation of these animals was not as high as







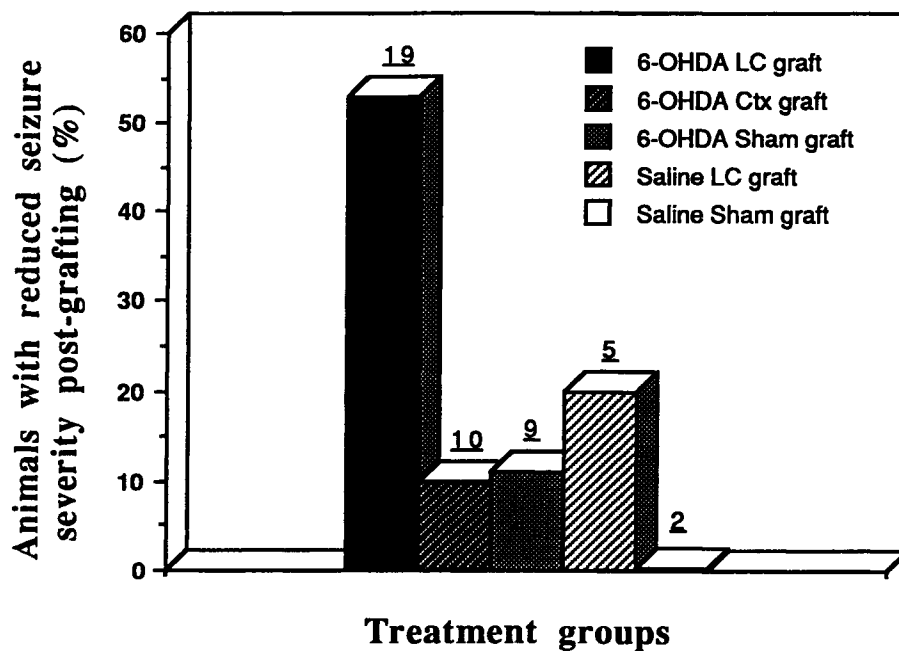
**Fig. 4:** Four graphs (A-D) each representing an individual showing one of the four typical behavioral responses of rats following 6-OHDA administration and fetal brain tissue grafting. The data in Panel A (representing animal GEPR-3, s2-#3) showed an increase in seizure severity from a score of 3 to a score of 9 by the third test after 6-OHDA. This represents an increase in severity from a moderate clonic seizure to a severe tonic-clonic seizure with full hindlimb extension. Subsequent to grafting fetal LC, the severity of seizures was again reduced from a score of 9 to the previous score of 3. Panel B shows the data from an animal (GEPR-3, s1-#2) who did not show an increase in seizure severity after 6-OHDA but who did show a reduction in seizure severity from a pregrafting score of 3 to a score of 0, representing a complete absence of seizure in response to the audiogenic stimulus. Panel C shows the data from an animal (GEPR-3, s4-#16) who showed an increase in seizure severity following 6-OHDA treatment, but who did not show any reduction in seizure severity up to 12 weeks following grafting of fetal cerebral cortex. Panel D shows the data from an animal (GEPR-3, s3-#24) who did not show an increase in seizure severity following 6-OHDA, nor was there a reduction in seizure severity following grafting.

**TABLE 2**  
Number of animals by treatment group which showed the following response patterns

Treatment Group (n)	Ex	Ex/Corr	N-Ex/Corr	Ex/N-Corr	N-Ex/N-Corr
6-OHDA/LC (19)	9/19	4	6	5	4
6-OHDA/Ctx (10)	4/10	1	1	3	5
6-OHDA/Sham (9)	2/9	1	0	1	7
Saline/LC (5)	0/5	0	1	0	4
Saline/Sham (2)	0/2	0	0	0	2

Ex refers to exacerbated seizure severity following 6-hydroxydopamine (6-OHDA or saline), Corr refers to corrected (reduced) seizure severity following grafting (N-refers to non-).

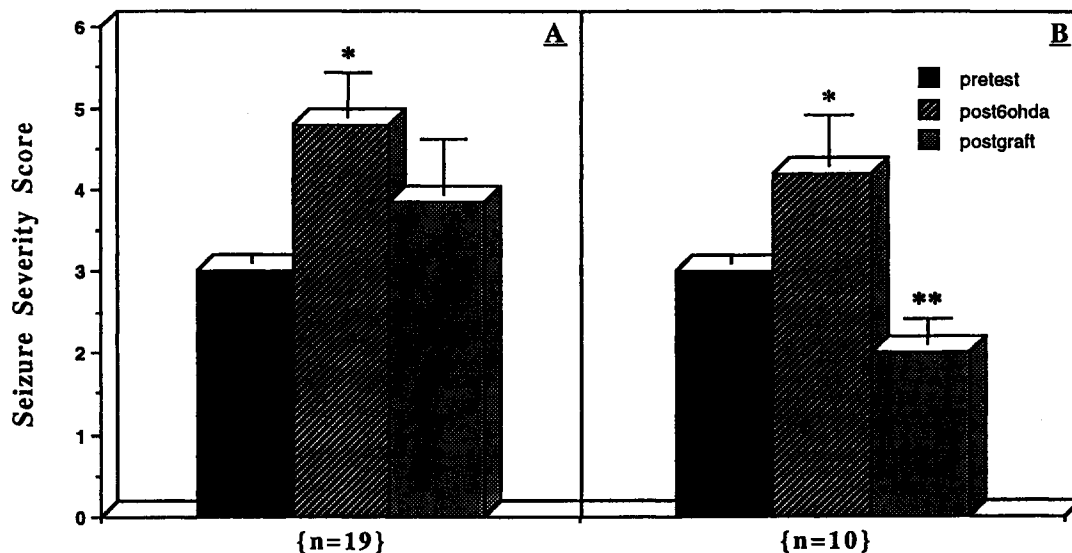
The response patterns Ex/Corr, N-Ex/Corr, Ex/N-Corr, N-Ex/N-Corr correspond to representative animals shown in Figure 4 A-D.



**Fig. 5:** The percentage of animals who showed a reduction in seizure severity subsequent to grafting or sham treatment. The incidence of reduction in seizure severity was highest in the 6-OHDA, LC transplanted group ( $p < 0.0167$ ).

that for the entire group ( $n=19$ ) due to the fact that some of these animals were not exacerbated by 6-OHDA yet all these animals' seizure severity scores were reduced following grafting (i.e., some to below pretest values). Following grafting of LC, seizure scores were significantly lower than both the

pretest and post 6-OHDA treatment scores ( $p < 0.05$ ). Latencies to the onset of running behavior and convulsions were not altered subsequent to brain infusions or transplantation in rats of any of the groups.



**Fig. 6:** Seizure severity scores (mean of three separate tests  $\pm$  S.E.M.) in all LC grafted animals ( $n=19$ , Panel A) and those LC grafted animals which showed a reduction in seizure severity following grafting ( $n=10$ , Panel B). In all animals, the pretest score was 3. Panel A: Following 6-OHDA, the severity of seizure in all animals increased significantly from a mean of 3 to 4.7 in the entire group (note, however, that only 39% of these animals were exacerbated following 6-OHDA). The effects of LC grafts on seizure severity across the entire group were not significant in that the scores after grafting were not significantly different from those after 6-OHDA; however, these scores were also not different from the pretest values ( $*=p<0.05$  from pretest scores only, ANOVA [ $F_{2,18} = 5.06$ ]). Panel B. In those 10 animals which showed reduction in seizure severity, 6-OHDA significantly increased the severity of seizure from 3 to 4.2 (note, however, that not all of these animals were exacerbated following 6-OHDA). After LC grafting, those 10 animals that were corrected had significantly lower seizure severity scores than animals at pretest and following 6-OHDA ( $*=p<0.05$  from pretest and post grafting;  $**=p<0.05$  from pretest and post 6-OHDA: ANOVA [ $F_{2,9} = 10.37$ ]).

## DISCUSSION

It is well documented that seizure severity in the GEPR is inversely correlated with brain NE level /14,20,21,23/. Previous studies in this laboratory /8/ and others /5/ have demonstrated that depletion of brain NE in normal rats and GEPR-3s using the catecholamine neurotoxin 6-OHDA results in an increase in seizure severity in a significant number of these animals. In the present study, analysis of NE content in the cortex, an area of the brain which receives the majority of its noradrenergic terminals from the LC, revealed that 6-OHDA microinfusion into the LC caused a 78% reduction in cortical NE. The 46% depletion of NE content in the brainstem as a result of microinfusion of 6-OHDA into the LC is also significant. It should be recognized that the remaining catecholamine nuclei in the brainstem, including those in the diffuse lateral tegmental system, remain intact. The effectiveness of the LC infusions is clearly demonstrated by the marked depletion of NE (78%) in the terminal regions of

these neurons (i.e., the cerebral cortex). Although the extent of NE depletion in terminals of LC neurons innervating the brainstem following LC lesion could not be dissected out, it is presumed that it would be similar to the depletion of NE in the cortex which is also innervated by the LC. Thus, in light of the remaining catecholamine cell groups in the brainstem, the 46% depletion following LC microinfusion of 6-OHDA appears to represent a rather large depletion of NE in those brainstem terminal fields which originate in LC neurons. The present data demonstrate that depletion of NE in GEPR-3s following the microinfusion of 6-OHDA into the LC is associated with an increase in the severity of seizures in approximately 40% of GEPR-3s. However, other studies in our laboratory have shown a greater incidence of seizure exacerbation (i.e., 50-70% of animals) following LC infusions of 6-OHDA /8/. The reason for the lower incidence of seizure exacerbation in the present study compared to previous work /8/ is unknown; however, the degree of NE depletion between the

studies was also different. In the present study, the intra-LC microinfusion of 6-OHDA reduced the content of NE in the cortex by 78%, while in the previous study /8/, cortical NE depletion was approximately 90%. The differences between the two studies in degree of central NE depletion after intra-LC microinfusion of 6-OHDA may account for the differences in the incidence of seizure exacerbation. Additionally, because of the small size of the LC as a target for microinfusion, differences between studies in central NE depletion may have resulted from subtle differences in location of the cannula tip within the surround of the LC. Interestingly, 6-OHDA-induced LC lesions have also been shown to significantly increase the severity of audiogenic-like seizures in normal rats rendered susceptible to sound-induced seizures by microinjection of N-methyl-D-aspartate (NMDA) into the inferior colliculus /7/. In that study /7/, as in the present one, some rats displayed a marked depletion of NE but failed to exhibit an increase in seizure severity following 6-OHDA treatment. The reason for this remains unknown, although it is conceivable that NE depletion in a crucial region not assayed *per se* is responsible for regulating seizure predisposition in the GEPRs and NMDA infused rats. Perhaps a better correlation between NE depletion and seizure exacerbation would be obtained should this hypothesized crucial region be examined.

A number of studies have reported beneficial effects of host NE or NE-tissue transplants on seizure activity in other models of epilepsy or epileptiform activity. Fetal LC cell suspensions transplanted into the hippocampal formation of adult rats suppress the onset and the progression of kindling-induced epilepsy in rats made hypersensitive to kindling by noradrenergic depletion /1,25/. Hippocampal tissue grafts in the anterior chamber of the eye are protected from epileptiform activity induced by penicillin, when adrenergic afferents to the grafts are activated /16/. Tonic inhibitory neurotransmission, as assessed by electrophysiology, can be reinstated in the hippocampal formation following placement of fetal LC grafts into the hippocampus /4/.

Very few studies have examined grafting in GEPRs /11,37/. Stevens /37/ reported that grafts of fetal cerebellum containing gamma-aminobutyric

acid (GABA) neurons transplanted to the surface of the inferior colliculus, or grafts of adrenal medulla transplanted to the lateral ventricle are, in general, ineffective in altering seizure expression in GEPRs. However, an identifiable cerebellar graft was found in only one of these animals upon autopsy and this graft was encapsulated and not integrated with the host brain. One of six rats with an adrenal medulla graft in the lateral ventricle showed a decrease in seizure severity. Our laboratory has previously reported that intraventricular or intrahippocampal transplantation of fetal pontine tissue containing noradrenergic neurons can effectively reduce severity of seizures in a limited number of GEPR-3s and GEPR-9s /11/. Grafting of fetal neurons has also been demonstrated to suppress seizure development in kindling-induced /1,2,25/ and facilitate pentylenetetrazol-induced seizures in rats with fimbria-fornix lesions /10/. Thus, grafted fetal noradrenergic or cholinergic neurons can effectively alter seizure expression in at least three models of epilepsy. In the present study, immunohistochemical detection of tyrosine hydroxylase (TH) in tissue sections of the grafted brains demonstrated numerous TH-positive neuron somata as well as fibers within the grafted tissues and that TH positive fibers invaded the parenchyma of the host brain through the graft/host interface. Moreover, in some cases, the densely packed clusters of neurons within the grafted LC were similar to the cytoarchitecture of the *in situ* locus coeruleus of control rats. The present study demonstrates that, while Ctx grafts grow to significantly larger size than LC grafts in the third ventricle, grafts containing the fetal LC are significantly more effective than grafts of neocortical tissue in reducing seizure severity in GEPRs depleted of NE. Additionally, although not statistically significant (likely due to the small number of animals), LC grafts appear to be more effective in reducing seizure severity in NE-depleted animals than in saline-treated LC-grafted animals. Approximately 53% of animals receiving 6-OHDA microinfusions and LC grafts showed significant reductions in seizure severity. In animals that displayed increases in seizure severity following 6-OHDA, LC grafts subsequently reduced the severity to at least the pre-infusion level. In animals which did not display an increase in seizure severity following 6-OHDA, LC grafts effectively reduced

seizure severity to below the preinfusion level and in 1 case completely abolished the display of AGS. In contrast, of those rats receiving microinfusions of saline into the LC, only 20% showed a decrease in seizure severity following transplantation of fetal LC tissue. These data suggest that the effectiveness of noradrenergic neural grafts in promoting reductions in seizure severity in GEPRs may be increased when central NE is depleted by 6-OHDA. It is a tenable hypothesis that depletion of central NE with 6-OHDA creates a synaptic void in the GEPR brain which promotes a more extensive integration between the fetal LC grafts and the host brains, increasing the potential to reduce seizure severity. This hypothesis is not without precedence. For example, hippocampal grafts in the anterior chamber of the eye are more readily innervated by LC co-grafts when competition from the host SCG is removed by lesioning this structure in the host. Additionally, it has been shown that neurite outgrowth *in vitro* from catecholaminergic explant cultures is much reduced in the presence of exogenously administered L-dopa, a precursor of NE /36/. These findings support the hypothesis that there is a type of feedback inhibition on neurite outgrowth and axon arborization from fetal grafts in the presence of synaptic competition or neurotransmitter feedback from the host. However, the hypothesis that development of NE fiber interconnections between the host and the grafted tissues in animals with NE depletion has been examined with LC grafts in the hippocampus /27/. In this study, at two weeks following depletion of NE in the host, there was no apparent difference in graft-derived axon densities or synaptic profiles between control animals and animals previously depleted of NE /27/.

The observation that fetal LC grafts effectively reduce seizure severity in a limited percentage of animals raises questions about the mechanism of this effect. It is presently unknown whether an obligatory site for regulation of seizure severity is innervated by NE neurons from the graft, or whether the release of NE into the ventricular fluid provides an anticonvulsant effect in the GEPR through a more general mechanism. A previous report found that grafts of adrenal medulla tissue had no effect when transplanted onto the surface of the inferior colliculus, or into the lateral ventricle of

GEPRs /37/. However, microinjection of noradrenergic agonists into the inferior colliculus also fails to reduce seizure severity in GEPRs /6/, suggesting that this is not the site at which NE produces an anticonvulsant effect in the GEPR. In other studies, we have shown that grafts of fetal LC placed into the parenchyma of the hippocampus can reduce seizure severity in limited numbers of GEPR-3s and that LC grafts into the third ventricle reduce seizure severity in both GEPR-9s and GEPR-3s /11/. Moreover, this effect may be more appreciable when the host brain is depleted of NE (present study). The reductions in seizure severities following grafting of fetal LC into the third ventricle support the findings of a seizure regulating site near the ventricular surface. In a report by Stull and colleagues /38/, near-ventricular terminal fields of host NE axons have been implicated in the regulation of electrically induced tonic extensor seizures in non-epileptic rats, and several near-ventricular areas of the brainstem have been implicated in regulation of seizures in the GEPR /19/. Thus, although the mechanism of action of NE grafts in the modification of seizure severity requires further study, the apparent findings of facilitated efficacy of fetal LC grafts to reduce seizure severity following depletion of host NE provide additional support for the anticonvulsant effects of NE in the epileptic brains as well as the potential of fetal NE tissue grafts to modify the severity of seizures. Furthermore, these studies provide the impetus to continue to explore the feasibility of neuronal replacement with grafting in a genetic model of epilepsy.

#### ACKNOWLEDGEMENTS

This work was supported by awards from the Epilepsy Foundation of America (R.W.C.) and the National Institute of Health (NS-22672, P.C.J.). The authors thank Michael Pence for his valuable technical assistance.

#### REFERENCES

1. Barry DI, Kikvadze I, Brundin P, Bolwig TG, Björklund A, Lindvall O. Grafted noradrenergic neurons suppress seizure development in kindling-

- induced epilepsy. *Proc Natl Acad Sci* 1987; 84: 8712-8715.
2. Bengzon J, Brundin P, Kalen P, Kokaia M, Lindvall O. Host regulation of noradrenalin release from grafts of seizure-suppressant locus coeruleus neurons. *Exp Neurol* 1991; 111: 49-54.
  3. Björklund A, Nornes H, Gage FH. Cell suspension grafts of noradrenergic locus coeruleus neurons in rat hippocampus and spinal cord: reinnervation and transmitter turnover. *Neuroscience* 1986; 18: 685-698.
  4. Björklund A, Segal M, Stenevi U. Functional reinnervation of the rat hippocampus by locus coeruleus implant. *Brain Res* 1979; 170: 409-426.
  5. Bourn WM, Chin L, Picchioni AL. Enhancement of audiogenic seizure by 6-hydroxydopamine. *J Pharm Pharmacol* 1972; 24: 913-914.
  6. Browning RA, Lanker ML, Faingold CL. Injections of noradrenergic and GABAergic agonists into the inferior colliculus: effects on audiogenic seizures in genetically epilepsy-prone rats. *Epilepsy Res* 1989; 4: 119-125.
  7. Browning RA, Wang C, Faingold CL. Effect of norepinephrine depletion on audiogenic-like seizures elicited by microinfusion of an excitant amino acid into the inferior colliculus of normal rats. *Exp Neurol* 1991; 112: 200-205.
  8. Browning RA, Wang C, Jobe PC. Effect of regional CNS norepinephrine depletion on seizure severity in the genetically epilepsy prone rat. *Epilepsia* 1989; 30: 651.
  9. Browning RA, Wang C, Lanker ML, Jobe PC. Electroshock- and pentylenetetrazol-induced seizures in genetically epilepsy-prone rats (GEPRs): differences in threshold and pattern. *Epilepsy Res* 1990; 6: 1-11.
  10. Cassel JC, Kelche C, Will BE. Susceptibility to pentylenetetrazol-induced and audiogenic seizures in rats with selective fimbria-fornix lesions and intrahippocampal septal grafts. *Exp Neurol* 1987; 97: 564-576.
  11. Clough RW, Browning RA, Maring ML, Jobe PC. Intracerebral grafting of fetal dorsal pons in genetically epilepsy-prone rats: effects on audiogenic-induced seizures. *Exp Neurol* 1991; 112: 195-199.
  12. Dailey JW, Jobe PC. Indices of noradrenergic function in the central nervous system of seizure-naive genetically epilepsy-prone rats. *Epilepsia* 1986; 27: 665-670.
  13. Deckel AW, Robinson RG, Coyle JR, Sanberg PR. Reversal of long term locomotor abnormalities in the kainic acid model of Huntington's disease by day 18 fetal striatal implants. *Eur J Pharmacol* 1983; 93: 287-288.
  14. Faingold CL. The genetically epilepsy-prone rat. *Gen Pharmacol* 1988; 19: 331-338.
  15. Freed WJ, Poltorak M, Becker JB. Intracerebral adrenal medulla grafts: a review. *Exp Neurol* 1990; 110: 139-166.
  16. Freedman R, Taylor DA, Seiger A, Olson L, Hoffer BJ. Seizures and related epileptiform activity in hippocampus transplanted to the anterior chamber of the eye: modulation by cholinergic and adrenergic input. *Ann Neurol* 1979; 6: 281-295.
  17. Friehs GM, Parker RG, He LS, Haines SJ, Turner DA, Ebner TJ. Lesioning of the striatum reverses motor asymmetry in the 6-hydroxydopamine rodent model of Parkinsonism. *J Neur Transplant Plast* 1991; 2: 141-156.
  18. Isacson O, Brundin P, Gage FH, Björklund A. Neural grafting in a rat model of Huntington's disease: progressive neurochemical changes after neostriatal ibotenate lesions and striatal tissue grafting. *Neuroscience* 1985; 16: 799-817.
  19. Jobe PC, Mishra PK, Ludvig N, Dailey JW. Genetic models of the epilepsies. In: Schwartzkroin PA, ed, *Concepts and Models in Epilepsy Research*. Cambridge UK: Cambridge University Press, 1993.
  20. Jobe PC, Picchioni AL, Chin L. Role of brain norepinephrine in audiogenic seizure in the rat. *J Pharm Exp Ther* 1973; 184: 1-10.
  21. Jobe PC, Reigel CE, Mishra PK, Dailey JW. Neurotransmitter abnormalities as determinants of seizure predisposition in the genetically epilepsy-prone rat. *J Pharmacol Exp Ther* 1986; 184: 1-10.
  22. Ko KH, Dailey JW, Jobe PC. Effect of increments in norepinephrine concentrations on seizure intensity in the genetically epilepsy-prone rat. *J Pharmacol Exp Ther* 1982; 222: 662-669.
  23. Laird HE, II, Jobe PC. The genetically epilepsy-prone rat. In: Jobe PC, Laird HE II, eds, *Neurotransmitters and Epilepsy*. Clifton, NJ: The Humana Press, 1987; 57-94.
  24. Lindvall O. Transplantation into the human brain: present status and future possibilities. *J Neurol Neurosurg Psychiatry* 1989; 126 (suppl): 39-54.
  25. Lindvall O, Barry DI, Kikvadze I, Brundin P, Bolwig TG, Björklund A. Intracerebral grafting of fetal noradrenergic locus coeruleus neurons: evidence for seizure suppression in the kindling model of epilepsy. In: Gash, DM, Sladek, JR Jr., eds, *Progress in Brain Research*. Amsterdam, New York: Elsevier Science Publishers BV, 1988; 78: 79-86.
  26. Madrazo I, Drucker-Collin R, Diaz V, Martinez-Malta J, Torres C, Becerril JJ. Open microsurgical autograft of adrenal medulla to the right caudate nucleus in two patients in intractable Parkinson's disease. *N Engl J Med* 1987; 316: 831-834.
  27. Murata Y, Chiba T, Brundin P, Björklund A, Lindvall O. Formation of synaptic graft-host connections by noradrenergic locus coeruleus neurons transplanted in the adult rat hippocampus. *Exp Neurol* 1990; 19: 258-267.
  28. Nishino H, Hashitani T, Kumazaki M, Sato H, Furayama F, Isobe Y, Watari N, Kania M, Shiosaka S. Long-term survival of grafted cells, dopamine

- synthesis/release, synaptic connections, and functional recovery after transplantation of fetal nigral cells in rats with unilateral 6-OHDA lesions in the nigrostriatal dopamine pathway. *Brain Res* 1990; 534: 83-93.
29. Olson L, Seiger A, Taylor D, Freedman R, Hoffer BJ. Conditions for adrenergic hyperinnervation in hippocampus: I. histochemical evidence from intraocular double grafts. *Exp Brain Res* 1980; 39: 277-288.
  30. Paxinos G, Watson C, eds, *The Rat Brain in Stereotaxic Coordinates*. Orlando, FL: Academic Press, 1986.
  31. Redmond DE, Roth RH, Elsworth JD, Sladek JR Jr, Collier TJ, Deutch AY, Haber S. Fetal neuronal grafts in monkeys given methylphenyltetrahydropyridine. *Lancet* 1986; 8490: 1125-1127.
  32. Reigel CE, Dailey JW, Jobe PC. The genetically epilepsy-prone rat: an overview of seizure-prone characteristics and responsiveness to anticonvulsant drugs. *Life Sci* 1986; 39: 763-774.
  33. Ridley RM, Thornley HD, Baker HF, Fine A. Cholinergic neural transplants into hippocampus restore learning ability in monkeys with fornix transections. *Exp Brain Res* 1991; 83: 533-538.
  34. Rosenfeld JV, Kilpatrick TJ, Bartlett PF. Neural transplantation for Parkinson's disease: a critical appraisal. *Aust NZ J Med* 1991; 21: 477-484.
  35. Santucci AC, Kanof PD, Haroutunian V. Fetal transplant-induced restoration of spatial memory in rats with lesions of the nucleus basalis of Meynert. *J Neur Transplant Plast* 1991; 2: 65-74.
  36. Steece-Collier K, Collier TJ, Sladek CD, Sladek JR Jr. Chronic levodopa impairs morphological development of grafted embryonic dopamine neurons. *Exp Neurol* 1990; 110: 201-208.
  37. Stevens JR, Phillips I, Freed WJ, Poltorak M. Cerebral transplants for seizures: Preliminary results. *Epilepsia* 1988; 29: 731-737.
  38. Stull RE, Jobe PC, Geiger PF. Brain areas involved in the catecholamine regulation of electroshock seizure intensity. *J Pharm Pharmacol* 1977; 29: 8-11.
  39. Yurek DM, Sladek JR Jr. Dopamine cell replacement: Parkinson's disease. *Ann Rev Neurosci* 1990; 13: 415-440.