

Major Limb Amputations: An Audit of Indications in a Suburban Surgical Practice

Olutola Akiode, FWACS, FMCS; A.M. Olusola Shonubi, FMCS, FWACS; Adewale Musa, FWACS; and Ganiyu Sule, MBBS

Sagamu, Ogun State, Nigeria

Background: Advancements in vascular and microsurgery in developed countries have led to fewer major limb amputations.

Aim: This audit of major limb amputations performed at the Olabisi Onabanjo University Teaching Hospital, Sagamu, Nigeria, between June 1998 and May 2003, was conducted to find out the indications for amputation and highlight those cases that could be salvageable.

Patients and Methods: This was a retrospective study. Case notes of all patients who had major limb amputations were examined for patients' age, sex, time of presentation, limb affected, indications for amputation, the severity of crush injury to limb, stage of musculoskeletal tumors and Wagner's grade of diabetic foot.

Results: A total of 71 limbs were amputated in 69 patients; 56 limbs (78.1%) were unsalvageable, while 15 limbs (21.1%) were salvageable. Trauma accounted for 76% followed by 22% performed due to gangrene secondary to diabetes mellitus. Out of the 56 unsalvageable limbs, 31 patients presented with severely crushed limbs. Out of the 15 salvageable limbs, there were 11 cases of clean-cut traumatic amputations, two of soft-tissue sarcoma and one each of ruptured popliteal aneurysm and stenosed popliteal artery.

Conclusion: Trauma and diabetes mellitus were leading indications for amputation. Expertise in limb salvage procedures and availability of appropriate equipment may reduce the numbers of amputations performed.

Key words: indication ■ amputations ■ gangrene ■ diabetes mellitus

© 2005. From Olabisi Onabanjo University Teaching Hospital, Sagamu, Nigeria (Akiode, consultant orthopaedic and trauma surgeon; Shonubi, consultant paediatric surgeon; Adewale, consultant general surgeon; GANIYU, surgical registrar). Send correspondence and reprint requests for *J Natl Med Assoc.* 2005;97:74-78 to: Dr. Olutola Akiode, Department of Orthopedics and Traumatology, Olabisi Onabanjo University Teaching Hospital, PMB 2001, Sagamu, Ogun State, Nigeria; e-mail: tolakiode@yahoo.com

INTRODUCTION

The indications for limb amputations are generally considered as the three Ds: dead limb, deadly limb and a damn nuisance of a limb.¹ The most common indications for limb amputation vary from study to study: trauma,² complications of diabetes mellitus³ and peripheral vascular disease.^{4,5}

There is a growing aggressive policy of revascularization in the developed world with various procedures being advocated in an attempt at revascularizing an ischemic limb even in poor candidates.⁶ Medicolegal issues sometimes influence decision-making as to whether to salvage or amputate a limb. The decision to perform limb salvage or primary amputation is thus a crucial one for the surgeon to make, and it is imperative that the surgeon makes a good initial decision.⁷

This study sought to evaluate the indications for the amputations carried out in our hospital and also to assess which cases might have been amenable to salvage procedures if facilities and skilled manpower existed.

AIMS AND OBJECTIVES

This study was carried out to audit the cases of amputation performed at the authors' institution between June 1998 and May 2003 so as to ascertain the indications for amputation and to evaluate which cases could have been salvaged.

PATIENTS AND METHODS

This was a retrospective study of amputations done at the Olabisi Onabanjo University Teaching Hospital, Sagamu, Nigeria, from June 1, 1998 to May 31, 2003. Case notes of all patients who had major limb amputations within the study period were examined. The following variables were extracted: patient's age, sex, occupation, limb affected, indication for amputation, degree of trauma and Wagner's classification of diabetic foot.⁸ All amputations distal to the wrist and the ankle were excluded.

Limbs that were considered to be salvageable were those limbs with clean-cut lacerations and those with vascular lesions (like aneurysms and thrombosed vessels secondary to trauma) that might have benefited from exploration and repair. Other salvageable limbs were limbs with low-grade noninvasive malignant bone tumors and soft-tissue sarcomas without bone involvement. Only those crushed limbs with presence of distal pulses and intact nerve supply at presentation were considered salvageable.

RESULTS

A total of 69 patients were evaluated with 71 limbs affected; there were two patients who had bilateral above-knee amputations (AKA). There were 52 males and 17 females with a male-to-female ratio of 3:1. The age range was 10 months to 80 years, with a peak age range of 20–29 years (Figure 1).

Figure 2 shows the indications for amputation. The most common indication was trauma, which resulted in dead and gangrenous limbs in 52 patients (54 limbs), representing 76.1%. Diabetes mellitus was the most common nontraumatic indication for amputation in 10 limbs (14.1%). An example of this from the archives is shown in Figure 3. All 10 cases

of diabetic foot gangrene presented with Wagner’s grades 4 and 5, (four and six limbs, respectively). There were six cases of malignant musculoskeletal tumors (8.5%): four metastatic osteosarcomas and two soft-tissue sarcomas. There was a case of bleeding popliteal aneurysm (1.4%).

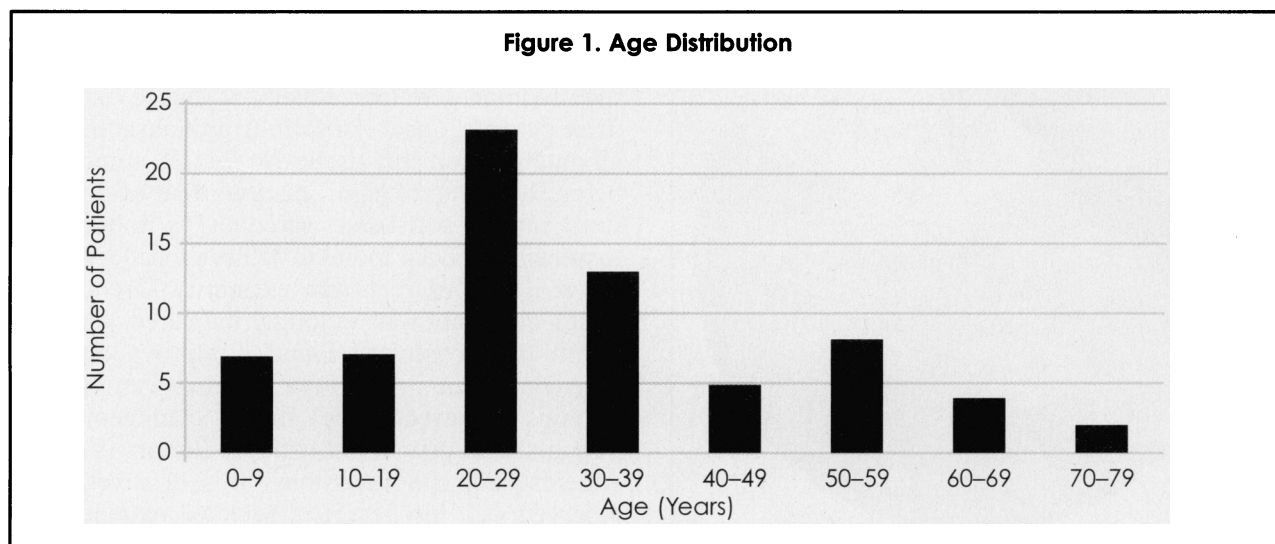
Fifteen limbs (21.1%) were assessed to be salvageable (Table 1). These consisted of 11 clean-cut traumatic amputations (four upper limb, seven lower limb); all patients presented within an hour of injury. There were two soft-tissue sarcomas without bone involvement: one was malignant fibrous histiocytoma, and the other was recurrent fibrosarcoma. The remaining two patients were one ruptured popliteal aneurysm and one stenosed popliteal artery. The patient with the ruptured popliteal aneurysm had amputation carried out due to severe, uncontrollable bleeding. In the case of the stenosed popliteal artery secondary to industrial accident, the patient presented with multiple injuries, including fractured pelvis, fractured femur, fractured ribs and a cold blue leg. The stenosis was diagnosed at arteriography, which showed a cut-off of blood supply.

The remaining 56 unsalvageable limbs (78.9%) comprised four cases of metastatic malignant bone tumors, 17 limbs that were gangrenous at presentation, four severely burnt limbs and 31 severely crushed limbs.

The most frequently performed procedure was AKA, which was done in 29 limbs followed by below-knee amputation (BKA) in 20 limbs. Above-elbow amputation (AEA) was performed in 16 limbs, while below-elbow amputation (BEA) was done in six limbs. Six patients underwent revision of BKA amputation to AKA amputation. An example from the archives is shown in Figure 4.

Postoperative complications occurred in 51 patients (73.9%). The complications included

Diagnosis	Number
Traumatic amputation	11
Malignant tumors	2
Popliteal artery aneurysm	1
Stenosed popliteal artery	1
Total	15



wound infection in 50 patients (72.5%), wound dehiscence in 15 patients (21.7%), stump pain in eight patients (11.6%) and phantom limb in three patients (4.0%). There were five (7.2%) with post-operative mortality. They were all diabetic and died from septicemia and complications of diabetes mellitus, accounting for 50% mortality among diabetic patients.

The majority, 91.5% (65 patients), did not have prosthesis fitted because they could not afford the cost.

DISCUSSION

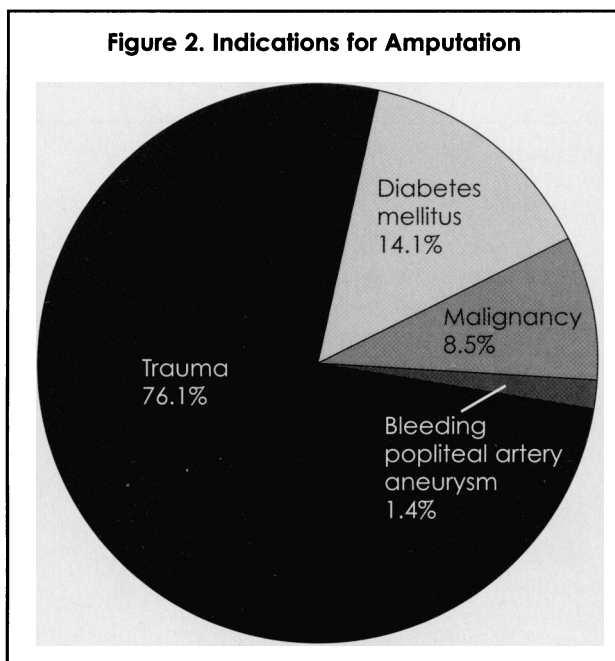
Trauma was the most common indication (76%) for limb amputation in this audit, similar to the findings in two previous studies in Nigeria, where trauma accounted for over 70%.^{2,9} This is in contradistinction to what is reported in developed countries where peripheral vascular disease is the leading cause for limb amputation.¹⁰ Crushed limbs are usually in jeopardy of being amputated, especially when the blood supply is compromised. These limbs may be salvaged by revascularization and stabilization of fractures, but the procedure may not be successful.

To this end, several systems have been devised to predict the success of limb salvage in crushed limbs. These include the Mangled Extremity Severity Score (MESS)¹¹ and the Mangled Extremity Syndrome Index (MESI).¹² A MESS of three-to-six was associated with viable limbs, while a score of seven-to-12 ultimately required amputations. A MESI of 20 was the dividing line below which limb salvage was probable and above which limb amputation was 100%.¹² The predictive value of MESS has been confirmed.¹³ In developed countries, limb

salvage is being performed more in preference for amputations, even in the mangled extremity in which microvascular techniques of reconstruction are performed.¹⁴ Unfortunately, at the time of this report, there was no surgeon skilled in vascular repair, and this resulted in primary amputation of the limbs in those cases of popliteal artery stenosis and bleeding popliteal traumatic aneurysm reported here. Severe trauma to the limbs with extensive tissue loss, however, remains a widely accepted indication for limb amputation despite advances in reconstructive surgery.¹⁵

Diabetes mellitus was the next common indication (14%) but was the most common cause of non-traumatic amputation, a situation similar to another Nigerian study, where it accounted for 26%.¹⁶ In a study in Kenya, diabetes mellitus with its complications was as common as trauma, each accounting for 26.5% of major amputations.¹⁷ A mortality of 50% was recorded in cases of diabetes mellitus in this study similar to what was obtained in the Kenyan study.¹⁷ Limb salvage by frequent use of revascularization in diabetic patients with limbs threatened by foot infection or localized gangrene is presently being performed.^{18,19} A selective approach to revascularization may be indicated in renal insufficiency and diabetes; long-term survival after revascularization being found to be poor,^{4,9,15} while failure of revascularization would necessitate amputation.^{4,5} Unfortunately, in our environment, patients often present late when extensive gangrene has occurred, and revascularization is not feasible.

Four cases of osteosarcoma were assessed as not being salvageable in this audit. They were reported as metastatic. Computerized tomography and magnetic resonance imaging scans were not done to stage the tumors because of unavailability of these facilities at our health institution. This would have enabled more accurate evaluation of the extent of spread of these tumors. However, clinical examination, plain and contrast radiography as well as operative findings were indicative of advanced tumors in these patients. There is a shifting attitude about limb amputation for soft-tissue sarcomas, amputation being found not to significantly affect overall survival rate in soft-tissue sarcoma.²⁰ Limb-sparing treatment has been found to achieve local control in the majority of recurrent extremity sarcoma for which amputation is no longer indicated. Amputation in these cases was found to improve local disease control but not survival.²¹ Primary amputation remains a powerful tool in the management of patients with primary soft-tissue tumors in whom wide excision is not possible.¹⁵ It is, however, being reserved as a last resort in selected patients with local recurrences.



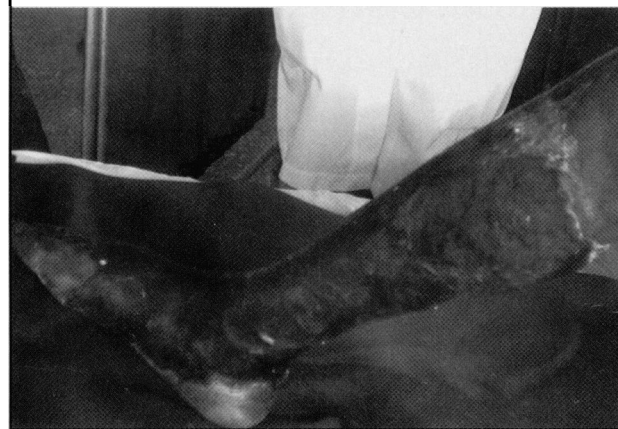
Major limb replantation is defined as replantation of limbs proximal to the wrist or the ankle.²² Crushed and avulsed parts make reconstruction more difficult to achieve.^{23,24} Eleven cases were identified of clean-cut traumatic amputations that might have benefited from limb replantations if the skills and facilities were available during the period covered by this audit. Replantation in the lower extremities remains a controversial issue,²⁵ because lower-limb prostheses provide a stable stance and a functional gait; therefore, prosthesis may be more functional than the replanted limb. In our environment, however, patients prefer to have their limbs, even a poorly functional one, rather than have an artificial one. Unfortunately, after amputations are performed, prostheses are not readily affordable by most patients in the developing world.^{2,9,17} In our study, 95.1% of the patients did not have prosthesis fitted for financial reasons.

One of the main limitations of this study is that it is a retrospective one. The retrospective analysis of the severity of limb injury with respect to prognostication is a difficult task. The decision to salvage a limb is more complex than presence of distal blood supply in a crushed limb, absence of local invasion of a tumor and revascularization of thrombosed vessels. In this study, we identified limbs that may benefit from possible salvage. However, it is recognized that such salvage procedures may not necessarily be successful.

CONCLUSIONS

Trauma was found to be a leading indication for amputations in this study. However, an increasing number of surgeons with vascular and microsurgical skills in Nigeria may make it possible to salvage more limbs. Early decision not to replant a limb or to amputate a limb must still be taken in order to reduce patients' morbidity and even mortality.

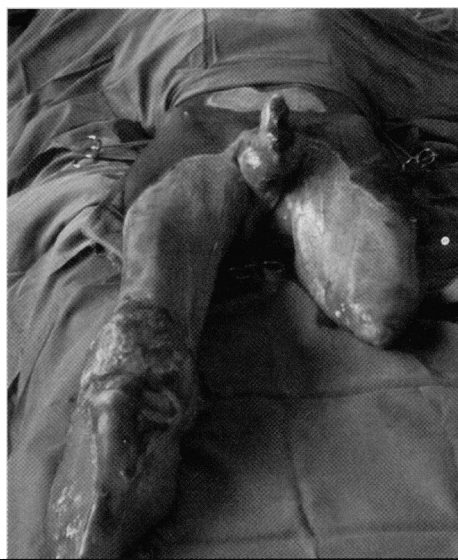Figure 3. Late presentation of gangrenous left leg of a 62-year-old diabetic patient. Patient died two days postoperatively.



REFERENCES

- Solomon L, Warwick DJ, Nayagam S. Orthopedic operations In: Solomon L, Warwick DJ, Nayagam S, eds. *Apley's system of orthopedics and fractures*. 8th ed. Arnold; 2001: p267.
- Olasinde AA, Oginni LM, Bankole JO, et al. Indications for amputations in Ile-Ife, Nigeria. *Niger J Med*. 2002;11:118-121.
- Tan MH, Gwee HM, Yeo PP, et al. Diabetic amputees in Singapore. *Tohoku J Exp Med*. 1983;141Suppl:575-582.
- Abou-Zamzam Jr AM, Teruya TH, Killeen JD, et al. Major lower extremity amputation in an academic vascular center. *Ann Vasc Surg*. 2003;17:86-90.
- Aftabuddin M, Islam N, Jafar MA, et al. The status of lower-limb amputation in Bangladesh: a six-year review. *Surg Today*. 1997;27:130-134.
- Tefera G, Turnipseed W, Tanke T. Limb salvage angioplasty in poor surgical candidates. *Vasc Endovascular Surg*. 2003;37:99-104.
- Tomaino M, Bowen V. Reconstructive surgery for lower limb salvage. *Can J Surg*. 1995;38:221-228.
- Wagner Jr FW. The diabetic foot. *Orthopedics*. 1987;10:163-167.
- Onuminya JE, Obekpa PO, Ihezue HC, et al. Major amputations in Nigeria: a plea to educate traditional bone setters. *Trop Doct*. 2000;30:133-135.
- Gregory-Dean A. Amputations: statistics and trends. *Ann Roy Coll Surg Eng*. 1991;73:137-142.
- Helfet DL, Howery T, Sanders R, et al. Limb salvage versus amputation: preliminary results of the mangled extremity severity score. *Clin Orthop*. 1990;256:80-86.
- Gregory RT, Gould RJ, Pecllet M, et al. The mangled extremity syndrome (MES): a severity grading system for multisystem injury of the extremity. *J Trauma*. 1985;25:1147-1150.
- Whittle AP, Russell TA, Taylor JC, et al. Treatment of open fractures of the fibial shaft with the use of interlocking nailing without reaming. *J Bone Joint Surg*. 1992;74-A:1162-1171.
- Tomaino MM. Lower limb salvage: microvascular reconstruction of post-traumatic soft-tissue and skeletal defects. *Orthopedics*. 1995;18:665-672.
- Soucacos PN, Dailiana ZH, Beris AE, et al. Major ablative procedures in orthopedic surgery. *Bull Hosp Jt Dis*. 1996;55:46-52.

Figure 4. A 44-year-old male with extensive third-degree electric burns. A revision of the right-below-knee amputation to above-knee amputation about to be performed because of exposure and destruction of the knee joint.



MAJOR LIMB AMPUTATIONS

16. Ogunlade SO, Alonge TO, Omololu ABO, et al. Major limb amputation in Ibadan. *Af J Med med Sci*. 2002;31:333-336.

17. Muyembe VM, Muhinga MN. Major limb amputation at a provincial general hospital in Kenya. *East Afr Med J*. 1999;76:163-166.

18. Korn P, Hoenig SJ, Skillman JJ, et al. Is lower extremity revascularization worthwhile in patients with end-stage renal disease? *Surgery*. 2000;128:472-479.

19. Sillesen H. Conservative treatment, amputation or revascularization for critical limb ischemia. *Ann Chir Gynaecol*. 1998;87:159-161.

20. Williard WC, Collin C, Casper ES, et al. The changing role of amputation for soft-tissue sarcoma of the extremity in adults. *Surg Gynecol Obstet*. 1992;175:389-396.

21. Stojadinovic A, Jaques DP, Leung DH, et al. Amputation for recurrent soft-tissue sarcoma of the extremity: indications and outcome. *Ann Surg Oncol*. 2001;8:509-518.

22. Urbianak JR. Replantation of amputated limbs and digits. In: Sabiston DC II, Lyerly HK, eds. *Sabiston Textbook of Surgery: The Biological Basis of Modern Surgical Practice* on CD-ROM. 15th ed. 1997.

23. Axelrod TS, Buchler U. Severe complex injuries to the upper extremity: revascularization and replantation. *J Hand Surg [Am]*. 1991;16:574-578.

24. Bowen CVA, Beveridge J, Milliken RG, et al. Rotating shaft avulsion amputations of the thumb. *J Hand Surg [Am]*. 1991;16:117-119.


25. Kutz JE, Jupiter JB, Tsai T-M. Lower limb replantation—a report of nine cases. *Foot Ankle*. 1983; 3:197-200. ■

We Welcome Your Comments

The *Journal of the National Medical Association* welcomes your Letters to the Editor about articles that appear in the *JNMA* or issues relevant to minority healthcare. Address correspondence to ktaylor@nmanet.org.

JOURNAL OF THE

National Medical Association



Art In Medicine

For those of you who are artists at heart, please submit the summation of your creative efforts to isheyn@nmanet.org for publication consideration in the "Art in Medicine" section of the *Journal of the National Medical Association*.

George Dawson, MD
JNMA Art in Medicine Editor