

NCTES, COMMENTS, AND ABSTRACTS

KWASHIORKOR

A NUTRITIONAL DISEASE OF CHILDREN ASSOCIATED WITH A MAIZE DIET

BY CICELY D. WILLIAMS, B.M. Oxon., M.R.C.P., D.T.M. & H. Lond.

THE name "kwashiorkor" indicates the disease the deposed baby gets when the next one is born, and is the local name in the Gold Coast for a nutritional disease of children, associated with a maize diet, which was first described in December, 1933.¹ An attempt is here made to compare the disease with other conditions, and to indicate the differential diagnosis.

Kwashiorkor is usually observed between the ages of six months and four years, the youngest case noted being nine weeks and the eldest five years old. Some sixty cases have been observed in three years among patients at the Children's Hospital, Accra, the mortality being about 90 per cent. The history always includes defective feeding. The mother is sick, old, and malnourished, or has become pregnant again while the patient is still very young; or the mother may have died, breast-feeding being supplied by an unsuitable foster-mother, very often a senile grandmother; for among these African women some mammary secretion may be present in a woman who has not had a child for 20 years. Supplementary feeds consist mainly of a gruel made from partially fermented white maize, called arkasa, or, for older children, a thick dough of the same called kenki or kon. The child at first appears to progress normally. After a variable interval it ceases to gain weight and becomes

irritable. Some swelling of the hands and feet appears. This always passes off, both in the event of improvement and in the terminal stages of fatal cases. There may be attacks of diarrhoea; there may be photophobia; and there was sloughing of the cornea in two cases. The most obvious feature is the skin condition. Small, black, thickened, crumpled patches appear first about the knees and elbows, afterwards along the extensor surfaces

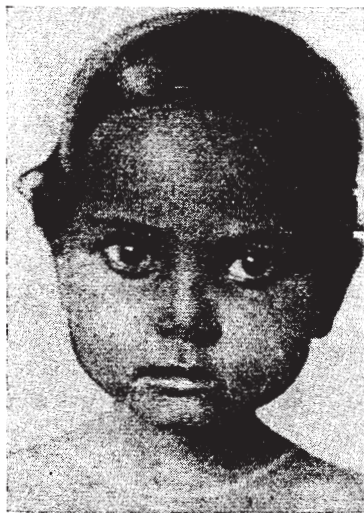

FIG. 1.—A half-caste child, aged 5, suffering from kwashiorkor, with sores at the corners of the mouth.

of the hands and the buttocks. These are areas exposed to irritation and pressure. They have no relation to exposure to light, in contrast to the lesions of pellagra. The skin is soft and pliant, but tends to peel off, leaving a moist, raw surface. There is no "branny desquamation." Small sores at the corners of the eyes and mouth and about the vulva are usual. There may be a trace of albumin in the urine. Malaria, bronchitis, and worms are frequent complications; in uncomplicated cases there may be a slight irregular pyrexia. The blood count is little affected; there is no great anaemia and no leucocytosis. The W.R. is negative. Post mortem the only constant

finding is an extreme fatty infiltration of the liver.

Cases seen very early react well and promptly to an improved diet, rich in accessory substances. Nestlé's sweetened condensed milk with cod-liver oil and malt seemed to be the most successful line of treatment. Unfortunately the condition is an insidious one, and once the dermatitis has set in there is not much hope of recovery. Butter, eggs, tomato, orange, liver, Marmite, yeast, Bemax, iron, and arsenic have also been tried in the treatment.

Figs. 1 and 2 show the condition in a half-caste child of five who died two months later. It is just possible to see the sores at the corners of the mouth. The dark thickened patches of skin are seen on the legs and buttocks. There are none in the areas typical of pellagra. The microphotographs are of the liver (Fig. 3) and of a section of skin (Fig. 4) from the same case. Some points in the differential diagnosis between kwashiorkor and pink disease, vitamin-A deficiency, pellagra, and vitamin-C deficiency are set out below.

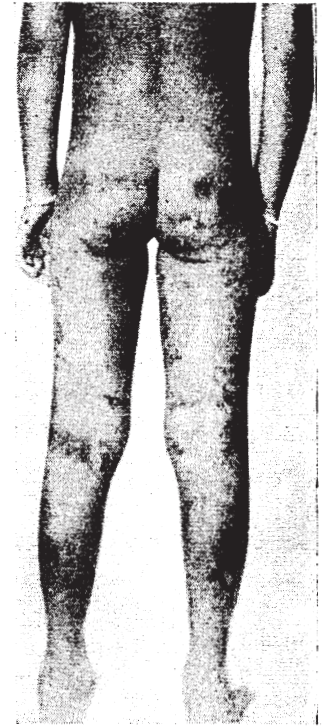


FIG. 2.—Dark thickened patches of skin on the legs and buttocks of the same child.

DIFFERENTIAL DIAGNOSIS

Pink disease.—Characteristics common to pink disease and kwashiorkor, both of which occur in

young children, are irritability, irregular pyrexia, and skin lesions. The latter reacts well to early treatment, whereas the former runs a prolonged course, unaffected by treatment. In kwashiorkor photophobia is seen only occasionally, skin lesions are distinct and typical, and desquamation is extensive, deep, and severe; whereas in pink disease photophobia is pronounced, skin lesions are different, and desquamation is slight.²

Vitamin-A deficiency.—Characteristics common to both kwashiorkor and vitamin-A deficiency are the lack of animal fats in the diet, the occurrence of skin lesions, attacks of enteritis, and improvement under cod-liver oil. Phrynodermia, Bitot's spots, night-blindness, and xerophthalmia, often described in connexion with vitamin-A deficiency, occur in other members of the same population, but have not been observed in kwashiorkor, nor does the liability to skin infections appear to be increased.³⁻¹⁰

Vitamin-A and -B deficiency of Sierra Leone has in common with kwashiorkor stomatitis, conjunctivitis, and skin lesions, but it occurs in adults; many cases show eversion of the eyelids, and the desquamation is relatively slight.^{11 12}

Vitamin-B deficiencies.—The differential diagnosis from beri-beri, which also causes oedema and affects children and infants, is that beri-beri, unlike kwashiorkor, may lead to sudden death in infants; may be very acute in onset; causes polyneuritis; and produces no skin lesions.¹³ Moreover beri-beri responds to treatment in hours instead of in weeks.

Vitamin-B₂ deficiency differs from kwashiorkor in that the diet leading to the condition contains

no milk or yeast, whereas the diet of the children described above usually includes milk, though its quality is probably defective; and arkasa and kenki do contain yeasts, which have not, however, yet been cultured or tested for biological value.^{14 15}

Other deficiencies.—Kwashiorkor cannot be due to deficiency of vitamin C or vitamin D, because the victims show no evidence of either scurvy or rickets. No tests for mineral or protein deficiencies have yet been made.

Pellagra has in common with kwashiorkor the occurrence of œdema, sores at corners of mouth and

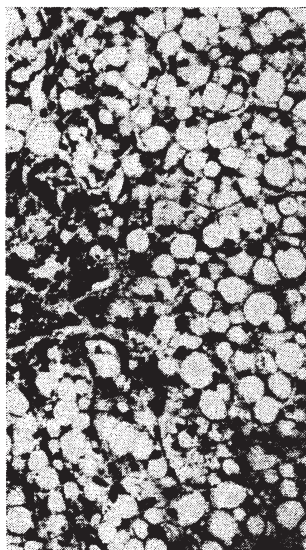


FIG. 3.—Photomicrograph of the liver showing extreme fatty infiltration.

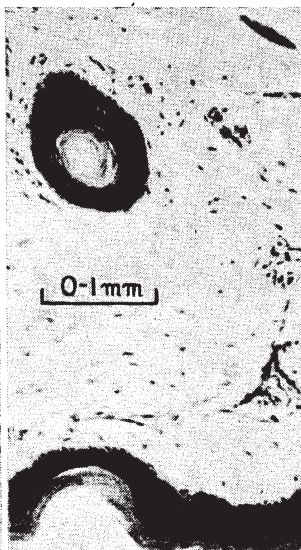


FIG. 4.—Photomicrograph of the skin.

eyes, skin lesions, irritability, and an association with maize diet and with diet poor in protein. The differences are set out below in tabular form.

Differences between Kwashiorkor and Pellagra

KWASHIORKOR	PELLAGRA ¹⁶⁻²⁸
Affected skin black, rugose, and soft.	Affected skin rough, dry, and branny.
Extensor surfaces and points of irritation and pressure affected.	Face, necklance area, and dorsum of hands and feet affected.
Skin not photosensitive.	Skin photosensitive.
Occurs in children under five years.	Rare in children.
Usual under two years.	Almost unknown under two years.
Reflexes unchanged.	Peripheral neuritis common.
Dementia not observed.	Dementia common.
Patients may be largely on a breast milk diet.	Very rare with milk diet.
Arkasa (preparation of maize) in diet contains yeasts.	Yeasts said to be curative.
Fatty infiltration of liver severe and constant.	Fatty infiltration of liver may be present, but is generally mild.
Never seen in adults.	Common in adults.
Common condition in the Gold Coast.	Never yet described in the Gold Coast.

It has been suggested that kwashiorkor is in fact pellagra,³⁰ but the points of difference appear to be more numerous and more striking than the points of similarity. The series of cases seen in East Africa by Dr. R. U. Gillan present apparently many points of resemblance to those described above³¹ and a perfectly typical case of kwashiorkor has been described by Dr. Dyce Sharp in Cape Coast.³²

I am indebted to the director of medical and sanitary services for permission to publish this article.

REFERENCES

- Williams, C. D.: Arch. Dis. Child., 1933, viii., 423.
- Thursfield, H., and Paterson, D.: Diseases of Children, London, 1934.
- Wilson, J. R., and Dubois, R. O.: Amer. Jour. Dis. Child., 1923, xxvi., 431.
- Frazier, C. N., and Hu, C. K.: Arch. Int. Med., 1931, lviii., 507.
- Andrews, G. C.: Diseases of the Skin, London, 1930, p. 861.
- Pillat, Arnold: Chin. Med. Jour., 1929, xliii., 907.
- Wright, R. E.: Brit. Jour. Ophth., 1932, vi., 164.
- Hsu, K. L.: Chin. Med. Jour., 1927, xii., 825.
- Mackay, H. M. M.: Arch. Dis. Child., 1934, ix., 65.
- Goodwin, G. P.: Brit. Med. Jour., 1934, ii., 113.
- Wright, E. J.: West African Med. Jour., 1928, ii., 127.
- Leone, London, 1930.
- Bray, G. W.: Trans. Roy. Soc. Trop. Med., 1928-29, xxii., 13.
- Goldberger, J.: Pub. Health Reports, 1927, xlii., 2193.
- Kagan, S. R.: Med. Life, 1933, xi., 434.
- Mellanby, E.: Nutrition and Disease, London, 1934.
- Niles, G. M.: Pellagra, London, 1916.
- Goldberger, Wheeler, and Sydenstricker: Pub. Health Reports, 1920, xxxv., 648, 1650, 2673.
- Sandwith, F. M.: Trans. Roy. Soc. Trop. Med., 1911-12, v., 120.
- Arkroyd, W. R.: Nutrition Abstracts and Reviews, 1933-34, iii., 337.
- Wilson, H.: Jour. Egypt. Med. Assoc., 1932, xv., 405.
- Wilson, H.: Ibid., 1932, xv., 490.
- Wheeler, S. A.: South Med. Jour., 1933, xxvi., 648.
- Stannus, H. S.: Trans. Roy. Soc. Trop. Med., 1913-14, vii., 32.
- Monauni, J.: Wien. klin. Woch., 1933, xlvi., 1413.
- Spies, T. D., and De Wolf, H. F.: Amer. Jour. Med. Sci., 1933, clxxxvi., 521.
- Fakhry, Assad: Jour. Egypt. Med. Assoc., 1932, xv., 53, 427.
- Ruffin, J. M., and Smith, D. T.: Amer. Jour. Med. Sci., 1934, clxxxvi., 512.
- Chick, H.: THE LANCET, 1933, ii., 341.
- Stannus, H. S.: Arch. of Dis. Child., 1934, ix., 115.
- Gillan, R. U.: East Africa Med. Jour., 1934, xi., 88.
- Dyce Sharp, N. A.: Trans. Roy. Soc. Trop. Med., 1934, xxviii., 411.