

## Early Hepatic Stages of *Plasmodium berghei*: Release of Circumsporozoite Protein and Host Cellular Inflammatory Response

ZAFAR M. KHAN, CHUI NG, AND JEROME P. VANDERBERG\*

Department of Medical and Molecular Parasitology, New York University  
School of Medicine, New York, New York 10016

Received 27 June 1991/Accepted 30 October 1991

After injection of *Plasmodium berghei* sporozoites into Norway-Brown rats, we were able to localize these sporozoites and the early hepatic trophozoites developing from them in histological sections of the liver stained with a sensitive immunogold-silver procedure. Sporozoites invading hepatocytes released substantial quantities of circumsporozoite protein into the hepatocyte cytoplasm. This intrahepatic cytoplasmic distribution reached a maximal level at about 4 h post-sporozoite injection. As the hepatic parasites continued to differentiate, circumsporozoite protein became undetectable within the cytoplasm of the hepatocytes and became localized around the periphery of each parasite. There was generalized cellular inflammation within the liver of the host, which first became evident at around 4 h post-sporozoite injection and progressed to the formation of well-defined granulomas by 24 h. Such histopathological changes were not seen in rats injected with killed sporozoites, indicating that the cellular inflammation was induced by viable, infective sporozoites. We did not observe cellular infiltration specifically associated with any of the developing hepatic stages that we observed, even up to 28 h post-sporozoite inoculation. These results indicate that viable sporozoites induced rapid and generalized hepatic inflammation in host rats. However, sporozoites that successfully invaded hepatocytes and then proceeded to develop further did not appear to be the target of inflammatory cells until a period beginning at around 40 h post-sporozoite inoculation.

Malaria is initiated by *Plasmodium* sporozoites, which are inoculated by mosquitoes, invade hepatocytes, and develop into hepatic schizonts. With the rodent malaria parasite *Plasmodium berghei*, mature schizonts begin to rupture at about 44 h post-sporozoite inoculation and the resultant merozoites initiate the erythrocytic stages of development. We have previously shown that when mature, nonimmunized rats were injected with *P. berghei* sporozoites, many of the developing hepatic schizonts were infiltrated by inflammatory cells (10). Eosinophils represented a pioneer component of this cellular infiltrate, which we detected as early as 40 h post-sporozoite injection, well before any hepatic schizonts could have matured and ruptured within the liver. This presented histological evidence that inflammatory cells can recognize and infiltrate intact hepatocytes containing schizonts in immunologically naive animals. It also poses the possibility that this inflammatory process can be enhanced by immunization.

By 40 h post-sporozoite injection, the inflammatory process was already well advanced. Many well-developed granulomas could be seen within the liver. It therefore seemed appropriate to investigate the initial stages of this process. A better understanding of the functional role of the inflammatory response requires analysis of the early stages of parasite interaction with inflammatory cells. However, the relatively small size of the hepatic schizont during its early residency in the liver, coupled with the possibility of its partial destruction by inflammatory cells, made it difficult to identify hepatic parasites positively by conventional staining techniques. Accordingly, we used a sensitive immunohistological staining procedure to identify circumsporozoite (CS) protein, an antigen that has been found to be present not only in the sporozoite but also in subsequent hepatic stages

of the parasite (7, 8). This procedure readily enabled us to locate these early stages and characterize the distribution of CS protein within them. The purpose of this report is to describe the release and distribution of CS protein within host hepatocytes during early parasite development and describe and characterize the inflammatory process in response to *P. berghei* sporozoite invasion and subsequent development.

### MATERIALS AND METHODS

**Parasites and experimental animals.** *P. berghei* NK65 sporozoites were obtained by dissection and homogenization of salivary glands from infected *Anopheles stephensi* mosquitoes, as previously described (21, 23). Females Norway-Brown rats (from a Harlan Sprague-Dawley virus-free colony) were chosen because of the high susceptibility of Norway-Brown rats to sporozoites of *P. berghei* (13). Rats 10 to 12 weeks old were used because of the full inflammatory response mounted by such animals against developing *P. berghei* hepatic schizonts (10).

**Experiments.** Sporozoites suspended in medium 199 (GIBCO) with 2% bovine serum albumin (GIBCO) were injected into the lateral tail vein of experimental rats, generally at a dosage of  $10^6$  sporozoites per animal. Rats were necropsied at 1, 2, 3, 4, 8, 16, 20, 24, 28, or 44 h post-sporozoite inoculation. Liver specimens were removed and fixed immediately, as indicated below. Inasmuch as sporozoite suspensions are normally contaminated with mosquito debris, which might itself induce an inflammatory response, we controlled for this with injections of comparable amounts of homogenized salivary glands from uninfected mosquitoes (salivary gland controls). To determine whether nonviable sporozoites had the capacity to induce inflammatory responses, we killed the sporozoites in some control preparations by exposure to a hypertonic solution of  $10\times$ -concent-

\* Corresponding author.

TABLE 1. Parasite morphology, distribution of CS protein, and nature of host response at various times postinjection of *P. berghei* sporozoites into rats<sup>a</sup>

Time (h) postinjection of sporozoites	Parasite morphology (Fig. 1 panel(s))	Distribution of CS protein (Fig. 1 panel(s))	Histopathological changes (Fig. 2 panel(s))	Mean histopathological activity index (range)
1-3	Undifferentiated sporozoite (1a, 1a'), with mid-region bulb (1b, 1b'), or with terminal bulb (1c, 1c')	Within parasite and throughout hepatocyte cytoplasm (with increase from 1 to 3 h)	None significant	0
4	As above or spherical (2a')	Within parasite and heavily throughout cytoplasm of hepatocyte (2a, 2a')	Congestion of sinusoids and central veins (a; HAI <sup>b</sup> score, 1), few eosinophils in portal tracts	0.5 (0-1)
8	Spherical (3) or with extensions (4)	Within parasite (3, 4); only small amount in cytoplasm of hepatocyte (3, 4)	As above plus inflammatory cells within sinusoids (b; HAI score, 3), very small cellular aggregates (b; center; HAI score, 4)	4.5 (3-6)
16	Spherical; mean diameter, 5 $\mu$ m (5a)	Around periphery of schizont (5a)	As above plus many foci of cellular aggregates (mean diameter, about 50 $\mu$ m) with neutrophils, eosinophils, mononuclear cells (c; HAI score, 4)	8.0 (6-10)
20	As above; mean diameter, 6 $\mu$ m (5b)	As above (5b)	As above plus larger, pregranulomatous aggregates of inflammatory cells (mean diameter, >100 $\mu$ m) (d; HAI score, 5)	12.5 (10-15)
24	As above; mean diameter, 9 $\mu$ m (5c)	As above (5c)	As above plus a few well-defined granulomas (e; HAI score, 6)	18.0 (15-21)
28	As above; mean diameter, 11 $\mu$ m (5d)	As above (5d)	As above, plus large, well-developed granulomas populated with histiocytes e, f; HAI score, 6)	21.0 (21-21)

<sup>a</sup> There was no association of inflammatory cells with parasites.

<sup>b</sup> HAI, histopathological activity index.

trated medium 199; alternatively, we killed sporozoites in several preparations by subjecting them to three cycles of freezing (in a propane bath cooled with dry ice) and thawing (killed sporozoite controls). Baseline control animals received no injections (untreated controls). We studied a total of 36 experimental rats within six experiments.

**Tissue processing and staining.** Liver specimens were fixed in 10% formalin in phosphate-buffered saline (PBS; GIBCO), dehydrated in a graded ethanol series, cleared in chloroform, and embedded in paraffin. All lobes of the liver were fixed, and random samples of tissue throughout the liver were sectioned. Sections 4  $\mu$ m thick were stained with hematoxylin and eosin (H&E) for histopathological studies. The sizes of hepatic parasites and of focal inflammatory reactions were measured by using an ocular micrometer previously calibrated with a stage micrometer. Serial sections were examined to ensure that the greatest diameter of each of these would be determined.

**Histopathological activity index.** To quantitate the inflammatory response, we used a numerical scoring system (10) that allowed us to compare objectively the histopathological changes in liver specimens fixed at various times after sporozoite injection. This is an additive system that assigns scores of 1 for expansion of portal tracts by inflammatory cells, 2 for portal and periportal inflammation, 3 for infiltration of sinusoids by inflammatory cells, 4 for foci of inflam-

matory cell aggregates, 5 for granulomatous aggregates, and 6 for well-defined granulomas.

**Immunogold-silver staining (IGSS).** IGSS was done to localize the CS antigen of *P. berghei* on sporozoites and young hepatic trophozoites too small to localize after conventional histological staining. For the primary antibody, we used a monoclonal antibody (MAb), 3D11 (27), to the immunodominant repeat region of the *P. berghei* CS protein, which persists on the surface of *P. berghei* hepatic schizonts throughout their development (3). To determine the reactivity of this MAb, a CS precipitation reaction with viable sporozoites (24) was performed before immunostaining.

Sections were deparaffinized in xylene, rehydrated through a graded ethanol series, and washed in PBS. Subsequent IGSS was done with the aid of a capillary action staining system (12; available from Fisher Scientific Products as Immunocode Probe-On slides and slide holders and Isolon reagent isolators). The IGSS procedure was performed by using the AuroProbe LM kit (Janssen Life Sciences Products; distributed by Amersham, Arlington Heights, Ill.) in our modification of previously described procedures (12, 16; manufacturer's instructions). The details of our procedure were as follows. The slides were washed for 5 dips in Dulbecco's PBS (DPBS; GIBCO) containing 0.075% Brij detergent (DPBS-Brij; pH 7.5) and assembled face to face in the Probe-On slide holder before being

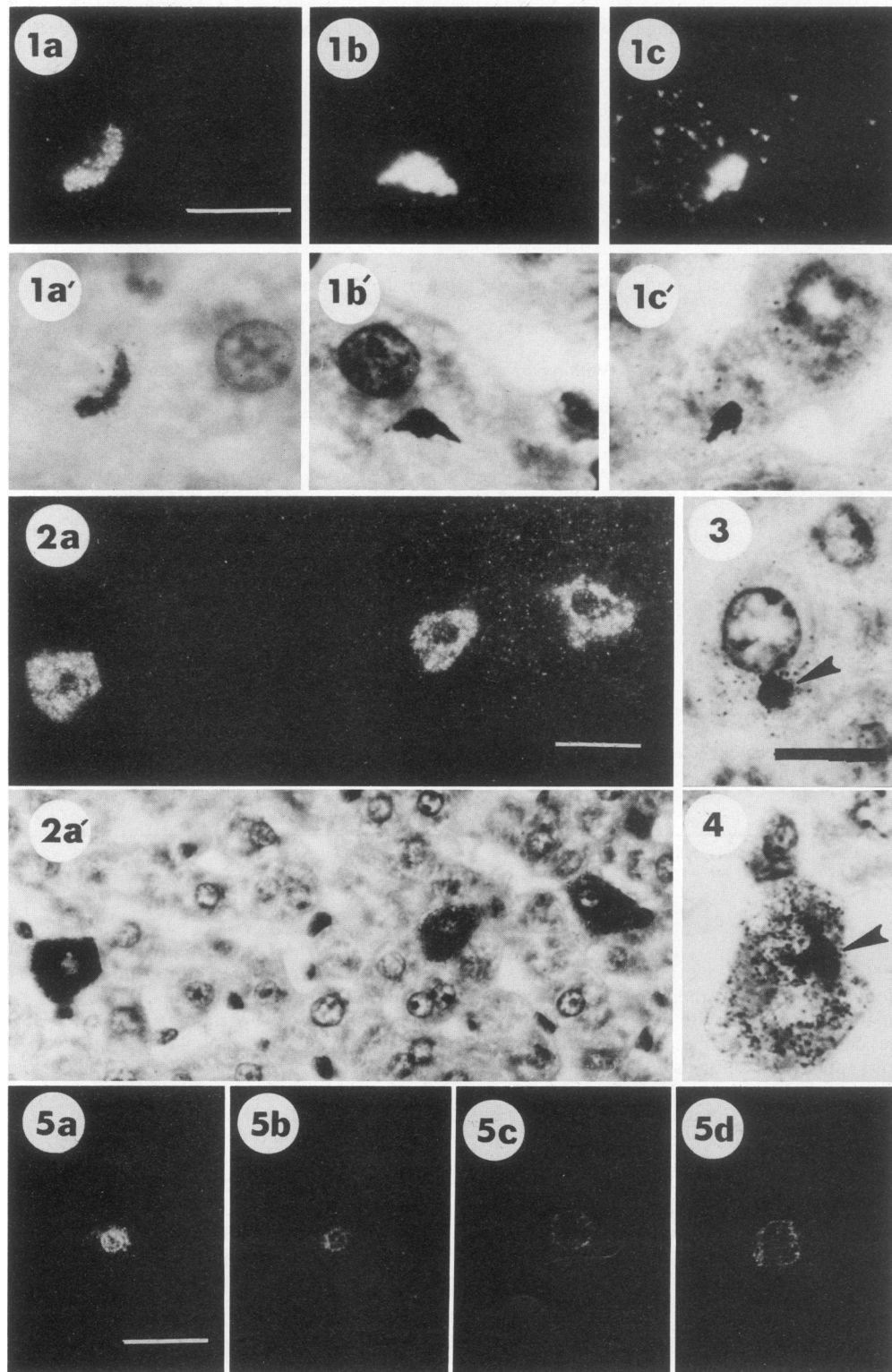


FIG. 1. (Panels 1a to 1c') Photomicrographs of developmental stages of *P. berghei* sporozoites at 1 to 4 h post-sporozoite injection. Sections were immunostained by IGSS with a MAb against the repeating epitope of the CS protein and counterstained with H&E. Epipolarization microscopy of sections shows silver grains, which appear white against a black background (1a to 1c). Bright-field microscopy of the same parasites stained with H&E is shown in panels a' to c'). Bar, 10  $\mu$ m. (1a and 1a') Morphologically undifferentiated sporozoite within a hepatocyte (1 h post-sporozoite injection). (1b and 1b') Differentiating sporozoite with mid-region bulb and arms on either side (4 h post-sporozoite injection). (1c and 1c') Differentiating sporozoite with terminal bulb (4 h post-sporozoite injection). (Panels 2a and 2a') Photomicrographs of a liver section showing three infected hepatocytes at 4 h post-sporozoite injection. The section was immunostained by IGSS and counterstained with H&E. Bar, 20  $\mu$ m. (2a) Epipolarization microscopy of a section immunostained by IGSS. Intense and homo-

incubated in blocking solution (0.1% bovine serum albumin, 0.1% gelatin [Janssen], 10% normal goat serum, 0.1% sodium azide in DPBS, pH 7.5) for 15 min. Slides were then drained, incubated with MAb 3D11 (diluted 1/20 in incubation buffer [0.8% bovine serum albumin, 0.1% gelatin, 1% normal goat serum, 0.1% sodium azide in PBS, pH 7.5]) for 45 min, and washed in four changes of DPBS-Brij. They were then incubated for 45 min with a secondary antibody (AuroProbe One GAM; Janssen) consisting of affinity-purified goat anti-mouse immunoglobulin linked to 1-nm-diameter gold particles diluted 1/50 in incubation buffer. After being washed in four changes of DPBS-Brij, the slides were fixed with 2% glutaraldehyde in PBS for 10 min. The slides were then removed from the holder and washed with distilled water for 5 min, and silver amplification steps were performed with the IntenSE M kit (Janssen) for 5 to 10 min at room temperature, with monitoring of the degree of silver enhancement by light microscopy. During this monitoring, we attempted to achieve a high degree of specific staining prior to development of a heavy, nonspecific background. Such staining allowed easier localization of parasites, although the heavy immunostaining sometimes obscured details of parasite morphology visualized by H&E. Accordingly, we understained parallel batches of slides to permit better visualization with H&E. After being washed once with distilled water for 5 min, slides were counterstained with H&E, dehydrated, and then mounted in Permount for observations with epipolarization microscopy (5), which allowed clear visualization of the silver particles. Some slides were counterstained instead with 4',6-diamidino-2-phenylindole (Sigma) as previously described (9), for visualization of schizont nuclei. Controls consisted of elimination of incubation steps with the primary and/or secondary antibodies.

## RESULTS AND DISCUSSION

Parasite morphology, distribution of CS protein, and the nature of the host response at various times from 1 to 28 h after sporozoite injection are presented in Table 1, together with references to Fig. 1 to 3, which illustrate these results. Control rats (nontreated controls, rats that received injections with noninfected salivary glands, or rats that received injections with equivalent numbers of killed sporozoites) had no striking histopathological changes in their livers, even by 28 h postinjection of sporozoites.

Our observations on differentiation of *P. berghei* sporozoites into hepatic schizonts have allowed us to confirm and extend *in vitro* and *in vivo* observations of previous workers, who reported that the transformation of elongate sporozoites into spherical hepatic trophozoites is first marked by the appearance of a terminal or mid-region bulb on each sporozoite (1, 8, 14, 15, 18). This differentiation continues with progressive enlargement of the bulb. Interestingly, this stepwise differentiation from an elongate to a spherical parasite resembles in reverse our previous description of the differ-

entiation of this parasite from a spherical fertilized gametocyte to an elongate ookinete (26).

We also observed in the present study that substantial quantities of CS protein were detectable throughout the cytoplasm of host hepatocytes, as determined by immunohistological staining of liver specimens taken during the first several hours post-sporozoite injection. Localization of hepatic schizonts by immunofluorescence has long been carried out with polyclonal sera raised against blood stages of the parasite (reviewed in reference 11) or against irradiated sporozoites (4). The latter researchers, who were able to localize hepatic schizonts of *P. berghei* as early as 14 h post-sporozoite injection, found a peripheral localization of immunofluorescence around the parasite.

In the first attempt to study the distribution of a defined antigen within liver stages of the parasite, *P. berghei* sporozoites were allowed to invade cultured WI38 or HepG2 cells and then at various times after sporozoite invasion the cultures were immunostained for CS protein by an immunoperoxidase procedure (8). Sporozoites were reported to have shed CS protein-containing material onto the surface of the target cells. These researchers further reported strong staining of the parasite surface membrane, cytoplasm, and parasitophorous vacuole membrane throughout development (7). However, later studies by this group with *P. falciparum* demonstrated that CS protein was limited to the surface of the sporozoite at 1 h postinvasion of sporozoites into hepatoma cells (2). These researchers thus concluded that the earlier findings were likely due to artifactual deposition of an immunoperoxidase reaction product on the closely opposed membrane of the parasitophorous vacuole. Similarly, studies with *P. falciparum* 2 h after invasion of cultured hepatocytes showed that CS protein was restricted to the sporozoite (18).

The degree of deposition of CS protein within the cytoplasm of a host hepatocyte has been even less clearly defined. Lines of CS protein through the host cell cytoplasm to the parasite have been reported (20); these workers also described disrupted areas of host cell cytoplasm adjacent to the parasite (6) but no generalized labeling of host cell cytoplasm. Localized masses of CS antigen have been described in the cytoplasm of host cells in 3- and 24-h-old cultures when undifferentiated sporozoites were still present (3).

The generalized distribution of CS protein throughout the cytoplasm, which we now report, appears to be a new observation. We were able to detect this because of the high sensitivity of the IGSS procedure and because this distribution of CS protein within the hepatocyte cytoplasm appears to be restricted in time, reaching a maximum concentration at about 4 h post-sporozoite invasion. Virtually all of the earlier studies were done 1 or 2 h postinvasion of sporozoites and likely missed the maximum deposition of parasite antigen into the hepatocyte cytoplasm. The restriction of this intrahepatocytic distribution of CS protein to the first several hours post-sporozoite invasion suggests continued release of CS protein by sporozoites. We have shown that sporozoites

---

geneous distribution of CS protein within the cytoplasm of host hepatocytes is seen. (2a') Bright-field microscopy of the same section to show H&E staining. (Panels 3 and 4) Photomicrographs of developing hepatic trophozoites at 8 h post-sporozoite injection. Bright-field microscopy of slides stained by IGSS and counterstained with H&E to show parasites (arrowheads), which are spherical, with no detectable CS protein within the host cell cytoplasm (panel 3) or spherical with projecting extensions, and the sparse distribution of CS protein within the host cell cytoplasm (panel 4). Bar, 10  $\mu$ m. (Panels 5a to 5d) Photomicrographs of four developing hepatic parasites immunostained by IGSS. Epipolarization microscopy shows that CS protein becomes more peripherally localized around the parasite as the parasite gradually increases in size (5a, 16 h; 5b, 20 h; 5c, 24 h; 5d, 28 h post-sporozoite injection). Note that CS protein is undetectable within the cytoplasm of host hepatocytes containing these parasites during this period of parasite development. Bar, 20  $\mu$ m.

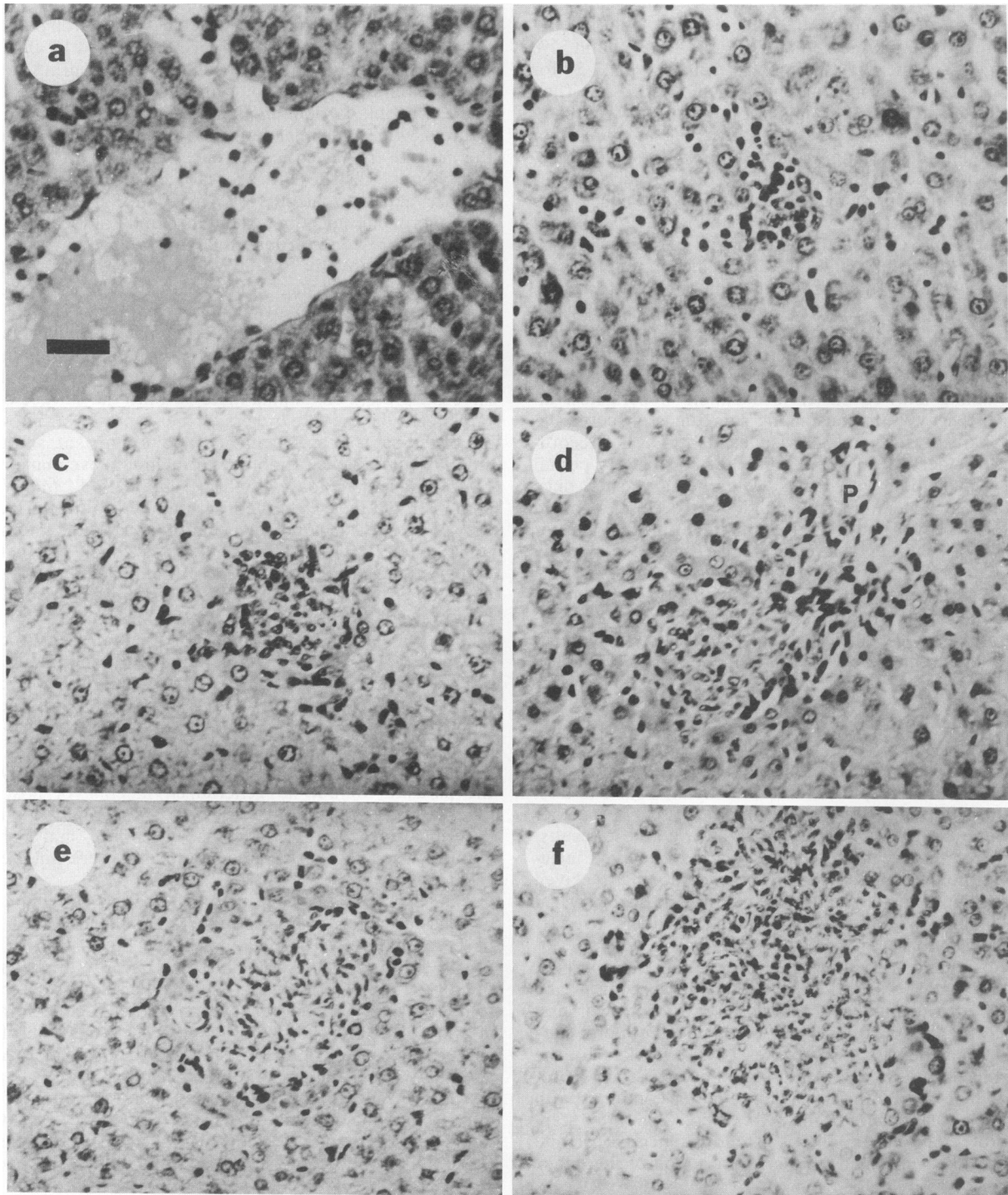


FIG. 2. Photomicrographs illustrating types of histopathological changes in livers of rats at various necropsy times postinjection of *P. berghei* sporozoites. Bar, 30  $\mu\text{m}$ . (a) At 4 h postinjection of sporozoites, showing a congested central vein with neutrophils and eosinophils within the lumen. (b) At 8 h postinjection of sporozoites, showing inflammatory cells in sinusoids, in either haphazard or linear array, and a small, central inflammatory cell aggregate containing neutrophils, eosinophils, and mononuclear cells. (c) At 16 h postinjection of sporozoites, showing a small inflammatory cell aggregate containing neutrophils, eosinophils, and mononuclear cells. (d) At 20 h postinjection of sporozoites, showing a pregranulomatous aggregate close to a portal tract (P). (e and f) At 24 and 28 h postinjection of sporozoites, showing two well-defined granulomas consisting predominantly of histiocytes with a few fibroblasts.

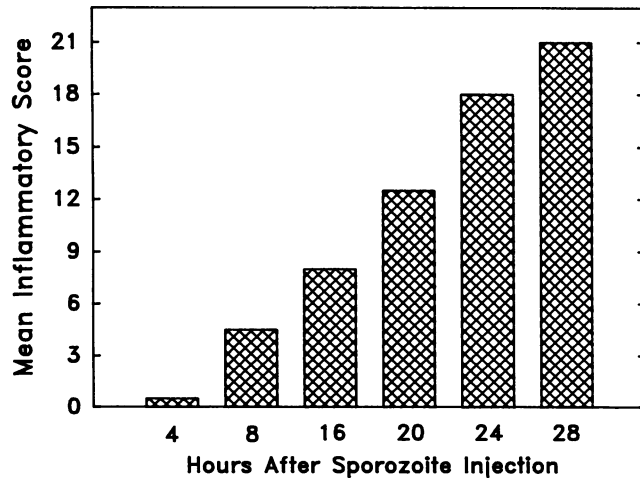


FIG. 3. Degrees of histopathological changes in the livers of Norway-Brown rats at various necropsy times postinjection of *P. berghei* sporozoites. Mean inflammatory scores were determined as described in Materials and Methods. Examples of these specific changes are shown in Fig. 2.

release large quantities of CS protein in vitro (19) and actively and extensively move within cells that they have invaded (22). Other workers have shown that CD8<sup>+</sup> cytotoxic cells can recognize epitopes of CS protein on the surface of infected hepatocytes (17, 25), thus implying that the parasite is capable of releasing CS protein into hepatocytes for endogenous processing and subsequent presentation on the hepatocyte surface. We now demonstrate the release of such protein by the parasite.

Our results indicate that injection of viable *P. berghei* sporozoites into Norway-Brown rats induces a rapid cellular inflammatory response within the liver. Hepatic histopathological changes could be seen within 4 h postinjection of sporozoites. This progressed to formation of well-defined granulomas by 24 h. Such histopathological changes were not seen in animals injected with killed sporozoites, thus indicating that the cellular inflammation was induced by viable, infective sporozoites. However, we did not observe cellular infiltration specifically associated with any of the developing hepatic stages that we observed, even up to 28 h post-sporozoite inoculation. These results suggest that the early and rapid generalized hepatic inflammation that we describe was induced by viable sporozoites shortly after sporozoite injection. We have observed in vitro that *P. berghei* sporozoites can destroy cells, such as macrophages, by actively penetrating and then exiting from them (22). Sporozoites that successfully invade hepatocytes and then proceed to develop further do not appear to be involved in induction of focal inflammatory infiltrates around themselves.

Our results indicate that *P. berghei* sporozoites injected into mature Norway-Brown rats induce two waves of granuloma formation: an early one that initiates shortly after sporozoites are injected (as described here) and a later one that appears to initiate with the infiltration of developing hepatic schizonts at about 40 h post-sporozoite injection (10). Until the initiation of this second wave of cellular inflammation, sporozoites that had successfully invaded hepatocytes and continued to develop appeared to be largely insensitive to the extensive hepatic inflammation going on elsewhere in the liver.

Now that we have described the inflammatory response to sporozoites in immunologically naive animals, it will be of interest to determine (i) the possible role of this cellular inflammation in the processing of sporozoite antigen during induction of the immune response, (ii) the changes in the developing hepatic schizont that render it susceptible to recognition by host inflammatory cells at around 40 h, and (iii) the manner in which the cellular response against sporozoites and developing hepatic schizonts is more effective in animals that have been previously immunized.

#### ACKNOWLEDGMENTS

We thank Ruth S. Nussenzweig and Alan Cochrane for kindly supplying MAb 3D11.

This work was supported by Public Health Service grant AI-24528 from the National Institutes of Health.

#### REFERENCES

- Aikawa, M., A. Schwartz, S. Uni, R. S. Nussenzweig, and M. R. Hollingdale. 1984. Ultrastructure of in vitro cultured exoerythrocytic stage of *Plasmodium berghei* in a hepatoma cell line. *Am. J. Trop. Med. Hyg.* 33:792-799.
- Aley, S. B., C. T. Atkinson, M. Aikawa, W. L. Maloy, and M. R. Hollingdale. 1987. Ultrastructural localization of *Plasmodium falciparum* circumsporozoite protein in newly invaded hepatoma cells. *J. Parasitol.* 73:1241-1245.
- Atkinson, C. T., M. Aikawa, S. B. Aley, and M. R. Hollingdale. 1989. Expression of *Plasmodium berghei* circumsporozoite antigen on the surface of exoerythrocytic schizonts and merozoites. *Am. J. Trop. Med. Hyg.* 41:9-17.
- Danforth, H. D., A. U. Orjih, and R. S. Nussenzweig. 1978. Immunofluorescent staining of exoerythrocytic schizonts of *Plasmodium berghei* in fixed liver tissue with stage-specific immune serum. *J. Parasitol.* 64:1123-1125.
- De Waele, M., W. Renmans, E. Segers, K. Jochmans, and B. Van Camp. 1988. Sensitive detection of immunogold-silver staining with darkfield and epi-polarization microscopy. *J. Histochem. Cytochem.* 36:679-683.
- Hamilton, A. J., A. Suhrbier, J. Nicholas, and R. E. Sinden. 1988. Immunoelectron microscopic localization of circumsporozoite antigen in the differentiating exoerythrocytic trophozoite of *Plasmodium berghei*. *Cell Biol. Int. Rep.* 12:123-129.
- Hollingdale, M. R., P. Leland, J. L. Leef, M. F. Leef, and R. L. Beaudoin. 1983. Serological reactivity of in vitro cultured exoerythrocytic stages of *Plasmodium berghei* in indirect immunofluorescent or immunoperoxidase antibody tests. *Am. J. Trop. Med. Hyg.* 32:24-30.
- Hollingdale, M. R., P. Leland, J. L. Leef, and A. L. Schwartz. 1983. Entry of *Plasmodium berghei* sporozoites into cultured cells, and their transformation into trophozoites. *Am. J. Trop. Med. Hyg.* 32:685-690.
- Hyman, B. C., and A. J. MacInnis. 1979. Rapid detection of malaria and other bloodstream parasites by fluorescence microscopy with 4',6-diamidino-2-phenylindole (DAPI). *J. Parasitol.* 65:421-425.
- Khan, Z., and J. P. Vanderberg. 1991. Eosinophil-rich, granulomatous inflammatory response to *Plasmodium berghei* hepatic schizonts in non-immunized rats is age-related. *Am. J. Trop. Med. Hyg.* 45:190-201.
- Krotoski, W. A., W. E. Collins, and J. R. Jumper. 1973. Detection of early exoerythrocytic schizonts of *Plasmodium cynomolgi* by immunofluorescence. *Am. J. Trop. Med. Hyg.* 22:443-451.
- Kumar, R. K. 1989. Immunogold-silver cytochemistry using a capillary action staining system. *J. Histochem. Cytochem.* 37:913-917.
- Meis, J. F., J. P. Verhave, P. H. Jap, and J. H. E. T. Meuwissen. 1983. An ultrastructural study on the role of Kupffer cells in the process of infection by *Plasmodium berghei* sporozoites in rats. *Parasitology* 86:231-242.
- Meis, J. F., J. P. Verhave, P. H. Jap, and J. H. E. T. Meuwissen.

1985. Transformation of sporozoites of *Plasmodium berghei* into exoerythrocytic forms in the liver of its mammalian host. *Cell Tissue Res.* **241**:353–360.
15. Meis, J. F., J. P. Verhave, P. H. Jap, R. E. Sinden, and J. H. E. T. Meuwissen. 1983. Malaria parasites—discovery of the early liver form. *Nature (London)* **302**:424–426.
  16. Pollard, K., D. Lunny, C. S. Holgate, P. Jackson, and C. C. Bird. 1987. Fixation, processing, and immunochemical reagent effects on preservation of T-lymphocyte surface membrane antigens in paraffin-embedded tissue. *J. Histochem. Cytochem.* **35**:1329–1338.
  17. Romero, P., J. L. Maryanski, G. Corradin, R. S. Nussenzweig, V. Nussenzweig, and F. Zavala. 1989. Cloned cytotoxic T cells recognize an epitope in the circumsporozoite protein and protect against malaria. *Nature (London)* **341**:323–346.
  18. Smith, J. E., J. F. Meis, T. Ponnudurai, J. P. Verhave, and H. J. Moshage. 1984. In-vitro culture of exoerythrocytic form of *Plasmodium falciparum* in adult human hepatocytes. *Lancet* **ii**:757–758.
  19. Stewart, M. J., and J. P. Vanderberg. 1991. Malaria sporozoites release circumsporozoite protein from their apical end and translocate it along their surface. *J. Protozool.* **38**:411–421.
  20. Suhrbier, A., A. J. Hamilton, J. Nicholas, and R. E. Sinden. 1988. The fate of the circumsporozoite antigens during the exoerythrocytic stage of *Plasmodium berghei*. *Eur. J. Cell Biol.* **46**:25–30.
  21. Vanderberg, J. P. 1977. *Plasmodium berghei*: quantitation of sporozoites injected by mosquitoes feeding on a rodent host. *Exp. Parasitol.* **42**:169–181.
  22. Vanderberg, J. P., S. Chew, and M. J. Stewart. 1990. *Plasmodium* sporozoite interactions with macrophages in vitro: a videomicroscopic analysis. *J. Protozool.* **37**:528–536.
  23. Vanderberg, J. P., and R. Gwadz. 1980. The transmission by mosquitoes of plasmodia in the laboratory, p. 153–234. In J. Kreier (ed.), *Research in malaria*, vol. II. Academic Press, Inc., New York.
  24. Vanderberg, J. P., R. S. Nussenzweig, and H. Most. 1969. Protective immunity produced by the injection of X-irradiated sporozoites of *Plasmodium berghei*. V. In vitro effects of immune serum on sporozoites. *Mil. Med. (Suppl.)* **134**:1183–1190.
  25. Weiss, W. R., S. Mellouk, R. A. Houghten, M. Sedegah, S. Kumar, M. F. Good, J. A. Berzofsky, L. H. Miller, and S. L. Hoffman. 1990. Cytotoxic T cells recognize a peptide from the circumsporozoite protein on malaria-infected hepatocytes. *J. Exp. Med.* **171**:763–773.
  26. Weiss, M., and J. P. Vanderberg. 1976. Studies on *Plasmodium* ookinetes. 1. Isolation and concentration from mosquito mid-guts. *J. Protozool.* **23**:547–551.
  27. Yoshida, N., R. S. Nussenzweig, P. Potocnjak, V. Nussenzweig, and M. Aikawa. 1980. Hybridoma produces protective antibodies directed against the sporozoite stage of malaria parasite. *Science* **207**:71–73.