

Ontogeny of ECL Cells in the Rat

Frank Sundler^a

*Department of Physiology and Neuroscience, Section of Neuroendocrine
Cell Biology, Lund University, Sweden*

ECL cells produce histamine and chromogranin A, and are restricted to the oxyntic mucosa of the stomach. ECL cell ontogeny has been studied in some detail in the rat. Using histidine decarboxylase immunostaining, the first ECL cells can be demonstrated at embryonic day 17. Immunoreactive histamine and chromogranin A appear one day later. At embryonic day 20, the vesicular monoamine transporter type 2 is also present in the ECL cells. Neonatally the ECL cell proliferation is slow; however, one to three weeks postnatally there is a rapid growth of ECL cells to populate the basal half of the glands. Gastrin is known to be an important stimulator of ECL cell activity and growth in the adult rat. As revealed in recent mouse gene knock out models gastrin does not seem to play a role in the early ECL cell differentiation and development.

INTRODUCTION

The ECL cells have a characteristic and restricted distribution in the gastrointestinal tract, being confined to the oxyntic mucosa of the stomach. Here, they constitute the predominant endocrine cell type [1, 2]. The cells are unique among gut neuroendocrine cells in that they have the ability to produce histamine [1-3]. This is a feature shared by the ECL cells in all species examined so far, including several mammals as well as a number of submammalian vertebrates [1-4]. Histamine is produced by the action of the enzyme histidine decarboxylase (HDC)^b, the presence of which in the ECL cells of rodents is well documented [3, 5]. It is also well established that gastrin is a key hormone for the regulation of ECL cell histamine production and secretion. Thus, the HDC activity in the ECL cells is subject to wide variations depending primarily on the circulating gastrin level [4-6].

Most of the knowledge on ECL cell biology has been gained from studies of the rat, where the cells are comparatively numerous and rich in histamine. In e.g., humans, they are considerably less numerous and contain less histamine [7, 8]. The ECL cells are also known to produce chromogranin A, an acidic protein stored in the secretory granules together with histamine [7-10].

In the ECL cells, presumably within the secretory granules, chromogranin A is proteolytically processed to yield, e.g., pancreastatin. Interestingly, in the rat circulating pancreastatin may serve as a marker for the ECL cells, emphasizing the great size of the ECL cell population in this species [10].

Recently data are accumulating to indicate that the ECL cells express the amine transporter VMAT-2 (vesicular monoamine transporter type 2) [11]. Presumably this transporter molecule serves to transfer newly formed histamine from the cytoplasm into the secretory granules for storage. Thus, VMAT-2 may serve as an additional marker for the ECL cells.

^aTo whom all correspondence should be addressed: Prof. Frank Sundler, Dept. of Physiology and Neuroscience, Neuroendocrine Cell Biology, E-blocket, 5:e vån. University Hospital, S-221 85 Lund, Sweden. Tel.: 46-46-17-77-10; Fax: 46-46-17-77-20.

^bAbbreviations: HDC, histidine decarboxylase; VMAT-2, vesicular monoamine transporter type 2; OPT, o-phtalaldehyde; APUD, amine precursor uptake and decarboxylation; L-DOPA, L-dihydroxy-phenylalanine.

ECL CELL ONTOGENY

So far, most data related to the ontogeny of the ECL cells have been obtained in the rat (for a review, see [12]). In early studies the OPT (o-phtalaldehyde) histofluorescence technique was used to demonstrate histamine in tissue sections. However, this method failed to reveal cells in the epithelium of the oxyntic mucosa before birth; not until a few days after birth could the first OPT-reactive endocrine cells be detected [13]. Studies utilizing the APUD (amine precursor uptake and decarboxylation) mechanism, which the ECL cells share with many other gut endocrine cells, revealed cells accumulating dopamine after preloading with L-DOPA in the oxyntic mucosa immediately before birth [14, 15].

Electron microscopy has also been used to reveal cells with the characteristic ultrastructural features of the ECL cells. However, cells with vesicular-type secretory granules typical of mature ECL cells could not be demonstrated until after birth [15].

Assays for HDC activity in the oxyntic mucosa have revealed barely detectable levels at birth. The enzyme activity increases slowly during the first postnatal week, and then more rapidly during the second and third weeks, coinciding with a marked rise in circulating gastrin levels, with both HDC and gastrin reaching high levels at the weaning period [15].

In more recent studies, employing immunocytochemistry for the demonstration of histamine, immunoreactive endocrine-like cells were detected in the oxyntic mucosa of the rat already at embryonic day 18 (E 18) [16, 17]. These data give a clear indication that the first ECL cells in the rat appear well before birth. As judged by the failure of endocrine cells in the oxyntic mucosa to exhibit APUD characteristics and characteristic ultrastructural features of ECL cells, the histamine-storing cells detected prenatally may be regarded as still immature ECL cells.

Studies in the fetal mouse stomach have revealed histamine-immunoreactive epithelial cells, interpreted as ECL cells, already at E15, suggesting that the ECL cells make their debut somewhat earlier in the mouse than in the rat [18]. In the stomach of the developing rat HDC mRNA expression has also been examined by *in situ* hybridization [17]. A clear signal was, however, not detected in the oxyntic mucosa until after birth, suggesting only low levels of HDC expression, undetectable with the *in situ* hybridization technique, in the first ECL cells appearing before birth. Using HDC immunocytochemistry, the first immunoreactive epithelial cells in the oxyntic mucosa of the rat can be detected at day E17 (Figure 1a). At this stage the cells are rare and located basally in the thin, poorly differentiated epithelium. A couple of days later the cells are provided with short processes (Figure 1b). The number of cells and the HDC immunostaining intensity increases slowly during the following days (Figure 1b). After birth, HDC-immunoreactive ECL cells gradually increase in number to become numerous two to three weeks postnatally (Figure 1c). At this stage, most of them are provided with cytoplasmic processes typical of mature ECL cells. Cells displaying chromogranin A/pancreastatin immunoreactivity are first seen at E 18 (Figure 2a). They are at this stage rare and weakly stained. The number of chromogranin A/pancreastatin-immunoreactive cells increases slowly during the following days, as judged by double immunostaining for HDC and chromogranin A, and some, but not all of them are identical with the cells containing immunoreactive HDC. Thus, chromogranin A seems to appear at the same stage in the fetal rat (E 18) as does histamine [16]. This makes sense, since both are thought to be stored in the same secretory granules.

Interestingly VMAT-2 immunoreactivity, abundantly observed in the ECL cells of the adult rat (Figure 3), can be demonstrated in the ECL cells before birth (Figure 3b). Thus, the ECL cells seem to acquire the ability to transport histamine into secretory granules at about the same time, or slightly after the amine starts to form and the secretory granules appear in the cells. Ultrastructural examination of the neonatal rat oxyntic mucosa reveals the appearance of endocrine-like cells with very few, basally located small round and electron-

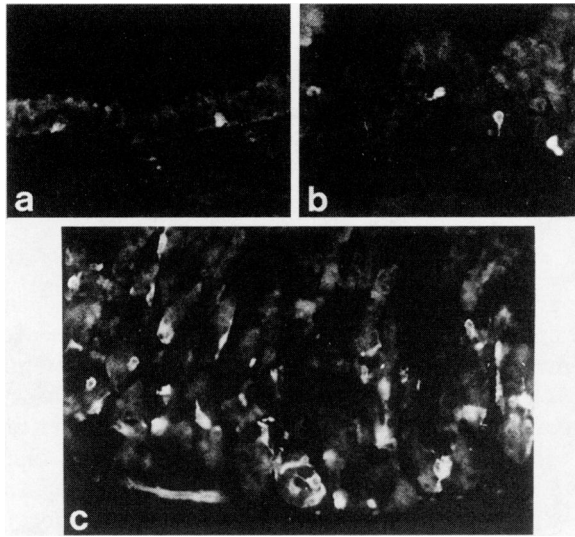


Figure 1. HDC immunofluorescence in oxyntic mucosa of fetal (stage E17) (a), newborn (b) and 14 d old (c) rats. HDC-immunoreactive cells, interpreted as ECL cells are first detected at E17. At this stage they are rare and located basally in the thin, flat epithelium. At birth ECL cells are still few, but more intensely immunoreactive and provided with delicate cytoplasmic processes. At 14 d postnatally the ECL cells are numerous and furnished with extensive cytoplasmic processes giving the impression of an ECL cell "syncytium" at the base of the glands. (x200).

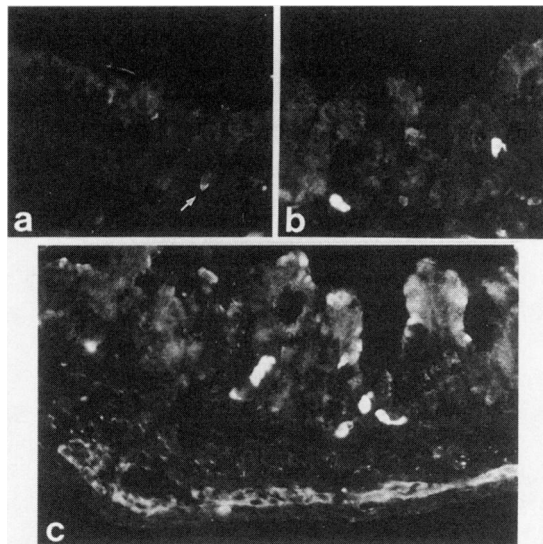


Figure 2. Chromogranin A immunofluorescence in oxyntic mucosa of fetal (stage E18) (a), (stage E20) (b) and newborn (c) rats. Chromogranin A-immunoreactive cells are first detected at E18 (arrow in a); they become more numerous and more intensely immunoreactive at later embryonic stages and are readily demonstrated at birth. A subpopulation of the cells is known to be identical with ECL cells. (x 200)

dense secretory granules at birth, together with cells having a mixed population of such granules and large, electron-lucent mucus-type vesicles (Figure 4a and 4b). Only at post-natal day four can cells and cell processes containing vesicular type granules characteristic of mature ECL cells be seen (Figure 4c). Thus, the ECL cells seem to obtain the ability to produce and store histamine and chromogranin A before the secretory granules have the ultrastructural features of the mature cells.

ECL CELL ONTOGENY: RELATION TO GASTRIN

There is strong evidence that gastrin plays a key role in the maintenance of the ECL cell population and in the regulation of the ECL cell activity; gastrin seems to be instrumental also in bringing about the ECL cell proliferation upon long-term blockade of acid secretion [2, 9, 12, 46].

How does the development of the ECL cells relate to the development of cells producing gastrin? It is generally agreed that in the rat the first gastrin-immunoreactive cells appear in the antrum just before birth. They remain, however, very few in this location during the first week postnatally, but then increase rapidly in number during the second postnatal week, to reach a high density at the time of weaning [15, 19]. However, it is worth mentioning in this context that in the rat, the pancreas is a rich source of gastrin, both in the form of progastrin and bioactive amidated gastrins, during the neonatal period [15, 20, 21]. Interestingly, the pancreatic gastrin cells develop earlier than the antral gastrin cells to reach a high density at birth. A few days after birth the cells decrease in number only to disappear from the pancreas during the second postnatal week [15, 19]. Thus, at least in the rat gastrin is produced before ECL cells make their debut, and a role for gastrin in the initiation of ECL cell development is thus possible. However, against such a role of gastrin speak recent data from mice deficient in gastrin receptors due to targeted disruption of the CCK-B receptor gene [22, 23]. In such mice, chromogranin A and HDC mRNA

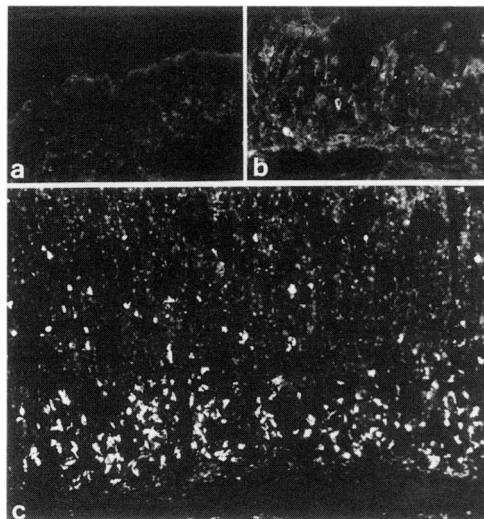


Figure 3. Vesicular monoamine transporter type 2 (VMAT-2) immunofluorescence in oxyntic mucosa of fetal (stage E17) (a), newborn (b) and adult (c) rats. VMAT-2-immunoreactive cells are lacking at E17. They are few and weakly immunoreactive at birth, but numerous and strongly immunoreactive in the adult rat. The bulk of VMAT-2 producing cells in the oxyntic mucosa of the adult rat are known to be ECL cells (x150).

abundance in the oxyntic mucosa is markedly reduced, but there remains a population of endocrine cells interpreted as ECL cells. Similar observations, i.e., remaining cells with the characteristics of ECL cells, have been made also in mice lacking gastrin due to targeted disruption of the gastrin gene [24]. In the gastrin deficient mice the ECL cells are quite small, poor in HDC, and accumulated at the base of the gland. This is in contrast to the wild type mice where the ECL cells in the oxyntic mucosa are often quite large, furnished with cytoplasmic processes and distributed along the basal half of the glands. The presence of recognizable ECL cells in mice lacking gastrin receptors or gastrin, indicate that ECL cells can be generated without gastrin. Gastrin seems to be important primarily for regulating the ECL cell activity, reflected in the histamine and chromogranin A production, and the size of the cell population. A role for gastrin in the proper spread of the cells along the glands seems also likely.

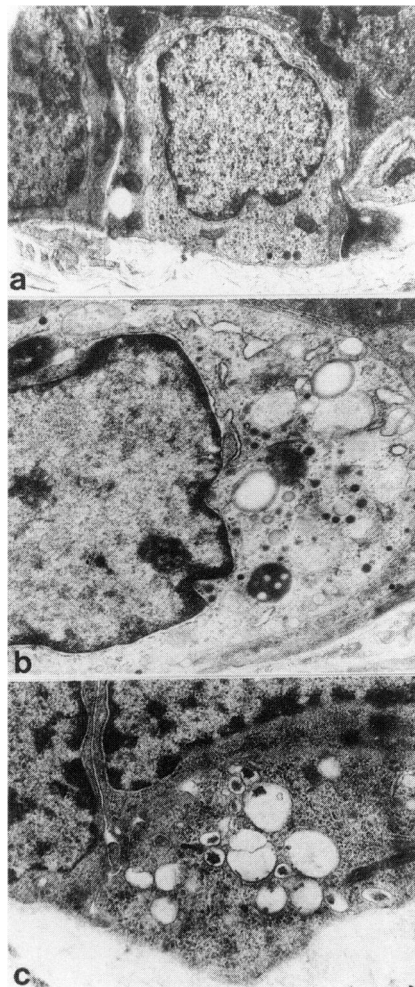


Figure 4. Electron micrographs showing endocrine cells in the oxyntic mucosa of newborn (a and b) and 4-day-old (c) rats. Cells with endocrine features, such as small, electron dense secretory granules, sometimes together with large electron lucent mucoid droplets, but lacking ECL cell characteristics are seen at birth. At day 4 postnatally, cells with vesicular-type secretory granules, typical of ECL cells, are detected (a: x8,000; b: x10,000; c: x12,000)

Acknowledgments: Grant support from Swedish MRC (project no. 4499) and the Pahlsson Foundation, and from the Medical Faculty, University of Lund.

REFERENCES

1. Håkanson, R., Böttcher, G., Ekblad, E., Panula, P., Simonsson, M., Dohlsten, M., Hallberg, T., and Sundler, F. Histamine in endocrine cells in the stomach. A survey of several species using a panel of histamine antibodies. *Histochemistry* 86:5-17, 1986.
2. Håkanson, R., Chen, D., and Sundler F. The ECL cells. In: Johnson, L.R., ed. *Physiology of the Gastrointestinal Tract*, Third Edition. New York: Raven Press; 1994. pp. 1171-1184.
3. Kubota, H., Taguchi, Y., Tohyama, M., Matsuura, M., Shiosaka, S., Ishihara, T., Watanabe, T., Shiotani, Y., and Wada, H. Electron microscopic identification of histidine decarboxylase-containing endocrine cells of the rat gastric mucosa: an immunohistochemical analysis. *Gastroenterology* 87:496-502, 1984.
4. Håkanson, R., Tielemans, Y., Chen, D., Andersson, K., Ryberg, B., Mattsson, H., and Sundler, F. The biology and pathobiology of the ECL cells. *Yale J. Biol. Med.* 65:761-774, 1992.
5. Larsson, H., Carlsson, E., Mattsson, H., Lundell, L., Sundler, F., Sundell, G., Wallmark, B., Watanabe, T., and Håkanson, R. Plasma gastrin and gastric enterochromaffin-like cell activation and proliferation. Studies with omeprazole and ranitidine in intact and antrectomized rats. *Gastroenterology* 90:391-399, 1986.
6. Sandvik, A.K., Dimaline, R., Mårvik, R., Brenna, E., Waldum, H.L. Gastrin regulates histidine decarboxylase activity and mRNA abundance in rat oxyntic mucosa. *Am. J. Physiol.* 267:G 254-G258, 1994.
7. Simonsson, M., Eriksson, S., Håkanson, R., Lind, T., Lönnroth, H., Lundell, L., O'Connor, T., and Sundler, F. Endocrine cells in the human oxyntic mucosa: a histochemical study. *Scand. J. Gastroenterol.* 23:1089-1099, 1988.
8. Lönnroth, H., Håkanson, R., Lundell, L., and Sundler, F. Histamine-containing endocrine cells in the human stomach. *Gut* 31:383-388, 1990.
9. Dockray, G.J., Varro, A., and Dimaline, R. Gastric endocrine cells: gene expression, processing and targeting of active products. *Physiol. Rev.* 76:767-798, 1996.
10. Håkanson, R., Ding, X-Q., Norlén, P., and Chen, D. Circulating pancreastatin is a marker for the enterochromaffin-like cells of the rat stomach. *Gastroenterology* 108:1445-1452, 1995.
11. Dimaline, R. and Struthers, J. Expression and regulation of a vesicular monoamine transporter in rat stomach: a putative histamine transporter. *J. Physiol.* 490:249-256, 1996.
12. Modlin, I.M. and Tang, L.H. The gastric enterochromaffin-like cell: an enigmatic cellular link. *Gastroenterology* 111:783-810, 1996.
13. Håkanson, R., Owman, Ch., and Sjöberg, N-O. Cellular stores of gastric histamine in the developing rat. *Life Sci.* 6:535-2543, 1967.
14. Håkanson, R., Owman, Ch., and Sjöberg, N-O. Three different systems of monoamine- storing cells in the gastrointestinal tract of fetal and neonatal rats. *Acta Physiol. Scand.* 75:213-220, 1969.
15. Ekelund, M., Håkanson, R., Hedenbro, J., Rehfeld, J.F., and Sundler, F. Endocrine cells and parietal cells in the stomach of the developing rat. *Acta Physiol. Scand.* 124:483-497, 1985.
16. Nissinen, M.J., Håkanson, R., and Panula, P. Ontogeny of histamine-immunoreactive cells in rat stomach. *Cell Tissue Res.* 267:241-249, 1992.
17. Nissinen, M.J., Karlstedt, K., Castrén, E., and Panula, P. Expression of histidine decarboxylase and cellular histamine-like immunoreactivity in rat embryogenesis. *J. Histochem. Cytochem.* 45:1241-1252, 1995.
18. Nissinen, M.J. and Panula, P. Developmental patterns of histamine-like immunoreactivity in the mouse. *J. Histochem. Cytochem.* 43:211-227, 1995.
19. Ondolfo, J.P. and Lehy, T. Comparative development of gastrin and somatostatin cell populations in the pancreas, stomach and duodenum of the rat during the perinatal period. *Anat. Rec.* 218:416-425, 1987.
20. Larsson, L-I., Rehfeld, J., Sundler, F., and Håkanson, R. Pancreatic gastrin in fetal and neonatal rats. *Nature* 262:609-610, 1976.
21. Bardram, L., Hilsted, L., and Rehfeld, J.F. Progastrin expression in mammalian pancreas. *Proc. Natl. Acad. Sci. USA* 87:298-302, 1990.

22. Nagata, A., Ito, M., Iwata, N., Kuno, J., Takano, H., Minowa, O., Chihara, K., Matsui, T., and Noda, T.G. Protein-coupled cholecystokinin-B/gastrin receptors are responsible for physiological cell growth of the stomach mucosa *in vivo*. Proc. Natl. Acad. Sci. USA 93:11825-11830, 1996.
23. Langhans, N., Rindi, G., Chiu, M., Rehfeld, J.F., Ardman, B., Beinborn, M., Kopin, A.S. Abnormal gastric histology and decreased acid production in cholecystokinin-B/gastrin receptor-deficient mice. Gastroenterology 112:280-286, 1997.
24. Friis-Hansen, L., Sundler, F., Li, Y., Gillespie, P.J., Saunders, T.L., Greenson, J.K., Owyang, C., Rehfeld, J.F., and Samuelson, L.C. Impaired gastric acid secretion in gastrin-deficient mice. Am. J. Physiol 274(Gastrointest. Liver Physiol 37):G561-G568, 1998.