

# CASE REPORTS

## Endometriosis of the Appendix

Nasser S. Al Oulaqi<sup>1</sup>, Ashraf F. Hefny<sup>1</sup>, Sandhya Joshi<sup>2</sup>, Khalid Salim<sup>1</sup>, Fikri M. Abu-Zidan<sup>3</sup>

Departments of Surgery<sup>1</sup> and Pathology<sup>2</sup>, Al-Ain Hospital, and Department of Surgery Faculty of Medicine and Health Sciences, United Arab Emirates University<sup>3</sup>, Al-Ain, United Arab Emirates.

### Abstract

Endometriosis is a well known cause of infertility. Endometriosis of the appendix is a very rare condition. To highlight this rare entity, we are reporting a case of a young lady who was admitted with recurrent attacks of lower abdominal pain associated with primary infertility. Preoperative diagnosis was acute appendicitis. Histopathological examination of the appendix revealed endometriosis. Endometriosis should be considered in the differential diagnosis of recurrent lower abdominal pain in young females especially with history of infertility.

Key words: appendix, endometriosis, female, infertility.

*African Health Sciences* 2008; 8(3): 196-198

### Introduction

Endometriosis is the presence of ectopic endometrial tissues outside the lining of uterine cavity<sup>1</sup>. It is a well known cause of chronic pelvic pain and infertility in females. Endometriosis of the appendix is rare and may present with acute or chronic abdominal pain. Preoperative diagnosis is difficult. The definitive diagnosis is usually established following histopathological examination of the appendix. Laparoscopy is the procedure of choice for the diagnosis and surgical treatment of endometriosis<sup>2</sup>. Herein we report a case of appendiceal endometriosis clinically presenting with recurrent attacks of abdominal pain associated with primary infertility which was diagnosed preoperatively as acute appendicitis.

### Case Report

A twenty-five year old lady was admitted complaining of right lower abdominal pain of one day duration. The pain was associated with nausea and vomiting. She had no vaginal discharge. Her menstrual cycles were regular, and she was on her 11<sup>th</sup> day of menstrual cycle. The patient had a history of primary infertility. On examination, the patient was not feverish, her pulse was 90 beat per minute, and her blood pressure was 120/80 mmHg. Abdominal examination showed guarding and tenderness in the lower abdomen with positive rebound tenderness. White blood cell count, electrolytes, and

urine analysis were normal. Pregnancy test was negative. Vaginal swab has shown no bacterial growth. Pelvic ultrasound has shown normal uterus and ovaries.

The patient was discharged home and advised to be followed up in the gynecological clinic. Three months later, the patient was re-admitted having the same complaint, and she was on her 10<sup>th</sup> day of menstrual cycle. Gynecological examination revealed vaginal discharge with tender adnexa but no masses could be felt. Laboratory tests and pelvic ultrasound were normal. The patient was discharged home after two days. Four months later the patient was re-admitted with right lower abdominal pain associated with diarrhea without nausea or vomiting. She was on her fourth day of menstrual cycle and laboratory tests were also normal. Pelvic ultrasound examination has revealed a small cyst in the right ovary. Intravenous pyelography was normal. After five days the patient was discharged home and was advised to be followed up in both gynecology and psychiatric clinics.

Nine months later, the patient was re-admitted with the same complaint for the fourth time. She was on her 17<sup>th</sup> day of menstrual cycle. Laboratory tests were normal. Open appendectomy was performed. Grossly, the appendix was normal with unremarkable serosa. There were no signs of endometriosis in other intra-abdominal locations of the operative field. Post operative period was uneventful. Histological examination of the appendix has shown unremarkable mucosa with few lymphoid follicles; the wall was irregularly thickened and showed endometrial glands and stromal cells embedded within the muscularis propria (Figure 1).

#### Correspondence

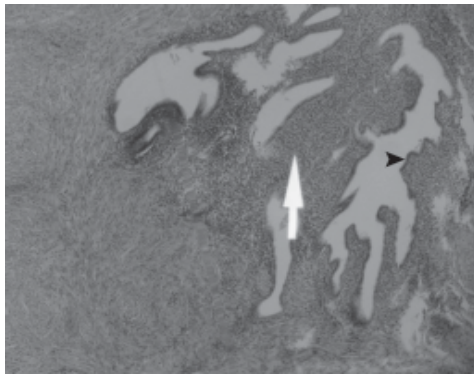
Ashraf Hefny

Specialist Surgeon, Department of Surgery, Al-Ain Hospital,  
PO Box 1006, Al-Ain, United Arab Emirates

Tel: +971 505232745, Fax: +971 37634222

E-mail: [hefnyashraf@hotmail.com](mailto:hefnyashraf@hotmail.com)

**Fig 1: Endometrial glands (arrow head) and stromal cells (arrow) embedded within the muscularis propria of the appendix.**



### Discussion

Endometriosis is usually associated with dysmenorrhea, chronic pelvic pain, and infertility<sup>3</sup>. Although some women with intestinal endometriosis remain asymptomatic, some of them come to medical attention because of abdominal pain, bowel obstruction, or an abdominal mass<sup>4</sup>.

Endometriosis of the appendix is rare. The prevalence of appendiceal endometriosis in patients with endometriosis is 2.8%<sup>5</sup>. Involvement of the appendix may present as appendicitis, mucocele of appendix, or appendicular mass that may mimic a neoplasm. Perforation of the appendix may occur especially during the first two trimesters of pregnancy<sup>4,6</sup>.

Our patient had a history of primary infertility with recurrent attacks of incapacitating lower abdominal pain which was not related to her menstruation. Endometriosis was never suspected preoperatively<sup>8</sup>. Many patients with appendiceal endometriosis experience chronic pelvic pain with significant decrease in the quality of life. Long term symptoms resolution was noticed following appendectomy<sup>9</sup>.

In one study of two hundred consecutive endometriosis operations with routine appendectomy, three occurrences of macroscopic appendiceal endometriosis were identified and proved on microscopic examination. In situ microscopic endometriosis of the appendix without macroscopic disease was not encountered<sup>10</sup>. In contrast, another study including 106 patients with routine appendectomy during laparoscopic treatment of ovarian endometriosis has shown gross abnormality only in 3.3% while microscopic examination has shown endometriosis of the appendix in 13.2% of patients<sup>11</sup>. In our patient, gross inspection of the appendix didn't give any hint of the diagnosis while microscopic examination has shown

features of endometriosis. Our patient had open appendectomy through gridiron incision with incidental finding of appendiceal endometriosis. Laparoscopic surgery may have been more useful in defining other locations of endometriosis.

If the standard pathological evaluation by H&E stain failed to demonstrate the endometrial tissue, appendiceal endometriosis can be suspected by marked increase in the number of mast cells in the muscularis propria which is known as catamenial appendicitis<sup>9</sup>.

The causes of infertility in patients with endometriosis remain uncertain. Laparoscopic ablation of endometriosis in combination with medical treatment improves fertility<sup>12</sup>. Appendectomy may be considered as part of the surgical ablation. Incidental appendectomy during surgical treatment of pelvic endometriosis is controversial<sup>10,11</sup>. Preoperative counseling and obtaining consent for appendectomy is important<sup>5</sup>.

*In summary* endometriosis of the appendix can mimic appendicitis and it should always be considered in the differential diagnosis of young women complaining of nonspecific recurrent lower abdominal pain especially with history of infertility.

### References

1. Khoo JJ, Ismail MS, Tiu CC. Endometriosis of the appendix presenting as acute appendicitis. *Singapore Med J* 2004; 45:435-436.
2. Idetsu A, Ojima H, Saito K, Yamauchi H, Yamaki E, Hosouchi Y, Nishida Y, Kuwano H. Laparoscopic appendectomy for appendiceal endometriosis presenting as acute appendicitis: Report of a case. *Surg Today* 2007; 37:510-513.
3. Offodile A 2nd, Hodgins JB, Arnell T. Asymptomatic intussusception of the appendix secondary to endometriosis. *Am Surg* 2007; 73:299-301.
4. Yantiss RK, Clement PB, Young RH. Endometriosis of the intestinal tract: A study of 44 cases of a disease that may cause diverse challenges in clinical and pathological evaluation. *Am J Surg Pathol* 2001; 25:445-454.
5. Gustofson RL, Kim N, Liu S, Stratton P. Endometriosis and the appendix: a case series and comprehensive review of the literature. *Fertil Steril* 2006; 86: 298-303.
6. Driman DK, Melega DE, Vilos GA, Plewes EA. Mucocele of the appendix secondary to endometriosis. Report of two cases, one with localized pseudomyxoma peritonei. *Am J Clin Pathol* 2000; 113:860-864.
7. Phupong V, Rungruksirivorn T, Tantirojn P, Triratanachai S, Vasuratna A. Infected endometrioma in pregnancy masquerading as acute appendicitis. *Arch Gynecol Obstet* 2004; 269:219-220.
8. Stefanidis Konstantinos, Kontostolis Stylianos, Pappa Lambrini, Kontostolis Emmanuel. Endometriosis of the appendix with symptoms of acute appendicitis in pregnancy. *Obstet Gynecol* 1999; 93:850.

9. Barrier BF, Frazier SR, Brennaman LM, Taylor JC, Ramshaw BJ. Catamenial appendicitis. *Obstet Gynecol* 2008; 111:558-561.
10. Wie HJ, Lee JH, Kyung MS, Jung US, Choi JS. Is incidental appendectomy necessary in women with ovarian endometrioma? *Aust N J Z Obstet Gynaecol* 2008; 48:107-111.
11. Harper A J, Soules MR. Appendectomy as a consideration in operations for endometriosis. *Int J Gynaecol Obstet* 2002; 79:53-54.
12. Ozkan S, Murk W, Arici A. Endometriosis and infertility: epidemiology and evidence-based treatments. *Ann NY Acad Sci* 2008; 1127:92-100.