

Distribution of Somatostatin Receptors in Normal and Neoplastic Human Tissues: Recent Advances and Potential Relevance

J.C. Reubi^a, J.-C. Schaer, R. Markwalder, B. Waser,
U. Horisberger and J. Laissue

*Division of Cell Biology and Experimental Cancer Research,
Institute of Pathology, University of Berne, Switzerland*

(Received January 30, 1997; returned for revision February 16, 1998; accepted March 9, 1998)

This short review describes the localization of somatostatin receptors with *in vitro* receptor autoradiography techniques in several non-classical, normal human somatostatin target tissues as well as in selected human tumors. In addition to brain, gut and neuroendocrine localizations, somatostatin receptors are expressed in most lymphatic tissues, including gut-associated lymphatic tissue, spleen and thymus; in the cortical and medullary area of the kidney; in the stroma of the prostate and in the epithelial cells of the thyroid. Among human tumors, the extremely high density of somatostatin receptors in medulloblastomas should be stressed as well as the favorable prognostic role of the presence of somatostatin receptors in neuroblastomas. Moreover, several types of mesenchymal tumors have somatostatin receptors as well. The receptor subtypes expressed by distinct tumors may vary: Whereas medulloblastomas and neuroblastomas predominantly express sst2, prostate cancers express sst1 rather than sst2. A further emerging somatostatin target is represented by the peritumoral veins, also known to express sst2 receptors. The multiple somatostatin targets in normal and pathological human tissues represents the basis for potential diagnostic and clinical applications of somatostatin analogs.

INTRODUCTION

In the last decade, somatostatin receptors (sst)^b were identified in a multitude of normal human tissues as well as in several types of human tumors. These data have been reviewed in detail elsewhere [1, 2]. In this article, we would like to focus on a number of recent data regarding sst distribution in a few selected normal and diseased human tissues.

SST IN NORMAL HUMAN TISSUES

Lymphatic tissue

In addition to the nervous system, endocrine system and gastrointestinal tract, the human lymphatic tissue represents one of the important sites of sst expression in the human body, as observed with *in vitro* receptor autoradiography. As seen in Table 1, several lymphatic organs can express sst: in the gut-associated lymphatic tissue (GALT), all lymphoid follicles containing germinal centers can be shown to express sst, which are preferentially

^a To whom all correspondence should be addressed: J.C. Reubi, M.D., Professor of Pathology, Division of Cell Biology and Experimental Cancer Research, Institute of Pathology, University of Berne, Murtenstrasse 31, CH-3010 Berne, Switzerland. Tel.: 31-632-32-42; Fax: 31-632-89-99 or 31-632-49-95.

^b Abbreviations: sst, somatostatin receptors; GALT, gut-associated lymphatic tissue; GEP, gastroenteropancreatic.

Table 1. Localization of sst in human lymphatic tissue.

Tissues	Site
Lymph nodes	Germinal centers
Tonsils	Germinal centers
Peyer's patches	Germinal centers
Solitary follicles (colon)	Germinal centers
Appendix	Germinal centers
Spleen	Red pulp
Thymus	Medulla

A sst subtype evaluation of these tissues is not yet available; however, the excellent labeling of these sites by ^{125}I -[Tyr³]-octreotide [4] indicates a strong expression of sst2.

located in the germinal centers, consisting primarily of activated lymphocytes [3]. Moreover, the red pulpa of the spleen is a further site of sst expression. Finally, the thymus also appears to be a site of sst expression. All samples from normal thymus in young children and adult individuals contained sst located in the thymic medulla. Because the medulla appears diffusely and homogeneously labeled and because the autoradiographic technique does not allow assigning the label to a given cell, we do not know whether sst are located on epithelial cells, stroma, reticulo-endothelial cells or on lymphocytes. No significant labeling was observed in the cortex nor in Hassal's corpuscles [4]. The majority of the sst in the lymphatic organs probably belong to the sst2 subtype, as they can bind octreotide with high affinity. However, a precise analysis of the sst subtypes expressed by lymphatic tissues is not yet available. The role of somatostatin in human lymphatic tissues has not been clearly established either.

Kidney

Specific and high affinity sst have been identified in the human kidney. Microscopic localization of these receptors was revealed by radioligand binding over cortical and medullary areas. In the cortex, the receptors were located in the proximal tubules [5]. In the medulla, sst were identified primarily in high density in medullary *vasa recta* (Figure 1). These sst probably belong to the sst2 subtype since they bind octreotide with high affinity. The distribution and density of sst in various regions of the renal cortex and medulla imply that somatostatin has multiple and possibly important functions in the human kidney. It is difficult, however, to evaluate the extent to which the localization of sst in various functional units, including *vasa recta* and proximal tubules, is compatible with the results of *in vivo* studies reporting the effects of pharmacological doses of somatostatin on kidney functions [6]. More studies investigating the physiology and pathophysiology of somatostatin in the human kidney are needed to understand its role in this organ and to predict whether the use of somatostatin analogs may be of potential interest in selected renal diseases.

Prostate

The human prostate expresses sst [7]. Unexpectedly, in all normal and hyperplastic prostates, the smooth muscles of the stroma, but not the glands, were shown to express the receptors (Figure 2). Muscular nodules were strongly receptor-positive as well. The receptors were of high affinity and high specificity for biologically active somatostatin analogs;

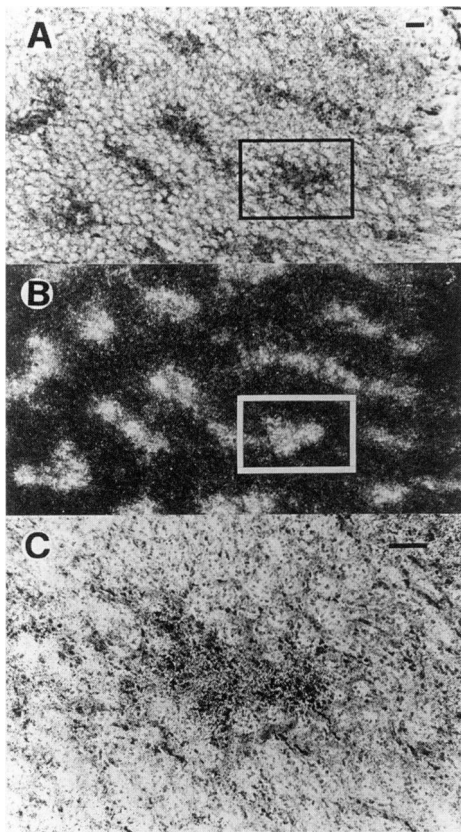


Figure 1. sst in the *vasa recta* of the medulla of a human kidney. Sections (A, stained with hematoxylin-eosin; Bar = 1 mm) were incubated with ^{125}I -[Tyr³]-octreotide and photoemulsion-coated to visualize sst in the *vasa recta* under dark-field illumination (B). C represents a detail of a group of *vasa recta* located in the black rectangle in A (Bar = 0.1 mm).

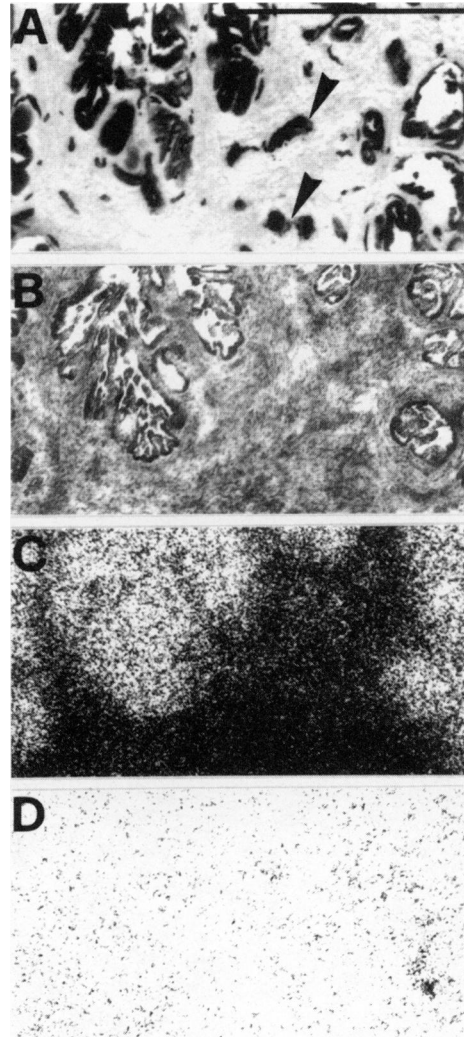


Figure 2. sst in a human prostate. A) F-VIII-like immunoreactivity showing strong labeling of prostatic glands and vessels (arrowheads). B) Hematoxylin-eosin stained section showing the glandular part surrounded by smooth muscle stroma. Bar = 1 mm. C) Autoradiogram showing total binding of ^{125}I -[Tyr³]-octreotide. Smooth muscles, but not glands, are labeled. D) Autoradiogram showing non-specific binding of ^{125}I -[Tyr³]-octreotide (in the presence of 10^{-6} mol/l unlabeled octreotide).

a high affinity for somatostatin-14, somatostatin-28 and octreotide was detected, suggesting the presence of the sst2 receptor subtype. *In situ* hybridization studies confirmed the presence of sst2 messenger ribonucleic acid in these tissues [7]. The presence of sst in prostate stromal cells was confirmed with other methods by Tatoud et al. [8].

No information regarding the precise role and function of sst in the prostate smooth muscle is presently available. Two sets of data suggest that the identified receptors may exist in relation with somatostatinergic neuronal input to the prostatic smooth muscle. First, the peripheral vegetative nervous system, in particular sympathetic efferents, is known to be somatostatinergic in various parts of the body. Second, the nervous prostatic plexus itself is rich in sst and, therefore, mediates somatostatin action. A somatostatinergic pathway to the prostatic smooth muscle may influence the contractility of the gland, independently of the indirect somatostatin action on the prostate mediated by the pituitary. Another possible role of sst in the prostatic stroma could be to influence the release of various growth factors synthesized in the stroma. As several of these growth factors act in a paracrine manner on the glandular part of the prostate to regulate prostate growth, somatostatin could indirectly regulate biological events in the prostatic gland through a stromal action.

Thyroid gland

We have recent data, using *in vitro* sst autoradiography, showing that surgically resected goiters of the human thyroid gland express sst. In all 15 goiters tested, we found sst having high affinity for octreotide and being located homogeneously in all epithelial cells [9]. Since most goiters consist of hyperplastic thyroid tissue, it is likely that similar receptor characteristics can be expected for the normal thyroid. The observed scintigraphic signal with Octreoscan in the normal thyroid, but also in the thyroid in Grave's disease [10], is likely to be due to sst localized on thyroid epithelial cells.

SST IN NEOPLASTIC TISSUES

General

A wide variety of human tumors express sst, which can be measured *in vitro* with radioligand binding techniques using ¹²⁵I-labeled somatostatin analogs in tumor homogenates or on tumor sections [1]. One of the tumor groups identified as having the highest incidence of sst are the neuroendocrine tumors, such as GH- and TSH-producing pituitary adenomas, non-secreting adenomas, as well as endocrine gastroenteropancreatic (GEP) tumors, pheochromocytomas, paragangliomas, medullary thyroid carcinomas and small-cell lung cancers. These tumors usually have a high density of sst, but a great individual variability in receptor density is observed. The clinical implications of these findings in terms of diagnosis and therapy have been discussed elsewhere [2, 10]. Other human tumors expressing sst include those of the nervous system (astrocytomas, neuroblastomas, meningiomas), malignant lymphomas, renal cell carcinomas and 50 percent of breast tumors.

Human tumors may express different sst subtypes [11]. As shown, for instance, with reverse transcriptase PCR and ribonuclease protection assay, pituitary adenomas appear to express all five sst subtypes, with particularly high levels of sst2 and sst5 [12, 13]. *In situ* hybridization for sst subtype mRNAs showed that other human tumor types can also express one or several of the sst subtypes [14, 15]. A frequently expressed subtype is sst2. Figure 3 shows an example of a sst2 expressing meningioma. The fact that many tumors express the sst2 subtype is important for sst *in vivo* imaging with octreotide-like ligands because the human sst2 represents the subtype with the highest affinity for octreotide.

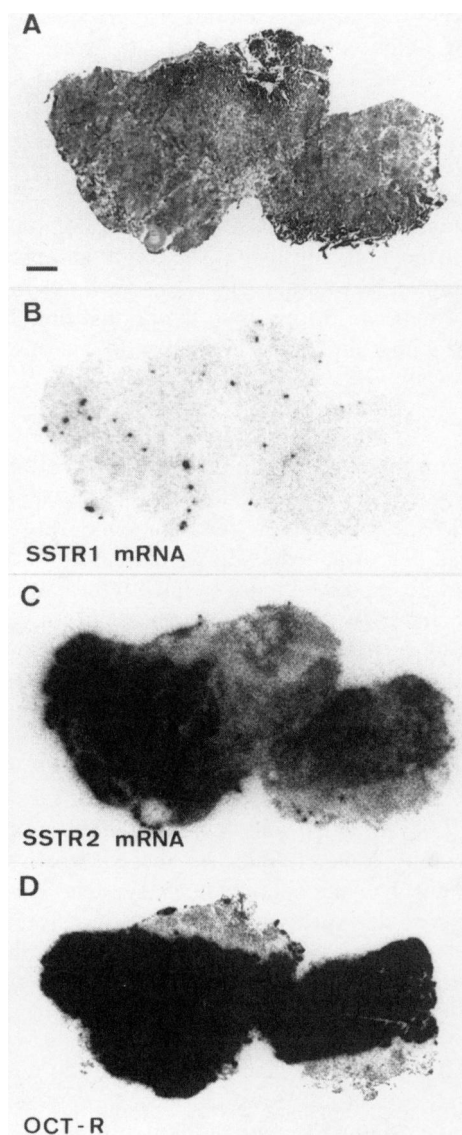


Figure 3. sst2 subtype in a meningioma. A) Hematoxylin-eosin stained section. Bar = 1 mm. B) Autoradiogram showing the lack of sst1 mRNA. C) Autoradiogram showing high abundance of sst2 mRNA. D) Autoradiogram showing total binding of ^{125}I -[Tyr³]-octreotide. Non-specific binding was negligible.

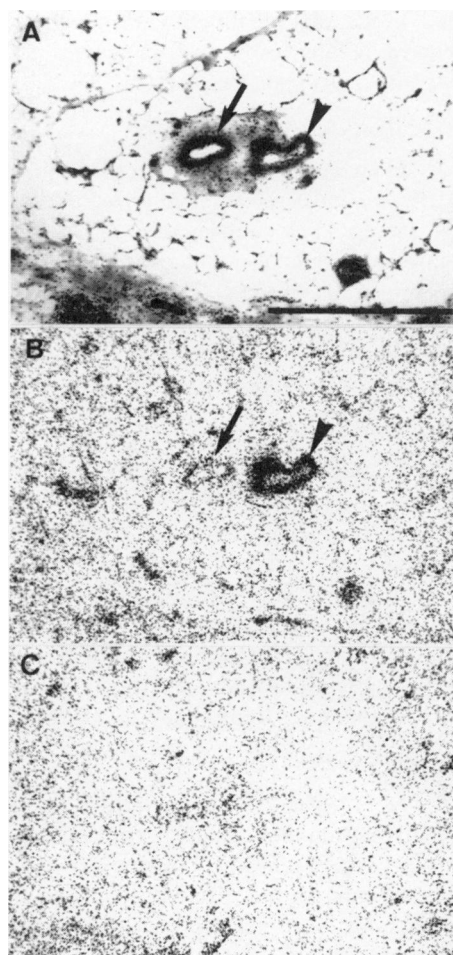


Figure 4. sst in a peritumoral vein located in fat tissue immediately adjacent to breast cancer. A) Hematoxylin-eosin stained section. Bar = 1 mm. The arrow shows an artery, the arrowhead a vein. B) Autoradiogram showing total binding of ^{125}I -[Tyr³]-octreotide. The vein, but not the artery, is strongly labeled. C) Non-specific binding.

In the next paragraphs, we would like to point towards selected tumor types that do not yet belong to the well-known sst-expressing human tumor types, but were recently identified as expressing sst.

Medulloblastomas

In an early study, we identified one medulloblastoma that had a very high sst density [16]. We have recently confirmed these data in a joint study with the University of Würzburg [17] showing that 12/12 medulloblastomas expressed sst, usually in an extremely high density comparable to that of gastrinomas for instance. The receptors were preferentially of the sst2 subtype. This type of tumor, therefore, represents a new, potentially important candidate for diagnosis with Octreoscan. More importantly, this tumor type may be an adequate target for radiotherapy with radiolabeled somatostatin analogs, due to its very high sst content.

Neuroblastomas

Neuroblastomas have also been shown *in vitro* to express sst in nearly 80 percent of the cases. The particular interest in this tumor type is that the correlation of sst expression with survival was statistically significant [18]. The survival of those patients whose tumors expressed sst was of longer duration than that of patients whose tumors did not. This was an independent prognostic factor; sst were expressed more frequently in tumor tissue from patients with lower stages of disease and in those with no evidence of N-myc amplification [18]. Survival analysis in this group of patients indicates that sst receptor expression is a favorable prognostic factor, a finding that may have important implications for the therapy in children with this malignancy [19].

Mesenchymal tumors

Not only can epithelial tumors frequently express sst, but also several types of mesenchymal tumors, as shown in a recent study [20]. Although only a limited number of cases per tumor type could be evaluated in this study, it clearly indicates that mesenchymal tumors, such as osteosarcomas, angiosarcomas, hemangiopericytomas, synovial sarcomas, histiocytomas, and several muscle cell tumors, do express sst and should, therefore, be included in the list of tumors to be considered as targets for diagnosis and therapy with somatostatin analogs, in particular, hemangiopericytomas with their high sst density.

Prostate cancers

Prostate carcinomas represent a particular type of cancer since they usually do not have sst which can be identified with ^{125}I -[Tyr³]-octreotide. However, they express sst identified with ^{125}I -[Leu⁸, D-Trp²², Tyr²⁵]-somatostatin-28, with a high affinity for somatostatin-14 and somatostatin-28, but low affinity for octreotide [7]. The receptors are located on tumor cells. *In situ* hybridization studies reveal a preferential expression of sst1, very much compatible with the results of pharmacological experiments. Moreover, a sst1 selective analog [21] is able to bind selectively and with high affinity to prostate cancer tissue, but not to sst2-, sst3- or sst5-expressing tumors [22]. Primary human prostate cancers, therefore, express a different sst subtype than benign prostate tissue. It should be emphasized that the above-mentioned study is based primarily on resectable primary prostate cancers, belonging to G1 and G2 (WHO) grading. It is not yet known whether less differentiated, more aggressive prostate cancers also preferentially express sst1. However, a recent joint study with the University of Uppsala showed that hormone-insensitive prostate cancers, metastatic to the bones, do express a low density of octreotide-sensitive (sst2) receptors in this location, as shown by *in vitro* receptor autoradiographic studies [23]. About one-third of the metastatic lesions can be visualized *in vivo* with

Octreoscan [23]. These data suggest that, in principle, human prostate cancers may be targets for somatostatin diagnosis and therapy. They appear to express different sst subtypes in different tumor stages, implying that somatostatin analogs with different selectivities for sst subtypes are required in each case. Although sst1 selective analogs such as des AA^{1,5}-[Tyr², D-Trp⁸, IAmp⁹]somatostatin may theoretically be adequate to identify primary (G1 and G2) prostate cancers [22], it should be remembered that those tumors are resected surgically and usually do not need an alternative therapy. Conversely, advanced metastatic prostate cancers appear to express sst2, but in such a low density that it would not justify the use of octreotide.

SOMATOSTATIN RECEPTORS IN PERITUMORAL VESSELS

Recently, the peritumoral vascular system of the host has emerged as a possible target of somatostatin action in tumor development. In a series of human colonic carcinomas, a high density of vascular sst has been observed in the immediate vicinity of all the tumors (0 to 2 cm); as the distance from the carcinomas increases (5 to 10 cm), the density of vascular sst in the colon decreases considerably, suggesting a local phenomenon related to the presence of the tumor [24]. The presence of vascular sst seems to be independent of the presence or absence of sst in the tumor itself. The sst was expressed by the veins and probably belongs to the sst2 subtype, since a high affinity for octreotide could be observed. More recently, we have investigated a large number of different types of human neoplasms and found that the expression of sst in peritumoral veins is a general phenomenon, although it appears highly variable [Denzler and Reubi, unpublished]. For instance, all medullary thyroid carcinomas, colonic and gastric cancers express sst in peritumoral veins, whereas this is rare in GEP tumors or ovarian cancers. A majority of parathyroidea adenomas, renal cell cancers, melanomas, sarcomas, breast cancers and prostate cancers have sst in peritumoral veins [Denzler and Reubi, unpublished]. Figure 4 shows a peritumoral vein in the vicinity of a breast adenocarcinoma. In some tumors, such as melanomas, the sst are not only expressed in peritumoral but also in intratumoral veins. This may be the reason why it is possible to successfully visualize this type of tumor *in vivo* with Octreoscan [25], although the melanoma itself expresses very few tumoral sst.

The function of somatostatin in the peritumoral vasculature, mediated by a high density of sst in the venous smooth muscle cells and possibly in the endothelium, can be defined to some extent: in normal and pathological states, the vasoconstrictive effect of somatostatin, in particular in the gut, is well-established [26]. Therefore, an increased sst density may allow a strong and rapid vasoconstriction, possibly resulting in local hypoxia and necrosis of the tumor, or a more prolonged vasoconstriction, directed against metastatic tumor dissemination. This mechanism may explain the occasional clinical observation of a marked decrease in tumor size during octreotide therapy in some patients. Alternatively, somatostatin may regulate the extent of peritumoral inflammation, as has been suggested for substance-P. Peritumoral veins, the main tumor-draining vessels, may control processes such as the extravasation of plasma, particularly of fibrin and of white blood cells associated with inflammation, tumor stromal generation, blood flow in the tumor, local thrombus formation and tumor growth and propagation. Finally, the high expression of sst in peritumoral veins may be seen as a defense of the host against tumor angiogenesis, as the latter can be inhibited by somatostatin analogs in the chick chorioallantoic membrane system [27], possibly through sst similar to those identified in human peritumoral vessels.

Somatostatin may, therefore, act locally on tumor growth through two different mechanisms dependent on local sst expression: through direct action on tumor cells or through action on peritumoral vessels, which may alter the hemodynamics of the tumor.

OUTLOOK

The clinical relevance of the above-mentioned high expression of sst in and around tumors is two-fold: diagnostic and therapeutic. For the well-established indications, like sst2 expressing neuroendocrine GEP tumors, an extensive discussion of the advantages of the diagnostic use of Octreoscan or therapeutic and radiotherapeutic use of octreotide analogs has been provided by several contributions to this conference. In this article, we have introduced additional sst-expressing tumor types, i.e., medulloblastomas, hemangiopericytomas and various mesenchymal tumors, which need to be evaluated in the above-mentioned indications. We have also shown evidence of sst subtype expression by human tumors. This may suggest development of subtype-specific ligands, i.e., sst1-selective analogs for primary prostate cancers; but the multiplicity of sst subtypes expressed simultaneously in individual tumors may also suggest the development of stable, "pan-somatostatin" analogs, i.e., analogs having a high affinity for all five sst subtypes. Such compounds may improve the scintigraphic diagnosis of sst-expressing tumors, but they may also have therapeutic effects different from octreotide, which may be worthwhile testing in regard to the rather unsatisfactory antitumoral effect of octreotide in sst-expressing non-endocrine tumors.

REFERENCES

1. Reubi, J.C., Kvols, L., Krenning, E., and Lamberts, S.W.J. Distribution of somatostatin receptors in normal and tumor tissue. *Metabolism* 39:78-81, 1990.
2. Lamberts, S.W.J., Krenning, E.P., and Reubi, J.C. The role of somatostatin and its analogs in the diagnosis and treatment of tumors. *Endocr. Rev.* 12:450-482, 1991.
3. Reubi, J.C., Horisberger, U., Waser, B., Gebbers, J.O., and Laissue, J. Preferential location of somatostatin receptors in germinal centers of human gut lymphoid tissue. *Gastroenterology* 103:1207-1214, 1992.
4. Reubi, J.C., Waser, B., Horisberger, U., Krenning, E., Lamberts, S.W.J., Gebbers, J.O., Gersbach, P., and Laissue, J.A. *In vitro* autoradiographic and *in vivo* scintigraphic localization of somatostatin receptors in human lymphatic tissue. *Blood* 82:2143-2151, 1993.
5. Reubi, J.C., Horisberger, U., Studer, U.E., Waser, B., and Laissue, J.A. Human kidney as target for somatostatin: High affinity receptors in tubules and *vasa recta*. *J. Clin. Endocrinol. Metab.* 77:1323-1328, 1993.
6. Vora, J.P., Owens, D.R., Ryder, R., Atiea, J., Luio, S., and Hayes, T.M. Effect of somatostatin on renal function. *Br. Med. J.* 292:1701-1702, 1986.
7. Reubi, J.C., Waser, B., Schaer, J.C., and Markwalder, R. Somatostatin receptors in human prostate and prostate cancer. *J. Clin. Endocrinol. Metab.* 80:2806-2814, 1995.
8. Tatoud, R., Degeorges, A., Prévost, G., Hoepffner, J., Gauvillé, C., Millot, G., Thomas, F., and Calvo, F. Somatostatin receptors in prostate tissues and derived cell cultures, and the *in vitro* growth inhibitory effect of BIM-23014 analog. *Molec. Cell. Endocrinol.* 113:195-204, 1995.
9. Reubi, J.C., Waser, B., Friess, H., Krenning, E.P., Büchler, M., and Laissue, J. Regulatory peptide receptors in goiters of the human thyroid. *J. Nucl. Med.* 38(Suppl.) 5:266P, 1997.
10. Krenning, E.P., Kwekkeboom, D.J., Pauwels, S., Kvols, L.K., and Reubi, J.C. Somatostatin receptor scintigraphy. *Nucl. Med. Ann.* 1995:1-50, 1995.
11. Reisine, T. and Bell, G.I. Molecular biology of somatostatin receptors. *Endocr. Rev.* 16:427-442, 1995.
12. Panetta, R. and Patel, Y.C. Expression of mRNA for all five human somatostatin receptors (hSSTR1-5) in pituitary tumors. *Life Sci.* 56:333-342, 1995.
13. Greenman, Y. and Melmed, S. Expression of three somatostatin receptor subtypes in pituitary adenomas: Evidence for preferential SSTR5 expression in the mammosomatotroph lineage. *J. Clin. Endocrinol. Metab.* 79:724-729, 1994.

14. Schaer, J.C., Waser, B., Mengod, G., and Reubi, J.C. Somatostatin receptor subtypes sst1, sst2, sst3, and sst5 expression in human pituitary, gastroenteropancreatic and mammary tumors: Comparison of mRNA analysis with receptor autoradiography. *Int. J. Cancer*. 70:530-537, 1997.
15. Reubi, J.C., Schaer, J.C., Waser, B., and Mengod, G. Expression and localization of somatostatin receptor SSTR1, SSTR2 and SSTR3 mRNAs in primary human tumors using *in situ* hybridization. *Cancer Res.* 54:3455-3459, 1994.
16. Reubi, J.C., Lang, W., Maurer, R., Koper, J.W., and Lamberts, S.W.J. Distribution and biochemical characterization of somatostatin receptors in tumors of the human central nervous system. *Cancer Res.* 47:5758-5764, 1987.
17. Müller, H.L., Frühwald, M.C., Scheubeck, M., Rendl, J., Warmuth-Meth, M., Sörensen, N., Köhl, J., and Reubi, J.C. A possible role for somatostatin receptor scintigraphy in the diagnosis and follow-up of children with medulloblastoma. *J. Neurooncol* 38:27-40, 1998.
18. Moertel, C.L., Reubi, J.C., Scheithauer, B.S., Schaid, D.J., and Kvols, L.K. Expression of somatostatin receptors in childhood neuroblastoma. *Amer. J. Clin. Path.* 102:752-756, 1994.
19. Kropp, J., Hofmann, M., and Bihl, H. Comparison of MIBG and pentetreotide scintigraphy in children with neuroblastoma. Is the expression of somatostatin receptors a prognostic factor?. *Anticancer Res.* 17:1583-1588, 1997.
20. Reubi, J.C., Waser, B., Laissue, J.A., and Gebbers, J. Somatostatin and vasoactive intestinal peptide receptors in human mesenchymal tumors: *In vitro* identification. *Cancer Res.* 56:1922-1931, 1996.
21. Liapakis, G., Hoeger, C., Rivier, J., and Reisine, T. Development of a selective agonist at the somatostatin receptor subtype SSTR1. *J. Pharmacol. Exp. Ther.* 276:1089-1094, 1996.
22. Reubi, J.C., Schaer, J.C., Waser, B., Hoeger, C., and Rivier, J.A. selective analog for the somatostatin receptor subtype sst1 expressed by human tumors. *Eur. J. Pharmacol.* 345:103-110, 1998.
23. Nilsson, S., Reubi, J.C., Kalkner, K., Laissue, J.A., Horisberger, U., Olerud, C., and Westlin, J. Metastatic hormone-refractory prostatic adenocarcinoma expresses somatostatin receptors and is visualized *in vivo* by (111-In)-labeled DTPA-D-(Phe-1)-octreotide scintigraphy. *Cancer Res. (Suppl.)* 55:5805s-5810s, 1995.
24. Reubi, J.C., Mazzucchelli, L., Hennig, I., and Laissue, J. Local upregulation of neuropeptide receptors in host blood vessels around human colorectal cancers. *Gastroenterology* 110:1719-1726, 1996.
25. Hoefnagel, C.A., Rankin, E.M., Valdés Olmos, R.A., Israels, S.P., Pavel, S., and Janssen, A.G. M. Sensitivity versus specificity in melanoma imaging using iodine-123 iodobenzamide and indium-111 pentetreotide. *Eur. J. Nucl. Med.* 21:587-588, 1994.
26. Sonnenberg, G.E., Keller, U., Perruchoud, A., Burckhardt, D., and Gyr, K. Effect of somatostatin on splanchnic hemodynamics in patients with cirrhosis of the liver and in normal subjects. *Gastroenterology* 80:526-532, 1981.
27. Woltering, E.A., Barrie, R., O'Dorisio, T.M., Arce, D., Ure, T., Cramer, A., Holmes, D., Robertson, J., and Fassler, J. Somatostatin analogues inhibit angiogenesis in the chick chorioallantoic membrane. *J. Surg. Res.* 50:245-251, 1991.