

## Comparative Analysis of Diagnostic Techniques for Localization of Gastrointestinal Neuroendocrine Tumors

Fathia Gibril and Robert T. Jensen<sup>a</sup>

*Digestive Diseases Branch, National Institute of Diabetes and Digestive and  
Kidney Diseases, National Institutes of Health, Bethesda, Maryland*

(Submitted March 25, 1997; Returned for revision April 20, 1998; Accepted June 15, 1998)

---

*In vitro* studies have shown that gastroenteropancreatic tumors, with the exception of insulinomas, have a high density of somatostatin receptors and can be imaged *in vivo* using somatostatin receptor scintigraphy (SRS) with either [<sup>123</sup>I-Tyr<sup>3</sup>]octreotide or [<sup>111</sup>In DTPA,DPhe<sup>1</sup>]octreotide. However, the sensitivity in relation to conventional imaging studies (ultrasound, CT, MRI, angiography) remains unclear. To address this question, we performed a prospective study of 80 patients with gastrinomas where SRS was compared with other conventional imaging techniques for detecting extrahepatic gastrinomas or liver metastases. Extrahepatic gastrinomas were identified by SRS in 58 percent of patients, whereas conventional imaging studies detected gastrinomas in 9 percent to 48 percent of patients. In detecting hepatic metastases in 24 patients with histologically-proven metastases, SRS was positive in 92 percent; ultrasound, CT or angiography in 42 percent to 62 percent; and MRI in 71 percent of patients. These results are compared with other studies in detecting gastrinomas as well as series including other PETs, excluding insulinomas, with insulinomas alone, and with carcinoid tumors. An analysis of the ability of SRS to identify gastrinomas found in different sites at surgery was performed. The role of endoscopic ultrasound (EUS) in detecting various PETs, in comparison to that of SRS, is yet to be established, particularly for extrapancreatic PETs. Therefore, the results of EUS in various studies containing patients with PETs are compared to those with SRS and conventional imaging studies. These data suggest that EUS is the first choice of localization methods for detecting insulinoma, which is an intrapancreatic tumor in almost all cases. In other PETs there still is not sufficient data to establish the relative roles of EUS and SRS.

---

### INTRODUCTION

Imaging studies are essential for planning an appropriate strategy in the management of gastrointestinal neuroendocrine tumors, carcinoid tumors and pancreatic endocrine tumors (PETs)<sup>b</sup> [1-3]. A number of conventional imaging methods such as ultrasound, computed tomographic scanning (CT), magnetic resonance imaging (MRI) and selective angiography [1, 2, 4-6], and for functional neuroendocrine tumors, functional localization methods have been recommended, such as portal venous sampling for hormonal gradients and selective intra-arterial provocative tests with hepatic venous sampling for hormone concentrations [7-10]. For carcinoid tumors, either conventional imaging methods, gastrointestinal barium studies and/or endoscopy are generally used [2, 3]. These studies generally show that selective angiography and MRI are the most sensitive

---

<sup>a</sup> To whom all correspondence should be addressed: Robert T. Jensen, M.D., NIH/NIDDK/DDB, Bldg. 10, Rm. 9C-103, 10 Center DR MSC 1804, Bethesda, Maryland 20892-1804. Tel.: (301) 96-4201; Fax: (301) 402-0600; E-mail: robtj@bdg10.niddk.nih.gov.

<sup>b</sup> Abbreviations: CT, computerized tomographic scanning; EUS, endoscopic ultrasound; MRI, magnetic resonance imaging; PET, pancreatic endocrine tumor; SRS, somatostatin receptor scintigraphy; STIR, short-time inversion recovery sequence.

modalities [1, 7, 9, 11]; however, they still fail to identify the primary in up to 50 percent of patients in some studies [1, 6, 12].

Recently, two newer localization methods using somatostatin receptor scintigraphy (SRS) or endoscopic ultrasound (EUS) are increasingly recommended. Several recent studies reported that SRS is superior to some conventional imaging studies in localizing gastrointestinal neuroendocrine tumors [13-21]. However, the information on SRS sensitivity compared with that of other imaging techniques is limited in most studies in various ways. Until recently the number of patients studied in the different series was small. Only a few studies compared SRS systematically with that of most sensitive conventional imaging methods, particularly selective angiography and MRI using STIR (short-time inversion-recovery sequences) [1, 6, 11]. The assessment of tumor detection was often on a lesion-by-lesion basis, and therefore, it was difficult to relate it to a given patient's management. Finally, many studies did not assess the sensitivity of SRS relative to other methods in different clinical situations such as whether localization methods were being used to identify a primary tumor or whether the localization studies were being performed to identify metastatic disease. This latter point is particularly important because some localization methods are better for localizing primary tumors, whereas other are used primarily to localize metastatic disease in the liver [1, 4, 11, 22-24]. Recently, endoscopic ultrasound has been increasingly used for localization of PETs and reported to be more sensitive than conventional imaging methods in detecting PETs, with its sensitivity reaching 94 percent in some series [23, 25-33]. At present, only a few studies have compared the relative sensitivity of endoscopic ultrasound to the SRS in localizing PETs [23, 27, 28], and the experience with nonfunctional or carcinoid tumor is even more limited. At present the relative roles of EUS and SRS in localization of PETs is unclear and controversial.

Recently, we have begun prospective studies to address both the sensitivity of SRS compared to conventional imaging studies and the sensitivity of endoscopic ultrasound compared to other tumor localization modalities in patients with gastrinomas. The first study is now completed and in this paper we will review the methods, results, and implications of this study. The NIH endoscopic ultrasound study is just beginning. Thus, in the latter part of this paper, the recent data from other centers on the use of endoscopic ultrasound to localize gastrointestinal neuroendocrine tumors will be reviewed briefly.

### **NIH STUDY ON THE COMPARATIVE SENSITIVITY OF SRS AND CONVENTIONAL IMAGING STUDIES IN LOCALIZING GASTRINOMAS**

In this study we prospectively compare the ability of SRS with that of other conventional imaging methods including ultrasound, CT, MRI and selective angiography to localize primary and metastatic gastrinoma in 80 consecutive patients with the Zollinger-Ellison syndrome [34].

#### **Methods**

All patients underwent SRS, CT, ultrasound, bone scanning, and MRI including T1-weighted spin-echo sequences and STIR sequences as described previously [1, 11, 24, 35]. Selective angiography was performed with selective injection of splenic, superior mesenteric, gastroduodenal and hepatic arteries as described elsewhere [1, 9, 10]. A single radiologist evaluated the results of all conventional imaging methods. For SRS, all patients received an intravenous injection of 6 mCi of [<sup>111</sup>In-DTPA,DPh<sup>1</sup>]octreotide. Images were obtained at 4 hours and 24 hours post injection. (At 4 hours, a 30-minute whole body scan, 10-minute planar spot views of the abdomen and SPECT [single-photon emission computed tomography] were done.) Repeated SPECT images were performed at 24 hours. Results of SRS were obtained while the nuclear medicine radiologist

was blinded to the results of the conventional imaging studies. All imaging studies were evaluated in two separate aspects: whether a possible primary or extrahepatic tumor was localized and whether hepatic metastases were found. All patients with suspected metastatic disease in the liver underwent percutaneous biopsy. The results are expressed as percentage of patients in whom any extrahepatic or hepatic tumor was localized. Each patient was counted only once (Table 1).

### Results

CT, MRI or angiography identified extrahepatic tumors in 28 percent to 31 percent and ultrasound detected extrahepatic tumors in 9 percent of patients (Table 1). Extrahepatic tumors were detected in 58 percent (46/80) of patients with SRS only, which was significantly more sensitive ( $p < .001$ ) (Table 1) than any conventional imaging methods alone, and it was equally sensitive to all conventional imaging methods combined. Figure 1, bottom, is an example of SRS localizing an extrahepatic gastrinoma in the pancreatic head area (i.e., a gastrinoma in a periduodenal lymph node was found at surgery) in a patient in whom the CT scan (Figure 1, top) and other conventional imaging methods were negative.

For localizing hepatic metastases in 24 patients with proven metastatic liver disease, SRS was the most sensitive of any localization method in detecting metastases in 92 percent (Table 1), and it was equal to all conventional imaging methods combined. Other imaging studies were less sensitive with the exception of MRI ( $p = .12$ ). Angiography detected hepatic metastases in 62 percent of patients but was less sensitive than SRS ( $p = .016$ ) as was ultrasound which detected hepatic metastases in 46 percent ( $p = .001$  vs. SRS), and CT, which detected hepatic metastases in 42 percent ( $p < .001$  vs. SRS) of patients. Figure 2 (bottom) is an example of the high sensitivity of SRS in detecting hepatic metastases in a patient in whom the CT scan (Figure 2, top) and other conventional imaging studies were negative.

Since we began using SRS at the NIH in June 1994, 31 patients underwent exploratory laparotomy for possible removal of the primary gastrinoma after the SRS and

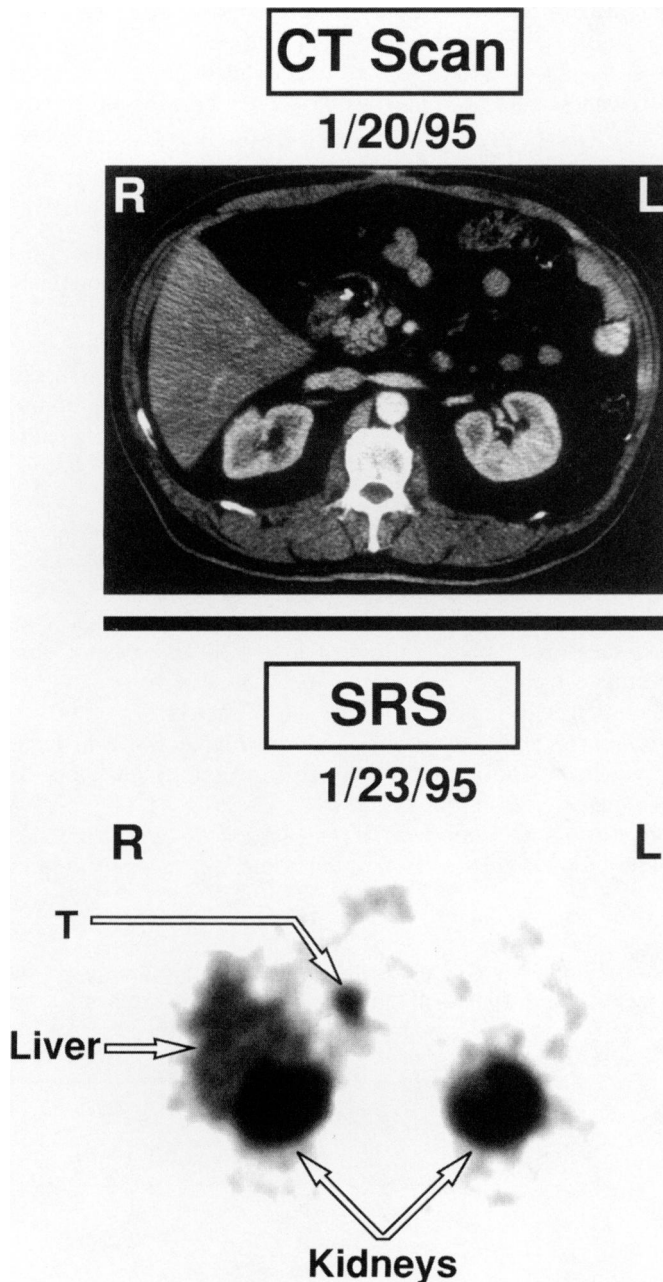
**Table 1. Ability of conventional imaging modalities and SRS to localize an extrahepatic gastrinoma or hepatic metastases in 80 patients with Zollinger-Ellison syndrome.**

Imaging method	Extrahepatic (n = 80)		Hepatic (n = 24)	
	Positive (%) <sup>2</sup>	P value (Compared to SRS)	Positive (%) <sup>2</sup>	P value (Compared to SRS)
Ultrasound	9	<.001	46	.001
CT scan	31	<.001	42	<.001
MRI	30	<.001	71	NS
Angiography	28	<.001	62	0.016
All conventional combined <sup>1</sup>	48	NS	83	NS
SRS	58	—	92	—
SRS and all other tests	68	NS	96	NS

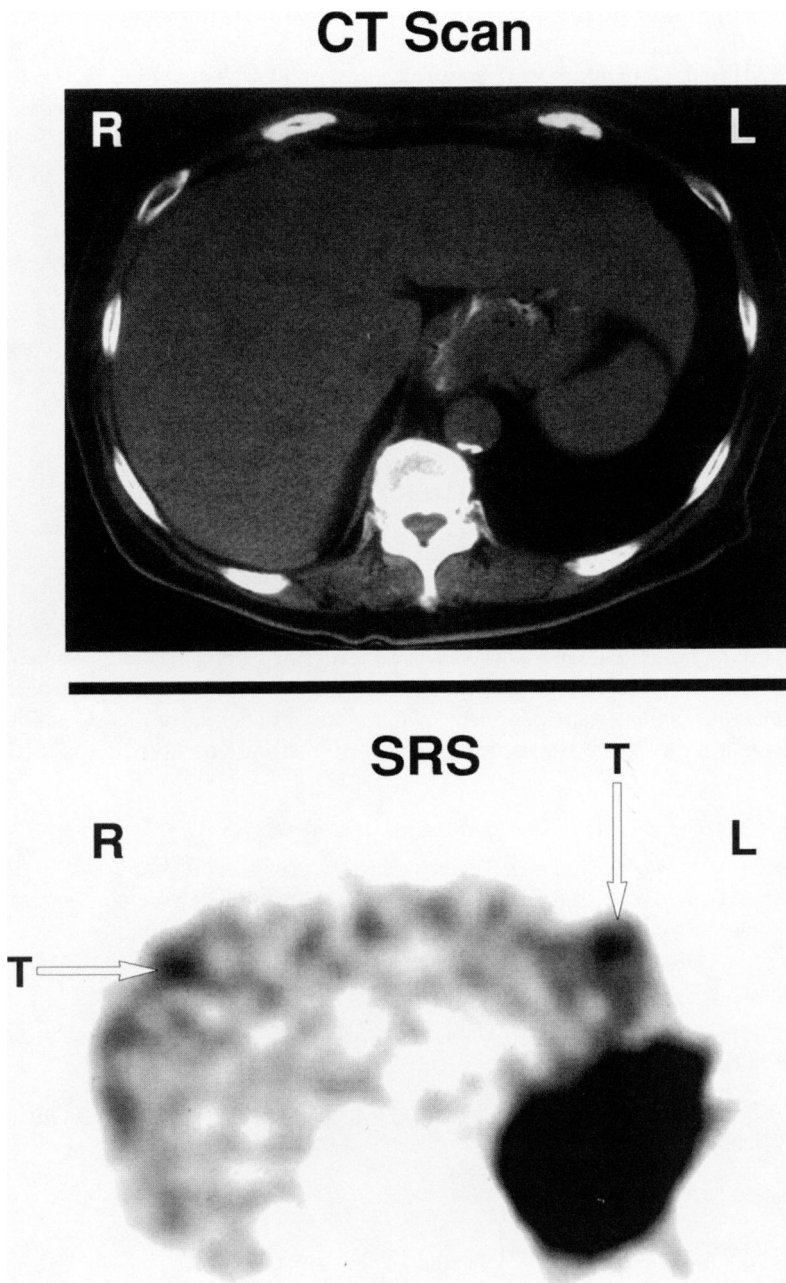
Shown are results for 80 patients for localization of extrahepatic gastrinoma and 24 patients with histologically proven liver metastases. Results from Ref. [24].

<sup>1</sup> All conventional results refer to results with ultrasound, CT scan, MRI and angiography.

<sup>2</sup> Positive percent is the percentage of patients in the indicated disease extent category (i.e., extrahepatic or hepatic) with a positive result with the indicated imaging modality.



**Figure 1. CT scan and SRS of a patient with localized gastrinoma.** This patient (NIH #2789772) is a 59-year-old male with a previous duodenal gastrinoma resection. His postoperative gastrin levels remain elevated. His CT scan (top) shows no lesion. The SRS (bottom) shows an increased uptake medial and anterior to the right kidney (arrow). At repeat surgery, a 6 mm gastrinoma in a periduodenal lymph node was removed with subsequent normalization of serum gastrin levels. This patient illustrates the increased sensitivity of SRS over conventional imaging studies (CT, ultrasound, MRI) in detecting extrahepatic gastrinomas, which has been reported in a number of recent studies [15, 27, 28, 34, 56].



**Figure 2. CT scan and SRS of a patient with metastatic gastrinoma to the liver.** This patient (NIH #1897238) is a 75-year-old female with histologically proven metastatic disease to the liver. The CT scan (top) shows no hepatic lesion. The SRS (bottom) shows two foci in the liver with one focus in the right liver lobe (arrow) and one focus in the left liver lobe (arrow). This patient illustrates the increased sensitivity of SRS over conventional imaging studies (CT, ultrasound, MRI) in detecting hepatic metastases and in demonstrating multiple metastases in different areas of the liver, which can influence determinations of possible resectability [34, 56, 57].

conventional imaging methods were performed. The results from 24 patients are shown in Table 2. Twelve of these patients were from the 80 patients discussed above and reported recently [34] and 12 patients were more recent patients not included in the first 80 patients. Gastrinoma was found in all patients at surgery. A total of 40 gastrinomas were found: 13 gastrinomas in the duodenum, 3 in the pancreas and 24 in the lymph nodes. Although the sensitivity of SRS for localizing duodenal gastrinoma was low (38 percent) when compared to localizing pancreatic gastrinomas (100 percent) and gastrinoma in lymph nodes (88 percent), it was more sensitive than ultrasound, CT, MRI (0 to 8 percent) and equal to angiography or all conventional imaging methods combined (31 percent) (Table 2). For duodenal and pancreatic tumors, SRS had equal sensitivity to that seen with all conventional imaging studies combined, but it was the more sensitive (88 percent) than a combination of all conventional imaging modalities in detecting gastrinomas in the lymph nodes (Table 2).

### RELATIONSHIP OF NIH RESULTS OF SRS SENSITIVITY COMPARED TO OTHER STUDIES IN PETS

#### *Applicability of NIH results to other PETs*

The results of our study likely have applicability to other less common PETs and carcinoid tumors for a number of reasons. Gastrinoma resembles all PETs with the exception of insulinoma in its biological behavior, growth pattern, histochemistry, rates of the occurrence of somatostatin receptors and malignant potential [2, 5, 6]. It resembles carcinoid tumors in the above characteristics, especially in the important areas of having a high density of somatostatin receptors, similar malignant potential and growth patterns [3, 13, 14, 36, 37].

#### *Comparison of NIH results with SRS to those from other studies*

The results of other studies in patients with Zollinger-Ellison syndrome and other PETs are compared with our study in Table 3. The imaging studies were compared by the percentage of patients with a positive result and not on a lesion-by-lesion basis. For extrahepatic gastrinomas the sensitivity of SRS was 56 to 80 percent (Table 3), which was more

**Table 2. Ability of conventional imaging studies and SRS to localize gastrinomas (n = 40) found at surgery in 24 consecutive patients.**

Imaging method	Gastrinomas location at surgery (percent identified)		
	Duodenum (n = 13)	Pancreas (n = 3)	Lymph node (n = 24)
Ultrasound	0%	33%	13%
CT scan	8%	67%	38%
MRI	8%	67%	41%
Angiography	31%	100%	44%
All conventional combined <sup>1</sup>	31%	100%	68%
SRS	38%	100%	88%
SRS and all other tests	62%	100%	95%

In the 24 patients, 13 duodenal gastrinomas, three pancreatic and 24 positive lymph nodes were found at surgery. Results are the percentage of the gastrinomas in the indicated category localized by the indicated imaging modality preoperatively.

<sup>1</sup> All conventional results refer to results with ultrasound, CT scan, MRI and angiography.

**Table 3. Comparison of the ability of SRS and conventional imaging modalities to localize an extrahepatic gastrinoma or other neuroendocrine tumor or hepatic metastases in various studies.**

Study	Year	Ref.	Extrahepatic (percent positive) <sup>1</sup>						Hepatic (percent positive) <sup>1</sup>							
			No. of Patients			Localization method			No. of Patients			Localization method				
			SRS	US	CT	MRI	Angio.	SRS	US	CT	MRI	Angio.				
<b>I. Gastrinomas</b>																
de Kerviler	1994	15	56	8	38	—	—	—	—	—	17	100	76	76	—	—
Krenning	1996	39	73	—	75	—	—	—	—	—	67	73	—	—	—	—
Gibril	1996	34	58	9	31	30	28	—	—	—	80	58	9	42	71	62
Zimmer	1996	28	80	40	40	40	—	—	—	—	10	80	40	40	—	—
Cadiot	1996	27	58	0	0	—	—	—	—	—	19	58	0	—	—	—
Literature	1992		—	23	50	21	68	—	—	—		—	14	54	67	62
	to 1996															
<b>II. All PETs<sup>2</sup></b>																
Krenning	1996	39	80	—	88	—	—	—	—	—	350	80	—	88	—	—
Wiene	1993	21	55	44	33	—	—	—	—	—	9	55	44	33	—	—
Scherubl	1993	16	58	41	41	41	—	—	—	—	12	58	41	41	41	—

<sup>1</sup> Percent positive is the percentage of patients with a positive result with the indicated imaging modality.

<sup>2</sup> All PETs means studies in which patients with different types of PETs were combined.

“—” Means no data were reported for the localization method indicated.

Table 4. Comparison of the ability of SRS to conventional imaging studies in localizing insulinomas or carcinoid tumors.

Study	Year	Ref.	No. of Patients	Extrahepatic (percent positive) <sup>1</sup>					Hepatic (percent positive) <sup>1</sup>				
				Localization method					Localization method				
				SRS	US	CT	MRI	Angio.	SRS	US	CT	MRI	Angio.
I. Insulinoma													
Krenning	1996	39	24	46	—	71	—	—	—	—	—	—	
Zimmer	1996	28	10	20	10	30	10	—	—	—	—	—	
Literature				—	33	35	20	63					
II. Carcinoid													
Krenning	1996	39	184	87	—	91	—	—	—	—	—	—	
Kisker	1996	38	22	73	53	68	—	—	—	17	88	94	
											94	94	

<sup>1</sup> Percent positive is the percentage of patients with a positive result with the indicated imaging modality. "—" Means no data were reported for the localization method indicated.



sensitive than other conventional imaging methods in the same study except CT (75 percent) in one series [39]. However, other studies in which SRS was not performed report higher sensitivities with CT and angiography than reported in most of the studies in Table 3 [1, 6, 40, 41]. For detecting metastatic gastrinomas, SRS has a 92 to 100 percent sensitivity, which was more sensitive than other imaging studies (42 to 76 percent) (Table 3). For series containing different PETs for the extrahepatic tumors, SRS was more sensitive than ultrasound, MRI and CT in two out of three studies (Table 3, bottom). For identification of hepatic metastases in patients with various PETs, there is little data; however, in one study [16], SRS was superior to CT, ultrasound or MRI (Table 3, bottom). For insulinomas (Table 4, top) the sensitivity of SRS for detecting extrahepatic tumors was as low as 20 percent to 46 percent, which was comparable with other imaging studies except angiography (63 percent) and CT (71 percent) in two series. For carcinoid tumors (Table 4, bottom) there are not many studies that have compared SRS with other conventional imaging methods with different disease extents [18]. The data shown in Table 4 demonstrate that for carcinoid tumors the sensitivity of SRS and other conventional imaging methods are equal, in general, for extrahepatic and hepatic metastases [38]; however, other studies reported that SRS was more sensitive in detecting distal metastases [18].

#### COMPARISON OF THE RESULTS OF SRS AND EUS FOR LOCALIZING VARIOUS PETs

A number of recent studies have reported that endoscopic ultrasound (EUS) is a highly sensitive technique to localize PETs [15, 23, 25-33]. In Table 5, results are shown from a comparison of SRS, EUS or CT in localizing various PETs from a number of studies, and the studies are stratified according to the type of tumor. For duodenal gastrinomas, there are little comparative data. Of the 11 duodenal gastrinomas in two studies, SRS recognized from 38 to 100 percent of duodenal tumors and EUS from 63 to 67 percent. These results suggest that both localization methods may miss a significant proportion of duodenal tumors. This possibility has been raised previously with EUS [42] and is consistent with our recent data in which SRS only localized 38 percent of duodenal gastrinomas (Table 2). Two recent studies [15, 27] suggest in gastrinomas for identification of duodenal tumors or gastrinomas in lymph nodes that the combination of both EUS and SRS may be better than either alone. Pancreatic gastrinomas are generally larger than duodenal gastrinomas [43] and are well seen by EUS [25, 28, 29, 33] and by SRS [28] (Table 5). Recent studies demonstrate that EUS is much more sensitive than SRS [23, 28] or conventional imaging [29-33] for localizing pancreatic insulinomas. These data are consistent with results of recent studies that demonstrate that insulinomas frequently have a low density of high affinity octreotide receptors (sstr 2, 5) [28, 44] and, therefore, are not frequently seen on SRS (Table 4). For all PETs of various types, the sensitivity of SRS was 52 percent in one study (Table 5), EUS from 82 to 89 percent and CT scanning from 0 to 36 percent in the different studies.

The exact relative role of EUS or SRS in patients with PETs at present is controversial [42, 45]. This has occurred because there are few studies comparing EUS and SRS in a large number of patients. However, the results summarized in Table 5 suggest the following conclusions: First, for duodenal gastrinomas it is clear both studies miss a proportion of these tumors. It remains unclear the exact percentage identified by each modality, whether these studies identify sufficient numbers of duodenal gastrinomas that their use for this is justified and whether the combination is better than either alone. This is an important point because in recent surgical series duodenal gastrinomas are being found more frequently than pancreatic gastrinomas [6, 27, 46-48]. Second, for pancreatic

**Table 5. Results of EUS, SRS, or other modalities in various studies in detecting PETs.**

Study	Year	Ref.	No. of tumors <sup>a</sup> or patients <sup>b</sup>	CT scan	Positive (percent) <sup>1</sup>		
					SRS	EUS	SRS and EUS combined
<b>I. Duodenal gastrinoma</b>							
Cadiot	1996	27	8 <sup>a</sup>	0	38	63	88
Zimmer	1996	28	3 <sup>a</sup>	0	100	67	—
Ruszniewski	1995	25	10 <sup>a</sup>	0	—	50	—
Thompson	1994	26	4 <sup>a</sup>	0	—	0	—
<b>II. Gastrinoma in lymph node alone or with duodenal tumor</b>							
Cadiot	1996	27	11 <sup>b</sup>	0	73	55	91
Ruszniewski	1995	25	8 <sup>a</sup>	0	—	63	—
Palazzo	1992	33	5 <sup>a</sup>	0	—	100	—
<b>III. Pancreatic gastrinoma</b>							
Zimmer	1996	28	9 <sup>a</sup>	33	89	89	—
Ruszniewski	1995	25	4 <sup>a</sup>	25	—	75	—
Rosch	1992	29	7 <sup>a</sup>	0	—	86	—
<b>IV. Pancreatic insulinoma</b>							
Zimmer	1996	28	14 <sup>a</sup>	21	14	93	—
Zimmer	1994	23	8 <sup>a</sup>	12	12	87	—
Glover	1992	31	15 <sup>a</sup>	20	—	80	—
Rosch	1992	29	31 <sup>a</sup>	0	—	81	—
Palazzo	1992	33	13 <sup>a</sup>	0	—	77	—
Ruszniewski	1995	30	19 <sup>a</sup>	10	—	89	—
Lightdale	1991	32	4 <sup>a</sup>	0	—	75	—
<b>V. All PETs<sup>2</sup></b>							
Zimmer	1994	23	25 <sup>a</sup>	36	52	88	—
Rosch	1992	29	37 <sup>b</sup>	0	—	82	—
Palazzo	1992	33	24 <sup>a</sup>	17	—	88	—
Lightdale	1991	32	9 <sup>a</sup>	11	—	89	—

<sup>1</sup> Percent positive is the percentage of tumors found at surgery localized by the indicated imaging modality pre-operatively.

<sup>2</sup> All PETs means studies in which patients with different types of PETs were combined.

“—” Means no data were reported for the localization method indicated.

gastrinomas, both EUS and SRS appear to identify 75-100 percent likely because these tumors are frequently large (i.e., >2 to 3 cm) [43]. It has, in fact, been recommended recently that EUS be routinely used in gastrinomas to exclude a pancreatic tumor [26]. For insulinomas EUS is clearly the procedure of choice. This conclusion is justified because these tumors are almost always intrapancreatic [49], which increases the ability to locate them on EUS, have a low density of high affinity somatostatin receptors that bind octreotide and thus are not well seen on SRS using [<sup>111</sup>In-DTPA-DPhe<sup>1</sup>]octreotide. Also, the tumors are frequently less than 1 cm and thus are not well seen on conventional imaging studies because their ability to detect PETs decreases with decreasing tumor size [11, 24, 40, 41, 50]. Third, only limited studies are available on other PETs. However, because most are intrapancreatic [2, 5], have a high density of somatostatin receptors similar to pancreatic gastrinomas [13, 14, 51] and are usually large at presentation [2, 5, 52], both SRS (50-60 percent) and EUS (40-70 percent) are likely more useful than conventional imaging studies. The usefulness of EUS in PETs that are not insulinomas is limited by the fact that in less than 30 to 40 percent of patients its use is indicated to localize the primary tumor [45]. This occurs because most patients with VIPomas, nonfunctioning PETs, glucagonomas, somatostatinomas and GRFomas present with metastatic disease to the liver, large primary tumors [2, 5, 53-55] and thus, location of the primary may be either not difficult and can be easily accomplished with conventional imaging studies or is not indicated because it will not alter management.

In conclusion, our recent NIH study [34] combined with other studies on gastrinomas and other PETs (Tables 3 and 4) demonstrate that SRS has greater sensitivity than conventional imaging studies (ultrasound, CT, MRI, angiography) at localizing either the primary tumor or hepatic metastases. In patients with carcinoid tumors, SRS has equal or greater sensitivity to conventional imaging modalities in the two comparative studies reported. For insulinomas, EUS has the greatest sensitivity and should be the initial imaging study of choice. For the other PETs including gastrinomas, which are frequently malignant, SRS should be the initial localization modality because of its sensitivity and ability to examine the whole body at once. In the future, it will be important to establish whether EUS or SRS is best for localization of the primary tumor for patients without metastatic disease to the liver or whether they are complementary.

#### REFERENCES

1. Orbuch, M., Doppman, J.L., Strader, D.B., Fishbeyn, V.A., Benya, R.V., Metz, D.C., and Jensen, R.T. Imaging for pancreatic endocrine tumor localization: recent advances. In: Mignon, M., and Jensen, R.T., eds. Endocrine tumors of the pancreas: recent advances in research and management. *Frontiers of Gastrointestinal Research*. Basel: S. Karger; 1995, pp. 268-281.
2. Norton, J.A., Levin, B., and Jensen, R.T. Cancer of the endocrine system. In: DeVita, V.T., Jr., Hellman, S., and Rosenberg, S.A., eds. *Cancer: principles and practice of oncology*. Philadelphia: J.B. Lippincott; 1993, pp. 1333-1435.
3. Jensen, R.T. and Norton, J.A. Carcinoid tumors and the carcinoid syndrome. In: DeVita, V.T., Jr., Hellman, S., and Rosenberg, S.A., eds. *Cancer: principles and practice of oncology*. Philadelphia: Lippincott-Raven; 1997, pp. 1704-1723.
4. Doppman, J.D., Shawker, T.H., and Miller, D.C. Localization of islet cell tumors. *Gastroenterol. Clin. North. Am.* 18:793-804, 1989.
5. Jensen, R.T. and Norton, J.A. Endocrine tumors of the pancreas. In: Yamada, T., Alpers, B.H., Owyang, C., Powell, D.W., and Silverstein, F.E., eds. *Textbook of gastroenterology*. 2nd edition. Philadelphia: J.B. Lippincott; 1995, pp. 2131-2166.
6. Jensen, R.T. and Gardner, J.D. Gastrinoma. In: Go, V.L.W., DiMagno, E.P., Gardner, J.D., Lebenthal, E., Reber, H.A., and Scheele, G.A., eds. *The pancreas: biology, pathobiology and disease*. New York: Raven Press; 1993, pp. 931-978.
7. Doppman, J.L., Chang, R., Fraker, D.L., Norton, J.A., Alexander, R., Miller, D.L., Collier, E., Skarulis, M.C., and Gorden, P. Localization of insulinomas to regions of the pancreas by intra-arterial stimulation with calcium. *Ann. Intern. Med.* 123:269-273, 1995.

8. Thom, A.K., Norton, J.A., Doppman, J.L., Chang, R., Miller, D.L., and Jensen, R.T. Prospective study of the use of intraarterial secretin injection and portal venous sampling to localize duodenal gastrinomas. *Surgery* 112(6):1002-1008, 1992.
9. Strader, D.B., Doppman, J.L., Orbuch, M., Fishbeyn, V.A., Benya, R.V., Jensen, R.T., and Met, D.C. Functional localization of pancreatic endocrine tumors. In: Mignon, M., and Jensen, R.T., eds. *Frontiers of Gastrointestinal Research*. Basel: S. Karger; 1995, pp. 282-297.
10. Gibril, F., Doppman, J.L., Chang, R., Weber, H.C., Termanini, B., and Jensen, R.T. Metastatic gastrinomas: localization with selective arterial injection of secretin. *Radiology* 198:77-84, 1996.
11. Pisegna, J.R., Doppman, J.L., Norton, J.A., Metz, D.C., and Jensen, R.T. Prospective comparative study of ability of MR imaging and other imaging modalities to localize tumors in patients with Zollinger-Ellison syndrome. *Dig. Dis. Sci.* 38:1318-1328, 1993.
12. Norton, J.A. Surgical treatment of islet cell tumors with special emphasis on operative ultrasound. In: Mignon, M., and Jensen, R.T., eds. *Endocrine tumors of the pancreas: recent advances in research and management*. *Frontiers in Gastrointestinal Research*. Basel: S. Karger; 1995, pp. 309-332.
13. Krenning, E.P., Kwekkeboom, D.J., Oei, H.Y., de Jong, R.J.B., Dop, F.J., Reubi, J.C., and Lamberts, S.W.J. Somatostatin-receptor scintigraphy in gastroenteropancreatic tumors. *Ann. N. Y. Acad. Sci.* 733:416-424, 1994.
14. Krenning, E.P., Kwekkeboom, D.J., Bakker, W.H., Breeman, W.A.P., Kooij, P.P.M., Oei, H.Y., van Hagen, M., Postema, P.T.E., de Jong, M., Reubi, J.C., Visser, T.J., Reijs, A.E.M., Hofland, L.J., Koper, J.W., and Lamberts, S.W.J. Somatostatin receptor scintigraphy with [<sup>111</sup>In-DTPA-D-Phe<sup>1</sup>]- and [<sup>123</sup>I-Tyr<sup>3</sup>]-octreotide: the Rotterdam experience with more than 1000 patients. *Eur. J. Nucl. Med.* 20:716-731, 1993.
15. de Kerviler, E., Cadiot, G., Lebtahi, R., Faraggi, M., le Guludec, D., and Mignon, M. Somatostatin receptor scintigraphy in forty-eight patients with the Zollinger-Ellison syndrome. *Eur. J. Nucl. Med.* 21:1191-1197, 1994.
16. Scherubl, H., Bader, M., Fett, U., Hamm, B., Schmidt-Gayk, H., Koppenhagen, K., Dop, F.J., Riecken, E.O., and Wiedenmann, B. Somatostatin-receptor imaging of neuroendocrine gastroenteropancreatic tumors. *Gastroenterology* 105:1705-1709, 1993.
17. Joseph, K., Stapp, J., Reinecke, J., Skamel, H.J., Höffken, H., Neuhaus, C., Lenze, H., Trautmann, M.E., and Arnold, R. Receptor scintigraphy with <sup>111</sup>In-Pentetreotide for endocrine gastroenteropancreatic tumors. *Horm. Metab. Res.* 27(suppl):28-35, 1993.
18. Hammond, P.J., Arka, A., Peters, A.M., Bloom, S.R., and Gilbey, S.G. Localization of metastatic gastroenteropancreatic tumours by somatostatin receptor scintigraphy with [<sup>111</sup>In-DTPA-D-Phe<sup>1</sup>]-octreotide. *Q. J. Med.* 87:83-88, 1994.
19. Pauwels, S., Leners, N., Fiasse, R., and Jamar, F. Localization of gastroenteropancreatic neuroendocrine tumors with <sup>111</sup>Indium-pentetreotide scintigraphy. *Semin. Oncol.* 21:15-20, 1994.
20. Kvols, L.K. Somatostatin-receptor imaging of human malignancies: a new era in the localization, staging, and treatment of tumors. *Gastroenterology* 105:1909-1914, 1993.
21. Weinel, R.J., Neuhaus, C., Stapp, J., Klotter, H.J., Trautmann, M.E., Joseph, K., Arnold, R., and Rothmund, M. Preoperative localization of gastrointestinal endocrine tumors using somatostatin-receptor scintigraphy. *Ann. Surg.* 218:640-645, 1993.
22. Weber, H.C. and Jensen, R.T. Pancreatic endocrine tumors and carcinoid tumors: recent insights from genetic and molecular biologic studies. In: Dervenis, C.G. ed. *Advances in pancreatic disease. Molecular biology, diagnosis and treatment*. Stuttgart: New York: Georg Thieme Verlag; 1996, pp. 55-75.
23. Zimmer, T., Ziegler, K., Bader, M., Fett, U., Hamm, B., Riecken, E.O., and Wiedenmann, B. Localisation of neuroendocrine tumours of the upper gastrointestinal tract. *Gut* 35:471-475, 1994.
24. Orbuch, M., Doppman, J.L., and Jensen, R.T. Localization of pancreatic endocrine tumors. In: Sleisenger, M.H., and Fordtran, J.S., eds. In: *Pancreatic endocrine tumors* (Issue editor Jensen, R. T.) *Sem. Gastrointest. Dis.* Duluth, MN: W.B. Saunders; 1995, pp. 90-101.
25. Ruszniewski, P., Amouyal, P., Amouyal, G., Grange, J.D., Mignon, M., Bouch, O., and Bernades, P. Localization of gastrinomas by endoscopic ultrasonography in patients with Zollinger-Ellison syndrome. *Surgery* 117:629-635, 1995.
26. Thompson, N.W., Czako, P.F., Fritts, L.L., Bude, R., Bansal, R., Nostrant, T.T., and Scheiman, J.M. Role of endoscopic ultrasonography in the localization of insulinomas and gastrinomas. *Surgery* 116:1131-1138, 1994.
27. Cadiot, G., Lebtahi, R., Sarda, L., Bonnaud, G., Marmuse, J.P., Vissuzaine, C., Ruszniewski, P., le Guludec, D., and Mignon, M. Preoperative detection of duodenal gastrinomas and peripan-

- creatic lymph nodes by somatostatin receptor scintigraphy. *Gastroenterology* 111:845-854, 1996.
28. Zimmer, T., Stolzel, U., Bader, M., Koppenhagen, K., Hamm, B., Buhr, H., Riecken, E.O., and Wiedenmann, B. Endoscopic ultrasonography and somatostatin receptor scintigraphy in the preoperative localisation of insulinomas and gastrinomas. *Gut* 39:562-568, 1996.
  29. Rosch, T., Lightdale, C.J., Botet, J.F., Boyce, G.A., Sivak, M.V., Jr., Yasuda, K., Heyder, N., Palazzo, L., Dancygier, H., and Schusdziarra, V. Localization of pancreatic endocrine tumors by endoscopic ultrasonography. *N. Engl. J. Med.* 326:1721-1726, 1992.
  30. Ruzsniowski, P., Amouyal, P., Amouyal, G., Cadiot, G., Mignon, M., and Bernades, P. Endocrine tumors of the pancreatic area: localization by endoscopic ultrasonography. In: Mignon, M. and Jensen, R.T., eds. *Endocrine tumors of the pancreas: recent advances in research and management*. Series: *Frontiers in Gastrointestinal Research*. Basel: S. Karger; 1995, pp. 258-267.
  31. Glover, J.R., Shorvon, P.J., and Lees, W.R. Endoscopic ultrasound for localisation of islet cell tumours. *Gut* 33:108-110, 1992.
  32. Lightdale, C.J., Botet, J.F., Woodruff, J.M., and Brennan, M.F. Localization of endocrine tumors of the pancreas with endoscopic ultrasonography. *Cancer* 68:1815-1820, 1991.
  33. Palazzo, L., Roseau, G., and Salmeron, M. Endoscopic ultrasonography in the preoperative localization of pancreatic endocrine tumors. *Endoscopy* 24:350-353, 1992.
  34. Gibril, F., Reynolds, J.C., Doppman, J.L., Chen, C.C., Venzon, D.J., Termanini, B., Weber, H.C., Stewart, C.A., and Jensen, R.T. Somatostatin receptor scintigraphy: its sensitivity compared with that of other imaging methods in detecting primary and metastatic gastrinomas: a prospective study. *Ann. Intern. Med.* 125:26-34, 1996.
  35. London, J.F., Shawker, T.H., Doppman, J.L., Frucht, H.H., Vinayek, R., Stark, H.A., Miller, L.S., Miller, D.L., Norton, J.A., Gardner, J.D., and Jensen, R.T. Zollinger-Ellison syndrome: prospective assessment of abdominal US in the localization of gastrinomas. *Radiology* 178:763-767, 1991.
  36. Kloppel, G., Schroder, S., and Heitz, P.U. Histopathology and immunopathology of pancreatic endocrine tumors. In: Mignon, M. and Jensen, R.T., eds. *Endocrine tumors of the pancreas: recent advances in research and management*. Series: *Frontiers of Gastrointestinal Research*. Basel: S. Karger; 1995, pp. 99-120.
  37. Jensen, R.T. Pancreatic endocrine tumors. *Curr. Opin. Gastroenterol.* 11:423-429, 1995.
  38. Kisker, O., Weinel, R.J., Geks, J., Zacara, F., Joseph, K., and Rothmund, M. Value of somatostatin receptor scintigraphy for preoperative localization of carcinoids. *World J. Surg.* 20:162-167, 1996.
  39. Krenning, E.P., Kooij, P.P.M., Pauwels, S., Breeman, W.A.P., Postema, P.T.E., de Herder, W.W., Valkema, R., and Kwekkeboom, D.J. Somatostatin receptor: scintigraphy and radionuclide therapy. *Digestion* 57(suppl 1):57-61, 1996.
  40. Maton, P.N., Miller, D.L., Doppman, J.L., Collen, M.J., Norton, J.A., Vinayek, R., Slaff, J.I., Wank, S.A., Gardner, J.D., and Jensen, R.T. Role of selective angiography in the management of Zollinger-Ellison syndrome. *Gastroenterology* 92:913-918, 1987.
  41. Wank, S.A., Doppman, J.L., Miller, D.L., Collen, M.J., Maton, P.N., Vinayek, R., Slaff, J.I., Norton, J.A., Gardner, J.D., and Jensen, R.T. Prospective study of the ability of computerized axial tomography to localize gastrinomas in patients with Zollinger-Ellison syndrome. *Gastroenterology* 92:905-912, 1987.
  42. Doppman, J.L. Pancreatic endocrine tumors—the search goes on [editorial]. *N. Engl. J. Med.* 326:1770-1772, 1992.
  43. Weber, H.C., Venzon, D.J., Lin, J.T., Fishbein, V.A., Orbuch, M., Strader, D.B., Gibril, F., Metz, D.C., Fraker, D.L., Norton, J.A., and Jensen, R.T. Determinants of metastatic rate and survival in patients with Zollinger-Ellison syndrome: a prospective long-term study. *Gastroenterology* 108:1637-1649, 1995.
  44. Jensen, R.T. Peptide therapy: recent advances in the use of somatostatin and other peptide receptor agonists and antagonists. In: Lewis, J.H. and Dubois, A., eds. *Current Clinical Topics in Gastrointestinal Pharmacology*. Malden, Massachusetts: Blackwell Science, Inc.; 1997, pp. 144-223.
  45. Jensen RT: Gastrin-producing tumors. *Cancer Treatment and Research*. 1996 (in press).
  46. Norton, J.A., Doppman, J.L., and Jensen, R.T. Curative resection in Zollinger-Ellison syndrome: Results of a 10-year prospective study. *Ann. Surg.* 215:8-18, 1992.
  47. Howard, T.J., Zinner, M.J., Stabile, B.E., and Passaro, E., Jr. Gastrinoma excision for cure. A prospective analysis. *Ann. Surg.* 211:9-14, 1990.

48. Jensen, R.T. and Norton, J.A. Endocrine tumors of the pancreas. In: Feldman, M., Scharschmidt, B.F., and Sleisinger, M.H., eds. *Pathology, Diagnosis and Management*, Sixth Edition. Philadelphia: W.B. Saunders; 1998, pp. 871-894.
49. Frucht, H., Howard, J.M., Slaff, J.I., Wank, S.A., McCarthy, D.M., Maton, P.N., Vinayek, R., Gardner, J.D., and Jensen, R.T. Secretin and calcium provocative tests in the Zollinger-Ellison syndrome: A prospective study. *Ann. Intern. Med.* 111:713-722, 1989.
50. Reubi, J.C., Laissue, J., Waser, B., Horisberger, U., and Schaer, J.C. Expression of somatostatin receptors in normal, inflamed, and neoplastic human gastrointestinal tissues. *Ann. N. Y. Acad. Sci.* 733:122-137, 1994.
51. Heitz, P.U., Kasper, M., Polak, J.M., and Kloppel, G. Pancreatic endocrine tumors. *Hum. Pathol.* 13:263-271, 1982.
52. Gibril, F. and Jensen, R.T. Somatostatin receptor scintigraphy in gastrinomas (Letter to the Editor). *Ann. Intern. Med.* 126:741-742, 1997.
53. Mignon, M., Jensen, R.T. (eds): *Endocrine tumors of the pancreas: recent advances in research and management*. Basel: S. Karger; 1995, pp. 1-482.
54. Eriksson, B. and Oberg, K. PPomas and nonfunctioning endocrine pancreatic tumors: clinical presentation, diagnosis, and advances in management. In: Mignon, M., and Jensen, R.T., eds. *Endocrine tumors of the pancreas: recent advances in research and management*. Series: *Frontiers in Gastrointestinal Research*. Basel: S. Karger; 1995, pp. 208-222.
55. Eriksson, B., Oberg, K., and Skogseid, B. Neuroendocrine pancreatic endocrine tumors. Clinical findings in a prospective study of 84 patients. *Acta Oncologica* 28:373-377, 1989.
56. Termanini, B., Gibril, F., Reynolds, J.C., Doppman, J.L., Chen, C.C., Stewart, C.A., Sutliff, V., and Jensen, R.T. Value of somatostatin receptor scintigraphy: A prospective study in gastrinoma of its effect on clinical management. *Gastroenterology* 112:335-347, 1997.
57. Jensen, R.T. Gastrinoma. *Bailliere's Clin. Gastroenterol.* 10:603-644, 1996.